

18207A Flower Hill Way
Gaithersburg, MD 20879
P (301) 926 4707
F (301) 926 4708

PATHOLOGY REPORT / SURGICAL BIOPSY

CBM Pathology
Carla B. MacLeod, M.D.
FNA / Cytopathology
Surgical Pathology

PATIENT: Doe, Jane	DOB: 4/8/1939	Collected: 12/29/2004
Ordering M.D.: Dr. Smith	Case #: S04-3333	Date Added: 12/30/2004
Clinical Dx: Abd pain	Record #: 33333	Completed: 12/30/2004

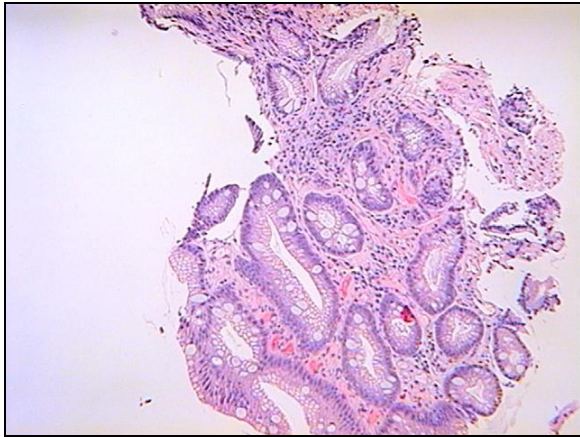
BIOPSY SITE: A) Gastric body; B) Esophagus biopsy.

CLINICAL DATA: Rule out H. pylori. Rule out Barrett's. Abdominal pain.

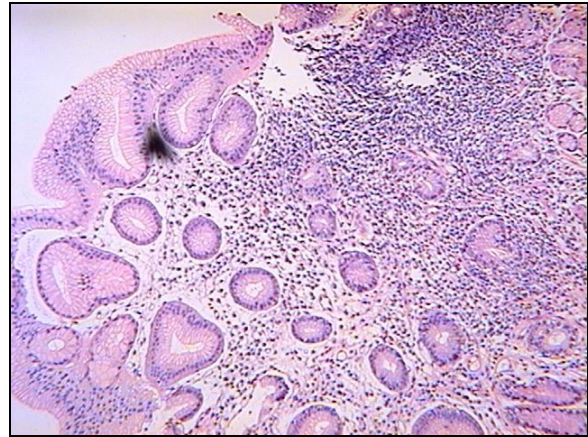
DIAGNOSIS:

A) Gastric body: Mild to moderate chronic gastritis with focal surface congestion and very mild activity, in fragments of fundic and antral-type mucosa. There is focal intestinal metaplasia. There is no evidence of dysplasia. Modified Giemsa stain shows very few microorganisms consistent with H. pylori (control slide is adequate).

B) Esophagus biopsy: Fragments of cardia-type mucosa with a minute focus of intestinal metaplasia consistent with Barrett's esophagus, mild and moderate chronic inflammation and mild regenerative activity. There is no evidence of dysplasia.



A)



B)

GROSS DESCRIPTION: A) Received in formalin are 4 fragments of tan soft tissue, each 0.2-0.3 cm in greatest diameter. Entirely submitted in A. B) Received in formalin are 4 fragments of tan soft tissue, each 0.25-0.5 cm in greatest diameter. Entirely submitted in B.

PREVIOUS CASES: No previous biopsy available.

Pathologist: Carla B. MacLeod, M.D.

Notification: Report faxed to Dr. Smith and to X Surgery Center on 12/30/04.