

18207A Flower Hill Way  
Gaithersburg, MD 20879  
P (301) 926 4707  
F (301) 926 4708



CBM Pathology  
Carla B. MacLeod, M.D.  
FNA / Cytopathology  
Surgical Pathology

## PATHOLOGY REPORT / SURGICAL BIOPSY

**PATIENT:** Doe, Jane

**DOB:** 6/16/1918

**Collected:** 6/6/2004

**Ordering M.D.:** Dr. Smith

**Case #:** S04-4444

**Date Added:** 6/7/2004

**Clinical Dx:** Lesion

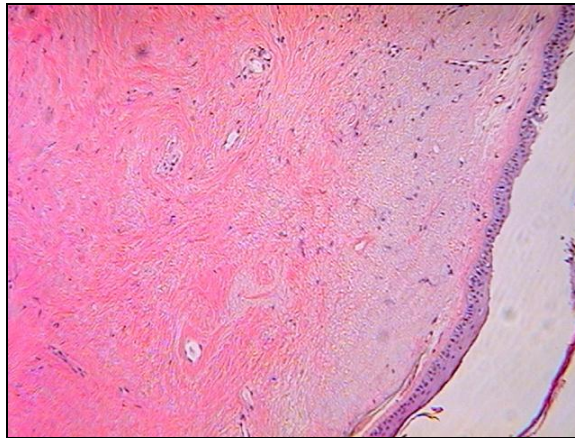
**Record #:** 44444

**Completed:** 6/8/2004

**BIOPSY SITE:** Vulvar lesion.

**CLINICAL DATA:** Vulvar lesion.

**DIAGNOSIS:** Lichen sclerosus et atrophicus.



**MICROSCOPIC DESCRIPTION:** Vulvar skin showing thinned epidermis with loss of rete ridges and underlying edema and homogenization of collagen in upper dermis.

**GROSS DESCRIPTION:** Received in formalin is one fragment of pale tan and smooth skin, 0.3 cm in greatest diameter. No discrete lesions are grossly identified. The entire specimen is submitted in one cassette.

**PREVIOUS CASES:** No previous biopsy available.

**Pathologist:** Carla B. MacLeod, M.D.

**Notification:** Report faxed to Dr. Smith office 6/9/2004