

# Effects of Semantic Impairment on Language Processing in Semantic Dementia

Jamie Reilly, Ph.D.,<sup>1,2</sup> and Jonathan E. Peelle, Ph.D.<sup>3</sup>

## ABSTRACT

---

Semantic dementia is a neurodegenerative disease characterized by progressive loss of conceptual and lexical knowledge. Cortical atrophy remains relatively isolated to anterior and inferior portions of the temporal lobe early in semantic dementia, later affecting more extensive regions of temporal cortex. Throughout much of the disease course, frontal and parietal lobe structures remain relatively intact. This distribution of cortical damage produces a unique language profile. Patients with semantic dementia typically experience profound deficits in language comprehension and production in the context of relatively well-preserved functioning in domains such as phonology, executive function, visuospatial processing, and speech perception. We discuss the effects of semantic impairment on language processing in semantic dementia within the context of an interactive theory of semantic cognition that assumes the active coordination of modality-neutral and modality-specific components. Finally, we argue the need for an etiology-specific language intervention for this population.

**KEYWORDS:** Dementia, language, semantic memory, semantic dementia

**Learning Outcomes:** As a result of this activity, the reader will be able to describe the speech and language profile of semantic dementia.

*Dementia* is a nonspecific term that denotes a constellation of deficits in memory, attention, and behavior that are associated with neurologic impairment. Dementia has a variety

of causes, including the accumulation of neuritic plaques, hypoxia/anoxia, metabolic insufficiencies, or vascular damage. Despite such varied causes, our strongest association

---

<sup>1</sup>Departments of Neurology and Communicative Disorders, University of Florida, Gainesville, Florida; <sup>2</sup>Brain Rehabilitation Research Center, Malcom Randall Veterans Affairs Hospital, Gainesville, Florida; <sup>3</sup>Department of Neurology, University of Pennsylvania School of Medicine, Philadelphia, Pennsylvania.

Address for correspondence and reprint requests: Jamie Reilly, Ph.D., Departments of Neurology & Communica-

tive Disorders, University of Florida, P.O. Box 100174, Gainesville, FL 32610 (e-mail: jreilly@php.ufl.edu).

Semantic Memory and Language Processing in Aphasia and Dementia; Guest Editor, Jamie Reilly, Ph.D.

Semin Speech Lang 2008;29:32–43. Copyright © 2008 by Thieme Medical Publishers, Inc., 333 Seventh Avenue, New York, NY 10001, USA. Tel: +1(212) 584-4662. DOI 10.1055/s-2008-1061623. ISSN 0734-0478.

with dementia is Alzheimer's disease (AD), and indeed AD is the most common form of dementia worldwide.<sup>1</sup> Nevertheless, many other dementia subpopulations exist, each with differing etiologies and cognitive profiles. Frontotemporal dementia (FTD) is one such family of dementias that has recently received considerable attention. Semantic dementia is among the most striking behavioral and anatomic variants of FTD.<sup>2-7</sup>

### WHAT IS SEMANTIC DEMENTIA?

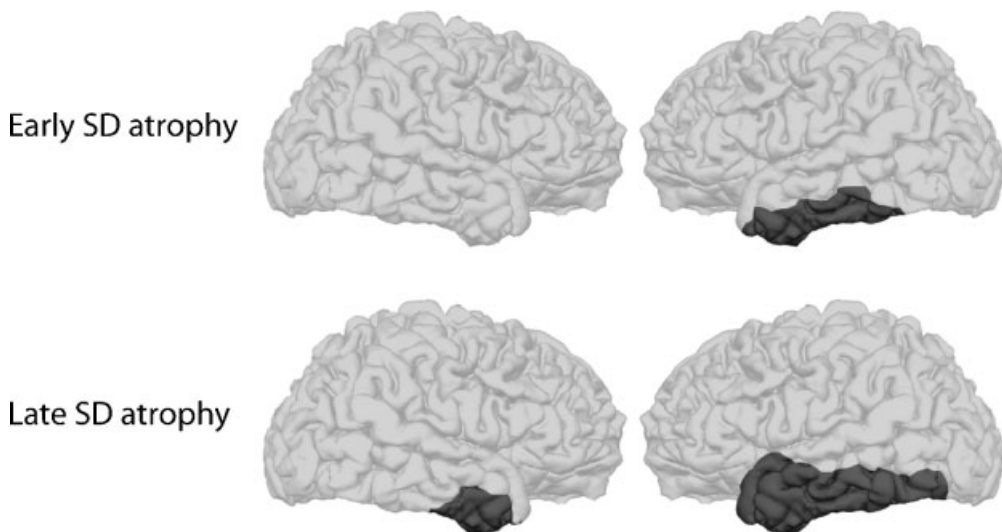
Warrington reported a series of patients who showed severe deficits in object recognition and naming.<sup>8</sup> After ruling out specific perceptual disorders such as visual agnosia, Warrington concluded that these patients experienced a selective loss of conceptual knowledge. This landmark study demonstrated the effects of a selective impairment of semantic memory on language processing. In ensuing years, several similar cases were reported under characteristic descriptions of progressive fluent aphasia and/or primary progressive aphasia (PPA), a condition described by Mesulam as "progressive aphasia without generalized dementia."<sup>9,10</sup> Since the publication of Mesulam's original

work, broad consensus has swung to the conclusion that semantic impairment underlies much of the associated language difficulties in this population. Accordingly, Snowden and colleagues labeled this variant of FTD *semantic dementia* (SD), a term commonly used today.<sup>11</sup>

### ANATOMIC LOCALIZATION OF ATROPHY IN SD

SD is a neurodegenerative disease associated with a progressive reduction of gray matter volume (i.e., cortical atrophy) in specific regions of the temporal lobe. Figure 1 illustrates typical loci of damage in SD in both early and later stages of the disease. Shaded areas indicate regions commonly identified as atrophied in anatomic studies of SD.

The early course of SD is characterized by cortical atrophy that remains relatively confined to anterior, lateral, and ventral portions of the temporal lobe, including the left temporal pole and the inferior and middle temporal gyri.<sup>6,11-13</sup> For unclear reasons, there is often an asymmetric hemispheric presentation of the disease. SD often compromises the left cerebral hemisphere first, later spreading to homologous regions of the right.<sup>2,14</sup>



**Figure 1** Illustration of stereotypical atrophy in patients with evolving SD. SD typically affects the left hemisphere first and most strongly, but eventually damage is apparent bilaterally. The ventral and inferior temporal lobes, particularly the temporal poles, are most strongly affected, although damage extends to include the lateral temporal lobes. Damage to medial temporal lobe areas is generally found to be less extensive than is observed in AD.

One common impression of SD is that medial temporal lobe (MTL) structures remain intact. Behaviorally, SD patients have been reported to show fair recent episodic memory relative to a temporally graded impairment for remote events.<sup>15</sup> For example, an SD patient might better recall details from today's lunch than from his wedding day 40 years ago. In contrast, patients with AD may show the reverse trend, characterized by an advantage in recall for remote over recent events. In AD, this characteristic pattern of forgetting known as anterograde amnesia has been linked to atrophy in MTL regions such as the hippocampus and entorhinal cortex.<sup>12,16</sup> The double dissociation observed between AD and SD in regard to episodic memory suggests greater preservation of MTL structures that support the formation of new episodic memories in SD.

Behavioral inference of preserved MTL was further corroborated by Mummery and colleagues in a structural imaging study, wherein the authors examined regional gray matter atrophy in a cohort of SD patients using voxel-based morphometry.<sup>13</sup> The authors found that significant atrophy did not extend to regions of the MTL such as hippocampal, entorhinal, or perirhinal cortex.<sup>13</sup> It should be noted, however, that other imaging studies have reported conflicting results. For example, Galton et al<sup>12</sup> and van de Pol et al<sup>17</sup> report volumetric loss of the hippocampi of SD patients (left > right; AD > SD). Nevertheless, despite divergence in the published anatomic studies of SD, there is general consensus that the disease compromises lateral temporal cortex to a greater extent than MTL structures that support the formation of new declarative memories.

### CLINICAL DIAGNOSIS OF SD

The differential diagnosis of SD can be difficult because of its overlap in presenting symptoms with AD. However, the distinction is important because these populations require different pharmacologic and behavioral management. In 1998, a clinical consensus meeting delineated a set of core and supporting features for SD.<sup>6</sup> We paraphrase in the following these core criteria with respect to relevant speech and language processing deficits.

### Disturbed Cognitive and Linguistic Functions

Patients with SD experience an insidious onset and gradual worsening of symptoms in the absence of a focal neurologic insult (e.g., stroke or closed head injury). One of the earliest markers is a language disturbance that is characterized by loss of word meaning that affects both production and comprehension. Patients commonly produce semantic paraphasias such as the word "ball" when the target word is "apple." Patients also commonly show prosopagnosia (impaired familiar face recognition) and associative visual agnosia (impaired visual object recognition). As the disease progresses, patients commonly show reading and writing impairments that manifest as surface dyslexia and dysgraphia.

### Preserved Cognitive and Linguistic Functions

Regions of frontal, parietal, and occipital cortex are often spared in SD (Fig. 1). Patients correspondingly present with preserved function in several cognitive domains, including executive processing, personality, calculation, recent episodic memory, visuospatial processing, auditory perception, and speech praxis.<sup>6,18-20</sup> Despite this range of preserved abilities, patients develop profound difficulties negotiating their interactions with the world, and in few domains is this impairment more evident than in language.

### THE RELATIONSHIP BETWEEN VISUAL AGNOSIA, APHASIA, AND SEMANTIC DEGRADATION

Among healthy adults, inferior and ventral portions of the temporal lobe comprise a critical pathway dedicated to visual object recognition. Damage to these structures is associated with visual agnosia, a perceptual disorder wherein patients have difficulties accessing the semantic system for objects presented in a visual modality.<sup>21-23</sup> Optic aphasia, a manifestation of visual agnosia, results in confrontation naming impairment for objects presented visually.<sup>21,24</sup> In both conditions, patients are typically able to access meaning from unimpaired

perceptual modalities (e.g., tactile manipulation or odor). Accordingly, it has been proposed that agnosia and aphasia represent *disconnection* syndromes that affect modality-specific access from a particular modality (e.g., visual or verbal) to the central semantic system.<sup>25</sup>

SD atrophy affects anterior portions of the temporal lobe that form the terminus of the ventral visual processing pathway as well as more ventral structures such as the fusiform gyrus that are also affected in visual agnosia.<sup>26–28</sup> The locus of this damage, therefore, suggests the possibility of a visual-perceptual basis for language difficulties in SD. However, it is also apparent that SD affects left hemisphere temporal lobe structures critical for lexical processing.<sup>9,10</sup> This distribution of damage to both visual association cortex and left hemisphere language regions informed Mesulum's influential theory of PPA.<sup>9,29</sup> Mesulum argued that the PPA poses a double threat to language that consists of associative visual agnosia (i.e., matching a stored visual object description to a concept) and aphasia. One strength of Mesulum's theory is that it makes an explicit, testable prediction. Specifically, core semantic knowledge is maintained in the context of modality-specific access deficits in vision and language. By this account, it should be possible to access knowledge in an alternate modality that is neither linguistically nor visually mediated. For example, one should be able to recognize a rose by its distinctive odor or a thunderstorm by its sound.

It is precisely this notion of a modality-specific access impairment that theoretical opponents have challenged. Counter to the prediction of modality-specific theory, SD patients tend to produce consistent performance across representational formats and tasks (e.g., semantic categorization of words vs. pictures, naming, word-to-definition matching). An example of such homogeneity was demonstrated by Bozeat et al,<sup>30</sup> who tested the ability of SD patients to identify environmental sounds. Patients were impaired on this task, showing no significant advantage for audition over words or pictures.<sup>30</sup> Other lines of research have demonstrated that SD patients show increasing impairment in demonstrating the appropriate

use of tools<sup>31</sup> and gesturing the functions of common objects<sup>32</sup> (but see Buxbaum et al<sup>33</sup>). Such cross-modality consistency is difficult to reconcile within a theory of impaired modality-specific access to an intact semantic system.

Tyler, Moss, and colleagues offer a “softer” visual degradation theory of SD, citing extensive research in cortical visual processing of nonhuman primates.<sup>34,35</sup> Ablation of the ventromedial temporal cortex of the Macaque impairs the animal's ability to make fine-grained visual distinctions.<sup>34</sup> Tyler et al demonstrated in functional imaging of healthy adults that an analogous area of cortex to that ablated in the Macaque (i.e., perirhinal cortex) is active when naming common objects at the basic category level (e.g., dog vs. cat) but not active when making domain-level judgments (e.g., living thing or man-made object).<sup>35</sup> Tyler et al suggested that perirhinal cortex may be critical for polymodal conjunctions of features (leg + torso + head) that are fundamental for discriminating objects.<sup>36</sup> Consistent with this view of fine-grained visual specificity, Tyler and colleagues speculate that damage to perirhinal cortex may underlie deficits in patient populations such as individuals with SD and herpes simplex viral encephalitis.<sup>35</sup> Specifically, a progressive loss of fine-grained visual specificity should produce characteristic naming impairments where general information about object domain is retained but distinctions within specific category coordinates (e.g., CAT vs. DOG) are lost.

On the surface, this perspective fits theories of hierarchical semantic organization in healthy, normal adults. SD patients typically show impairment for distinguishing between basic-level concepts, tending to make coordinate and superordinate semantic naming errors (e.g., “horse” or “animal” for dog).<sup>5,32,37–40</sup> The same hierarchical taxonomic loss is evident in concept definitions and in delayed picture copying tasks where SD patients have been observed to assign prototypic features to a particular exemplar. For example, Bozeat et al report the case of an SD patient who showed a striking prototypicality effect in delayed picture drawing/copying—adding four legs to a picture of a duck.<sup>41</sup> The authors attributed this “bottom up” loss of specificity squarely within the

semantic system rather than isolating the effect to higher-level visual processing. Therefore, although promising, Moss and Tyler's theory of fine-grained visual specificity awaits further empirical support in brain-behavior correlations with SD patients.

### **THEORIES OF KNOWLEDGE LOSS IN SD: WHAT DEGRADES?**

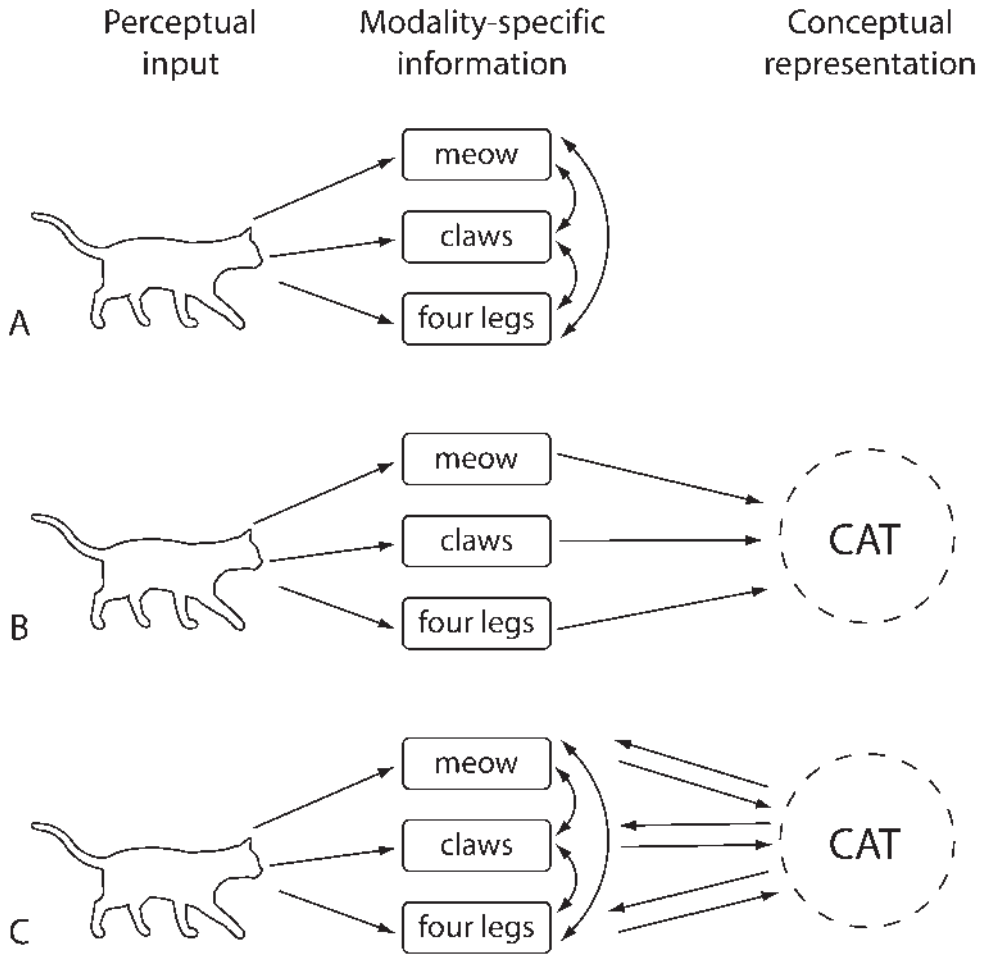
There is general consensus that SD is not a disorder of higher-level visual perception or aphasia but, rather, a progressive loss of semantic knowledge.<sup>42-50</sup> The organization of such knowledge, however, remains an issue of theoretical contention. The theoretical distinctions are valuable for a clinician to understand because familiarity with basic theories of semantic organization is essential toward developing intervention strategies for semantically based language disorders. If, for example, one assumes that knowledge is intact but inaccessible, strategies for language rehabilitation can focus on circumventing the impaired route or strengthening weakened associations (see Kiran and Bassetto,<sup>51</sup> this issue). However, degraded core knowledge is not amenable to such approaches and may require more extensive "reconstruction" of large-scale semantic networks.

Dominant theories of semantic memory are subsumed under two general approaches. For brevity, we term these approaches *distributed/embodied* and *amodal*. Distributed/embodied theories assume that the brain decomposes objects into different features (e.g., DOG → tail, fur, barking, etc.) and that these constituent features are stored in cortical regions related to modality-specific perceptions that are also active during actual perception of the object.<sup>52-54</sup> The coactivation of these regions is necessary for remotely evoking the original concept. For example, one's concept of a dog may include visual information, auditory information, olfactory detail, and so forth. According to distributed/embodied theories, visual information associated with DOG would be stored in areas important for perceiving visual features along the ventral temporal lobe and auditory information near primary auditory areas. When the concept of DOG is activated,

one would expect to observe cortical activation in each of the sensory domains. Importantly, this coactivation is expected to occur regardless of how the concept is activated. For example, a word that has strong auditory associations (e.g., THUNDER) should recruit brain regions involved in auditory perception, even when read silently. The distributed/embodied approach is supported by functional neuroimaging studies that demonstrate a strong link between perception and conceptual representation, such as the finding that pictures of appetizing food engage gustatory cortex<sup>55</sup> or that pictures of tools activate cortical areas dedicated to grasp in premotor cortex.<sup>56,57</sup>

Although fully distributed or embodied approaches to semantic cognition are appealing in their parsimony, SD presents a puzzle for such theories. SD patients with intact auditory and premotor cortex do not typically show processing advantages for concepts with highly salient features in domains such as environmental sounds or tools.<sup>30</sup> One way to account for such uniform degradation of knowledge is to assume that semantic memory involves a set of abstract, modality-neutral representations. That is, the original sensory features that compose an object are encoded in more of an abstract, propositional form. Such an approach, inspired in large part by SD patients' performance, has been advanced by Rogers and colleagues, who propose that information from different sensory modalities ultimately converges with other types of affective and verbally mediated knowledge.<sup>14,49,58-60</sup> The authors have hypothesized that such convergence occurs in anterior temporal cortex (i.e., the temporal pole), the cortical region where SD patients typically show the greatest degree of atrophy (J. Reilly et al, unpublished data, 2008).<sup>12,13,61,62</sup>

Figure 2 provides a schematic of three models of semantic cognition. In a fully distributed approach shown in Fig. 2A, perceptual information activates regions of modality-specific cortex, and conceptual knowledge is the concurrent activation of a unique combination of these nodes. A strong amodal account, illustrated in Fig. 2B, hypothesizes that perceptual information feeds into central semantic store where semantic memory is stored. We



**Figure 2** Schematic illustrations of three models of semantic representation. (A) In a fully distributed/embodied model, perceptual input activates modality-specific areas of cortex; this coactivation is in itself the conceptual representation. (B) In an amodal view of semantics, perceptual information activates modality-specific regions of cortex, which feed into an amodal store where the concept is represented. (C) A hybrid approach to object representation, advocated in the current article, posits that sparse representation of a concept is stored amodally but that modality-specific regions of cortex must be activated for detailed perceptual information.

have proposed a theory of semantic organization that synthesizes the fully distributed and modality-neutral approaches, shown in Fig. 2C. We hypothesize that object concepts are stored in lateral temporal cortex as modality-neutral representations.<sup>50,52</sup> We agree that information from different modalities (verbal knowledge, hearing, vision) converges upon a single, unitary representation (e.g., CAT). However, this representation is “sparse” in that it is stripped of its original sensory detail. It is not equivalent to encyclopedic or verbal knowledge

because it has access to the original perceptual features of an object. To enrich this sparse representation, it is necessary to index modality-specific regions of cortex, and this indexing is governed by external task demands. For example, if we ask the reader to make a relative size judgment of two animals presumably not in view—“Is a Labrador retriever larger than a poodle?”—we expect her to access abstract semantic representations of “retriever” and “poodle” and then recruitment of visual association cortex to aide in making a relative size



judgment. However, if asked, "Is a Labrador retriever friendlier than a poodle?" we predict less recruitment of visual association cortex and more activation of cortical regions dedicated to affective knowledge (e.g., amygdala). Thus, we hypothesize that there is dynamic interactivity in semantic memory between modality-neutral and modality-specific components (J. Reilly et al, unpublished data).<sup>61</sup>

### MODALITY-SPECIFIC AND MODALITY-NEUTRAL LOSS IN SD

We believe that semantic impairment in SD reflects compromise of two major systems: (1) abstract semantic representations stored in lateral temporal cortex; and (2) visual semantic feature knowledge stored in the ventral temporal pathway of visual object recognition. By this account, as SD progresses patients would be expected to lose core concepts that support language. Moreover the additional loss of visual association cortex should differentially impact concepts with high visual salience. Relative processing differences for abstract and concrete words in SD provide evidence for this dual component loss.

Healthy adults typically show advantages for concrete words (e.g. dog) over abstract words (e.g., love). This advantage, referred to as the *word concreteness effect*, is apparent across many domains, including speed and accuracy of word recognition,<sup>62</sup> word list recall,<sup>63</sup> age of acquisition,<sup>64</sup> and reading.<sup>65</sup> Theories of semantic memory differ in their explanations of the word concreteness effect, but one common assumption is that the additional visual salience associated with concrete words facilitates their processing over abstract words.<sup>66</sup> Some SD patients have been reported to show striking *reverse concreteness effects* in their language processing (i.e., advantages for abstract over concrete words). This controversial effect has been reported in naming,<sup>67</sup> word-to-definition matching,<sup>68</sup> lexical decision latencies,<sup>61</sup> and single-word semantic judgments.<sup>20</sup> In our work, we have found that these abstract word advantages are *relative* in that both word types are subject to impairment. This degree of uniformity is consistent with the degradation of core semantic knowledge that underlies both

concrete and abstract words. Moreover, the additional impairment for concrete words sometimes seen in SD is also consistent with loss of visual feature knowledge stored in modality-specific regions of inferior temporal cortex (i.e., the ventral visual pathway).

### NAMING AND KNOWING IN SD

Profound naming difficulties are a common feature of SD.<sup>6,11,14,69-71</sup> A central question concerns whether associated naming deficits result from the loss of conceptual knowledge (semantic anomia), lexical degradation, or an inability to link phonologic word forms to their corresponding semantic representations (pure anomia). Evidence that SD reflects true semantic anomia is derived from several elegant lines of research demonstrating strong correlations between semantic knowledge and naming ability. Lambon Ralph and colleagues, for example, contrasted quality of the content of concept definitions for successfully named words versus words for which patients were anomic.<sup>47</sup> SD patients consistently produced richer definitions for objects that they were able to name successfully, thus demonstrating a strong correlation between "naming" and "knowing."

Patterson and colleagues have argued that the relation between naming and knowing in SD reflects a strong frequency-by-typicality interaction in semantic memory.<sup>19,48</sup> That is, low-frequency, atypical members of semantic categories (e.g., penguins) are most vulnerable to semantic degradation, whereas high-frequency, prototypical category members (e.g., robins) prove more resilient to such loss. Lambon Ralph accordingly hypothesized that as SD progresses, this loss of bottom-up specificity causes category exemplars to merge into their most frequent prototypes. For example, "cat" is a prototypical small animal, and SD patients may use the label for other small animals. This loss of specificity ultimately compromises semantic memory so that patients name exemplars at a very nonspecific level (e.g., producing "animal" or "thing" in place of bird).<sup>14</sup>

Several SD case studies support these predictions. Hodges et al reported the longitudinal

case of an SD patient who could successfully name a cat and an elephant, but less than 2 years later he called both "animal."<sup>38</sup> This lack of specificity is also apparent in picture drawing, where patients are asked to reproduce a picture from memory after a brief delay. SD patient D.S. could accurately copy a rhinoceros when directly viewing the picture. However, the picture was removed from sight and after a 10-second delay, the patient's reproduction was conspicuously missing distinctive features such as horns and armor.<sup>48</sup> Again, this is consistent with a loss of hierarchical specificity: the patient recognizes the drawing as a type of animal but not as the distinct subordinate "rhinoceros."<sup>41</sup>

### DISCOURSE PRODUCTION IN SD

One of the most striking characteristics of SD is preserved functioning in nonsemantic domains. Anecdotally, it is often difficult to detect impairment in casual conversation with an SD patient. Individuals with SD tend to produce fluent, well-formed utterances and pepper their conversations with overlearned phrases (e.g., "Oh, I'm doing just fine."). Yet, closer scrutiny reveals that language content is remarkably empty and circumlocutory.

A handful of studies have examined the quality of discourse production in SD. Bird et al described both the content and form of SD narratives elicited through the "Cookie Theft" picture description of the Boston Diagnostic Examination of Aphasia in a longitudinal case study of three SD patients.<sup>40,72</sup> Speech rate in patients was comparable with that of age-matched controls, but patients showed significant content differences. Consistent with the authors' theory of a frequency-by-typicality interaction, SD patients produced fewer low-frequency nouns (e.g., "fork") as a function of disease severity. These individuals did, however, retain highly frequent closed class words (e.g., "the") and verbs (e.g., "went"). Bird and colleagues found that the overall level of meaningful content in SD narratives showed a linear decline across time. Narrative was thus marked by the production of large amounts of closed class words (e.g., "the," "this") and generic verbs (e.g., "went") in the context of a sweeping loss of nouns from the narrative repertoire.

Using a different method of eliciting discourse, Ash and colleagues examined SD discourse by asking patients to narrate a wordless children's picture book.<sup>73</sup> This task permitted the investigators to examine several factors, including global connectedness of events, conveyance of story gist, and referencing temporally remote events. Not surprisingly, SD patients had great difficulties narrating the story. Output was reduced relative to age-matched controls (SD = 81 words per minute [wpm]; controls = 142 wpm), and patients were observed to provide many nonspecific references (e.g., "that thing"). Ash et al also noted the predominance of nonspecific pronominal references (e.g., "he" for main characters) and general superordinate terms (e.g., "animal" or "critter" instead of "dog" and "frog"). Despite severe anomia, patients were able to demonstrate knowledge of global connectivity across the episodes of the story, suggesting at least some degree of preservation of story gist.

### PHONOLOGIC PRESERVATION IN SD

Phonology remains a clear strength until the very latest stages of SD,<sup>19,74</sup> suggesting that SD patients may show increasing reliance upon phonology to process language as their lexical-semantic systems decline.<sup>75-77</sup> This hypothesis has a basis in the characteristics of speech perception of healthy adults, who make active use of phonologic cues in the speech stream to speed the efficiency of language processing. For example, word length and syllable stress patterns provide listeners with probabilistic markers of grammatical class (i.e., nouns longer than verbs, nouns hold initial syllable stress).<sup>78</sup> Similar phonologic differences may aid listeners in making rapid semantic distinctions (abstract words are longer and more derivationally complex than concrete).<sup>78,79</sup>

In a series of experiments, we examined such "bootstrapping effects" in SD. Perhaps the most striking example came from a study of single-word semantic judgments in which we varied words by both their meaning and form.<sup>20</sup> SD patients made forced-choice judgments of meaning for words that differed by length (one or three syllables), grammatical class (verb or



noun), and concreteness (abstract or concrete).<sup>20</sup> Patients heard each word and answered yes/no to the question, "Can you see, hear, or touch this?" In this task, SD patients showed relative sensitivity to word form in the context of insensitivity to the experimental manipulation of word meaning. Patients often misclassified longer concrete words (e.g., "apartment") as abstract and shorter abstract words (e.g., "truth") as concrete. From this response pattern, we concluded that SD patients exercise sensitivity to a phonologically mediated property of English word meaning.

### READING AND WRITING IN SD

The relative preservation of phonology in SD is also evident in the domain of written language. Reading and writing difficulties are prevalent, manifesting as surface dyslexia and dysgraphia in SD.<sup>80-83</sup> These disorders are characterized by impairment in reading and spelling orthographically irregular words, a pattern commonly interpreted to reflect overreliance upon grapheme-to-phoneme conversion (i.e., letter-by-letter reading). Thus, when words conform to orthographic regularity (e.g., "cat"), SD patients are often able to produce the target correctly. However, in situations where lexical-semantic knowledge is necessary to overcome imperfect grapheme-phoneme correspondence (e.g., "yacht"), SD patients show marked impairment.<sup>84,85</sup> Surface dyslexia has thus been described as "reading without semantics."

### FUTURE DIRECTIONS FOR BEHAVIORAL TREATMENT

Here we have described the unique profile of semantic impairment associated with SD. This neurodegenerative disease presents an *in vivo* model for discerning the structure and deterioration of semantic memory, and for this reason there is great interest in this population within the cognitive neuroscience community. Unfortunately, this interest has produced only marginal spillover toward the development of a language intervention for this population (see Jokel et al<sup>86</sup> and Snowden and Neary<sup>71</sup> for noteworthy exceptions). Perhaps the most significant challenge to developing a treatment for

SD is the dynamic nature of the disease. In aphasia resulting from stroke, the associated language impairment is typically static or improving, whereas SD is associated with progressive deterioration. This fundamental difference necessitates a very different approach to language treatment in these populations.

One naïve strategy is to attempt to retrain the structure of forgotten concepts in SD as these difficulties emerge. As patients become anomie for specific items, training would focus on rebuilding that particular concept. We (and others) have argued that this reactive approach is inherently flawed, because while training is occurring on a recently lost concept, other concepts are concurrently being lost (J. Reilly et al, unpublished data; Kwok et al<sup>74</sup>). Instead, we have proposed that maintenance of a carefully structured set of core vocabulary is likely to produce the best functional results for SD. Rather than reacquisition of forgotten concepts, patients should focus on preserving a strongly combinatorial set of known words as the disease progresses. Jokel and colleagues have shown very promising results applying a similar maintenance strategy to SD.<sup>86</sup> A necessary requirement of this approach is the identification of key items early on in the disease process so that these concepts and their usage can be reinforced.

### CONCLUSION

Our goal in this review was to describe of the profile of SD within the context of a broader theory of semantic knowledge. We hypothesize that semantic memory involves active coordination between modality-specific and modality-neutral representations and that SD likely compromises the integrity of both components (J. Reilly et al, unpublished data). This includes progressive degradation of abstract, modality-neutral representations in lateral temporal cortex, and the additional loss of modality-specific regions of visual association cortex critical for the storage of visual feature knowledge. The progressive decline of lexical and semantic knowledge in SD differentiates this disease from other forms of dementia and aphasia. We argue accordingly that there is a need for an etiology-specific treatment approach for this

population. Although there is not yet an accepted best practice for behavioral treatment, recent developments in elucidating the organization of semantic knowledge in this population offer encouraging targets for intervention. One promising approach is focused on the maintenance of a core set of vocabulary as disease severity worsens.

#### ACKNOWLEDGMENT

This work was supported in part by NIH grants DC001924–11a2 and NS54575.

#### REFERENCES

1. Hebert LE, Scherr PA, Bienias DA, Evans DA. Annual incidence of Alzheimer's disease in the United States projected to the years 2000 through 2050. *Alzheimer Dis Assoc Disord* 2001;15:169–173
2. Gorno-Tempini ML, Dronkers NF, Rankin KP, et al. Cognition and anatomy in three variants of primary progressive aphasia. *Ann Neurol* 2004;55:335–346
3. Hodges JR, Davies RR, Xuereb JH, et al. Clinicopathological correlates in frontotemporal dementia. *Ann Neurol* 2004;56:399–406
4. Hodges JR, Patterson K. Nonfluent progressive aphasia and semantic dementia: a comparative neuropsychological study. *J Int Neuropsychol Soc* 1996;2:511–524
5. Hodges JR, Patterson K, Oxbury S, Funnell E. Semantic dementia: progressive fluent aphasia with temporal lobe atrophy. *Brain* 1992;115:1783–1806
6. Neary D, Snowden JS, Gustafson L, et al. Frontotemporal lobar degeneration: a consensus on clinical diagnostic criteria. *Neurology* 1998;51:1546–1554
7. Peelle JE, Grossman M. Language processing in frontotemporal dementia: a brief review. *Language and Linguistics Compass* 2008;2:18–35
8. Warrington EK. The selective impairment of semantic memory. *Q J Exp Psychol* 1975;27:635–657
9. Mesulam M. Slowly progressive aphasia without generalized dementia. *Ann Neurol* 1982;11:592–598
10. Mesulam M. Primary progressive aphasia: a language-based dementia. *N Engl J Med* 2003;349:1535–1542
11. Snowden JS, Goulding PJ, Neary D. Semantic dementia: a form of circumscribed cerebral atrophy. *Behav Neurol* 1989;2:167–182
12. Galton CJ, Patterson K, Graham K, et al. Differing patterns of temporal atrophy in Alzheimer's disease and semantic dementia. *Neurology* 2001;57:216–225
13. Mummery CJ, Patterson K, Price CJ, Ashburner J, Frackowiak RSJ, Hodges JR. A voxel-based morphometry study of semantic dementia: relationship between temporal lobe atrophy and semantic memory. *Ann Neurol* 2000;47:36–45
14. Lambon Ralph MA, McClelland JL, Patterson K, Galton CJ, Hodges JR. No right to speak? The relationship between object naming and semantic impairment: neuropsychological evidence and a computational model. *J Cogn Neurosci* 2001;13:341–356
15. Graham KS, Patterson K, Hodges JR. Episodic memory: new insights from the study of semantic dementia. *Curr Opin Neurobiol* 1999;9:245–250
16. Harasty JA, Halliday GM, Kril JJ, Code C. Specific temporoparietal gyral atrophy reflects the pattern of language dissolution in Alzheimer's disease. *Brain* 1999;122:675–686
17. van de Pol LA, Hensel A, van der Flier WM, et al. Hippocampal atrophy on MRI in frontotemporal lobar degeneration and Alzheimer's disease. *J Neurol Neurosurg Psychiatry* 2006;77:439–442
18. Halpern CH, Glosser G, Clark R, et al. Dissociation of numbers and objects in cortico-basal degeneration and semantic dementia. *Neurology* 2004;62:1163–1169
19. Jefferies E, Patterson K, Lambon Ralph MA. The natural history of late-stage “pure” semantic dementia. *Neurocase* 2006;12:1–14
20. Reilly J, Cross K, Troiani V, Grossman M. Single word semantic judgments in semantic dementia: do phonology and grammatical class count? *Aphasiology* 2007;21:558–569
21. Farah MJ. The neurological basis of mental imagery: a computational analysis. *Cognition* 1984;18:245–272
22. Humphreys GW, Forde EME. Hierarchies, similarity, and interactivity in object recognition: “category-specific” neuropsychological deficits. *Behav Brain Sci* 2001;24:453–509
23. Humphreys GW, Riddoch MJ. Features, objects, action: the cognitive neuropsychology of visual object processing, 1984–2004. *Cogn Neuropsychol* 2006;23:156–183
24. Caramazza A, Mahon BZ. The organization of conceptual knowledge: the evidence from category-specific semantic deficits. *Trends Cogn Sci* 2003;7:354–361
25. Geschwind N. Disconnexion syndromes in animals and man. *Brain* 1965;88:237–297
26. Farah MJ, McClelland JL. A computational model of semantic memory impairment: modality specificity and emergent category specificity. *J Exp Psychol* 1991;120:339–357

27. Humphreys GW, Riddoch MJ. A case series analysis of "category-specific" deficits of living things: the HIT account. *Cogn Neuropsychol* 2003;20:263–306
28. Martin A, Chao LL. Semantic memory and the brain: structure and processes. *Curr Opin Neurobiol* 2001;11:194–201
29. Mesulam M. Primary progressive aphasia. *Ann Neurol* 2001;49:425–432
30. Bozeat S, Lambon Ralph MA, Patterson K, Garrard P, Hodges JR. Non-verbal semantic impairment in semantic dementia. *Neuropsychologia* 2000;38:1207–1215
31. Bozeat S, Lambon Ralph MA, Patterson K, Hodges JR. When objects lose their meaning: what happens to their use? *Cogn Affect Behav Neurosci* 2002;2:236–251
32. Coccia M, Bartolini M, Luzzi S, Provinciali L, Lambon Ralph MA. Semantic memory is an amodal, dynamic system: evidence from the interaction of naming and object use in semantic dementia. *Cogn Neuropsychol* 2004;21:513–527
33. Buxbaum LJ, Schwartz MF, Carew TG. The role of semantic memory in object use. *Cogn Neuropsychol* 1997;14:219–254
34. Bussey TJ, Saksida LM. The organization of visual object representations: a connectionist model of effects of lesions in perirhinal cortex. *Eur J Neurosci* 2002;15:355–364
35. Tyler LK, Stamatakis EA, Bright P, et al. Processing objects at different levels of specificity. *J Cogn Neurosci* 2004;16:351–362
36. Moss HE, Rodd JM, Stamatakis EA, Bright P, Tyler LK. Anteromedial temporal cortex supports fine-grained differentiation among objects. *Cereb Cortex* 2005;15:616–627
37. Grossman M, Ash S. Primary progressive aphasia: a review. *Neurocase* 2004;10:3–18
38. Hodges JR, Graham N, Patterson K. Charting the progression in semantic dementia: implications for the organisation of semantic memory. *Memory* 1995;3:463–495
39. Hodges JR. Semantic dementia: disorder of semantic memory. In: D'Esposito M, ed. *Neurological Foundations of Cognitive Neuroscience*. Cambridge, MA: MIT Press; 2003:67–87
40. Bird H, Lambon Ralph MA, Patterson K, Hodges JR. The rise and fall of frequency and imageability: noun and verb production in semantic dementia. *Brain Lang* 2000;73:17–49
41. Bozeat S, Lambon Ralph MA, Graham KS, et al. A duck with four legs: Investigating the structure of conceptual knowledge using picture drawing in semantic dementia. *Cogn Neuropsychol* 2003;20:27–47
42. Funnell E. Evidence for scripts in semantic dementia: implications for theories of semantic memory. *Cogn Neuropsychol* 2001;18:323–341
43. Cipolotti L, Warrington EK. Semantic memory and reading abilities: a case report. *J Int Neuropsychol Soc* 1995;1:104–110
44. Moss HE, Tyler LK, Hodges JR, Patterson K. Exploring the loss of semantic memory in semantic dementia: evidence from a primed monitoring study. *Neuropsychology* 1995;9:16–26
45. Hodges JR, Bozeat S, Lambon Ralph MA, Patterson K, Spatt J. The role of conceptual knowledge in object use: evidence from semantic dementia. *Brain* 2000;123:1913–1925
46. Graham KS, Simons JS, Pratt KH, Patterson K, Hodges JR. Insights from semantic dementia on the relationship between episodic and semantic memory. *Neuropsychologia* 2000;38:313–324
47. Lambon Ralph MA, Graham KS, Patterson K, Hodges JR. Is a picture worth a thousand words? Evidence from concept definitions by patients with semantic dementia. *Brain Lang* 1999;70:309–335
48. Patterson K. The reign of typicality in semantic memory. *Philos Trans Roy Soc B. Biol Sci* 2007;362:813–821
49. Rogers TT, Hocking J, Noppeney U, et al. Anterior temporal cortex and semantic memory: reconciling findings from neuropsychology and functional imaging. *Cogn Affect Behav Neurosci* 2006;6:201–213
50. Snowden JS, Griffiths H, Neary D. Semantic dementia: autobiographical contribution to preservation of meaning. *Cogn Neuropsychol* 1994;11:265–292
51. Kiran S, Bassetto G. Evaluating the effectiveness of semantic based treatment for naming deficits in aphasia: what works? *Semin Speech Lang* 2008;29:71–82
52. Barsalou LW, Simmons WK, Barbey AK, Wilson CD. Grounding conceptual knowledge in modality-specific systems. *Trends Cogn Sci* 2003;7:84–91
53. Pecher D, Zeelenberg R, Barsalou LW. Sensorimotor simulations underlie conceptual representations: modality-specific effects of prior activation. *Psychon Bull Rev* 2004;11:164–167
54. Simmons WK, Barsalou LW. The similarity-in-topography principle: reconciling theories of conceptual deficits. *Cogn Neuropsychol* 2003;20:451–486
55. Simmons WK, Martin A, Barsalou LW. Pictures of appetizing foods activate gustatory cortices for taste and reward. *Cereb Cortex* 2005;15:1602–1608
56. Martin A, Wiggs CL, Ungerleider LG, Haxby JV. Neural correlates of category-specific knowledge. *Nature* 1996;379:649–652
57. Pulvermuller F. Brain mechanisms linking language and action. *Nat Rev Neurosci* 2005;6:576–582

58. Jefferies E, Lambon Ralph MA. Semantic impairment in stroke aphasia versus semantic dementia: a case-series comparison. *Brain* 2006;129:2132–2147
59. Rogers TT, Hodges JR, Lambon Ralph MA, Patterson K. Object recognition under semantic impairment: the effects of conceptual regularities on perceptual decisions. *Lang Cogn Process* 2003;18:625–662
60. Rogers TT, Lambon Ralph MA, Garrard P, et al. Structure and deterioration of semantic memory: a neuropsychological and computational investigation. *Psychol Rev* 2004;111:205–235
61. Reilly J, Peelle J, Grossman M. A unitary semantics account of reverse concreteness effects in semantic dementia. *Brain Lang* 2007;103:86–87
62. Kroll JF, Merves JS. Lexical access for concrete and abstract words. *J Exp Psychol Learning Memory*. *Cognition* 1986;12:92–107
63. Walker I, Hulme C. Concrete words are easier to recall than abstract words: evidence for a semantic contribution to short-term serial recall. *J Exp Psychol Learn Mem Cogn* 1999;25:1256–1271
64. Reilly J, Chrysikou E, Ramey CH. Support for hybrid models of the age of acquisition of English nouns. *Psychon Bull Rev* 2007;20(6):1164–1170
65. Sadoski M, Paivio A. *Imagery and Text: A Dual Coding Theory of Reading and Writing*. Mahwah, NJ: Lawrence Erlbaum; 2001
66. Paivio A. *Mental Representations: A Dual Coding Approach*. New York, NY: Oxford University Press; 1985
67. Breedin SD, Saffran EM, Coslett HB. Reversal of the concreteness effect in a patient with semantic dementia. *Cogn Neuropsychol* 1994;11:617–660
68. Yi H, Moore P, Grossman M. Reversal of the concreteness effect for verbs in semantic dementia. *Cogn Neuropsychol* 2007;21:1–19
69. Grossman M. Frontotemporal dementia: a review. *J Int Neuropsychol Soc* 2002;8:566–583
70. Grossman M, McMillan C, Moore P, et al. What's in a name: voxel-based morphometric analyses of MRI and naming difficulty in Alzheimer's disease, frontotemporal dementia and corticobasal degeneration. *Brain* 2004;127:628–649
71. Snowden JS, Neary D. Relearning of verbal labels in semantic dementia. *Neuropsychologia* 2002;40:1715–1728
72. Goodglass H, Kaplan E. *The Assessment of Aphasia and Related Disorders*. 2nd ed. Philadelphia, PA: Lea and Feibiger; 1983
73. Ash S, Moore P, Antani S, McCawley G, Work M, Grossman M. Trying to tell a tale: discourse impairments in progressive aphasia and fronto-temporal dementia. *Neurology* 2006;66:1405–1413
74. Kwok S, Reilly J, Grossman M. Acoustic-phonetic processing in semantic dementia. *Brain Lang* 2006;99:145–146
75. Reilly J, Grossman M. Language processing in dementia. In: Budson A, Kowell N, eds. *Alzheimer's Disease and Associated Disorders*. Edinburgh, Scotland: Blackwell Synergy Press; In press
76. Reilly J, Martin N, Grossman M. Effects of semantic impairment on repetition and verbal short-term memory: evidence from semantic dementia. *Brain Lang* 2004;91:140–141
77. Reilly J, Martin N, Grossman M. Verbal learning in semantic dementia: is repetition priming a useful strategy? *Aphasiology* 2005;19:329–339
78. Kelly MH. Using sound to solve syntactic problems: the role of phonology in grammatical category assignments. *Psychol Rev* 1992;99:349–364
79. Reilly J, Kean J. Formal distinctiveness of high- and low-imageability nouns: analyses and theoretical implications. *Cogn Sci* 2007;31:1–12
80. Patterson K, Lambon Ralph MA, Jefferies E, et al. "Presemantic" cognition in semantic dementia: six deficits in search of an explanation. *J Cogn Neurosci* 2006;18:169–183
81. Patterson K, Lambon Ralph MA. Selective disorders of reading? *Curr Opin Neurobiol* 1999;9:235–239
82. Blazely AM, Coltheart M, Casey BJ. Semantic impairment with and without surface dyslexia: implications for models of reading. *Cogn Neuropsychol* 2005;22:695–717
83. Shallice T, Warrington EK, McCarthy R. Reading without semantics. *Q J Exp Psychol A* 1983;35A:111–138
84. Coltheart M. Deep dyslexia is right-hemisphere reading. *Brain Lang* 2000;71:299–309
85. Coltheart M, Rastle K, Perry C, Langdon R, Ziegler J. DRC: a dual route cascaded model of visual word recognition and reading aloud. *Psychol Rev* 2001;108:204–256
86. Jokel R, Rochon E, Leonard C. Treating anomia in semantic dementia: Improvement, maintenance, or both? *Neuropsychol Rehabil* 2006;16:241–256