Canadian Association of Radiologists' Journal
1-8

DOI: 10.1177/0846537120916419
journals.sagepub.com/home/caj
SAGE

The Role of Emergency Radiology in COVID-19: From Preparedness to Diagnosis

Muhammad Umer Nasir, MBBS, FCPS[1], James Roberts, MD, MSc[2], Nestor L. Muller, MD, PhD, FRCPC[3], Francesco Macri, MD, PhD[1], Mohammed F. Mohammed, MD, SB-RAD, CIIP[4], Shahram Akhlaghpoor, MD[5], William Parker, MD[2], Arash Eftekhari, MD[6], Susan Rezaei, MD[7], John Mayo, MD, FRCPC[3], and Savvas Nicolaou, MD, FRCPC[1,2]

Abstract

Emergency trauma radiology, although a relatively new subspecialty of radiology, plays a critical role in both the diagnosis/triage of acutely ill patients, but even more important in providing leadership and taking the lead in the preparedness of imaging departments in dealing with novel highly infectious communicable diseases and mass casualties. This has become even more apparent in dealing with COVID-19, the disease caused by the novel coronavirus SARS-CoV-2, first emerged in late 2019. We review the symptoms, epidemiology, and testing for this disease. We discuss characteristic imaging findings of COVID-19 in relation to other modern coronavirus diseases including SARS and MERS. We discuss roles that community radiology clinics, outpatient radiology departments, and emergency radiology departments can play in the diagnosis of this disease. We review practical methods to reduce spread of infections within radiology departments.

Résumé

La radiologie traumatologique d'urgence, bien que relativement nouvelle parmi les sous-spécialités de la radiologie, joue un rôle essentiel dans le diagnostic et le tri des patients présentant un trouble aigu. Mais son rôle est encore plus important quand il s'agit d'offrir un leadership et de prendre des initiatives dans la préparation des services d'imagerie face à la gestion de maladies contagieuses hautement infectieuses et de pertes humaines massives. Cela est devenu encore plus évident face à la COVID-19, la maladie provoquée par le nouveau coronavirus SARS-CoV-2, apparue pour la première fois à la fin de 2019. Nous passons en revue les symptômes, l'épidémiologie et les tests de cette maladie, puis abordons les constatations caractéristiques de la COVID-19 dans l'imagerie par rapport aux autres maladies récentes à coronavirus, dont le SRAS et le SRME (ou MERS). Nous discutons du rôle que peuvent jouer les cliniques de radiologie communautaires, les services de radiologie pour patients ambulatoires et les services de radiologie d'urgence dans le diagnostic de cette maladie. Nous passons en revue les moyens pratiques utilisables pour réduire la propagation des infections dans les services de radiologie.

Keywords

COVID-19, emergency and trauma radiology, MERS, SARS, CT, preparedness

Introduction

Infections associated with the SARS-CoV-2 virus (COVID-19) were first recognized in the Hubei province, People's Republic of China, in late 2019. All of the first reported cases were linked to the Huanan Seafood Wholesale Market in Wuhan, China.[1] The disease was later declared a global health

[1] Department of Emergency and Trauma Radiology, Vancouver General Hospital, Vancouver, British Columbia, Canada
[2] Department of Radiology, Vancouver General Hospital, University of British Columbia, Vancouver, British Columbia, Canada
[3] Department of Thoracic Radiology, Vancouver General Hospital, University of British Columbia, Vancouver, British Columbia, Canada
[4] King Saud bin Abdulaziz University for Health Sciences, King Abdullah International Medical Research Center, Ministry of the National Guard, Health Affairs, Medical Imaging Department, Abdominal Imaging Section, Riyadh, Saudi Arabia
[5] Department of Radiology, Pardis Noor Medical Imaging Centers, Tehran, Iran
[6] Surrey Memorial Hospital, Department of Radiology, University of British Columbia, Vancouver, British Columbia, Canada
[7] Imam Khomeini Hospital Complex, Tehran, Iran

Corresponding Author:
Muhammad Umer Nasir, MBBS, FCPS, Department of Emergency and Trauma Radiology, Vancouver General Hospital, 899 W12th Avenue, Vancouver, British Columbia, Canada V5Z 1M9.
Email: dromernasir@gmail.com

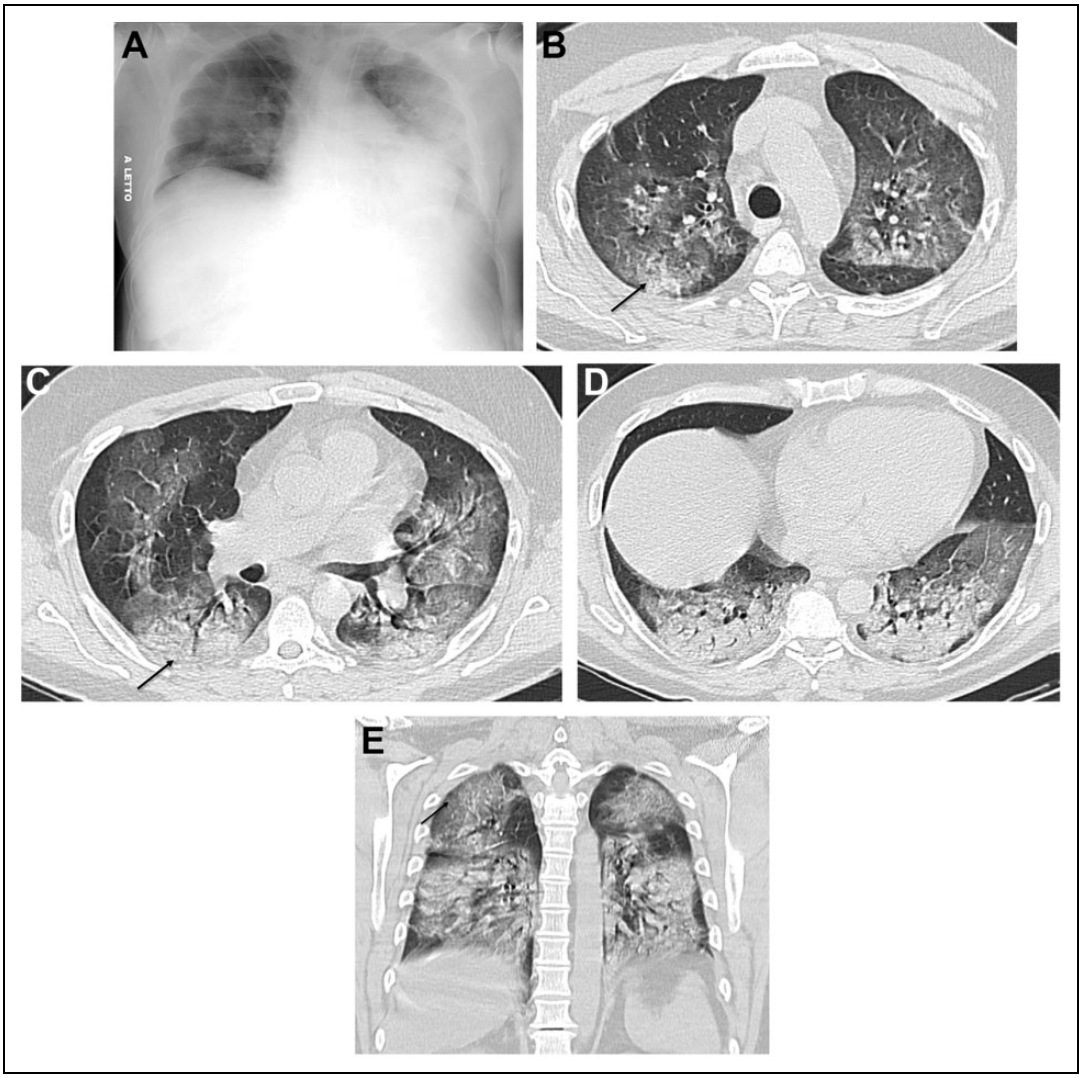

Figure 1. Polymerase chain reaction–positive COVID-19. A 53-year-old Italian male presenting with severe shortness of breath. No reported travel in the recent past weeks in the areas at risk of COVID-19. Images acquired the same day of the shortness of breath onset. No known history of comorbidities (case courtesy of Dr Ugo D'Ambrosio, Santa Maria Goretti Hospital, Latina, Italy). A, Portable chest radiograph. Low lung volumes. Left greater than right pulmonary consolidation (case courtesy of Dr Ugo D'Ambrosio, Santa Maria Goretti Hospital, Latina, Italy). B, Axial chest computed tomography (CT). Confluent upper lobe ground-glass opacities. Small areas of consolidation are shown in the posterior upper lobes (arrow) (case courtesy of Dr Ugo D'Ambrosio, Santa Maria Goretti Hospital, Latina, Italy). C, Axial chest CT. Bilateral upper lobe diffuse ground-glass opacities and lower lobe consolidation (arrow). Respiratory artifact due to difficulty breath holding as a result of severe dyspnea (case courtesy of Dr Ugo D'Ambrosio, Santa Maria Goretti Hospital, Latina, Italy). D, Axial chest CT. Bibasal ground-glass opacities and consolidations (case courtesy of Dr Ugo D'Ambrosio, Santa Maria Goretti Hospital, Latina, Italy). E, Coronal chest CT. Better shown on the coronal reformation is upper lobe predominant ground-glass (arrow) and lower lobe predominant consolidation (case courtesy of Dr Ugo D'Ambrosio, Santa Maria Goretti Hospital, Latina, Italy).

emergency by the World Health Organization. COVID-19 shares etiologic and clinical similarities with other contemporary coronavirus syndromes, including MERS identified in 2012 and SARS in 2003.

As of March 9, 2020, 57 COVID-19 cases have been confirmed in Canada, representing a fraction of the total 110 000 confirmed cases globally with over 3800 fatalities. Currently, most cases are in China followed by Italy, South Korea, and Iran.[2] The mortality rate of COVID-19 is estimated at 3.4%, compared to 10% and 34% of SARS and MERS, respectively.[3] Most Canadian cases to date have been spread through local transmission. The infection is spread primarily through contact and droplets (some reports suggest orofecal transmission as well), with an average incubation period of 5 days before symptoms develop.[4]

Symptoms of infection are variable and nonspecific and include dry cough, fever, fatigue, myalgias, and dyspnea. Less commonly encountered symptoms include a productive cough, pleuritic chest pain, hemoptysis, and diarrhea.[4,5] Older male patients with comorbidities are more prone to be infected with an unfavorable outcome.[6]

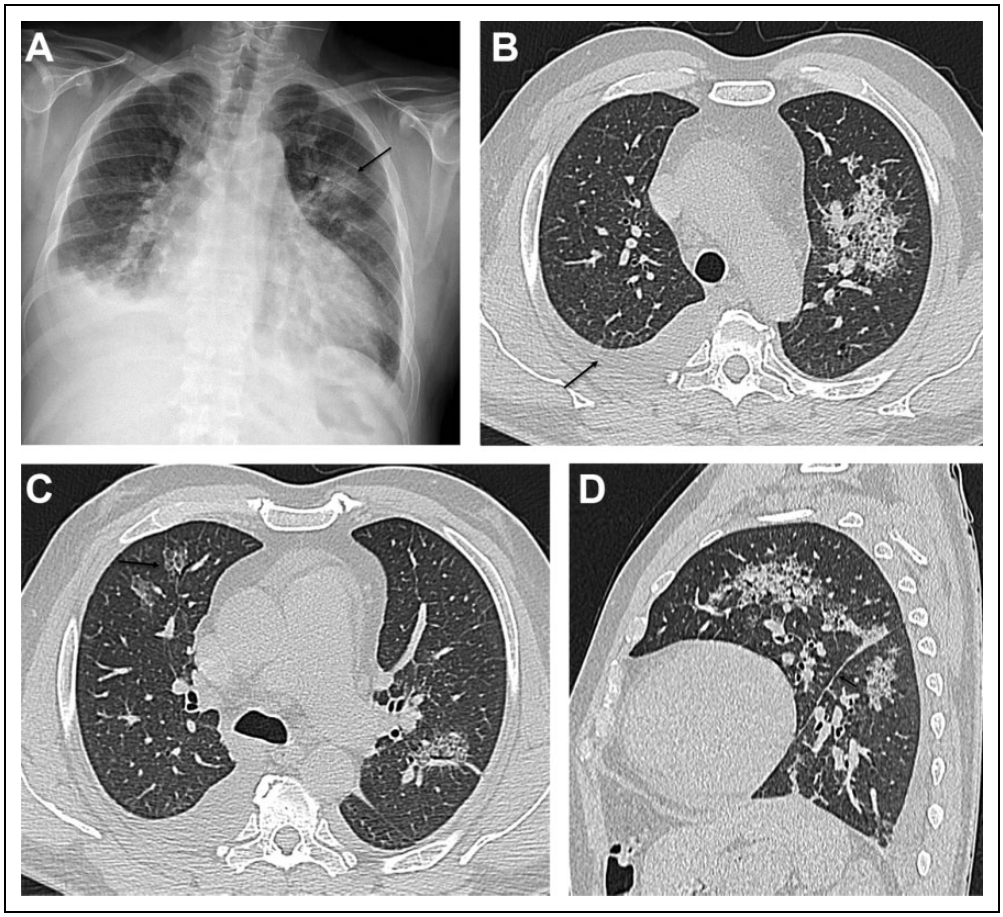

Figure 2. Polymerase chain reaction–positive COVID-19 case. A 71-year-old male patient with travel to the north of Italy 12 days prior. Images acquired after 2 days from the onset of fever, cough, and shortness of breath. Comorbidities include treated hepatocellular carcinoma, cirrhosis, and hypertrophic cardiomyopathy (case courtesy of Dr Ugo D'Ambrosio, Santa Maria Goretti Hospital, Latina, Italy). A, Initial chest radiograph. Patchy ground-glass opacity in the left upper lung (arrow), and right basal atelectasis/consolidation and associated small right pleural effusion are shown (case courtesy of Dr Ugo D'Ambrosio, Santa Maria Goretti Hospital, Latina, Italy). B, Axial chest computed tomography (CT). Ground-glass opacity and septal thickening shown in the left upper lobe. A small right pleural effusion is also shown (arrow) (case courtesy of Dr Ugo D'Ambrosio, Santa Maria Goretti Hospital, Latina, Italy). C, Axial CT of the chest. Bilateral patchy ground-glass opacities and associated interlobular septal thickening (arrow), and right greater than left small pleural effusions (case courtesy of Dr Ugo D'Ambrosio, Santa Maria Goretti Hospital, Latina, Italy). D, Sagittal chest CT multiplanar reformation. Peribronchovascular ground-glass opacities and associated septal thickening (arrow) in the left upper and lower lobes.

Patients have the highest viral load in sputum during the recovery phase, warranting prolonged quarantine, usually 14 days.[7] Patients with compromised immune systems or comorbidities can develop severe pneumonia, acute respiratory distress syndrome, and multiple organ failure leading to death, whereas in immunocompetent patients, it has a very similar disease course as that of influenza.[5]

Diagnosis

Patients presenting to the emergency department with lower respiratory tract symptoms should be first clinically screened for COVID-19. Current BC Centre for Disease Control and Public Health Agency of Canada guidelines recommend testing for patients with compatible symptoms and who traveled to affected areas within 14 days of symptom onset or who were in close contact with a confirmed or probable case of COVID-19 or no clear alternative diagnosis.[8]

Polymerase chain reaction (PCR) is the current gold standard for confirming infection, performed using nasal or pharyngeal swab specimens or induced sputum. Other pertinent hematological and biochemical testing of proven COVID-19 cases shows elevated C-reactive protein, followed by lymphopenia with white blood cell count elevation.[4]

Role of Imaging

Suspected lower respiratory tract infection often warrants imaging, either in the form of chest radiography, often first-line despite its lower sensitivity, or chest computed tomography (CT). Imaging of suspected or confirmed COVID-19 cases in Canada will likely increase as the number of cases increases

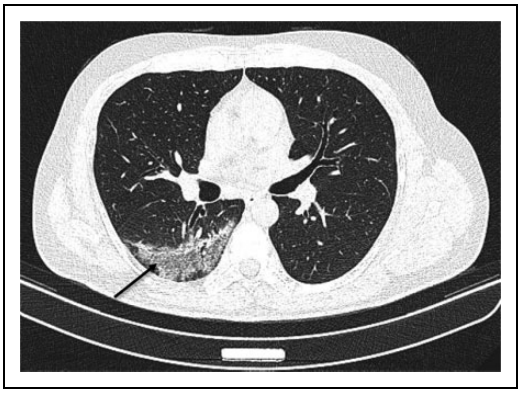

Figure 3. A 56-year-old female patient presenting after 1 week of dry cough, fever, and pleuritic chest pain. Axial computed tomography (CT) of the chest. Right lower lobe ground-glass opacity with partial surrounding dense consolidation (arrow); possible organizing pneumonia pattern.

nationally. Routine unenhanced chest CT is a useful tool in early diagnosis of COVID-19 infection, especially in settings of limited availability of reverse transcriptase polymerase chain reaction (RT-PCR). Based on a prospective analysis of 1014 patients, the sensitivity of CT is estimated to be 97% in detecting COVID-19 infection. The sensitivity of the RT-PCR has been reported to be in the range of 60 to 70%.[9]

Although PCR is the gold standard for confirming infection, chest CT has been shown to be more sensitive for the detection of COVID-19. Polymerase chain reaction–negative cases with positive CT findings and high clinical suspicion may benefit from repeat PCR testing.[10] Despite the higher sensitivity of CT, up to 15% to 20% of patients with confirmed infection will have no parenchymal findings on chest CT within the earliest phase of infection,[11,12] Bai et al has reported high specificity (93%-100%) of CT in differentiating COVID-19 from other viral pneumonia; however, the sensitivity is in the range of 70 to 93%.[13] Chest radiographs can be used in monitoring disease progression, coinfection, or stability especially in critically ill patients.

Pulmonary Manifestations of COVID-19

COVID-19, SARS, and MERS have overlapping imaging features making it difficult to differentiate these pulmonary syndromes on the basis of imaging. Eighty to eighty-five percent of the patients with these pulmonary syndromes present with abnormal imaging features.[11]

Early chest CT findings of *COVID-19* include peripheral patchy or ovoid bilateral ground-glass opacities, with lower lobe predominance in 50% to 75% of patients (Figure 1); this pattern is frequently followed by mixed density pulmonary opacities and consolidation and crazy-paving peaking at days 9 to 13, with consolidation becoming the predominant feature (Figure 2).[4] Less commonly encountered imaging findings include the "reversed halo sign" (Figure 3), lymphadenopathy, pleural effusion, centrilobular nodules, tree-in-bud nodules, and cystic change.[14]

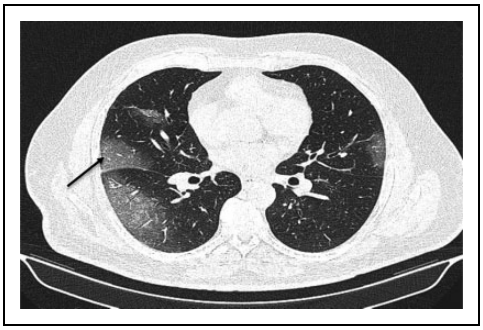

Figure 4. A 40-year-old male with COVID-19 who presented with 3-day history of fatigue, myalgia, and dry cough. Peripheral patchy ground-glass opacities (arrow).

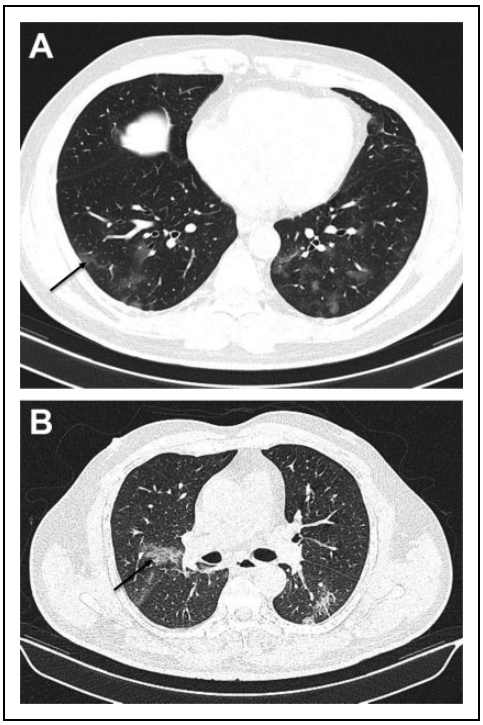

Figure 5. Polymerase chain reaction–proven COVID-19 case. A 53-year-old male patient with a 10-day history of malaise. A, Axial computed tomography (CT) of the chest. Patchy lower lobe ground-glass opacities (arrow). B, Axial CT of the chest. Relatively dense ground-glass opacities in the right upper lobe and superior segments of lower lobes (arrow).

Normal CT chest or a predominantly ground-glass pattern is seen during the early (0-2 days) phase of the disease (Figure 4). Pulmonary parenchymal consolidation is frequently seen in the intermediate to late (3-12 days) phase of disease, from onset of symptoms to imaging manifestations, especially in patients with compromised immunity and comorbidities (Figure 5).[14]

Recovery phase of the disease is marked by the improvement in these radiographic features. However, pertinent negative findings such as absence of lymphadenopathy and pleural effusions early in the disease on CT in COVID19 and

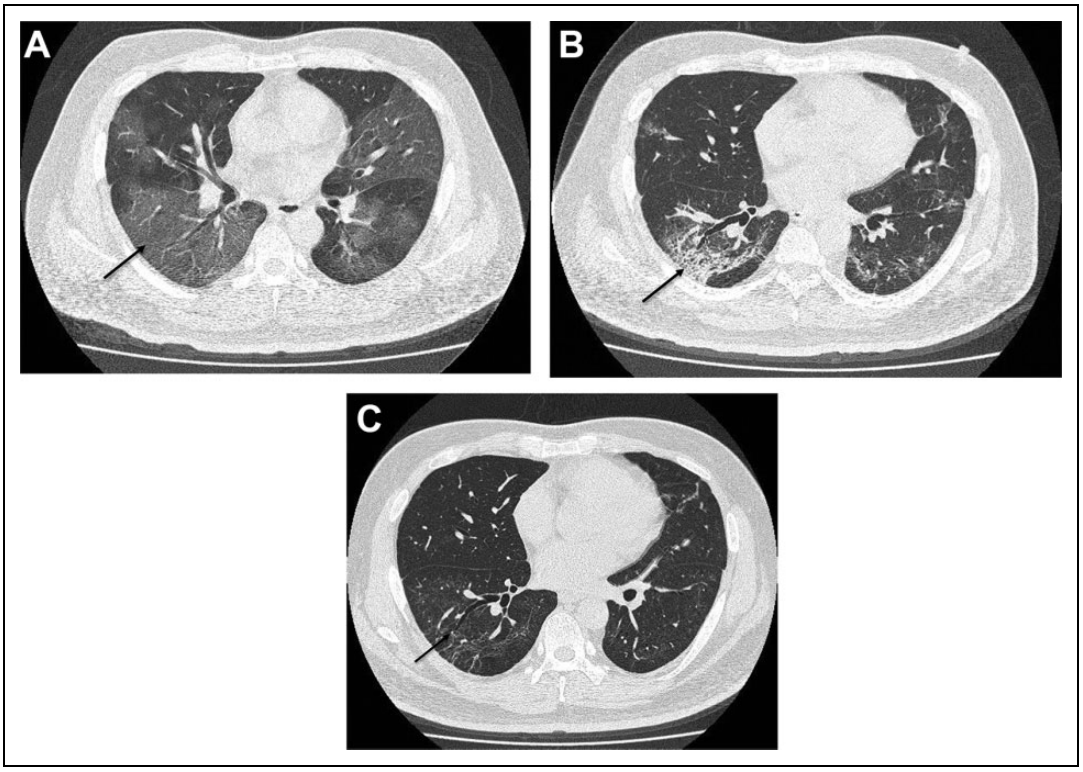

Figure 6. Polymerase chain reaction–positive SARS case. A, Axial computed tomography (CT) of the chest. Bilateral confluent ground-glass opacities (arrow). B, Axial CT of the chest. Improvement of the ground-glass opacities after 4 weeks, but with evolution in the same distribution to septal thickening with suggestion of early traction bronchiectasis suggesting evolving fibrosis (arrow). C, Axial CT of the chest 3 months later. Mild bronchiectasis (arrow) with further resolution of previously shown ground-glass opacities. Some residual interstitial changes and small patchy areas of ground-glass opacification.

SARS can help narrow the differential diagnosis. If present, then the possibility of a bacterial superinfection or an alternative diagnosis should be entertained. Temporal evolution of imaging finding can be another differentiating point. Bacterial pneumonia predominantly has a lobar pattern at presentation with bronchial and alveolar exudates, in contrast to the early phase of COVID-19 infection. Consolidations with bronchial wall thickening in the pediatric population may suggest mycoplasma pneumonia.[15]

Elderly patients with comorbidities are known to have a fulminant disease course of COVID-19, making it a potential mimic of pulmonary edema. Central perihilar ground-glass opacities with classic "bat-wing" distribution may suggest pulmonary edema, contrary to peripheral patchy ground-glass opacities of COVID-19. Furthermore, pulmonary edema in patients with heart failure has pathognomonic signs of bilateral interlobular septal thickening, bronchial cuffing, and cephalad vascular redistribution.[16]

Contrary to MERS and COVID, SARS frequently shows unilateral involvement.[17] Early manifestations on chest radiography in SARS include focal or multifocal, ill-defined airspace opacification involving the middle and lower lobes. These imaging features may progress to form multifocal confluent consolidations in both lungs, if left untreated or in immunocompromised patients over the course of 1 to 2 weeks.[18] Chest CT imagining initially shows ground-glass opacity and consolidation in involved segments. The reticular pattern starts to appear after the second week and peaks around the fourth week, and this can be seen associated with traction bronchiectasis as well (Figure 6).[19]

In contrast to SARS and COVID-19, the coronavirus causing *MERS* was first identified in the sputum of a Saudi Arabian patient and is mainly transmitted through nonhuman, zoonotic sources such as bats and camels.[20] Majority of patients with MERS also present with ground-glass opacities during the early phase of disease. However, imaging features such as fibrosis (33%), pneumothorax, isolated consolidation (20%), or pleural effusion (33%) are commonly encountered in MERS (Figures 7 and 8).[21]

Preparedness

The radiology department has an obligation to ensure patient-centered care while maintaining staff safety. With hospital radiology departments and community radiography clinics having the potential to be hubs for infection spread, plans to prevent nosocomial infection spread should be developed.

The health authority of the authors (Vancouver Coastal Health) has developed a pandemic preparedness checklist

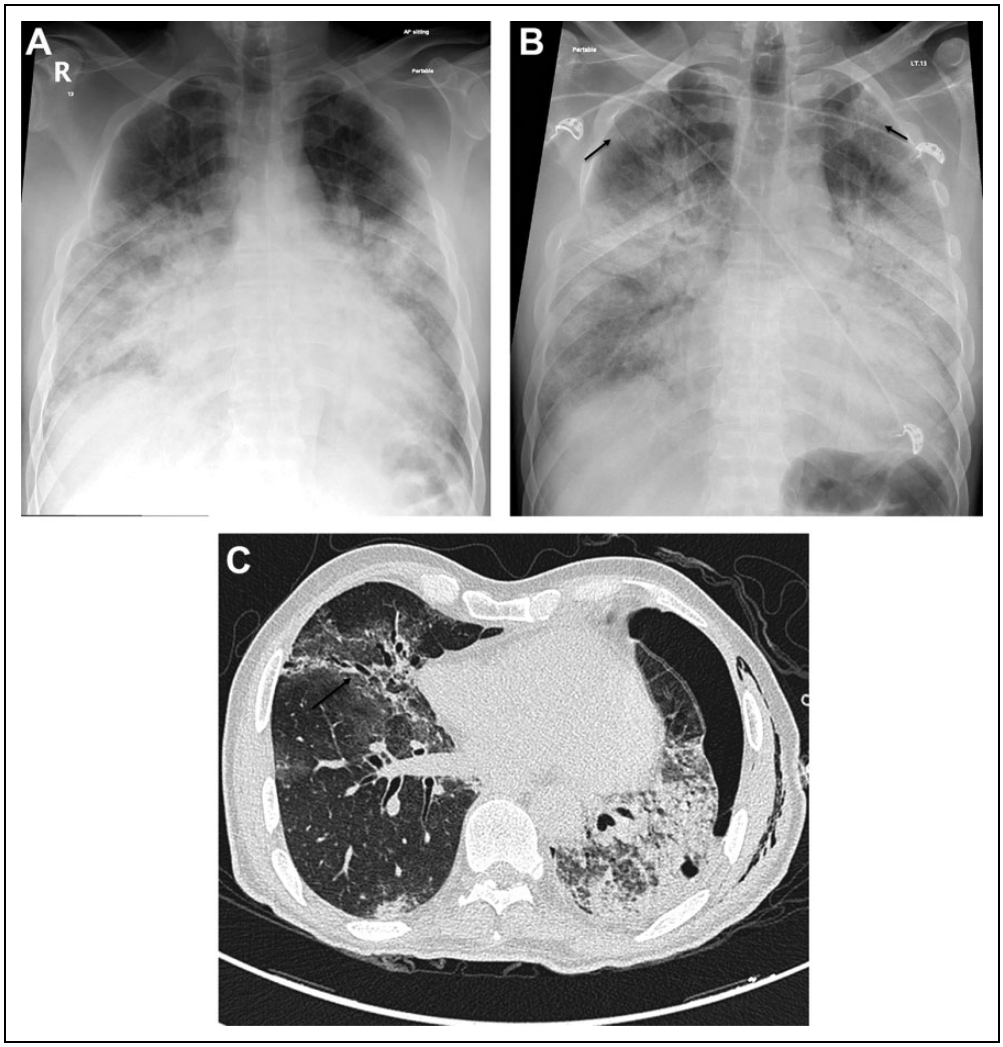

Figure 7. Polymerase chain reaction–positive MERS case. A, Initial chest radiograph at day 0 of admission. Bilateral perihilar and lower lung consolidation. No pneumothorax or pleural effusion at initial presentation. B, Follow-up chest radiograph at day 5 of admission. Worsening bilateral consolidations (arrow) with development of left-sided pleural effusion. C, Follow-up axial computed tomography (CT) of the chest at 1 month. New left-sided pneumothorax. Persistent left greater than right lower lobe consolidation. Note the fibrosis and traction bronchiectasis in the right middle lobe (arrow).

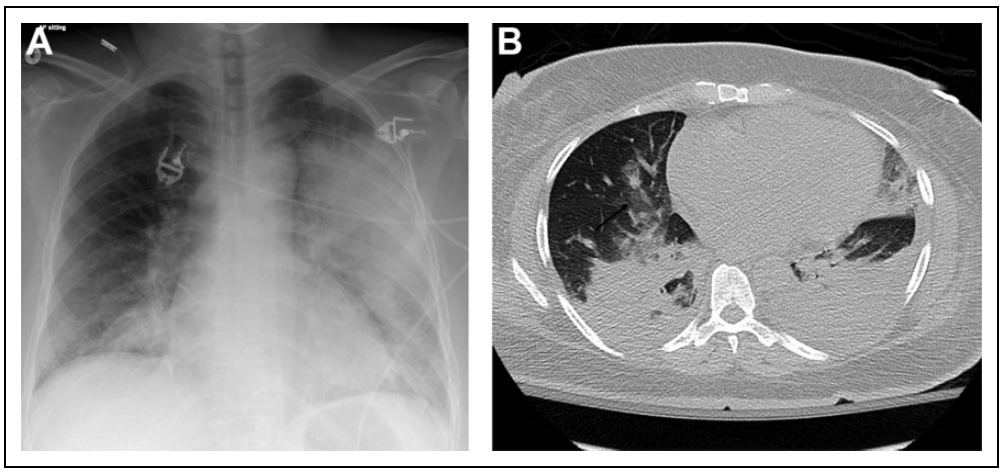

Figure 8. MERS-CoV case with poor prognosis. A, Chest radiograph. Initial chest radiograph at day 0 of admission. Left greater than right perihilar and lower lung consolidations. B, Axial CT image (lung windows). Bilateral lobe consolidation and middle lobe ground-glass opacity (arrow).

(originally devised for potential influenza outbreaks) for medical clinics that can be applied to radiology clinics and outpatient hospital radiology departments.[22]

Preventing patient-to-staff transmission: Consider the use of barrier protections (eg, Plexiglas) at reception and ensure appropriate distance between patients and reception staff. Personal protective equipment (PPE) for staff involved in direct patient care of potential COVID-19 cases should include gloves, surgical masks (airborne precautions including N95 respirators are not indicated), and isolation gowns.

Preventing patient-to-patient transmission: Supply patients with hand sanitizer and surgical masks at entrances. Remove items shared by patients from waiting rooms (eg, magazines); other shared items (eg, pens, clipboards) should be replaced (eg, use disposable pencils instead). Consider separating patients with respiratory symptoms from those without into separate waiting areas, and/or batch imaging patients with respiratory symptoms at a specific time of day.

Preventing staff/facility-to-patient transmission: Supply staff with hand sanitizer. Ensure that appropriate disinfection methods are used on clinic equipment including radiography equipment between uses. Ensure that staff showing respiratory symptoms do not attend work.

Effective communication between the referring services and emergency radiology department is crucial in limiting the spread of this highly contagious infection. The radiology department should be notified before transferring the suspected case so that appropriate infection control measures are in place beforehand. Radiographers should be trained adequately on the use of PPE and infection control procedures as they will be in the first line of contact. Portable acquisition of radiographs should be encouraged in a negative pressure room whenever possible to limit the transportation of the patient. However, if patients have to be transported to the radiology department, they should come with a clear respiratory precaution sign and with a surgical face mask on. Patients should be guided about the respiratory etiquette, and use of pamphlets with clear instructions can be helpful in such scenarios. The room should ideally not be used for 15 minutes after imaging the suspected patient. Radiographers must utilize full PPE for cleaning and disinfection after the patient is discharged from the room according to the manufacturer's instructions.

In case of a large number of suspected or positive patients, a dedicated imaging equipment and room should be used, or the imaging should be performed at an allocated time preferably at the end of the CT list. Development of artificial intelligence in detecting the suspicious pattern of disease involvement may be beneficial in mass screening.

Conclusion

Infections associated with the SARS-CoV-2 virus (COVID-19) have the potential to cause high morbidity and mortality in Canada. While the clinical symptoms and radiographic findings of this infection are not specific, radiology will play a crucial role in raising suspicion for potential COVID-19 cases, helping guide screening and identifying complications. By implementing the respiratory etiquettes, and institutional infection control measures, as radiology departments, we can do our part to minimize spread of this infection and ensure staff and patient safety.

Declaration of Conflicting Interests

The author(s) declared the following potential conflicts of interest with respect to the research, authorship, and/or publication of this article: UBC has a master research agreement with Siemens Healthineers.

Funding

The author(s) received no financial support for the research, authorship, and/or publication of this article.

ORCID iD

Shahram Akhlaghpoor, MD https://orcid.org/0000-0001-9993-3801

References

1. Li Q, Guan X, Wu P, et al. Early transmission dynamics in Wuhan, China, of novel coronavirus-infected pneumonia. *N Engl J Med* 2020;382:1199-1207. doi:10.1056/NEJMoa2001316.
2. World Health Organization. Coronavirus disease 2019 (COVID-19). Situation Report—41. 2020. https://www.who.int/docs/default-source/coronaviruse/situation-reports/20200301-sitrep-41-covid-19.pdf?sfvrsn=6768306d_2. Accessed March 9, 2020.
3. Ducharme J, Wolfson E. The WHO estimated COVID-19 mortality at 3.4%. That doesn't tell the whole story. *Time*. 2020. https://time.com/5798168/coronavirus-mortality-rate/. Accessed March 9, 2020.
4. Yang W, Qiqi C, Le Q, et al. Clinical characteristics and imaging manifestations of the 2019 novel coronavirus disease (COVID-19): a multi-center study in Wenzhou city, Zhejiang, China. *J Infect*. 2020;80(4):388-393. doi:10.1016/j.jinf.2020.02.016.
5. Huang C, Wang Y, Li X, et al. Clinical features of patients infected with 2019 novel coronavirus in Wuhan, China. *Lancet*. 2020;395(10223):497-506. doi:10.1016/s0140-6736(20)30183-5.
6. Chen N, Zhou M, Dong X, et al. Epidemiological and clinical characteristics of 99 cases of 2019 novel coronavirus pneumonia in Wuhan, China: a descriptive study. *Lancet*. 2020;395(10223):507-513. doi:10.1016/s0140-6736(20)30211-7.
7. Rothe C, Schunk M, Sothmann P, et al. Transmission of 2019-nCoV Infection from an asymptomatic contact in Germany. *N Engl J Med*. 2020;382(10):970-971. doi:10.1056/NEJMc2001468.
8. PHSA Laboratories, BCCDC Public Health Laboratory. Guidance on sample collection for novel coronavirus (2019-nCoV) testing as of Jan 30, 2020. http://www.bccdc.ca/resource-gallery/Documents/Statistics%20and%20Research/Statistics%20and%20Reports/Epid/Influenza%20and%20Respiratory/ERV/BCCDC_PHL_Updated_nCoV_Lab_Guidance.pdf. Accessed March 9, 2020.

9. Ai T, Yang Z, Hou H, et al. Correlation of Chest CT and RT-PCR testing in coronavirus disease 2019 (COVID-19) in China: a report of 1014 cases. *Radiology*. 2020:200642. doi:10.1148/radiol.2020200642.
10. Xie X, Zhong Z, Zhao W, Zheng C, Wang F, Liu J. Chest CT for typical 2019-nCoV pneumonia: relationship to negative RT-PCR testing. *Radiology*. 2020;200343. doi:10.1148/radiol.2020200343.
11. Hosseiny M, Kooraki S, Gholamrezanezhad A, Reddy S, Myers L. Radiology perspective of coronavirus disease 2019 (COVID-19): lessons from severe acute respiratory syndrome and middle east respiratory syndrome. *AJR Am J Roentgenol*. 2020:1-5. doi:10.2214/AJR.20.22969.
12. Bernheim A, Xueyan M, Mingqian H, et al. Chest CT findings in coronavirus disease-19 (COVID-19): relationship to duration of infection. *Radiology*. 2020:200463. doi:10.1148/radiol.2020200463.
13. Bai HX, Hsieh B, Xiong Z, et al. Performance of radiologists in differentiating COVID-19 from viral pneumonia on chest CT. *Radiology*. 2020:200823. doi:10.1148/radiol.2020200823.
14. Ng MY, Lee EY, Yang J, et al. Imaging profile of the COVID-19 infection: radiologic findings and literature review. *Radiol Cardiothorac Imag*. 2020;2(1):e200034. doi:10.1148/ryct.2020200034.
15. Dai WC, Zhang HW, Yu J, et al. CT imaging and differential diagnosis of COVID-19. *Can Assoc Radiol J*. doi:10.1177/0846537120913033.
16. Lu H, Stratton CW, Tang Y. Outbreak of pneumonia of unknown etiology in Wuhan, China: the mystery and the miracle. *J Med Virol*. 2020;92(4):401-402. doi:10.1002/jmv.25678.
17. Paul NS, Roberts H, Butany J, et al. Radiologic pattern of disease in patients with severe acute respiratory syndrome: the Toronto experience. *Radiographics*. 2004;24(2):553-563. doi:10.1148/rg.242035193.
18. Wong KT, Antonio GE, Hui DS, et al. Severe acute respiratory syndrome: radiographic appearances and pattern of progression in 138 patients. *Radiology*. 2003;228(2):401-406. doi:10.1148/radiol.2282030593.
19. Ooi GC, Khong PL, Müller NL, et al. Severe acute respiratory syndrome: temporal lung changes at thin-section CT in 30 patients. *Radiology*. 2004;230(3):836-844. doi:10.1148/radiol.2303030853.
20. Mobaraki K, Ahmadzadeh J. Current epidemiological status of Middle East respiratory syndrome coronavirus in the world from 1.1.2017 to 17.1.2018: a cross-sectional study. *BMC Infect Dis*. 2019;19(1):351. doi:10.1186/s12879-019-3987-2.
21. Das KM, Lee EY, Langer RD, Larsson SG. Middle East respiratory syndrome coronavirus: what does a radiologist need to know? *Ame J Roentgenol*. 2016;206(6):1193-1201. doi:10.2214/ajr.15.15363.
22. Daly P. *Vancouver Coastal Health, Physicians' Office Checklist: April, 2007*. https://sneezesdiseases.com/assets/uploads/15829215479rDhSXOy8OpwzyNyUJhq81XNCzuZ.pdf. Accessed March 9, 2020.