
ORIGINAL ARTICLE

A Prospective Study Comparing Platelet-Rich Plasma and Local Anesthetic (LA)/Corticosteroid in Intra-Articular Injection for the Treatment of Lumbar Facet Joint Syndrome

Jiuping Wu, MSc*; Jingjing Zhou, MSc[†]; Chibing Liu, MSc*; Jun Zhang, MSc*; Wei Xiong, MSc*; Yang Lv, MSc*; Rui Liu, MSc*; Ruiqiang Wang, MSc*; Zhenwu Du, MD, PhD*; Guizhen Zhang, MD, PhD*; Qinyi Liu, MD, PhD*

*Department of Orthopaedics, The Second Hospital, Jilin University, Changchun, Jilin;

[†]Department of Imaging and Nuclear Medicine, The Second Hospital, Jilin University, Changchun, Jilin, China

■ Abstract

Objectives: To compare the effectiveness and safety between autologous platelet-rich plasma (PRP) and Local Anesthetic (LA)/corticosteroid in intra-articular injection for the treatment of lumbar facet joint syndrome.

Methods: Forty-six eligible patients with lumbar facet joint syndrome were randomized into group A (intra-articular injection with PRP) and group B (intra-articular injection with LA/corticosteroid). The following contents were evaluated: pain visual analog scale (VAS) at rest and during flexion, and the Roland-Morris Disability Questionnaire (RMQ), Oswestry Disability Index (ODI), and modified MacNab criteria for pain relief and applications of post-treatment drugs. All outcome assessments were performed immediately after and at 1 week, 1, 2, 3, and 6 months after treatment.

Results: No significant difference between groups was observed at baseline. Compared with pretreatment, both group A and group B demonstrated statistical improvements in the pain VAS score at rest or during flexion, the RMQ, and the ODI ($P < 0.01$). And there were significant differences between the 2 groups on the above-mentioned items ($P < 0.05$). For group B, subjective satisfaction based on the modified MacNab criteria and objective success rate were highest (80% and 85%) after 1 month, but only 50% and 20% after 6 months. However, for group A, they increased over time. In addition, there were no treatment-related complications in either group during follow-up.

Conclusions: Both autologous PRP and LA/corticosteroid for intra-articular injection are effective, easy, and safe enough in the treatment of lumbar facet joint syndrome. However, autologous PRP is a superior treatment option for longer duration efficacy. ■

Address correspondence and reprint requests to: Qinyi Liu, MD, PhD, Department of Orthopaedics, The Second Hospital, Jilin University, No. 218 Ziqiang Street, Nanguan District, Changchun, Jilin 130041, China. E-mail: 1226527208@qq.com.

J.W. and J.Z. contributed equally to this work.

Submitted: June 28, 2016; Revised September 21, 2016;

Revision accepted: October 26, 2016

DOI: 10.1111/papr.12544

Key Words: low back pain, lumbar facet joint syndrome, intra-articular injection, platelet-rich plasma, LA/corticosteroid

INTRODUCTION

Lumbar facet joint syndrome has been defined as a kind of low back pain with or without referred pain to the buttock, groin, or proximal thigh deriving from lumbar

facet joints. In 1911, Goldthwaite¹ claimed firstly that disorders of facet joints were likely to be one of the important causes of low back pain, and in 1927, Putti² demonstrated by dissecting 75 cadavers that local inflammations and degenerative changes of lumbar facet joints could cause sciatica from irritation of nerve roots. In 1933, the term "lumbar facet joint syndrome" was coined by Ghormley, and he defined it as low back pain with or without referred pain resulting from local lesions of lumbar facet joints.³ Since then, the comprehension of lumbar facet joint syndrome has thrown fresh light on the source of low back pain. Current studies have illustrated that among cases of low back pain, 15% to 52% are caused by lumbar facet joint syndrome.^{4,5}

To date, although the exact mechanisms of lumbar facet joint syndrome are still unknown, numerous investigators believe that osteoarthritis is most responsible for lumbar facet joint syndrome, similar to that seen in other peripheral synovial joints.⁶⁻⁸ Some studies have demonstrated a significant increase in the levels of multiple pro-inflammatory cytokines such as growth-related oncogene- α (GRO- α), soluble intercellular adhesion molecule-1 (sICAM-1), interferon- γ (IFN- γ), tumor necrosis factor- α (TNF- α), interleukin (IL)-1 β , IL-6, and IL-17, as well as anti-inflammatory cytokines IL-10 and IL-13, in the facet joint tissues with degenerative disorders.^{9,10} Moreover, in the late stage of lumbar facet joint syndrome, structural changes also appeared, such as osteoarthritis with narrowing, joint space narrowing, osteophytosis, joint hypertrophy, subchondral sclerosis, and bony deformity.¹¹

Currently, conservative treatment, interventional treatment, and surgical treatment are the 3 main therapeutic methods for lumbar facet joint syndrome, among which interventional treatment is currently the most commonly used procedure.¹² Interventional intra-articular injection for the treatment of lumbar facet joint syndrome has been applied with increasing frequency as the landmark study by Mooney and Robertson provided important evidence for the impressive efficacy of intra-articular block with steroids and local anesthetics for lumbar facet joint pain.¹³ Although multiple injected drugs (such as steroids, local anesthetics, normal saline, hyaluronic acid, and phenols) have been shown to be effective for the pain relief of lumbar facet joint syndrome in many studies, the actual results using different drugs for intra-articular injection are controversial.^{14,15} Steroid is one of the most commonly used injected drugs; however, previous uncontrolled studies have indicated that the long-term relief of low back pain

after intra-articular steroid injection is only 18% to 63%.¹⁴ Therefore, it seems meaningful to apply a new injectable drug and to prove its effectiveness and safety for the treatment of lumbar facet joint syndrome.

Platelet-rich plasma (PRP) is an autologous blood derivative that contains high concentrations of activated growth factors and cytokines, including platelet-derived growth factor (PDGF), transforming growth factor- β (TGF- β), fibroblast growth factor (FGF), insulin-like growth factor 1 (IGF-1), connective tissue growth factor (CTGF), and epidermal growth factor (EGF), as well as bioactive proteins that influence the healing of tendon, ligament, muscle, and bone.¹⁶⁻¹⁸ These elements act as humoral mediators to induce an anti-inflammatory effect and the natural healing cascade by promoting cell proliferation, migration and differentiation, protein transcription, extracellular matrix regeneration, angiogenesis, and collagen synthesis.¹⁹⁻²¹ Regarding these excellent biological properties, PRP seems to be one of the most appropriate novel options for the treatment of lumbar facet joint syndrome.

Hence, we used intra-articular injection with autologous PRP to treat lumbar facet joint syndrome. In addition, this study was conducted with the aim to explore the effectiveness and safety of intra-articular autologous PRP injection by comparing it with intra-articular conventional LA/corticosteroid injection for the treatment of lumbar facet joint syndrome.

METHODS

Participants and Study Design

This prospective, randomized, controlled study was conducted for comparing the effectiveness and safety of autologous PRP and LA/corticosteroid in intra-articular injection in a university hospital outpatient department of orthopedics. Ethical clearance was approved by the local ethical committees before commencement of this study (Reg. No. 54).

Ninety-three patients who were suspected to have potential lumbar facet joint syndrome were assessed for the eligibility to participate in our prospective, randomized controlled study. The inclusion and exclusion criteria for diagnosing lumbar facet joint syndrome are shown in Table 1. Sixteen patients did not meet the inclusion criteria, and 7 patients refused to enter the study. The remaining 70 patients with lumbar facet joint syndrome were first managed with conservative treatment, such as physical therapy, massage, acupuncture,

Table 1. Inclusion and Exclusion Criteria for Eligible Patients with Lumbar Facet Joint Syndrome

Inclusion Criteria	Exclusion Criteria
Continuous or intermittent local low back pain with or without referred pain to the buttock, groin, or proximal thigh	Pain score of < 4 at rest on visual analog scale
Local paraspinal tenderness	Duration of continuous or intermittent low back pain of < 3 months;
Increase of pain on flexion, rotation, or lateral bending and with local excessive stress	Radicular neurologic complaints or with evident disk herniations
Fracture-like feelings when bending down	Prior surgery on the spine
Experience of hard physical labor or sedentariness	Prior interventional treatment on lumbar facet joints
Absence of neurological deficit	Intolerance of local anesthesia, corticosteroid, contrast medium, or blood derivatives
Findings of lumbar facet joint degenerative changes on lumbar spine radiograph (osteoarthritis with narrowing, joint space narrowing, osteophytosis, joint hypertrophy, subchondral sclerosis, and bony deformity)	Local or systemic infection or spinal infection
	Uncorrectable coagulopathy
	Pregnancy
	Lack of strong enough other physical conditions for interventional treatment

and oral drugs. One month later, the patients who did not obtain obvious pain relief ($\leq 50\%$) were recommended to receive a diagnostic intra-articular block with 0.5% lidocaine. The patients who failed to receive intra-articular injection or who had negative diagnostic blocks were excluded from the study. After a series of rigorous screenings, 47 patients were not enrolled in this study. The remaining 46 patients were assigned randomly to 2 groups. Group A patients ($n = 23$) were treated with intra-articular injection with autologous PRP under fluoroscopy; group B patients ($n = 23$) were treated with intra-articular injection with a mixture of 0.5% lidocaine and 5 mg/mL betamethasone (4:1, vol/vol) under fluoroscopy (Figure 1).

After the intra-articular injections were completed successfully, a 6-month follow-up was arranged for all patients to evaluate the effectiveness and safety of this treatment. The time points of follow-up were immediately after and at 1 week, 1, 2, 3, and 6 months after treatment. During the follow-up period, if post-treatment low back pain was unbearable for the patients, oral acetaminophen was allowed for temporary pain relief. The applications of oral acetaminophen were recorded for evaluating synthetically the outcome measurements.

Diagnostic Intra-Articular Block

Patients were positioned in the prone position with a pillow under the abdomen to straighten the lumbar

spine, and a C-arm was used for fluoroscopy. When the targeted lumbar facet joint space was clearly seen by rotating the C-arm, the puncture point was marked at the intersection of the ray and the skin. After skin sterilization and local infiltration anesthesia, a 21-gauge spinal needle was gently inserted into the facet joint space under fluoroscopic control. The position of the spinal needle was confirmed by injecting 0.1 to 0.2 mL of nonionic contrast medium (iohexol 15 g/50 mL) (Figure 2). When the needle was in place, 0.5 mL of 0.5% lidocaine was injected into the lumbar facet joint.

Selection of targeted levels of diagnostic intra-articular block was initially based on the findings of degenerative changes on the lumbar spine radiograph, regions of pain or referred pain, sites of palpated tenderness in the low back, and rich clinical experiences of the expert. A potential degenerative lumbar facet joint should be considered at the sites of maximal tenderness upon deep palpation, at levels with radiographic degenerative findings, at levels where mechanical, segmental provocation causes concordant pain, and/or at levels demonstrating palpable articular restriction in light of other segmental findings, such as facilitated muscle tone. Every patient might have unilateral or lateral and 1 or multiple degenerative lumbar facet joints. In addition, for every patient, 1 week was needed for the accurate evaluation of the validity and full metabolism of lidocaine after the diagnostic intra-articular block.

Interventional Treatment

PRP Preparation. Platelet-rich plasma preparation was performed in a standard laboratory that is subordinate to the department of orthopedics in our university hospital. For autologous PRP preparation, the standard 2-step centrifugation method was used. In the immediate pretherapeutic period, 5 to 10 mL (the exact amount depends on the number of treated levels) of venous blood sample was collected in sodium citrate anticoagulative tubes under sterile conditions. Then, the sample was centrifuged first at 200 g for 10 minutes at room temperature. Two layers were obtained after this centrifugation. The erythrocytes remained at the bottom of the tube, whereas platelets and leukocytes remained in the plasma at the top. The obtained plasma was centrifuged again at 400 g for 10 minutes to remove part of the platelet-poor plasma. Approximately 1 to 2 mL of buffy coat autologous PRP was prepared for lumbar facet joint injection as soon as possible. The

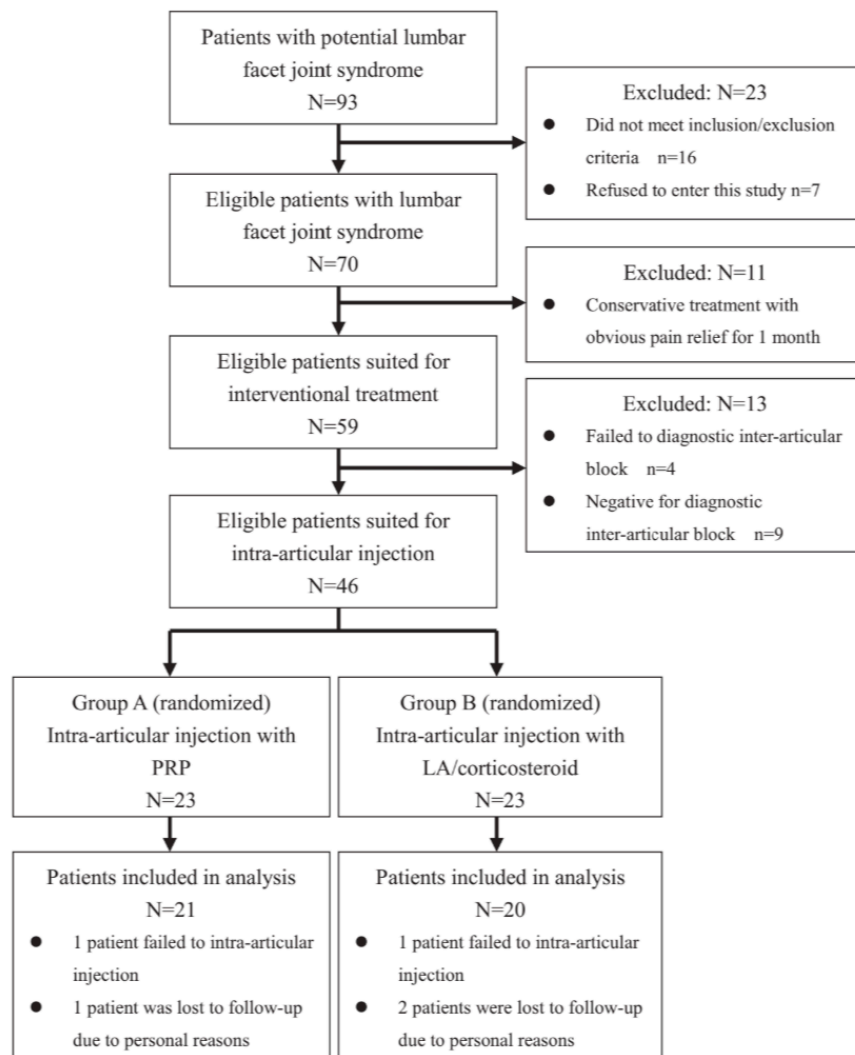


Figure 1. Flowchart diagram for study design. PRP, platelet-rich plasma; LA, local anesthetic.

concentration of platelet in native peripheral blood before the treatment and that in PRP after standard centrifugations was tested to ensure that the platelet concentration in PRP was almost 4 to 5 times greater than that in native peripheral blood (100 to $300 \times 10^9/\text{mL}$).

Intra-Articular Injection Under Fluoroscopy. Intra-articular injection under fluoroscopy was carried out as described above for diagnostic intra-articular block, and arthrography with 0.1 to 0.2 mL of nonionic contrast medium was performed to ensure that the spinal needle was positioned in the joint space. For group A patients, if optimal positioning of the needle was achieved, approximately 0.5 mL of autologous PRP for every targeted joint was injected slowly. For group B

patients, the same dose of the mixture of 0.5% lidocaine and 5 mg/mL betamethasone ($4:1$, vol/vol) was injected into each targeted segment. Whether group A or group B, the treated levels were identical to the levels of diagnostic intra-articular blocks.

After injection treatment, the absence of short-term complications such as bleeding, allergy, or nerve injury was confirmed for every patient before leaving the hospital. In addition, rest for 1 week was suggested to avoid the overuse of the waist after this procedure.

Outcome Measurements

The effectiveness measurements included post-treatment pain relief, improvement in lumbar function, and patients' satisfaction. The safety measurements included

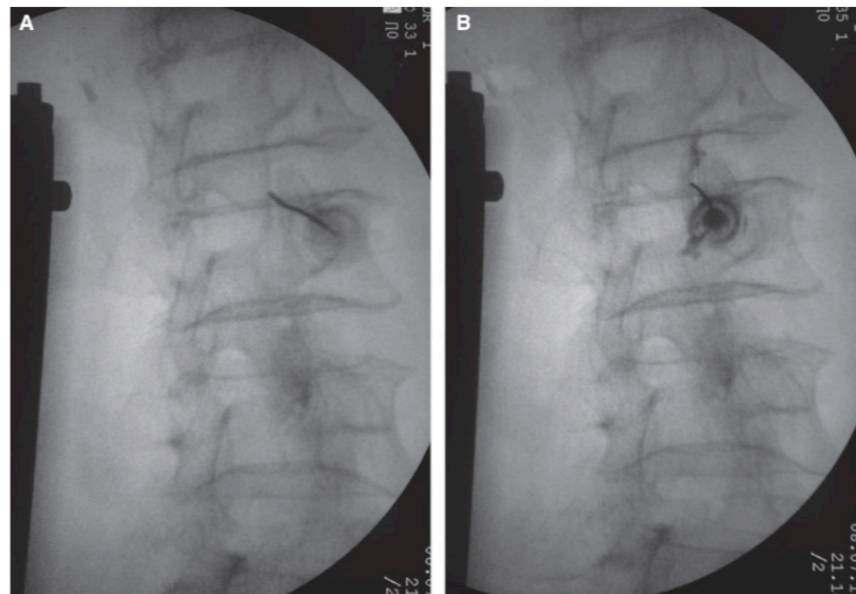


Figure 2. The position of the spinal needle was confirmed by fluoroscopy during a standard procedure of diagnostic intra-articular block: without contrast medium (A) and with contrast medium (B).

increased pain and relevant complications such as bleeding, infection, allergy, neurologic deficit, and injection-related complications. The evaluation indexes of pain relief included the pain visual analog scale (VAS) (pain scale, 0 to 10) at rest and during flexion; a pain relief rate of over 50% at rest was defined as the objective treatment success. Outcome measurements for improvement in lumbar function were applied by the Roland-Morris Disability Questionnaire (RMQ) and Oswestry Disability Index (ODI). The outcome of the RMQ is a total score (0 represents no disability and 24 represents maximum disability).²² The ODI is a self-administered questionnaire with 10 items concerning intensity of pain, lifting, ability to care for oneself, ability to walk, ability to sit, sexual function, ability to stand, social life, sleep quality, and ability to travel.²³ Each item in the ODI has 6 options to represent a score from 0 to 5. A percentage score indicates the result: total score of the patient/total raw score possible \times 100%. If the patient has failed to complete all items, the total raw score will remove the score of the uncompleted items.

The modified MacNab criteria were used for the evaluation of patient-reported subjective satisfaction, rated as excellent, good, fair, or poor. The outcomes “excellent” and “good” were classified as satisfaction, whereas “fair” and “poor” were classified as dissatisfaction. Simultaneously, the relevant complications after treatment were observed to assess the safety of

intra-articular injection with different drugs. In addition, the total use of acetaminophen after treatment was recorded and analyzed for the outcome measurements.

Randomization and Blinding

After a series of rigorous screenings, 46 patients were enrolled in the study. After completed written informed consent, they were assigned randomly to group A or group B.

All patients were blinded before treatment and after treatment to which drugs were injected. All intra-articular injections were performed by the same experienced spine expert, and he was not involved in the subsequent steps. The new reviewers completed the follow-up and assessment of all outcomes, and, more importantly, they were blinded to group assignment.

Statistical Analysis

The statistical analysis was performed using the SPSS version 19.0 program (IBM Corp., Armonk, NY, USA). For standard descriptive statistics, means \pm standard deviations (SD) were given. The Mann-Whitney *U*-test was used for the comparisons of nonparametric variables between the 2 groups; similarly, the Pearson chi-square test was used for categorical variables and the independent-samples *t*-test was used for normal

distributed data. The Wilcoxon test was applied for the comparisons of the situations between pretreatment and post-treatment. $P < 0.05$ with 95% confidence intervals was considered statistically significant.

RESULTS

Forty-six eligible patients were assigned randomly to group A (23 patients) and group B (23 patients). For group A, 21 patients completed the final evaluation at the end of 6 months (1 patient failed to receive an intra-articular injection and 1 patient was lost to follow-up due to personal reasons). Only 20 patients attended the final follow-up visit in group B (1 patient failed to receive an intra-articular injection and 2 patients were lost to follow-up).

General demographic and clinical characteristics of patients are listed in Table 2. At baseline, all samples were considered homogeneous. The patients from different groups were similar with regard to gender, age, body mass index, pain VAS at rest and during flexion, duration of pain, status of referred pain, sides of pain, and levels treated ($P > 0.05$).

Regarding the outcomes of low back pain, assessed by pain VAS at rest and during flexion, significant reductions occurred in both groups at all follow-up points except immediately after injection ($P < 0.01$). But in the comparison between the 2 groups, the VAS scores at rest and during flexion decreased more in group B at 1 week and 1 month after injection ($P < 0.01$).

Table 2. General Demographic and Clinical Characteristics of Patients in Group A (Intra-Articular Injection with Platelet-Rich Plasma) and Group B (Intra-Articular Injection with LA/Corticosteroid) at Baseline

Variables	Group A (n = 23)	Group B (n = 23)	P
Male	10 (43.48%)	9 (39.13%)	0.77
Female	13 (56.52%)	14 (60.87%)	
Ages (years)	52.91 ± 7.60	52.78 ± 7.25	0.95
BMI	22.56 ± 1.39	22.38 ± 1.45	0.66
VAS at rest	7.09 ± 1.08	6.74 ± 1.10	0.26
VAS during flexion	8.04 ± 0.88	8.13 ± 0.87	0.69
Duration of pain (months)	19.43 ± 12.30	16.70 ± 12.03	0.35
With referred pain	9 (39.13%)	11 (47.83%)	0.552
Sides of pain			
Left	5 (21.74%)	7 (30.43%)	0.767
Right	7 (30.43%)	6 (26.08%)	
Bilateral	11 (47.83%)	10 (43.49%)	
Levels treated			
Single level	5 (21.74%)	7 (30.43%)	0.502
Multiple levels	18 (78.26%)	16 (69.57%)	

BMI, body mass index; VAS, visual analog scale.

However, at 3 months after injection and thereafter, pain relief was significantly better in group A ($P < 0.01$) (Figure 3).

The results about improvement of lumbar functional capacity assessed by the RMQ and ODI are shown in Figure 4. Significant improvement in lumbar functional capacity was observed in both the groups compared with baseline values ($P < 0.01$). The analysis of most follow-up points showed a statistically significant difference between the 2 groups. The changes as assessed by the RMQ and ODI over time were in agreement with the pain VAS scores. In the short-term period (1 week and 1 month), group A patients improved more than group B patients ($P < 0.05$); however, the opposite seems to have occurred in the long-term period (3 and 6 months) ($P < 0.05$).

According to the modified MacNab criteria, the outcomes of patient-reported subjective satisfaction are shown in Table 3. For group B, the highest subjective satisfaction was 80% after 1 month, but only 50% after 6 months. For group A, however, the subjective satisfaction was progressive over time (47.62% to 80.95%). At the end of 6 months, group A patients were more likely to report satisfaction with their treatment than group B patients ($P < 0.05$), but no statistical differences were found between either group at any other follow-up points ($P > 0.05$). Similarly, the highest objective success rate with over 50% pain relief (85.00%) occurred at 1 week and 1 month in group B. For group A, the highest objective success rate was 80.95%, found at 3 and 6 months after treatment. During the 6-month follow-up period, 8 patients (40.00%) in group B used acetaminophen for temporary post-treatment pain relief, whereas only 5 patients (23.81%) in group A did so (Table 4).

In addition, whether group A or group B, no patients reported any severe treatment-related complications or adverse events during the 6-month follow-up period. Only 7 patients (33.33%) in group A and 5 patients (25.00%) in group B reported that low back pain increased immediately after the injection.

DISCUSSION

Although no conclusive evidence about the precise mechanisms of autologous PRP has been demonstrated, PRP is still widely used for tissue repair in many different musculoskeletal disorders, such as osteoarthritis, lateral epicondylitis, rotator cuff disease, Achilles and patella tendinopathy, hamstring injuries, and degenerative

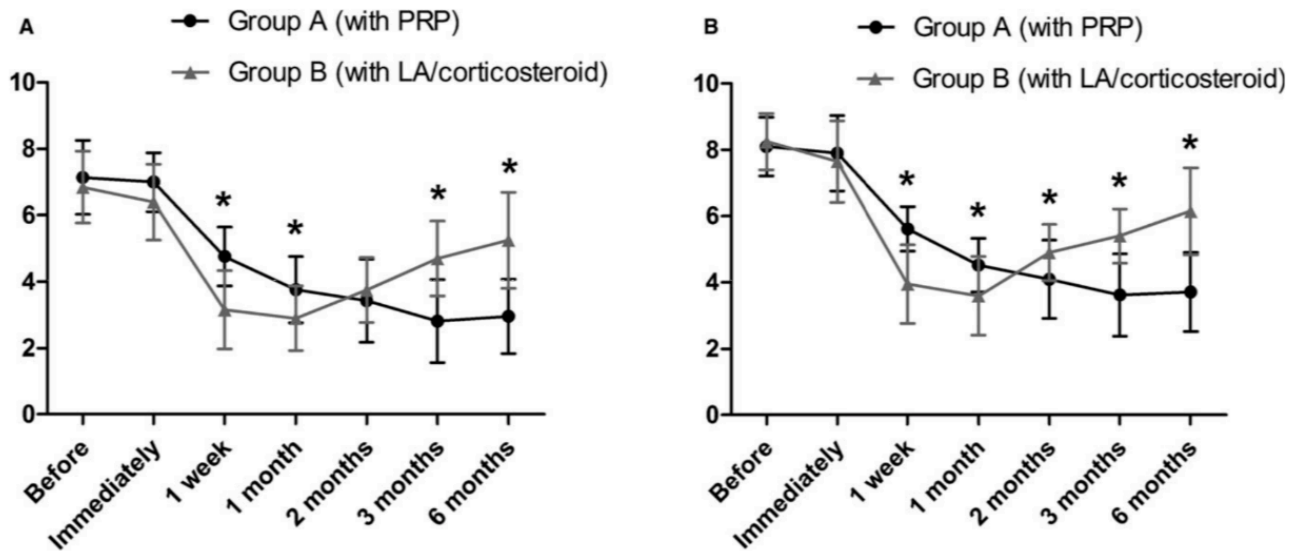


Figure 3. The visual analog scale scores of low back pain at rest (A) and during flexion (B). *Significant difference between groups ($P < 0.01$). PRP, platelet-rich plasma; LA, local anesthetic.

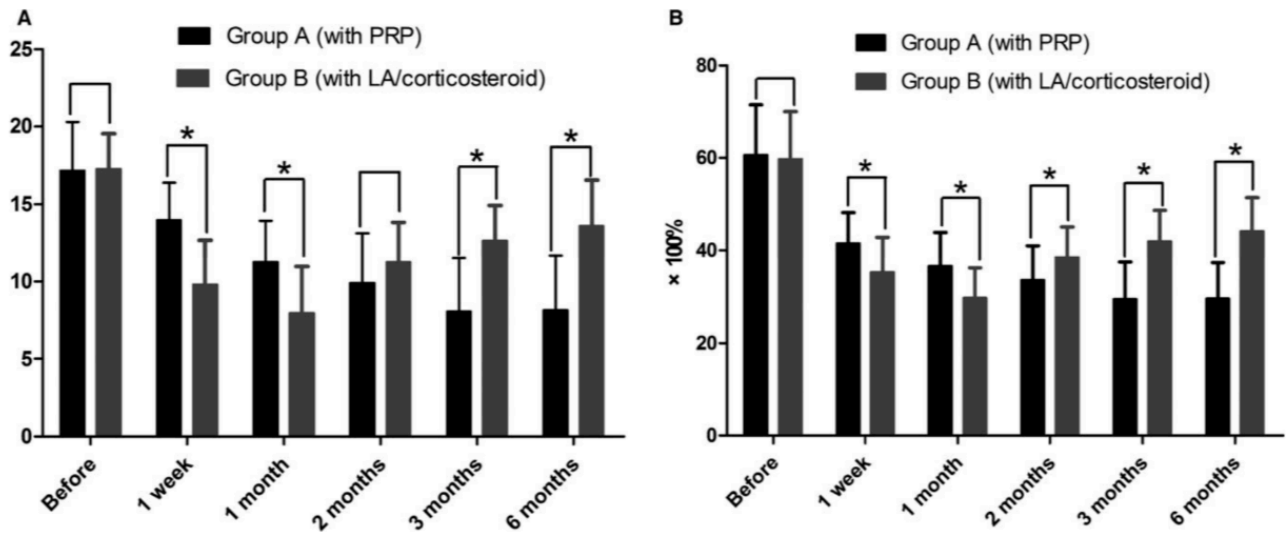


Figure 4. The comparisons of lumbar functional capacity between two groups: Roland-Morris Disability Questionnaire (A) and Oswestry Disability Index (B). *Significant difference between groups ($P < 0.05$). PRP, platelet-rich plasma; LA, local anesthetic.

spine disease.²⁴ Due to the rich activated growth factors and cytokines, PRP has powerful anti-inflammatory effects and natural healing abilities.^{19–21} Many previous studies have demonstrated that PRP can provide appealing antinociceptive and anti-inflammatory effects by suppressing inflammatory mediator concentration and expression of their genes in synoviocytes and chondrocytes, especially in osteoarthritis of peripheral synovial joints such as those in the knee and hip.^{25,26} As the only synovial joints in the spine, most investigators believe that inflammatory changes such as

osteoarthritis are most responsible for lumbar facet joint syndrome, similar to other peripheral synovial joints.^{6–8} In addition, as autologous PRP is derived from patients' own venous blood; theoretically, it is a safer option for facet joint injection than other heterogeneous drugs.²⁷

Therefore, we tried to use autologous PRP as one of the appropriate novel treatment options for lumbar facet joint syndrome and compare the effectiveness and safety of intra-articular autologous PRP injection vs. intra-articular LA/corticosteroid injection in the treatment of

Table 3. Comparisons Between Groups for Subjective Satisfaction: Modified MacNab Criteria

Group	Excellent	Good	Fair	Poor	P
Immediately after					
A	2 (9.52%)	8 (38.10%)	4 (19.05%)	7 (33.33%)	0.636
B	3 (15.00%)	8 (40.00%)	4 (20.00%)	5 (25.00%)	
1 week					
A	4 (19.05%)	8 (38.10%)	6 (28.57%)	3 (14.29%)	0.228
B	10 (50.00%)	5 (25.00%)	3 (15.00%)	2 (10.00%)	
1 month					
A	6 (28.57%)	7 (33.33%)	6 (28.57%)	2 (9.52%)	0.203
B	12 (60.00%)	4 (20.00%)	2 (10.00%)	2 (10.00%)	
2 months					
A	9 (42.86%)	6 (28.57%)	4 (19.05%)	2 (9.52%)	0.658
B	6 (30.00%)	7 (35.00%)	5 (25.00%)	2 (10.00%)	
3 months					
A	11 (52.38%)	5 (23.10%)	3 (14.29%)	2 (9.52%)	0.153
B	5 (25.00%)	6 (30.00%)	6 (30.00%)	3 (15.00%)	
6 months					
A	11 (52.38%)	6 (28.57%)	2 (9.52%)	2 (9.52%)	0.037
B	4 (20.00%)	6 (30.00%)	6 (30.00%)	4 (20.00%)	

P indicates the comparisons between groups using Pearson chi-square test; the patients who considered the outcomes of this treatment as "excellent" or "good" were classified as having satisfaction and the patients who considered as "fair" or "poor" were classified as having dissatisfaction. Group A indicates intra-articular injection with platelet-rich plasma; group B indicates intra-articular injection with LA/corticosteroid.

lumbar facet joint syndrome. The aim of this study was not to provide conclusive insight into the fundamental mechanisms of PRP injection for the treatment of lumbar facet joint syndrome.

Corticosteroid with or without local anesthetic is one of the most common drugs for interventional lumbar facet joint injection treatment and seems to be the gold standard for comparison of newer injection therapies. Most experts believe that the rationale for lumbar facet joint corticosteroid injection is to treat the inflammation due to osteoarthritis,²⁸ whereas local anesthetic is only for the apparent temporary alleviation of symptoms. However, the exact mechanism of action of intra-articular LA/corticosteroid injection is unknown. Besides, the therapeutic effects of lumbar facet joint syndrome with interventional intra-articular LA/corticosteroid injection are also controversial. A narrative

review conducted by Bogduk revealed that the apparent efficacy of lumbar intra-articular corticosteroid injection for low back pain was not better than that of a sham injection.²⁹ However, Carrette et al.³⁰ reported significant pain relief and functional improvement at 6-month follow-up after corticosteroid injection. Ribeiro et al.³¹ also found that there was slight pain relief and functional improvement at 24 weeks after intra-articular corticosteroid injection. Interestingly, the lowest VAS score (4.7) occurred at 1 week and 4 weeks after treatment, whereas the pain VAS score at 24 weeks was 5.3. Pneumáticos et al.³² showed that 87% of patients with facet joint abnormalities had an improvement in the pain score at 1 month after corticosteroid and local anesthetic injections, but only 53% patients had the same results after 6 months. These results seem to indicate that the short-term effects of the injection with corticosteroid with or without local anesthetic are better than the long-term effects. In several systematic reviews, investigators have asserted that there is fair to good evidence for intra-articular corticosteroid injection to treat lumbar facet joint pain for short-term pain relief and functional improvement, but evidence of long-term pain relief is limited.^{14,15} According to the above changes of LA/corticosteroid treatment, our results of LA/corticosteroid injection showed that the mean VAS scores at rest were 6.40, 3.15, 2.90, 3.75, 4.70, and 5.25 immediately after and at 1 week, 1, 2, 3, and 6 months after treatment, respectively.

In our comparative study, general demographic and clinical characteristics of patients with autologous PRP or LA/corticosteroid injection treatment were similar at baseline. Compared with baseline, both PRP and LA/corticosteroid showed significant pain relief at rest and during flexion. In the short-term period (1 month), LA/corticosteroid had a better outcome for pain relief than PRP. However, in a longer term period, for PRP, sustained reduction of pain VAS scores at rest and

Table 4. Results of Objective Success Rate and Total Usage Rate of Post-Treatment Drugs Between Groups Over Time

Group	Immediately after	1 week	1 month	2 months	3 months	6 months
Objective success rate with over 50% pain relief at rest						
A	0 (0.00%)	4 (19.05%)	13 (61.90%)	15 (71.43%)	17 (80.95%)	17 (80.95%)
B	0 (0.00%)	17 (85.00%)	17 (85.00%)	12 (60.00%)	3 (15.00%)	4 (20.00%)
P		< 0.001	0.095	0.440	< 0.001	< 0.001
Total usage rate of acetaminophen after treatment						
A	3 (14.29%)	5 (23.81%)	5 (23.81%)	5 (23.81%)	5 (23.81%)	5 (23.81%)
B	3 (15.00%)	3 (15.00%)	3 (15.00%)	3 (15.00%)	5 (15.00%)	8 (40.00%)
P	1.000*	0.751*	0.751*	0.751*	1.000*	0.265

The total usage rate of post-treatment drugs is calculated by a cumulative method.

*The results are calculated by Pearson chi-square test with a continuity correction. Group A indicates intra-articular injection with platelet-rich plasma; group B indicates intra-articular injection with LA/corticosteroid.

during flexion occurred at the end of 6 months after injection; for LA/corticosteroid, reductions were less marked after 6 months but remained statistically significant compared with baseline. These changes were consistent with lumbar functional improvements, which were assessed by the RMQ and ODI. Other results, such as patient-reported subjective satisfaction, objective success rate, and total usage rate of post-treatment drugs, also confirmed these changes. All of these outcomes demonstrated that autologous PRP was a superior treatment option for longer duration efficacy in the treatment of lumbar facet joint syndrome, compared with conventional LA/corticosteroid.

Similar situations appear in other fields, especially musculoskeletal disorders. Many controlled and uncontrolled studies have demonstrated that favorable pain relief and functional improvement could have been obtained by intra-articular PRP injection, whether in hip osteoarthritis or knee osteoarthritis.^{33,34} A systematic review by Meheux et al.¹⁸ summarized that the clinical outcomes of knee osteoarthritis are significantly better after PRP injection vs. hyaluronic acid injection at 3 to 12 months post-treatment. Gosens et al.³⁵ and Rodriguez³⁶ compared the effectiveness of PRP to standard corticosteroid injection for later epicondylitis and showed that at short-term follow-up, both groups had significant improvement in pain and function, but at long-term follow-up, PRP was more effective, providing more positive results than corticosteroid.

Due to the lack of pathognomonic predictors that allow one to definitively discriminate between patients with low back pain of lumbar facet joint origin and low back pain of other sources, the diagnosis of lumbar facet joint syndrome depends principally on a comprehensive diagnostic method, including the histories, clinical features, physical examinations, and radiologic findings, as well as invasive diagnostic blocks when necessary.¹⁴ The combination of clinical factors and radiologic findings may be helpful for the initial diagnosis of lumbar facet joint syndrome, but it is limited and unreliable.^{37,38} Consequently, although the false-positive rate of a single diagnostic block is as high as 38%,³⁹ it is still generally accepted that invasive diagnostic blocks (intra-articular blocks or medial branch blocks) are the most reliable methods for diagnosing lumbar facet joints as low back pain generators.⁴⁰⁻⁴² For these reasons, we used the comprehensive criteria of clinical factors and radiologic findings for the initial diagnosis of lumbar facet joint

syndrome, and applied diagnostic blocks for the confirmed diagnosis.

In addition, based on our experiences, after approximately 0.5 mL of solution was injected into each lumbar facet joint, the injection pressure was significantly increased. To avoid the rupture of the joint capsule and efflux of injected drugs, only 0.5 mL of different drugs was selected to be injected. This approach is in agreement with the literature.⁴³

The complications of lumbar facet joint injection are mostly 2-sided: complications related to puncture and complications related to various drugs, but they are all exceedingly rare.¹⁵ In our study, whether PRP or LA/corticosteroid was utilized, patients had no severe treatment-related complications or adverse events in the 6-month follow-up period. Only 7 patients (33.33%) in group A and 5 patients (25.00%) in group B reported increased low back pain immediately after the injection, and in all instances, the pain was relieved in a few hours without any pharmacological interventions. The increased low back pain was suspected to come from injection site tissue damage during puncture and expansion of the joint capsule. Only 1 patient in each group failed to complete the intra-articular injection. Therefore, the treatment method of lumbar facet joint injection is easy and safe enough.

As an initial study, our study might have many limitations, such as the lack of a placebo-controlled group and relatively small sample. In a future study, a placebo-controlled trial, larger sample size, and tighter patient selection criteria may provide a more convincing result and further support these findings.

In conclusion, autologous PRP is an ideal new injectable drug for the application of intra-articular injection to treat lumbar facet joint syndrome. Both PRP injection and LA/corticosteroid injection were determined to be effective, easy, and safe enough for the treatment of lumbar facet joint syndrome after 6 months of follow-up. However, autologous PRP may be a superior treatment option for longer duration efficacy.

CONFLICT OF INTERESTS

The authors report no conflict of interests.

REFERENCES

1. Goldthwaite JE. The lumbosacral articulation: an explanation of many cases of lumbago, sciatica, and paraplegia. *Boston Med Surg J.* 1911;164:365-372.

2. Putti V. New concepts in the pathogenesis of sciatica pain. *Lancet*. 1927;2:53–60.
3. Ghormley RK. Low back pain with special reference to the articular facets, with presentation of an operative procedure. *J Am Med Assoc*. 1933;101:1773–1777.
4. Proietti L, Schiro GR, Sessa S, Scaramuzza L. The impact of sagittal balance on low back pain in patients treated with zygoapophysial facet joint injection. *Eur Spine J*. 2014;23 (suppl 6):628–633.
5. Manchikanti L, Singh V, Falco FJ, Cash KA, Pampati V. Lumbar facet joint nerve blocks in managing chronic facet joint pain: one-year follow-up of a randomized, double-blind controlled trial: Clinical Trial NCT00355914. *Pain Physician*. 2008;11:121–132.
6. Kalichman L, Li L, Kim DH, et al. Facet joint osteoarthritis and low back pain in the community-based population. *Spine (Phila Pa 1976)*. 2008;33:2560–2565.
7. Marcia S, Masala S, Marini S, et al. Osteoarthritis of the zygapophysial joints: efficacy of percutaneous radiofrequency neurotomy in the treatment of lumbar facet joint syndrome. *Clin Exp Rheumatol*. 2012;30:314.
8. Shuang F, Hou SX, Zhu JL, et al. Establishment of a rat model of lumbar facet joint osteoarthritis using intraarticular injection of urinary plasminogen activator. *Sci Rep*. 2015;5:9828.
9. Igarashi A, Kikuchi S, Konno S, Olmarker K. Inflammatory cytokines released from the facet joint tissue in degenerative lumbar spinal disorders. *Spine (Phila Pa 1976)*. 2004;29:2091–2095.
10. Kim JS, Ali MH, Wydra F, et al. Characterization of degenerative human facet joints and facet joint capsular tissues. *Osteoarthritis Cartilage*. 2015;23:2242–2251.
11. Civelek E, Cansever T, Kabatas S, et al. Comparison of effectiveness of facet joint injection and radiofrequency denervation in chronic low back pain. *Turk Neurosurg*. 2012;22:200–206.
12. Boswell MV, Colson JD, Spillane WF. Therapeutic facet joint interventions in chronic spinal pain: a systematic review of effectiveness and complications. *Pain Physician*. 2005;8:101–114.
13. Mooney V, Robertson J. The facet syndrome. *Clin Orthop Relat Res*. 1976;115:149–156.
14. Cohen SP, Raja SN. Pathogenesis, diagnosis, and treatment of lumbar zygapophysial (facet) joint pain. *Anesthesiology*. 2007;106:591–614.
15. Falco FJ, Manchikanti L, Datta S, et al. An update of the effectiveness of therapeutic lumbar facet joint interventions. *Pain Physician*. 2012;15:E909–E953.
16. Kabiri A, Esfandiari E, Esmaeili A, Hashemibeni B, Pourazar A, Mardani M. Platelet-rich plasma application in chondrogenesis. *Adv Biomed Res*. 2014;3:138.
17. Yadav R, Kothari SY, Borah D. Comparison of local injection of platelet rich plasma and corticosteroids in the treatment of lateral epicondylitis of humerus. *J Clin Diagn Res*. 2015;9:Rc05–Rc07.
18. Meheux CJ, McCulloch PC, Lintner DM, Varner KE, Harris JD. Efficacy of intra-articular platelet-rich plasma injections in knee osteoarthritis: a systematic review. *Arthroscopy*. 2016;32:495–505.
19. Bendinelli P, Matteucci E, Dogliotti G, et al. Molecular basis of anti-inflammatory action of platelet-rich plasma on human chondrocytes: mechanisms of NF-kappaB inhibition via HGF. *J Cell Physiol*. 2010;225:757–766.
20. Mazzocca AD, McCarthy MB, Intravia J, et al. An in vitro evaluation of the anti-inflammatory effects of platelet-rich plasma, ketorolac, and methylprednisolone. *Arthroscopy*. 2013;29:675–683.
21. Campbell KA, Saltzman BM, Mascarenhas R, et al. Does intra-articular platelet-rich plasma injection provide clinically superior outcomes compared with other therapies in the treatment of knee osteoarthritis? A systematic review of overlapping meta-analyses. *Arthroscopy*. 2015;31:2213–2221.
22. Monticone M, Baiardi P, Vanti C, et al. Responsiveness of the Oswestry Disability Index and the Roland Morris Disability Questionnaire in Italian subjects with sub-acute and chronic low back pain. *Eur Spine J*. 2012;21:122–129.
23. Fairbank JC, Pynsent PB. The Oswestry disability index. *Spine (Phila Pa 1976)*. 2000;25:2940–2952; discussion 2952.
24. Cook JL, Smith PA, Bozynski CC, et al. Multiple injections of leukoreduced platelet rich plasma reduce pain and functional impairment in a canine model of ACL and meniscal deficiency. *J Orthop Res*. 2016;34:607–615.
25. Andia I, Maffulli N. Platelet-rich plasma for managing pain and inflammation in osteoarthritis. *Nat Rev Rheumatol*. 2013;9:721–730.
26. Sundman EA, Cole BJ, Karas V, et al. The anti-inflammatory and matrix restorative mechanisms of platelet-rich plasma in osteoarthritis. *Am J Sports Med*. 2014;42:35–41.
27. Everts PA, Knape JT, Weibrich G, et al. Platelet-rich plasma and platelet gel: a review. *J Extra Corpor Technol*. 2006;38:174–187.
28. Lakemeier S, Lind M, Schultz W, et al. A comparison of intraarticular lumbar facet joint steroid injections and lumbar facet joint radiofrequency denervation in the treatment of low back pain: a randomized, controlled, double-blind trial. *Anesth Analg*. 2013;117:228–235.
29. Bogduk N. A narrative review of intra-articular corticosteroid injections for low back pain. *Pain Med*. 2005;6:287–296.
30. Carette S, Marcoux S, Truchon R, et al. A controlled trial of corticosteroid injections into facet joints for chronic low back pain. *N Engl J Med*. 1991;325:1002–1007.
31. Ribeiro LH, Furtado RN, Konai MS, Andreo AB, Rosenfeld A, Natour J. Effect of facet joint injection versus systemic steroids in low back pain: a randomized controlled trial. *Spine (Phila Pa 1976)*. 2013;38:1995–2002.
32. Pneumáticos SG, Chatziioannou SN, Hipp JA, Moore WH, Esses SI. Low back pain: prediction of short-term outcome of facet joint injection with bone scintigraphy. *Radiology*. 2006;238:693–698.
33. Patel S, Dhillon MS, Aggarwal S, Marwaha N, Jain A. Treatment with platelet-rich plasma is more effective than

placebo for knee osteoarthritis: a prospective, double-blind, randomized trial. *Am J Sports Med.* 2013;41:356–364.

34. Battaglia M, Guaraldi F, Vannini F, et al. Efficacy of ultrasound-guided intra-articular injections of platelet-rich plasma versus hyaluronic acid for hip osteoarthritis. *Orthopedics.* 2013;36:e1501–e1508.

35. Gosens T, Peerbooms JC, van Laar W, den Ouden BL. Ongoing positive effect of platelet-rich plasma versus corticosteroid injection in lateral epicondylitis: a double-blind randomized controlled trial with 2-year follow-up. *Am J Sports Med.* 2011;39:1200–1208.

36. Rodriguez JA. Corticosteroid versus platelet-rich plasma injection in epicondylitis. *Orthop Nurs.* 2014;33:257–265; quiz 266–257.

37. Deyo RA, Rainville J, Kent DL. What can the history and physical examination tell us about low back pain? *JAMA.* 1992;268:760–765.

38. Boden SD. The use of radiographic imaging studies in the evaluation of patients who have degenerative disorders of the lumbar spine. *J Bone Joint Surg Am.* 1996;78:114–124.

39. Schwarzer AC, Aprill CN, Derby R, Fortin J, Kine G, Bogduk N. The false-positive rate of uncontrolled diagnostic blocks of the lumbar zygapophysial joints. *Pain.* 1994;58:195–200.

40. Bogduk N. International Spinal Injection Society guidelines for the performance of spinal injection procedures. Part 1: Zygapophysial joint blocks. *Clin J Pain.* 1997;13:285–302.

41. Slipman CW, Bhat AL, Gilchrist RV, Issac Z, Chou L, Lenrow DA. A critical review of the evidence for the use of zygapophysial injections and radiofrequency denervation in the treatment of low back pain. *Spine J.* 2003;3:310–316.

42. Senoglu N, Senoglu M, Safavi-Abbasi S, Shedd SA, Crawford NR. Morphologic evaluation of cervical and lumbar facet joints: intra-articular facet block considerations. *Pain Pract.* 2010;10:272–278.

43. Lynch MC, Taylor JF. Facet joint injection for low back pain. A clinical study. *J Bone Joint Surg Br.* 1986;68:138–141.