



Pediatric Non-Fatal Strangulation PhotoDocumentation Protocol 2018

Supplemental Edition for Pediatric * Cases

[The Edition for Adult Strangulation Cases Can Be Found Here](#)

**The children used in this protocol are child models. All photography sessions were done with and under parental supervision.*



SDFI

Secure Digital
Forensic Imaging

Secure Beyond Reasonable Doubt®

Introduction:

Kid-Friendly Communication in a Medical Setting: Helpful Tips

1. Talk with the child and use their name. This helps the child feel that you care.
2. Smile and say something positive to the child. *"Your hair looks cute today"* etc. Kids like friendly adults and will respond better.
3. Sit or squat lower than the child. This gives them some feeling of control over the situation. This will help calm their nerves, fears and anxieties thus increasing their level of cooperation.
4. Phrase your instructions as "helping". *"I need you to help me by placing your in hands your lap. Let me show you."*
5. Reassure and praise when it is due. *"You are doing such a good job!"*
6. Give the child a helping role. Children like to help and playing a role in their own examination gets their minds off being apprehensive or fearful.
7. Distraction is your friend in pediatric care. Have child friendly toys or coloring books for them to play with as well.

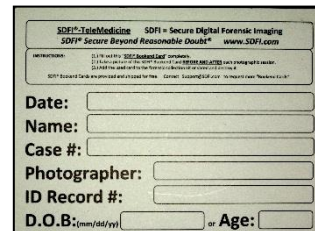
Mastering the lingo: What Kids Hear When you say...

1. Young children do not get abstract ideas. They are concrete, so be specific with the task. Instead of saying *"relax"*, say *"please place your hand on your lap"*.
2. Use open ended questions allowing them to talk. Be patient and listen.
3. Trauma informed care and interviews work better when you ask children questions that will make them use any of their five senses. *"Tell me everything about what you smelled?"* etc.
4. Children respond better to friendly adults who smile and listen.

Procedure:

1. The very first photo the forensic examiner will take is that of a book end card or the patient’s ID wristband. It will mark the start of the examination/PhotoDocumentation.

Note: A copy of the SDFI bookend card can be downloaded at



SDFI®-TeleMedicine SDFI = Secure Digital Forensic Imaging
SDFI® Secure Beyond Reasonable Doubt® www.SDFI.com

IDENTIFICATION: [] (Print name in all caps, DO NOT WRITE IN THESE SPACES)
SDFI®-TeleMedicine, 806 Buchanan Blvd, STE 115-299, Boulder City, NV 89005
SDFI®-TeleMedicine, 806 Buchanan Blvd, STE 115-299, Boulder City, NV 89005

Date: []
Name: []
Case #: []
Photographer: []
ID Record #: []
D.O.B: (mm/dd/yy) [] or Age: []

http://www.sdfi.com/downloads/SDFI_1Up_Bookend_Card_Page_Scaling_None.pdf

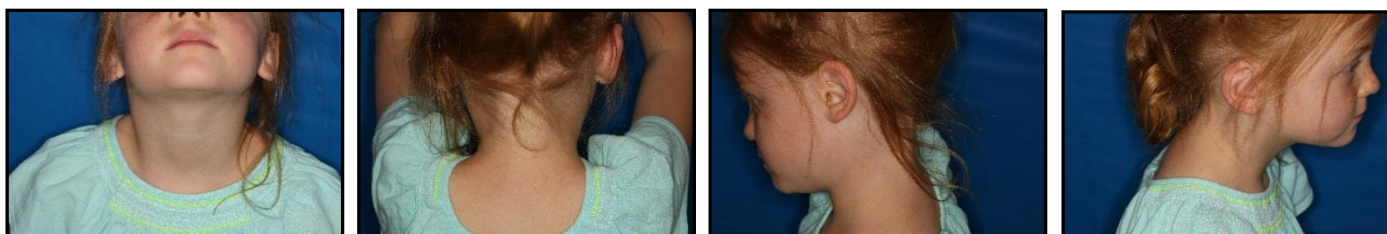2. Perform a full body overlapping photographic storyboard. This series of photos will identify the patient and will be useful in determining the general condition of the patient at the time of examination.

Note: a copy of the PhotoDocumentation Protocol can be downloaded at

http://www.sdfi.com/downloads/SDFI_Digital_Protocol.pdf. Once downloaded, refer to pages 2 & 3 of the protocol for more information about this step.



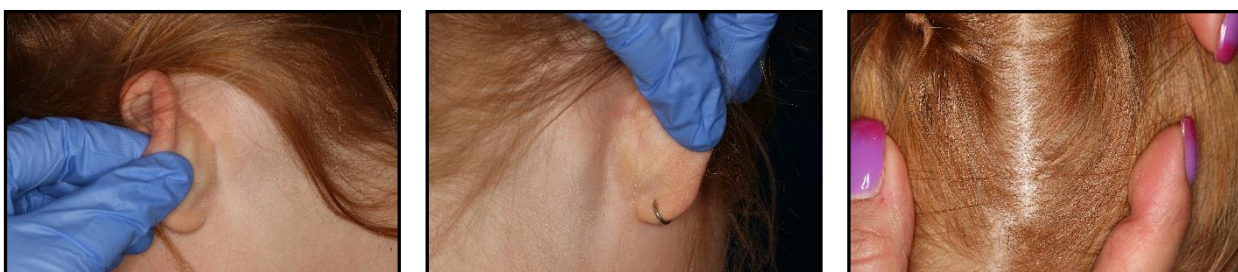3. Take a series of mid-distance photos of the front (*with head tilted backwards to expose the full neck and the area under the chin*), back, left side of the face/head, upper chest/neck, upper back/nape and shoulders.



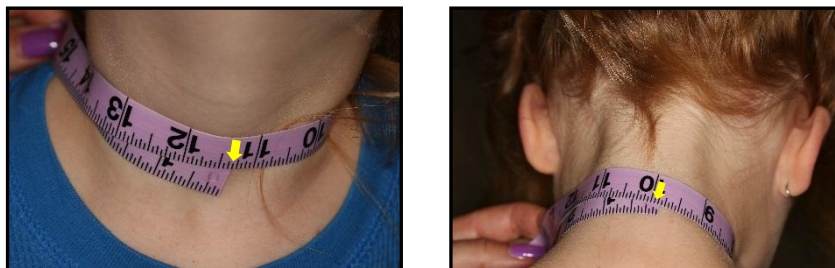

4. Take a series of close-up photos of any visible injury and any area of interest on the front, left side, right side and back of the neck. Take a photo of the finding with a measuring device like the ABFO Photomacrographic scale, then a second photo without the measuring device. Repeat for additional findings.

Conduct an assessment and take close-up photos of visible injuries to other areas such as the ears, **behind the ears**, scalp, jaw line, submandibular area and chin. Examine the tympanic membrane as well and document your findings.



5. Take an initial measurement around the neck using a tape measure. Mark where in the neck area the measurement was taken. Take a close-up photo of this measurement. Take a second measurement on the same area around the neck using a tape measure after 12-24 hours and take a close-up photo of this measurement. Document your findings and follow your medical protocol. An increase in size will indicate swelling and potential medical issues.



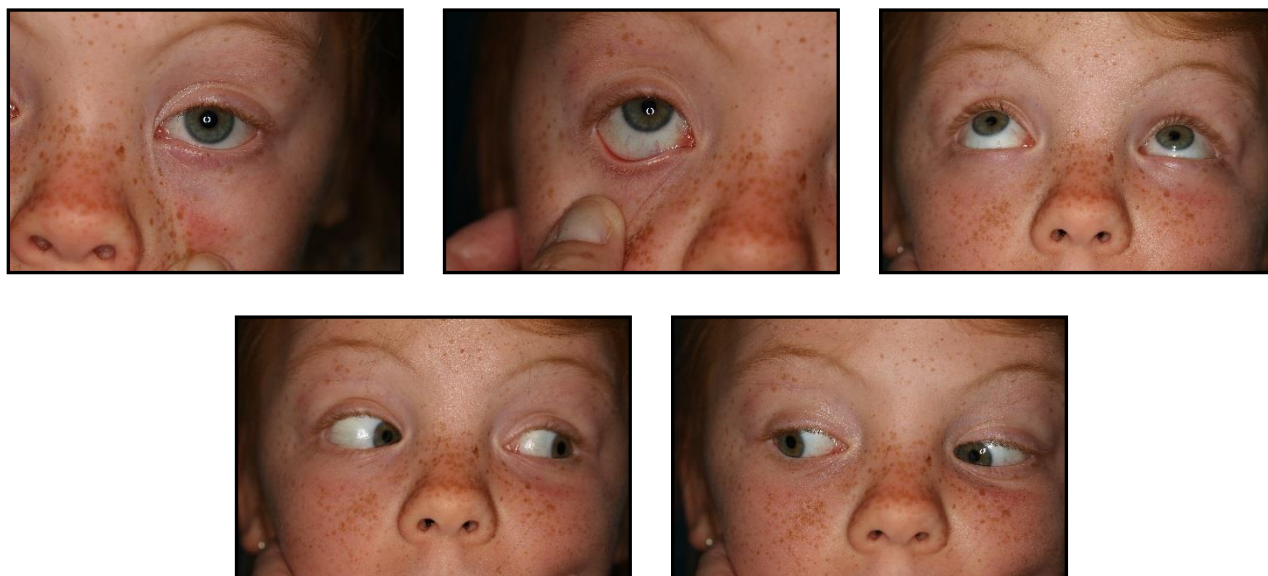6. Capture a series of close-up photos of the eyes looking to the front, up, down, to the left and to the right. The examiner should look for petechial hemorrhages or sub-conjunctival hemorrhages. In some cases, you might need to hold the child's head still as some have a tendency to turn their heads as well when the instructions are given. Holding up a toy to the direction you want the child to look can be effective. There are no hemorrhages noted in these photographs.



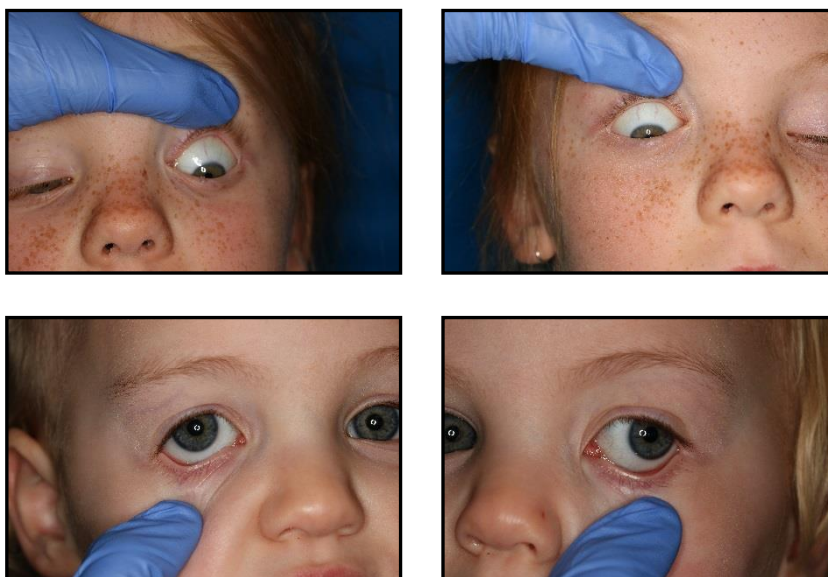
SDFI

Secure Digital
Forensic Imaging

Secure Beyond Reasonable Doubt®



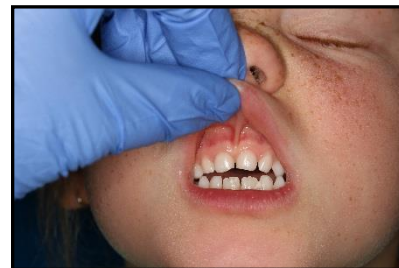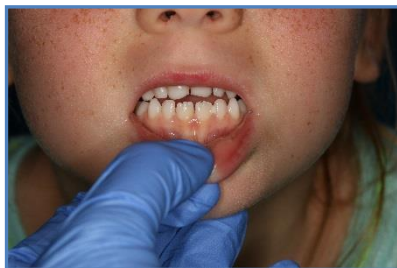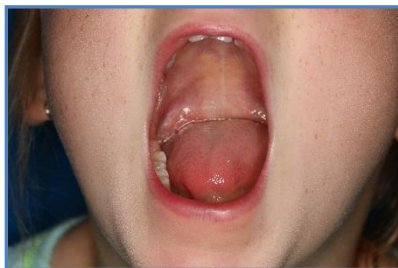7. Use the finger of your gloved hand to gently lift the upper eyelids. Take a close-up photo of each eyelid. Some children may not tolerate a Q-tip to be used to roll the upper eyelid and at times this can stress them. This will make conducting the rest of the examination more difficult. "Do no harm" is a good principle to follow. If the child is able, consider having the child retract their own eyelids.



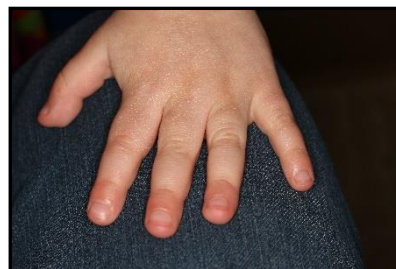
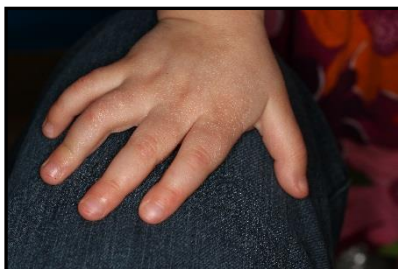
8. Take a series of close-up photos of the upper and lower lip if you see or suspect bruising, hemorrhaging or detect the presence of petechiae. The examiner will also look into the oral cavity and assess the soft and hard palate, uvula, oropharynx, tongue, inside of the upper and lower lip and cheeks. If you see or suspect bruising, hemorrhaging or detect the presence of petechiae on any of these areas, capture additional close-up photos.

Most children are curious to see photographs of their own mouth. If they are, take advantage of this opportunity to have them help you angle their head to enable you to get a better shot inside the oral cavity. To perform an assessment of the back of the upper and lower lip, use the finger of a gloved hand to gently lift up or pull down the lips. You can also get them involved by asking them to help you hold the lip up or down to expose the area of interest. Giving positive reinforcement to the child by saying “good job” will help you put them at ease.



9. Take a close-up photo of both hands separately using the SDFI Hand Map. If you see or suspect bruising, abrasions or other findings, capture additional close-up photos with a measurement scale first, then without a scale. You can have young children put their hands on the parent’s lap or even their own if they are not comfortable putting their hands on a hand map.

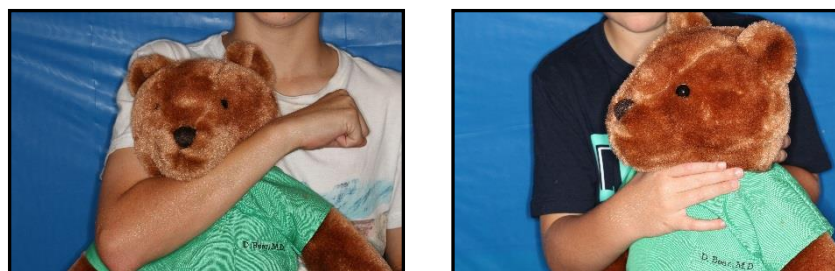


10. The use of a mannequin or Styrofoam head can be effective in understanding the dynamics of the assault. This tool can show the physical positions of how the patient and perpetrator were during the assault. If the child is old enough or has the cognitive ability to do the representational shift, have the child show how the strangulation happened using the toy model or Styrofoam head. Capture mid-distance photos of the demonstration.




The examiner should always be sensitive to how the child may react in using this method and should follow what the child is comfortable doing. The examiner could also use a toy doll to have the child show what happened or even ask the child to draw a representation using a crayon and paper.

A good rapport with the child is important during this part of the examination. Communicating with a calm tone while giving the child specific and easy to understand instructions will help the examiner get better results. Example: *“This is a teddy bear. Can you show me what happened to you?”* In many places, it will be a forensic interviewer (Child Advocacy staff, law enforcement or even a child protection worker) who will be doing the interview rather than the forensic examiner. Take photos of the ligature that might have been used if it is available. Follow your local protocol.



Sometimes children will not have the words to describe the incident but they are able to draw from memory what happened to them.




11. Take a photo of the bookend card, patient's ID wristband or of the printed evidence label which will mark the conclusion of this part of the examination.

SDFI-TeleMedicine SDFI - Secure Digital Forensic Imaging SDFI® Secure Beyond Reasonable Doubt® www.SDFI.com	
<small>INSTRUCTIONS: Do not write, scribble, or mark on this card. Scan the card and send to the forensic analyst via email or text message. SDFI-TeleMedicine is a registered trademark of SDFI-TeleMedicine LLC. © 2017 SDFI-TeleMedicine LLC. All rights reserved.</small>	
Date:	<input type="text"/>
Name:	<input type="text"/>
Case #:	<input type="text"/>
Photographer:	<input type="text"/>
ID Record #:	<input type="text"/>
D.O.B.: (mm/dd/yyyy) <input type="text"/>	or Age: <input type="text"/>



Non-Fatal Manual Strangulation Chart

Trauma Informed Patient Care: Often times the Pediatric patient may have difficulty in showing the position of the perpetrator's hands on their neck during the assault. This chart, also known as the six pack, is another tool that will help the child describe the event by pointing to one of the six positions that closely resemble what happened to them. The positions are numbered 1-6 for ease of documentation by the provider.



Examiner's Notes: _____



References for this Pediatric Strangulation Supplement

Adewele, L. (2009), Anatomy and assessment of the pediatric airway. *Pediatric Anesthesia*, 19(s1), 1–8.
[doi:10.1111/j.1460-9592.2009.03012.x](https://doi.org/10.1111/j.1460-9592.2009.03012.x)

D Davies, M Lang, R Watts. Pediatric hanging and strangulation injuries: A 10-year retrospective description of clinical factors and outcomes. *Pediatric Child Health* 2011;16(10):e78-e81.
Retrieved from: <https://www.ncbi.nlm.nih.gov/pmc/articles/PMC3225483/pdf/pch16e078.pdf>

Harless, J., Ramaiah, R., & Bhananker, S. M. (2014). Pediatric airway management. *International Journal of Critical Illness and Injury Science*, 4(1) 65–70. Retrieved from:
<http://www.ijciis.org/article.asp?issn=2229-5151;year=2014;volume=4;issue=1;page=65;epage=70;aulast=Harless>

Baldwin-Johnson, C. & Wiese, T. (2015). Strangulation in Children. Responding to Strangulation in Alaska: Guidelines for Law Enforcement, Healthcare Providers, Advocates and Prosecutors. San Diego: [Training Institute on Strangulation Prevention](#), 48-57.

Faugno, D. K., Trujillo, A. C., Bachmeier, B. A., & Speck, P. M. (2017). *Manual nonfatal strangulation assessment for healthcare providers and first responders*. Florissant, MO: STM Learning. Available at:
https://www.amazon.com/Nonfatal-Strangulation-Assessment-Forensic-Learning/dp/1936590700/ref=sr_1_1?s=books&ie=UTF8&qid=1500746587&sr=1-1

Faugno, D., Wasnak, D., Strack, G. B., Brooks, M.A., Gwinn, C. (2013). Strangulation forensic examination: Best practice for health care providers. *Advanced Emergency Nursing Journal*, 35(4), 314-327.
[doi:10.1097/TME.0b013e3182aa05d3](https://doi.org/10.1097/TME.0b013e3182aa05d3)

International Association of Forensic Nurses (2016). Non-Fatal Strangulation Documentation. Tool Kit. Retrieved from:
http://c.ymcdn.com/sites/www.forensicnurses.org/resource/resmgr/resources/Strangulation_Documentation_.pdf

International Association of Forensic Nurses (2016). The Evaluation and Treatment of Non-Fatal Strangulation in the Health Care Setting. Retrieved from:
http://c.ymcdn.com/sites/www.forensicnurses.org/resource/resmgr/education/Strangulation_Position_Paper.pdf

Jain, V., Ray, M., Singhi, S. (2001). Strangulation injury: A fatal form of child abuse. *The Indian Journal of Pediatrics*, 68(6), 571-572. doi:[10.1007/BF02723257](https://doi.org/10.1007/BF02723257)

Plattner, T., Bolliger, S., & Zollinger, U. (2005). Forensic assessment of survived strangulation. *Forensic Science International*, 153(2), 202–207. doi: [10.1016/j.forsciint.2004.09.106](https://doi.org/10.1016/j.forsciint.2004.09.106)

Sabo, R.A., Hanigan, W.C., Flessner, K., Rose, J., Aaland, M., (1996). Strangulation injuries in Children, Part 1: A clinical analysis. *Journal of Trauma and Acute Care Surgery*, 40(1), 68-72.

Sabo, R.A., Hanigan, W.C., Flessner, K., Rose, J., Aaland, M. (1996). Strangulation injuries in Children, Part 2: Cerebrovascular hemodynamics. *Journal of Trauma and Acute Care Surgery*, 40(1), 73-77.

Sep, D., & Thies, K. (2007). Strangulation injuries in children. *Resuscitation*, 74(2), 386–391.
Retrieved from: <https://www.ahcmmedia.com/articles/19950-strangulation-injuries>



SDFI

Secure Digital
Forensic Imaging

Secure Beyond Reasonable Doubt®

Special thanks to the following individuals for their involvement with this project:

Diana Faugno – MSN, RN, CPN, SANE-A, SANE-P, FAAFS, DF-IAFN
Forensic Nurse Examiner
Barbara Sinatra Children’s Center

Denise Rodriguez Bowman - MSW
Child Forensic Interview Specialist
Riverside County Child Assessment Team
Riverside County Child Protective Services

Valerie Sievers – MSN, RN, CNS, SANE-A, SANE-P
Forensic Clinical Nurse Specialist, Forensic Nurse Examiner
Safe Passage – Child Advocacy Center

Trinity Ingram-Jones - DNP, CPNP, PCNS, AFN-BC, SANE-A, SANE-P
Ingram-Jones & Associates, LLC
Medical-Forensic Examiner and Consultant to
Helen's Haven Children's Advocacy Center

Cathy Baldwin-Johnson - MD FAAFP
Medical Director
Alaska CARES, Anchorage, Alaska
The Children’s Place, Wasilla, Alaska

Brijida Rodarte - Deputy District Attorney
Sexual Assault & Child Abuse Team
Riverside County District Attorney’s Office

Bill Smock - MD, Police Surgeon
Louisville Metro Police Department
Medical Director – The Institute of Clinical Forensic Medicine and Nursing



SDFI | Secure Digital
Forensic Imaging

Secure Beyond Reasonable Doubt®

SDFI Pediatric Non-Fatal Strangulation PhotoDocumentation Protocol 2018



FI®-TeleMedicine LLC
806 Buchanan Blvd. STE 115-299
Boulder City, NV 89005
Phone: 310-492-5372
Support@SDFI.com
www.SDFI.com
See Our Web Page For Office Hours

Copyright © - 2017 - 2018

Pediatric Non-Fatal Strangulation PhotoDocumentation Protocol
SDFI-TeleMedicine LLC, 806 Buchanan Blvd, STE 115-299, Boulder City, NV, 89005
Support@SDFI.com • 310-492-5372 • www.SDFI.com