



# The Smoking Gun

**Pioneering alien implant researcher and surgeon, Dr. Roger Leir shares his biggest cases and never-before-seen photos of his work**

**S**tarting research in the field of UFO's, Alien Abductions and Implants was a leap of consciousness for me as my educational background was in academic science. I had no trouble conceiving the possibility of intelligent life, even more advanced than our own. It was simple for me to gaze at the stars on a clear night and realize that each star was an actual sun.

This followed by the reasoning, suns must have planets that revolved around them as we do in our own solar system. If this was so, then why was it not possible for those other worlds to be inhabited with life similar or even dissimilar to the life on our planet? What's more, I had to consider other forms of life could be much older and if they had survived longer, then were also possibly

advanced in intelligence. Our written and recorded history provides us with a record of how long mankind has seen craft of unknown origins flying through our skies. Perhaps our ancient record was the key to probing the UFO Phenomena. Over many centuries a very careful campaign of organized deceit enveloped our world, telling us those who saw things flying in our skies or who claimed contact with non-terrestrial beings were deceived, first by the Gods of the ancient literature and modified through the centuries by clever and skilled deceivers of the truth, into a modern campaign which dismissed all sightings and individual experiences as illusions by nut cases who should be receiving psychiatric treatment.

Over and over the paid skeptics

and debunkers asked, "Where is the Smoking Gun?" "Where is your physical evidence?" When their questions were answered by physical trace cases from landed craft, portions of metallic objects taken from crash sites, millions of civilian and eyewitness testimonies, close encounters of the third and fourth kinds and other forms of scientific evidence, the debunking community paid little heed or simply responded with silly remarks whose concepts were biased and bordered on the ridiculous.

The problem is even more complicated with the fact that most populations still pray to higher masters. They are obligated by society to feed their families and be responsible members of some sociological order. This included academic science itself. It is only a handful of

academic scientists, some retired and some from military employment who were brave enough to come forth and tell the truth. My hat is off to all these individuals who include astronauts such as Dr. Edgar Mitchell, Gordon Cooper and others who have stepped up to the plate and made statements that were so profound, it should have impacted the world.

I began my research numerous decades ago, but did not leap into the field with ultimate serious motives until about twenty years ago. To date our research team through our non profit, 501(c)3 research organization, A&S Research has performed 17 surgeries for removal of objects from alleged alien abductees suspected of being alien implants.

The implants have undergone rigorous examinations by both biological and metallurgical scientists associated with some of the world's most prestigious laboratories such as Los Alamos National Labs, New Mexico Tech, University of Toronto, York University, Southwest Laboratories, Seal Laboratories and numerous others with the same validation. The discoveries have been both earth shattering and prove beyond the shadow of a doubt that these objects are non-terrestrial in origin and have been placed in humans all over the world by advanced species for reasons we still do not understand.

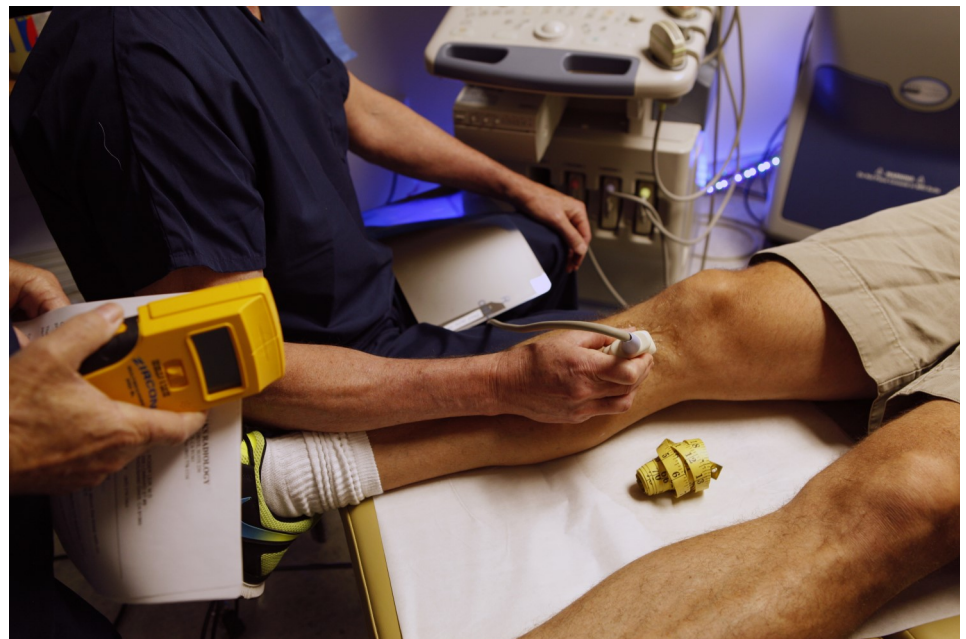#### Some of the findings:

1. No inflammatory or rejection reaction by the body to these foreign objects.
2. No visible portal of entry.
3. Collections of specialized nerve endings surrounding the ob-

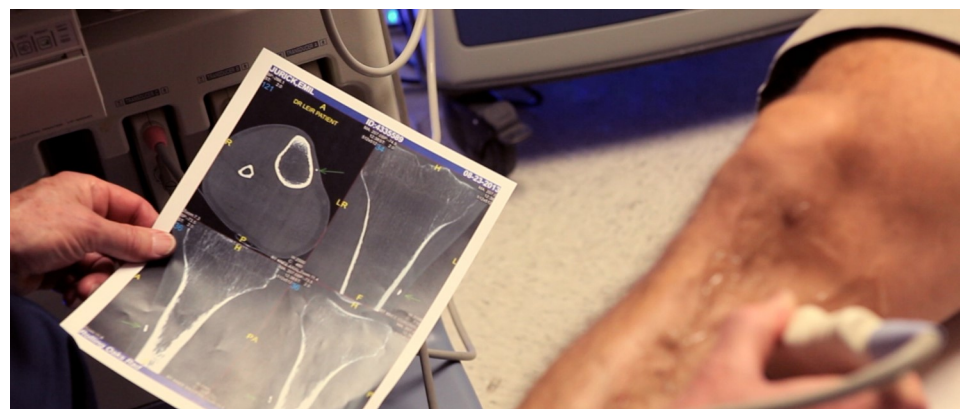
ject.

4. An outer coating of ceramic-biological material.
5. A metallic phase where inorganic metal becomes biological tissue.
6. The emission of radio waves which are deep space frequencies in the FM band.
7. Electromagnetic fields in excess of ten milligauss.
8. Composition of Meteoric Iron.
9. Rare Earth Metals such U-236, a single isotope of Uranium existing by itself, as well as elements such as Iridium which is very rare and hard to find in the earth's crust..

10. Non-terrestrial isotopic ratios indicating the involved elements did not come from this earth.
11. The existence of Carbon Nano Tubes, Carbon Nano Strands and Carbon Nano Fibers. (These entities were considered non existent in nature and many scientists made definitive statements they could not be made in a laboratory. This has now been reversed as commercial products are being designed and made from this technology. Carbon Nano structures are now the strongest substance known to mankind. The oldest of these was in a specimens taken from one our surgical patients, which had been in



Ultrasound being used for visualization of implant. Photo: A&S Research



Review of CAT scan showing object near bone. Photo: A&S Research

*The Smoking Gun continued...*

their body for over 46 years, which was old enough to eliminate back engineering from UFO Crash Sites such as Roswell.)

12. Gold Spheres which have yet unknown function.

13. Metallic caverns that are no larger than the diameter of one atom.

14. Resistance to ordinary cutting techniques such as metallic sawing, or severing with a cutting instrument. (One of our specimens had to be cut with a Laser.)

15. There are also a number of unknown structures seen with the electron microscope which we do not understand.

There is an abundance of Sodium Chloride Orthorhombic crystals of varying sizes. This is the same material as common ordinary table salt, but the crystals of table salt have no regular shape. Crystals were used for many years in the electronic systems of radio to get multiple frequencies or radio stations. The original radio was re-

ferred to as a Crystal Set which required only the simplest of materials to construct.

Eighteen separate and distinctive objects have been removed from individuals who allege alien abduction. Only one of these objects was of an earthly origin which was a piece of crystal-like glass produced in low numbers by Dow Corning Glass Company. All the others showed multiple qualities of non-terrestrial origin. The last three cases, surgeries 15, 16 and 17 were by far the most interesting cases from a scientific point of view. This, because the scientific equipment had advanced to the point where more could be learned about the non-terrestrial aspects. When I first started this research, the equipment was so primitive, we were not able to do the advance studies we have now been doing routinely.

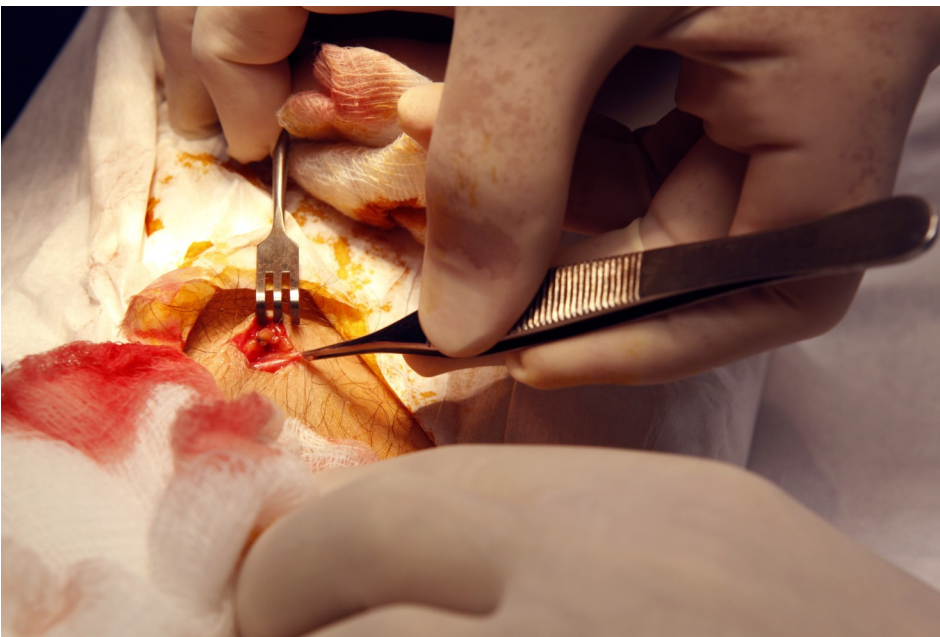Also an important factor is what earthly science knows about our solar system and the universe. With the advent of the Hubble and other Satellite Telescopes op-

erating in the ultraviolet and infrared light spectrum, our scientists now have advanced knowledge which can be applied to research on earthly grounds. Who would ever think that we would discover planets, orbiting other suns in large numbers and in the so called "Goldilocks Zone." Even a simple thing like water was once thought to be confined to our earthly environment alone. Now we know that the presence of water is probably universal.

In a brief discussion of the three last cases, I shall enumerate the highlights.

**Case number 15** involved a male patient who was married with several young children and a resident of Southern California. He had a long history of abductions and they involved both his wife and family. One morning he awoke with pain in a toe and several small dots of blood on the bed sheet. This had occurred during the night and he made an appointment the following day with me in my office, as an ordinary foot patient. He withheld the fact that he was an abductee. He finally related to me the story about his last nights incident and confessed he had seen me on television. After examination I became suspicious that he did have a foreign body in his toe and suggested an x-ray.

At the time there were no wounds or signs of blood. The x-rays proved positive for a metallic foreign body and because of his pain, it was recommended that it be removed. On his follow up visit he told me about his many abduction experiences and why he chose me as his specialist. The patient was given a copy of our extensive



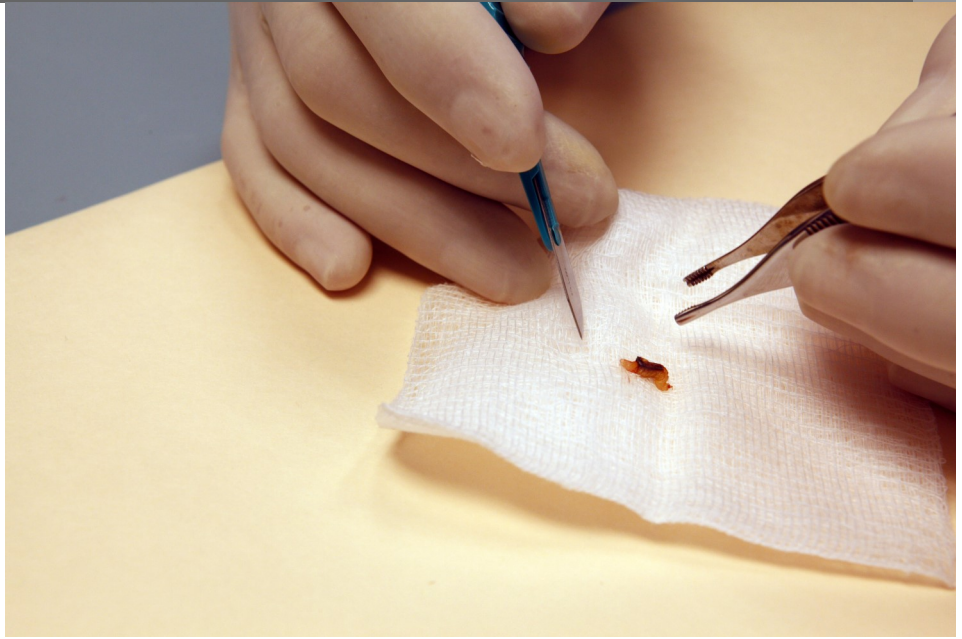Object being surgically removed. Photo: A&S Research

questionnaire and was told to fill it out and return them to me. Following that his surgery was scheduled.

**The following is a partial list of unusual events associated with his surgery:**

1. All of our surgeries are performed with the use of an X-ray device called a C Arm. This allows the surgeon to see the object on two television screens and we can visualize the instruments we are using to remove it while they are inside the body. This was the first object that broke into several smaller pieces during the process of removal. Each piece was placed on surgical gauze and then transferred into the container filled with the patients own blood serum. We had removed all the pieces except for one final piece. When we revisited the TV screens we noticed the final segment that was left was gone. After an adequate time of searching for it we simply gave up because it was not there and had simply vanished.

2. After three days went by, I re-examined the container holding the individual segments of the object and noticed they were all lined up in a straight line on the bottom of the container. I re-sealed the container and shook them up, placed the container on a table and waited about 15 minutes. Re-examination was shocking as they had again re-assembled themselves in the order they were in the x-ray. I called our camera operator. He came and we filmed this several times. We have no explanation for this metallic behavior and can only conclude that the alloys were some kind of memory metal.



Object on a sterile surgical sponge. Darker portion is metal. Photo: A&S Research

**Case number sixteen** was a gentleman who lived in Tennessee. He had an object in his thigh. His memory was that of an abduction experience when he was about 9 years of age. It involved two of his closest friends who were about the same age.

They were on an overnight camping trip which was only a few blocks from where he lived. The boys had a wagon, blankets for construction of a tent, the makings for a fire, and food like marshmallows to toast. The weather was perfect with a clear sky and unlimited visibility. They applied their skills to a makeshift tent construction and set their sleeping bags so their heads were outside of the tent enabling them to see a clear view of the sky. They had a great deal of fun with the barbeque and the marshmallow toasting. The shroud of sleepiness finally set in and they crawled into their sleeping bags and stared up at the wondrous site of the majestic heavens. Suddenly one of the boys shouted to the others, "What is that?"

It was a very bright star which

seemed to be getting brighter and brighter and coming closer and closer. The boys were now fully awake. Suddenly the star became a circular craft and hovered right over them. They had no fear whatsoever as this was part of a great adventure. A multitude of colored lights circled the outside rim of the craft.

The next thing that happened was a cone of bright bluish white light which shot down from the bottom of the craft — and they began to levitate upward. They showed no fear and were having fun, stating they now had the ability to fly. Ascending upward they passed through an opening in the bottom of the craft and found themselves in a large circular room.

Their hosts were described as the typical petite, black eyed Gray Beings with large wrap around eyes, small in stature with large heads and communicated without the use of the mouth directly into the heads of the boys. Our surgical victim was told not to be afraid and his only concern was that of

*Smoking Gun continued...*

his mates.

He was told they would be separated for only a short while but would soon be back together and no harm would come to them. Each one was then escorted down a different circular corridor. Under hypnosis our surgical candidate described rooms on either side of this long corridor and stated they looked like hospital rooms. Under hypnosis he remembered them putting something into his thigh but there was no pain.

After this they were all three reunited in the same large room and beamed back to the campsite. They all noticed the sun was beginning to rise and that they had been gone most of that night. Then something very strange occurred. All three boys found a fresh vegetable garden and furiously tore the vegetables out of the ground and ate them.

**Case number 17** was a gentleman in his forties who is a resident of Southern California. He has conscious memory of one experience when he was young with bluish-white light and gray beings in his bedroom. He has very few other memories and has not undergone any hypnotherapy for memory en-

hancement, but scored very high on our battery of questions pertaining to his possibility of being an Alien Abductee.

He recently underwent a surgical procedure for removal of a metallic object from his calf area. It was typical in all forms, positive MGauss readings and radio wave emissions. It was a metallic rod about 8mm in length and about as big around as a pencil lead. This fits the general description of about eight of the other objects

“This author and researcher would like to clearly state, with the all the research results of true academic scientists that have the so called ‘Smoking Gun.’”

removed. There was no scar or portal of entry. The object clearly showed on x-ray and Cat Scan as well as an Ultrasonogram. The surgery went well and the patient is recovering satisfactorily post operatively.

The only testing performed so far was under the optical microscope which showed the object had a heavy exterior biological coating


that cracked like the shell of a nut exposing the metal inside. An SEM and EDX was performed and it was noted that the coating showed biological material, however there was a lack of biological factors indicative of human origin. The major portion of the metal was meteoric iron. There were also numerous heavy bundles of carbon nanotubes, nanofibers and nanostrands. Further testing is forthcoming.

This author and researcher would like to clearly state, with the all the research results of true academic science that we have the so called “Smoking Gun”. This was evidenced at the Citizens Hearing in Washington DC this passed May. In my testimony before a respected Congressional Committee I discussed in detail some of the factors expressed in this article. Additionally I submitted a copy of the “OSTP Report”, given to President Obama by this organization in the White House last year when he was attempting to raise money for his health care legislation.

###

The author’s new book will soon be available to the public. Its title is **“UFO’S DON’T EXIST” (THE GREATEST LIE THAT ENVELOPED THE WORLD)**. The Foreword for the book was written by Astronaut Dr. Edgar Mitchell. Watch for it soon at your local book store, Amazon.com or my website, **Alienscalpel.com**

*Dr. Leir is a Podiatric Surgeon, who has been in private practice in Ventura County, California for the past 43 years. Dr. Leir anticipates performing more surgeries in the future and is investigating the physiological and biological aspects of the alien abduction phenomenon.*



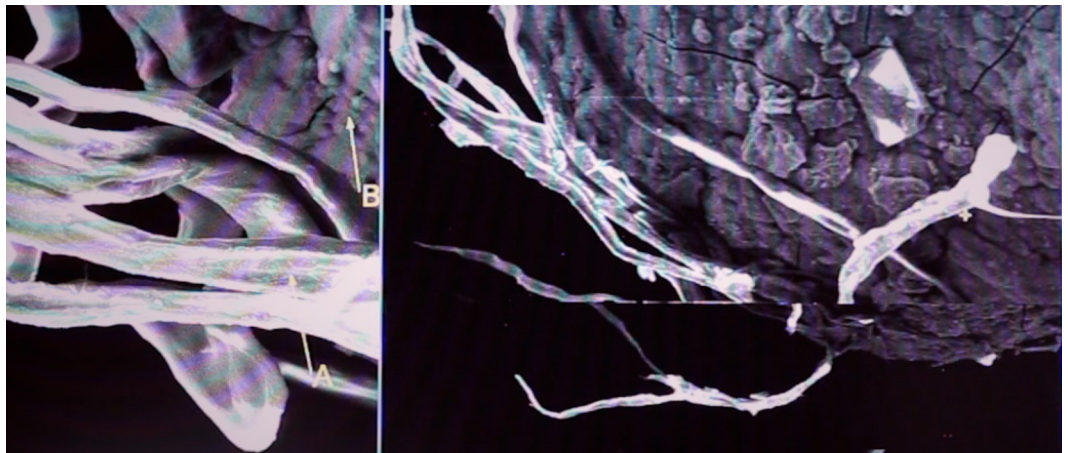
Inside vacuum of electron microscope prior to insertion of implant



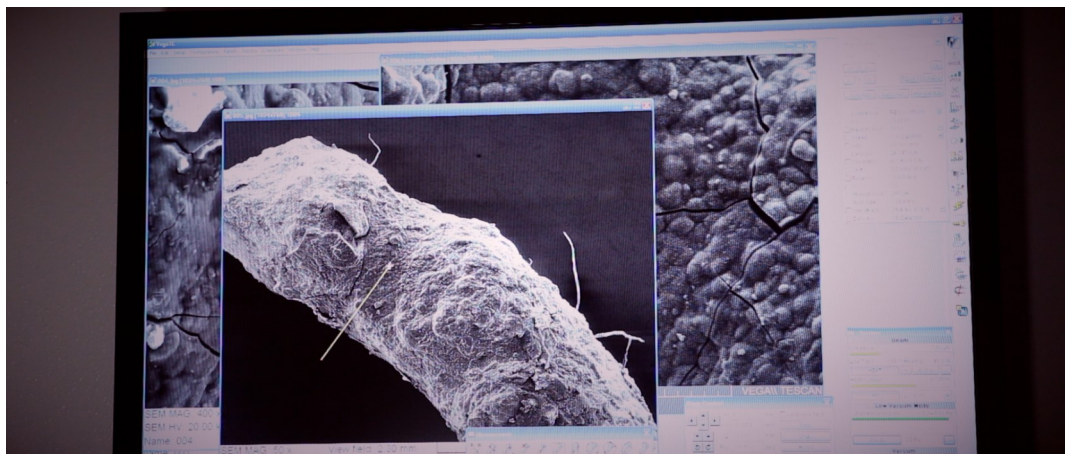Above right: Scientist mounts a portion of the implant for insertion into the electron microscope.



Right: Use of a Gauss meter to measure electromagnetic fields.



Object being examined with Electron Microscope showing Carbon Nano-bundles.



View using Electron Microscope with less magnification showing Carbon Nano Fibers.

All photos with this article are copyrighted by A&S Research