



EMERGING INFECTIOUS DISEASES[®]

February 2011

Influenza

Vol 17, No 2, February 2011



U.S. DEPARTMENT OF
HEALTH AND HUMAN SERVICES
CENTERS FOR DISEASE CONTROL
AND PREVENTION

EMERGING INFECTIOUS DISEASES

February 2011

ISSN 1082-9752
CODEN EIDED
PSYCHOLOGY & SCIENCE
PUBLISHED BY
WILEY-Blackwell
Number 2, 2011



References

1. Renault P, Solet JL, Sissoko D, Balleydier E, Larrieu S, Filleul L, et al. A major epidemic of chikungunya virus infection on Reunion Island, France, 2005–2006. *Am J Trop Med Hyg.* 2007;77:727–31.
2. Sergon K, Yahaya AA, Brown J, Bedja SA, Mlindasse M, Agata N, et al. Sero-prevalence of chikungunya virus infection on Grande Comore Island, Union of the Comoros, 2005. *Am J Trop Med Hyg.* 2007;76:1189–93.
3. Beesoon S, Funkhouser E, Kotea N, Spielman A, Robich RM. Chikungunya fever, Mauritius, 2006. *Emerg Infect Dis.* 2008;14:337–8. DOI: 10.3201/eid1402.071024
4. Ratsitorahina M, Harisoa J, Ratovonjato J, Biacabe S, Reynes JM, Zeller H, et al. Outbreak of dengue and chikungunya fevers, Toamasina, Madagascar, 2006. *Emerg Infect Dis.* 2008;14:1135–7. DOI: 10.3201/eid1407.071521
5. Gerardin P, Guernier V, Perrau J, Fianu A, Le RK, Grivard P, et al. Estimating chikungunya prevalence in La Reunion Island outbreak by serosurveys: two methods for two critical times of the epidemic. *BMC Infect Dis.* 2008;8:99. DOI: 10.1186/1471-2334-8-99
6. Kariuki NM, Nderitu L, Ledermann JP, Ndirangu A, Logue CH, Kelly CH, et al. Tracking epidemic chikungunya virus into the Indian Ocean from East Africa. *J Gen Virol.* 2008;89:2754–60. DOI: 10.1099/vir.0.2008/005413-0
7. Schuffenecker I, Iteanu I, Michault A, Murri S, Frangeul L, Vaney MC, et al. Genome microevolution of chikungunya viruses causing the Indian Ocean outbreak. *PLoS Med.* 2006;3:e263. DOI: 10.1371/journal.pmed.0030263
8. D’Ortenzio E, Grandadam M, Balleydier E, Dehecq JS, Jaffar-Bandjee MC, Michault A, et al. Sporadic cases of chikungunya, Reunion Island, August 2009. *Euro Surveill.* 2009;14.
9. ProMED-mail. 2009 June 11 [cited 2010 Jun 7]. http://www.promedmail.org/pls/apex/f?p=2400:1202:1420708405369099:NO:F2400_P1202_CHECK_DISPLAY,F2400_P1202_PUB_MAIL_ID:X,77916
10. Delatte H, Paupy C, Dehecq JS, Thiria J, Failloux AB, Fontenille D. *Aedes albopictus*, vector of chikungunya and dengue viruses in Reunion Island: biology and control [in French]. *Parasite.* 2008;15:3–13.

Address for correspondence: Eric D’Ortenzio, Epidemiology Unit—Institut Pasteur de Nouvelle-Calédonie, 9-11 Avenue Paul Doumer—BP 61 98845 Noumea, New Caledonia; email: edortenzio@pasteur.nc

Segniliparus rugosus–associated Bronchiolitis in California Sea Lion

To the Editor: Until now, *Segniliparus rugosus* has not been isolated from nonhuman animals or the environment (1). On April 14, 2010, a rescue team from Pacific Marine Mammal Center impounded an emaciated and unresponsive subadult female California sea lion (*Zalophus californicus*) stranded on the beach at San Onofre, California, USA. Physical examination showed the animal to be obtunded and emaciated (third-stage malnutrition), with moderate bradycardia, hypoventilation, and hypothermia. Euthanasia was elected because of a poor prognosis. Immediately before euthanasia, a blood sample was taken for a complete blood count and serum chemistry evaluation. A postmortem examination was conducted immediately after euthanasia.

The postmortem examination showed marked subcutaneous and visceral adipose tissue depletion, as well as moderate skeletal muscle loss, especially in the axial skeleton. In the lungs, a frothy, greenish, mucoid material exuded from several dozen bronchioles. Samples of the exudate were submitted for cytologic examination and bacterial culturing (IDEXX Laboratories, Irvine, CA, USA). Selected tissues were sampled and fixed in 10% neutral buffered formalin for histopathologic examination.

Complete blood count and serum chemistry analysis showed moderate anemia; relative neutrophilia and monocytosis; mild to moderate relative lymphopenia; moderate to markedly reduced albumin, globulin, and total protein levels; and elevated creatine kinase and alkaline phosphatase levels. Such values are common in California sea lions with severe malnutrition (starvation).

Cytologic examination of the bronchiolar exudate indicated large amounts of mucin with erythrocytes; occasional epithelial cells; and small to moderate numbers of eosinophils, neutrophils, monocytes, and lymphoid cells, characteristic of a mild to moderate, subacute, mixed bronchiolitis. Histologic examinations of 3 sections of lung showed 33 bronchioalveolar foci containing varying numbers of adult *Parafilaroides decorus* nematodes, without associated inflammation. Eleven other foci showed moderate to marked chronic inflammation, with nematodes in only 2 foci. Gram stain did not show bacteria in any of these foci. Lesions were not found in sections of liver, kidney, bladder, spleen, and heart.

A commercial veterinary laboratory (IDEXX Laboratories) isolated an acid-fast organism from the lung swab. This organism was referred to National Jewish Medical and Research Center (Denver, CO, USA) for species identification and sensitivity analysis. By 16S rDNA sequencing, the organism was identified as *S. rugosus*. Sensitivity testing showed that it was susceptible to rifabutin, cycloserine, clofazimine, moxifloxacin, ciprofloxacin, and clarithromycin and resistant to rifampin, streptomycin, amikacin, kanamycin, capreomycin, ethambutol, and ethionamide.

As in humans, this isolation of *S. rugosus* was associated with pathologic changes in the respiratory tract. Whether the relationship was causal or simply a fortuitous isolation of a previously unrecognized part of the normal respiratory flora is uncertain. However, a recent report by Sikorski et al. stated that “Environmental screens and metagenomic surveys did not detect a single phylotype... of the members of the genus *Segniliparus*” (2). In contrast, this case report begs the question of whether *S. rugosus* could be free-living in the oceans or part of the flora of any number of ocean-dwelling vertebrates or invertebrates.

Richard H. Evans

Author affiliation: Pacific Marine Mammal Center, Laguna Beach, California, USA

DOI: 10.3201/eid1702.101511

References

1. Butler W, Floyd M, Brown J, Toney S, Daneshvar M, Cooksey R, et al. Novel mycolic acid-containing bacteria in the family *Segniliparaceae* fam. nov., including the genus *Segniliparus* gen. nov., with descriptions of *Segniliparus rotundus* sp. nov. and *Segniliparus rugosus* sp. nov. *Int J Syst Evol Microbiol.* 2005;55:1615–24. DOI: 10.1099/ijs.0.63465-0
2. Sikorski J, Lapidus A, Copeland A, Misra M, Glavina Del Rio T, Nolan M, et al. Complete genome sequence of *Segniliparus rotundus* type strain (CDC 1076T). *Stand Genomic Sci.* 2010;2:203–11. DOI: 10.4056/sigs.791633

Address for correspondence: Richard H. Evans, Pacific Marine Mammal Center, 20612 Laguna Canyon Rd, Laguna Beach, CA 92651, USA; email: revans@pacifcmmc.org

Orbiviruses in Rusa Deer, Mauritius, 2007

To the Editor: Bluetongue and epizootic hemorrhagic disease are caused by orbiviruses transmitted by *Culicoides* spp. biting midges (Diptera: Ceratopogonidae). These diseases are restricted to regions where their vectors exist (1) and seem to be expanding to previously unaffected areas (2). Infection of wild and domestic ruminants is common. Bluetongue virus (BTV) causes severe clinical disease in certain breeds of sheep; BTV and epizootic hemorrhagic disease virus (EHDV) cause clinical disease in some species of deer (3,4).

Rusa deer (*Cervus timorensis rusa*), originally from Indonesia, are found in diverse countries in the

Pacific region (Papua New Guinea, New Caledonia, New Zealand, and Australia). Introduced to the island of Mauritius in 1639, they are commonly raised in high numbers ($\approx 60,000$) for meat production (5). Mauritius is considered free from major livestock diseases; its animal health surveillance is based mainly on clinical monitoring and inspection of carcasses at slaughter. To our knowledge, circulation of orbiviruses in Rusa deer has not been reported in detail in any country where this deer is present.

Our study was an initial screening survey of the deer population on the island. A total of 369 deer, representing 28 private farms, were chosen from a list of 42,959 deer. Blood was collected at slaughter, and serum samples were sent to Onderstepoort Veterinary Institute, South Africa, to be tested for antibodies against orbiviruses with a homemade indirect ELISA. To distinguish between BTV and EHDV,

samples positive by indirect ELISA were tested for BTV antibodies with the competitive ELISA produced by the Institute for Animal Health (Pirbright, UK). Of the samples positive by competitive ELISA, 3 were tested by serum neutralization against the 24 BTV serotypes (cutoff value >16).

Simultaneously, *Culicoides* spp. midges were trapped in Onderstepoort-type blacklight traps at 3 deer farms in coastal areas (Figure). Trapping was conducted 1 night at each farm, during optimal weather conditions. Midges were kept at room temperature in 95% ethanol until sent to Strasbourg University, France, for identification.

Of the 369 deer serum samples tested, 15 were positive for BTV and 5 for EHDV; seroprevalence was 4.1% for BTV (95% confidence interval 2.0%–6.1%) and 1.3% for EHDV (95% confidence interval 2.0%–6.1%). No significant differences were observed for sex ($\chi^2 = 0.05$,

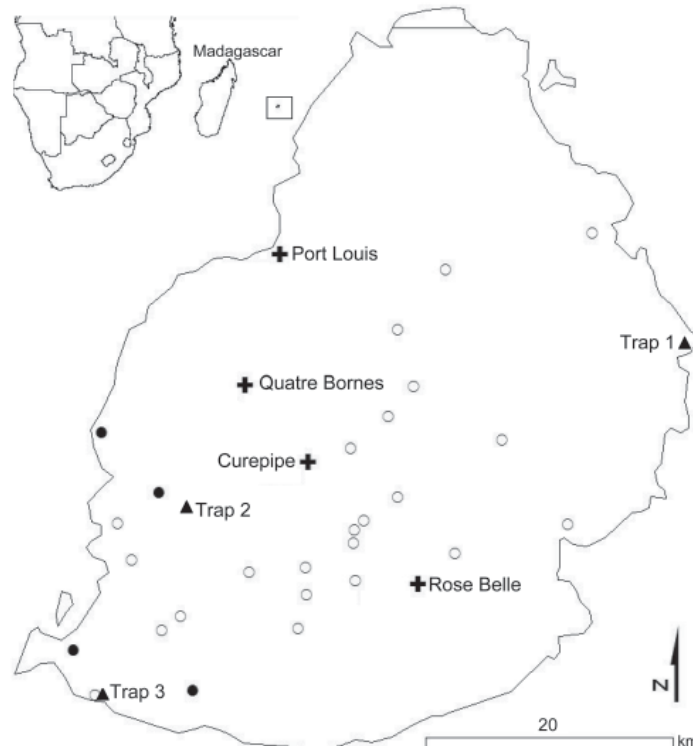


Figure. Location of farms where Rusa deer were sampled (open circles), herds with orbivirus-seropositive deer (closed circles), biting midge collection sites (triangles), and main cities (crosses) in Mauritius. Most (99%) *Culicoides* spp. midges were trapped at sites 1 and 3. Inset show location of Mauritius (in square) in relation to Africa and Madagascar.