

Anogenital Injuries in Adolescents after Consensual Sexual Intercourse

Jeffrey S. Jones, MD, Linda Rossman, MSN, Melissa Hartman, MD,
Carmen C. Alexander, RN

Abstract

Objectives: To compare the types and locations of anogenital injuries occurring in adolescent females (13–17 years old) after consensual and nonconsensual sexual intercourse. **Methods:** The authors conducted a retrospective, matched case–control study to assess anogenital injuries in female adolescents presenting to a free-standing nurse examiner clinic during a four-year study period. Adolescents were selected for inclusion in the study if they reported consensual sexual intercourse (CSI) and agreed to a medical–legal examination. Control subjects were victims of alleged sexual assault or nonconsensual sexual intercourse (NCSI) matched to cases by age and prior sexual intercourse experience. Genital trauma was documented using colposcopy with nuclear staining and digital photography. Data were analyzed using chi-square and t-tests. **Results:** Fifty-one cases of CSI were identified; the age range was 13 to 17 years (mean = 15.1 years). Overall, 49% (25/51) of CSI subjects reported no prior sexual intercourse experience. CSI and NCSI were comparable in terms of race, time to

physical examination, alcohol use, and frequency of genital injuries (73% vs. 85%, $p = 0.069$). The mean number of documented anogenital injuries in CSI subjects was 1.9 ± 1.5 . These injuries commonly involved the hymen, fossa navicularis, and posterior fourchette. CSI subjects had a greater number of anogenital injuries (2.6 ± 2.0 ; $p = 0.02$), typically involving the fossa navicularis, labia minora, and hymen. The most common type of injury in both groups was lacerations (39% vs. 41%); however, NCSI subjects had a greater incidence of anogenital abrasions, ecchymosis, and edema ($\chi^2 = 10.4$, $p = 0.035$). **Conclusions:** Anogenital trauma was documented in 73% of adolescent females after consensual sexual intercourse versus 85% of victims of sexual assault. The localized pattern and severity of anogenital injuries were significantly different when compared with victims of sexual assault. **Key words:** consensual; nonconsensual; sexual assault; diagnosis; anogenital injuries. *ACADEMIC EMERGENCY MEDICINE* 2003; 10: 1378–1383.

The physical examination of sexual assault victims is performed to identify and treat injuries, as well as collect forensic evidence for prosecution.¹ Recent advances in clinical forensic medicine show that trained examiners using colposcopy obtain evidence of anogenital trauma in 71% to 86% of rape victims.^{2–4} Although this is a significant improvement over protocols relying on gross visualization⁵ or toluidine blue dye enhancement,⁶ little has been written comparing anogenital findings in adolescent rape victims with those in females adolescents having consensual intercourse.

Previous studies have shown that the prevalence of anogenital injury in adult women who are victims of rape is greater than that seen in adult women having consensual intercourse.^{7,8} The purpose of this study was to compare the type and location of anogenital injuries occurring in female adolescents after reported consensual sexual intercourse (CSI) and nonconsensual sexual intercourse (NCSI).

METHODS

Study Design. This was a retrospective, matched case–control study to assess anogenital injuries in female adolescents (13–17 years old) presenting after sexual assault to a freestanding nurse examiner clinic. The study protocol was approved by our hospital's institutional review board.

Study Setting and Population. The Nurse Examiner Program (NEP) is a community-based program that provides 24-hour comprehensive response to adolescent and adult victims of sexual assault. It is located in downtown Grand Rapids, Michigan, at the Young Women's Christian Association (YWCA). The NEP is associated with a university-affiliated emergency medicine residency program and works in conjunction with local law enforcement agencies and the

From the Grand Rapids MERC/Michigan State University Program in Emergency Medicine, Spectrum Health Hospital—Butterworth Campus, YWCA Nurse Examiner Program, Grand Rapids, MI. Received December 30, 2002; revision received March 13, 2003; accepted March 17, 2003.

Presented at the ACEP Research Forum, Chicago, IL, October 2001. Supported by a grant from the Blodgett Butterworth Health Care Foundation, Spectrum Health, Grand Rapids, Michigan.

Address for correspondence and reprints: Jeffrey S. Jones, MD, Department of Emergency Medicine, Spectrum Health—Butterworth Campus, 100 Michigan Street Northeast, Grand Rapids, MI 49503-2560. Fax: 616-391-3674; e-mail: jeffjones44@attbi.com. doi:10.1197/S1069-6563(03)00555-4

existing domestic/sexual assault programs of the YWCA. It is staffed by registered nurses who have been trained to perform a medical–legal examination on victims of sexual assault.⁹ Education of the nurse examiner usually consists of approximately 40 hours of training in all aspects of caring for this population, including physical examination, forensic preservation of evidence, documentation, and courtroom testimony. Approximately 120 adolescent sexual assault victims are evaluated at the NEP each year.¹⁰

Female sexual assault victims between the ages of 13 and 17 years were eligible for inclusion in the study if they consented to a forensic examination during the 48-month study period. Cases were selected for inclusion in the study if they reported CSI. For the purposes of this study, we defined CSI as penile–vaginal penetration of an adolescent who was a willing and cooperative participant in the sexual activity. An example of a typical case would be a teenager brought to the NEP by her parents after discovery of CSI with a boyfriend. Control (NCSI) subjects were victims of alleged sexual assault matched to CSI subjects by age and prior sexual intercourse experience. Each CSI subject was matched to four NCSI subjects.¹¹ Girls were excluded if they were victims of multiple assailants, they denied penile–vaginal penetration, documentation was incomplete or missing, or if the history of the assault was vague or unclear (e.g., intoxication).

Study Protocol. Anogenital trauma is typically documented at the NEP using colposcopy with nuclear staining and digital photography. Toluidine blue dye is used in all acute cases to highlight areas of suspected abrasions or superficial lacerations in the genital and perianal areas.^{6–8} Ten anatomic areas are routinely evaluated and photographed for the presence and type of injury: the labia minora, labia majora, posterior fourchette, fossa navicularis, hymen, clitoris, vagina, cervix, perineum, and perianal area. Anoscopy is performed at the examiner's discretion. For the purposes of this study, the type and location of genital injuries were recorded using a standardized classification system.¹² Definitions of findings used by the nurse examiners were those listed in the *Glossary of Terms and the Interpretations of Findings for Child Sexual Abuse Evidentiary Examinations*, published in 1998 by the American Professional Society on the Abuse of Children.¹³

Patient demographic data and injury information were obtained from NEP medical records using appropriate safeguards to protect patient confidentiality. Medical records were reviewed by one research nurse who was trained using a set of "practice" medical records. One of the investigators met frequently with the abstractor to resolve questions. A second investigator performed a blinded critical review of a random sample of 10% of the charts to

determine reliability. The interrater agreement for this sample of charts was excellent (κ -statistic = 0.92). Standardized abstraction forms were used to guide data collection.

Measures. The primary outcome of interest was the frequency of anogenital findings documented in young females after reported and NCSI. A power analysis determined that 40 cases were needed to detect a 20% difference in the proportion of patients with physical findings with a power of 0.8 and an alpha of 0.05. This analysis was based on a previous study showing anogenital injuries in 86% of adolescent sexual assault victims.¹⁰

Data Analysis. Data were entered from NEP records into Microsoft Excel (version 9.0; Microsoft, Redmond, WA). Analyses were performed using True Epistat (version 4.0, Epistat Services Inc., Richardson, TX). Descriptive statistics (mean, standard deviation [SD], confidence intervals) were used to describe the frequency of anogenital injury and location and type of injury. CSI and NCSI were compared based on demographic data (e.g., race, time to physical examination, alcohol use, and frequency of genital injuries). The mean number of documented anogenital injuries for each group was calculated, as were the typical locations and type of injury (abrasion, laceration, erythema, ecchymosis, edema). Discrete variables were analyzed with the use of chi-square tests; t-tests were used for comparisons of two means.

RESULTS

Case files of 523 adolescent NEP patients were reviewed; 51 (10.3%) reported only CSI. The patients age range was 13 to 17 years (mean \pm SD = 15.1 \pm 1.6 years). Overall, 49% (25/51) of CSI subjects reported no prior sexual intercourse experience. Two hundred four NCSI subjects were matched to CSI subjects by age and whether they reported any previous sexual intercourse experience. CSI and NCSI groups were comparable in terms of race, marital status, time to physical examination, and alcohol use (Table 1). Significant demographic differences between the groups included whether the assailant was known to the victim, location of CSI or NCSI, and whether the adolescent had prior CSI within 72 hours of the reported assault.

Both groups of patients had similar time intervals between sexual intercourse (CSI or NCSI) and examination, likelihood of filing a police report, and the type of reported sexual assault. The percentages listed in Table 2 add to more than 100% because more than one type of assault was documented in 25 (49%) of CSI patients and 91 (45%) NCSI patients. Not surprisingly, the NCSI patients had a greater prevalence of nongenital injuries.

TABLE 1. Patient Demographics in Adolescent Girls after Consensual (CSI) and Nonconsensual Sexual Intercourse (NCSI)

Characteristic	CSI (n = 51)	NCSI (n = 204)
Ethnicity (% white)	32 (63%)	150 (74%)
Marital status (% single)	50 (98%)	193 (95%)
Alcohol or drug use <24 hr	18 (35%)	83 (41%)
Assailant known to victim*	51 (100%)	175 (86%)
Previous consensual intercourse <72 hours*	16 (31%)	31 (15%)
Examined <72 hours of assault	46 (90%)	177 (87%)
Time interval to exam, mean (SD)	18.5 ± 7.5 h	20.0 ± 8.3 h
Police report filed	40 (78%)	179 (88%)
Age of assailant, mean (SD)	18.3 ± 3.3	22.6 ± 9.2
Location*		
Victim's home	14 (28%)	56 (27%)
Assailant's home	27 (52%)	67 (33%)
Vehicle	2 (4%)	14 (7%)
Outdoors	2 (4%)	30 (15%)
Other/combination	6 (12%)	37 (18%)

*p < 0.05.

SD = standard deviation.

Anogenital injuries were documented in 73% of CSI patients versus 85% of NCSI patients ($\chi^2 = 3.4$; $p = 0.065$). The mean number \pm SD of documented anogenital injuries in CSI was 1.9 ± 1.5 . These injuries commonly involved the hymen, fossa navicularis, and posterior fourchette. NCSI patients had a greater number of anogenital injuries (2.6 ± 2.0 ; $p = 0.02$), typically involving the fossa navicularis, followed by the labia and hymen. Figure 1 shows the distribution of injuries in the 210 patients (37 CSI and 173 NCSI) with documented anogenital trauma. The injury pattern was statistically different between adolescents having CSI versus NCSI ($\chi^2 = 11.0$; $p = 0.015$).

Six hundred twenty-seven anogenital injuries were documented. Figure 2 shows the predominant types of injury, including abrasions, bruising, tissue edema, erythema, and tears or lacerations. The most common type of injury in both groups was lacerations (39% vs. 41%); however, NCSI patients had a greater incidence of anogenital abrasions, ecchymosis, and edema. These differences in the types of injuries were statistically significant ($\chi^2 = 10.4$; $p = 0.035$). Lacerations were generally seen on the posterior fourchette and fossa, abrasions appeared on the labia minora, and ecchymosis was seen on the cervix and hymen (Figure 3).

Overall, 125 adolescents reported no prior sexual intercourse experience (25 CSI patients and 100 NCSI controls). Ninety-one percent of this subgroup had documented anogenital injuries; the mean number of injuries was 2.7 ± 2.4 . The most common sites of injury were the hymen, fossa navicularis, and labia minora. In comparison, 74% of the adolescents having prior sexual experience had anogenital injuries ($\chi^2 = 12.0$; $p < 0.001$). The mean number of injuries was 2.2 ± 2.0 . Adolescents with prior sexual intercourse

TABLE 2. Clinical Findings

Characteristic	CSI (n = 51)	NCSI (n = 204)
Type of sexual assault		
Vaginal	51 (100%)	204 (100%)
Oral	16 (31%)	47 (23%)
Anal	6 (12%)	27 (13%)
Digital	9 (18%)	49 (24%)
Nongenital trauma*	4 (8%)	78 (38%)
Anogenital trauma	37 (73%)	173 (85%)
Anogenital injuries, mean \pm SD*	1.9 ± 1.5	2.6 ± 2.0
Anogenital injuries, range	0–7	0–8

*p < 0.05.

SD = standard deviation.

experience had a similar distribution of genital injuries as those who reported no prior experience.

DISCUSSION

To the best of our knowledge, this is the first case-control study to evaluate the type and location of anogenital injuries occurring in adolescent girls after CSI and NCSI. Anogenital injuries were documented in 73% of girls after CSI versus 85% of girls who were sexually assaulted (NCSI). Although these prevalence data were not statistically different, the localized pattern, severity, and extent of injuries in rape victims appear to differ from changes after CSI.

Data documenting the incidence of anogenital injuries in voluntarily sexually active girls are scarce. Slaughter and colleagues¹⁴ found in their group of consenting volunteers that injury occurred in 11% compared with injury in 89% of the sexually assaulted patients. The sites of injury were the same as in NCSI, but the number of sites injured per person was less in the volunteers having CSI than in those who were assaulted. However, the majority of consenting volunteers evaluated in this study were adults (69/75), and nuclear staining was not used to enhance the detection of lacerations and abrasions. Norvell et al. conducted a prospective study on 18 volunteers, each of whom was examined after 72 hours of sexual abstinence and again within 6 hours of vaginal intercourse.¹⁵ Using colposcopic magnification and nuclear staining, anogenital injuries were found in 61% of patients after consensual vaginal intercourse. It is important to note that these data apply only to the adult population. Adolescents have a higher incidence of painful voluntary intercourse, partly explained by the spasticity of the pubococcygeus muscle.⁶ The incidence of perineal lacerations in adolescents having voluntary intercourse was 28% and was not statistically significant from the incidence in adolescent rape victims.⁶

The factors or circumstances associated with anogenital injury during CSI can be more readily

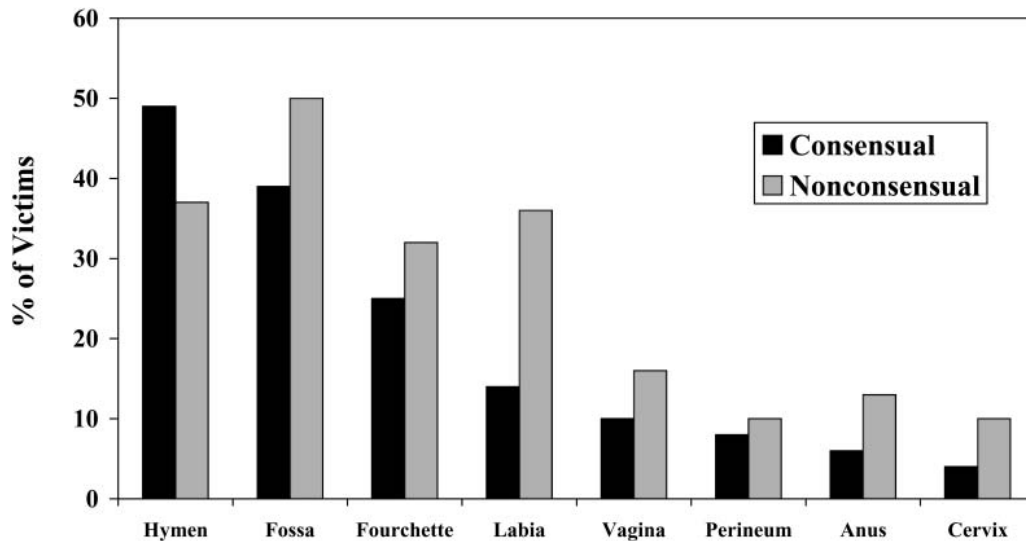


Figure 1. Frequency and location of injury in the 210 patients with anogenital findings.

understood by considering the sexual response cycle originally described by Masters and Johnson.¹⁶ As part of the sexual arousal or excitement phase, the inner two thirds of the vagina (where lacerations and ruptures are more likely to occur) elongates and distends. The internal diameter increases two to three times and lengthens by 10% to 20%.¹⁷ As the vagina becomes lubricated with transudate, the uterus and cervix elevate within the pelvic cavity. Intercourse that occurs without this physiologic preparation of the genitalia is more likely to lead to injury.¹⁸ The following other predisposing factors and causes have also been proposed: first coitus, rough or hurried coitus, intoxication, variant coital positions, anatomical disproportion, mental factors (fear of discovery), postmenstrual state, and clumsiness.¹⁶⁻¹⁹ The problem is most likely multifactorial, with different causes playing a greater role from case to case.¹⁸

Although some investigators have focused on hymenal tears when looking for genital trauma in

adolescent rape victims,¹⁴ the hymen was not the most common site of injury in adolescents reporting NCSI. This study, as well as other studies in adult women reporting penile penetration, confirm the equal vulnerability of the fossa navicularis, labia minora, and posterior fourchette.^{14,20,21} The injuries showed consistent topologic features, varying with the site and nature of tissue. Lacerations appeared most often on the posterior fourchette and fossa, abrasions appeared on the labia minora, and ecchymosis was seen on the cervix and hymen. This pattern provides evidence that the major cause of genital trauma seen in rape victims occurs as an entry injury, with insertion or attempts at insertion of the penis into the vagina.¹⁴ The relative fixation of the posterior portion of the introitus (including the lower part of the hymen and the posterior fourchette) to the perineal body, with its multiple muscular attachments, may account for a focusing of stresses and consequent tears in this region.¹⁹

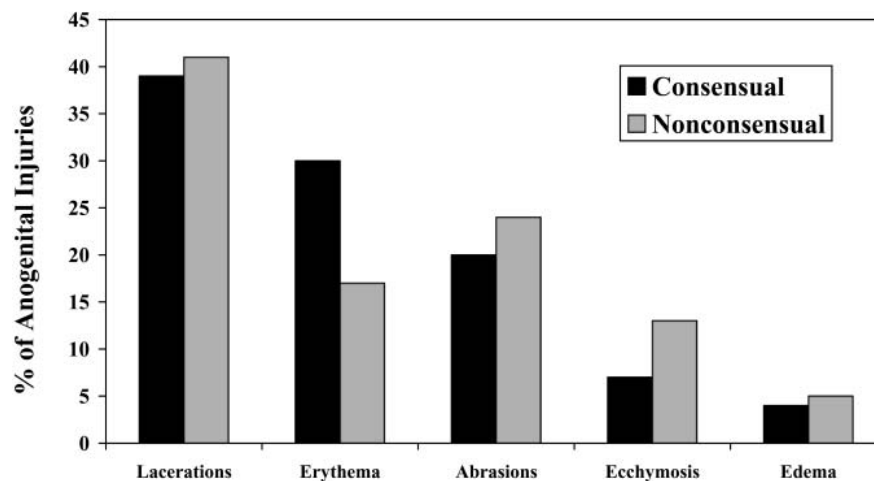


Figure 2. Types of genital trauma documented after consensual (case subjects) and nonconsensual (control subjects) intercourse.

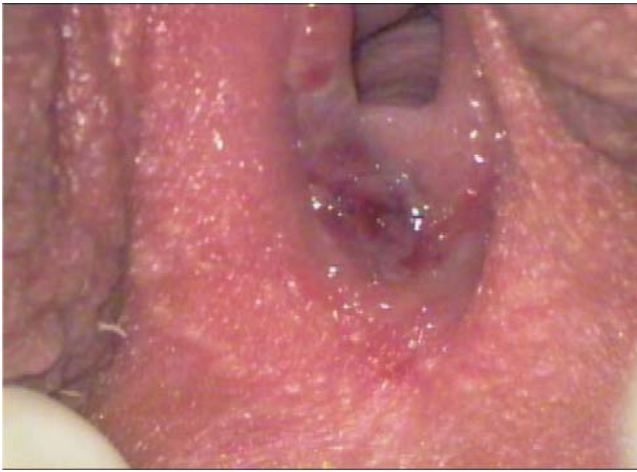

Figure 3. Contusion to hymen after consensual intercourse.

Lower vaginal injuries were more common in self-described virgins evaluated after CSI or NCSI. Hymenal trauma is a frequent part of first intercourse. Hymenal injuries (which include tears, abrasions, ecchymosis, edema, and erythema) tend to be posterior (63% being between the 5 o'clock and 7 o'clock positions) and to cause only minor bleeding and pain.²² More violent coitus, such as that seen during rape, may produce extension of hymenal lacerations into the vaginal walls or the perineal body and rectum, which can sometimes be accompanied by significant hemorrhage.¹⁹

Erythema was the only type of anogenital trauma that was more prominent in adolescents reporting CSI (Figure 2). Several investigators have suggested that "redness", which is a very subjective observation, should not be assumed to be due to trauma in patients who report sexual assault.^{14,15,21} In a small study of 18 adult women seen within 6 hours after CSI,¹⁵ the most consistent physical finding was widespread hypervascularity (50%). In a retrospective study of adolescent sexual assault, Adams and colleagues²¹ found that the degree of localized erythema was not higher in patients examined within 24 hours compared with those examined at 48 to 72 hours. They concluded that hypervascularity might result from sexual contact in some adolescents. In others, hypervascularity alone may be a normal variant and in the same posterior locations as that seen with NCSI. Although it is often difficult for adolescent sexual assault victims to return for follow-up examinations, a study in which the genital examination is repeated 24 and 48 hours after the initial evaluation would help answer questions as to the causes and significance of the findings described.

The age at which an adolescent may consent to sexual intercourse varies by state and ranges from 14 to 18 years of age. The consent of an adolescent younger than this specified age is legally irrelevant because she is defined as being incapable of consenting. All 50 states and the District of Columbia have laws criminalizing statutory rape. Such laws typically base

the severity of the crime on the age of the adolescent victim, the age difference between the adolescent and her assailant, and the relationship between the adolescent and assailant (e.g., incest, authority figure) at the time of the assault.²³ Consequently, 78% of adolescents consenting to sexual intercourse in this study filed a police report. Because of the retrospective nature of the study, we could not followup on patients to determine the final legal outcome.

LIMITATIONS

Several limitations are noted in this study, including the small number of CSI subjects with anogenital injuries ($n = 37$) and the use of a single urban clinic setting. We could not control for the clinical evaluations by different examiners. It may be that documentation was not uniform, although the nine nurse examiners had a similar level of training and experience. The findings of the examiners were recorded on state-mandated reporting forms and were taken as the most accurate representation of the actual physical findings.

Forty percent of all patients had been exposed to alcohol or other drugs during the time of assault. The history of CSI versus NCSI may be suspect in some of these cases. However, the documented history of the sexual assault by forensic nurses is quite detailed and considered accurate by legal authorities. In addition, girls were excluded if the history of the assault was inconsistent because of intoxication or psychosocial issues.

Because of the retrospective nature of this study, specific information concerning previous sexual activity was limited. CSI and NCSI subjects were matched by age and whether they reported any prior sexual intercourse experience. We were unable to quantify in adolescents how extensive this experience was. In addition, 15% of the NCSI group had had consensual intercourse within 72 hours of the reported assault. It is possible that anogenital injuries attributed to the sexual assault were actually secondary to prior consensual intercourse.

Many variables (e.g., hormonal status, lubrication, position, and assailant characteristics) are not fully understood in how they might influence physical trauma during sexual intercourse and therefore need to be investigated in ongoing research. These investigations will facilitate our understanding of the impact that various environmental events and behaviors play in sexual assault and the associated anogenital injuries.

CONCLUSIONS

Seventy-three percent of the adolescents (aged 13–17 years) reporting CSI had documented anogenital injuries. In comparison, 85% of victims of alleged sexual assault had anogenital injuries. Although these

prevalence data were not statistically different, the localized pattern, severity, and extent of injuries in rape victims appear to differ from changes after consensual sex.

These results present several important challenges for emergency care providers. Clearly, the presence of anogenital trauma suggests that penetration has occurred and implies nothing about consent. In addition, anogenital injury is not an inevitable consequence of sexual assault—the lack of genital injury does not imply consent by the victim or lack of penetration by the assailant.

References

1. Gray-Eurom K, Seaberg DC, Wears RL. The prosecution of sexual assault cases: correlation with forensic evidence. *Ann Emerg Med.* 2002; 39:39–46.
2. Schwartz N, Jones JS, Rossman L, Wynn B, Dunnuck C. Adolescent sexual assault: epidemiology and patterns of anogenital injury [abstr]. *Ann Emerg Med.* 2002; 40:S100.
3. Wynn B, Boyd K, Jones JS, Rossman L. Comparison of sexual assaults by strangers versus known assailants in a community-based population [abstr]. *Acad Emerg Med.* 2002; 9:382.
4. Rossman L, Wynn B, Jones JS. The sexual assault exam: a comparison of physical findings between an emergency department and a freestanding nurse examiner clinic [abstr]. *Ann Emerg Med.* 1999; 34:156.
5. Bowyer L, Dalton M. Female victims of rape and their genital injuries. *Br J Obstet Gynaecol.* 1997; 104:617–20.
6. McCauley J, Gorman R, Guzinski G. Toluidine blue in the detection of perineal lacerations in pediatric and adolescent sexual abuse victims. *Pediatrics.* 1986; 78:1039–42.
7. Lauber AA, Souma ML. Use of toluidine blue for documentation of traumatic intercourse. *Obstet Gynecol.* 1982; 60:644–8.
8. McCauley J, Guzinski G, Welch R, Gorman R, Osmer F. Toluidine blue in the corroboration of rape in the adult victim. *Am J Emerg Med.* 1987; 5:105–8.
9. Rossman L, Dunnuck C. A community sexual assault program based in an urban YWCA: the grand rapids experience. *J Emerg Nurs.* 1999; 25:424–7.
10. Jones JS, Rossman L, Wynn B, Dunnuck C, Schwartz N. Comparative analysis of adult versus adolescent assault: epidemiology and patterns of anogenital injury. *Acad Emerg Med.* 2003; 10:872–7.
11. Schlesselman JJ, Stolley PD. *Case-Control Studies: Design, Conduct, Analysis.* New York, NY: Oxford University Press, 1982.
12. Slaughter L, Brown C. Colposcopy to establish physical findings in rape victims. *Am J Obstet Gynecol.* 1992; 166:83–7.
13. American Professional Society on the Abuse of Children. *Glossary of Terms and the Interpretations of Findings for Child Sexual Abuse Evidentiary Examinations.* Chicago, IL: APSAC, 1988.
14. Slaughter L, Brown CRV, Crowley S, Peck R. Patterns of genital injury in female sexual assault victims. *Am J Obstet Gynecol.* 1997; 176:609–16.
15. Norvell MK, Benrubins GI, Thompson RJ. Investigation of microtrauma after sexual intercourse. *J Reprod Med.* 1984; 29:269–71.
16. Masters WH, Johnson VE. *Human Sexual Response.* London: J & A Churchill Ltd., 1966.
17. Elam AL, Ray VG. Sexually related trauma: a review. *Ann Emerg Med.* 1986; 15:576–84.
18. Hoffman RJ, Ganti SA. Vaginal laceration and perforation resulting from first coitus. *Pediatr Emerg Care.* 2001; 17: 113–4.
19. Geist RF. Sexually related trauma. *Emerg Med Clin North Am.* 1988; 6:439–66.
20. Evrard JE, Gold EM. Epidemiology and management of sexual assault victims. *Obstet Gynecol.* 1979; 53:381–7.
21. Adams JA, Girardin B, Faugna D. Adolescent sexual assault: documentation of acute injuries using photo-colposcopy. *J Pediatr Adolesc Gynecol.* 2001; 14:175–80.
22. Teixeira WR. Hymenal colposcopic examination in sexual offenses. *Am J Forensic Med Pathol.* 1981; 2:209–15.
23. Committee on Adolescent Health Care of the American College of Obstetricians and Gynecologists. Adolescent victims of sexual assault. *ACOG Educational Bulletin.* 1998; 252:1–5.