

Upper Cervical Specific Protocol and Results for 139 Patients with Medically Diagnosed Meniere's Disease

Michael T. Burcon BPh, D.C.¹

ABSTRACT

Objective: The cause of Meniere's disease is unknown; the pathophysiology is poorly understood, and the treatment empirical. One theory is that the most common cause of Meniere's disease is a structural problem, i.e., an upper cervical subluxation complex that is irritating the origin of CNVIII and partially blocking the Eustachian tube. The objective is to demonstrate the effectiveness of cervical specific chiropractic management with one hundred and thirty nine patients medically diagnosed with Meniere's disease.

Methods: Detailed case histories were taken on the first visit, followed by spinal examinations. Patients were required to furnish a letter from their ENT medical specialists, along with copies of the reports from the tests performed. Because evidence of upper cervical subluxation was discovered in each patient, three cervical x-rays were taken; lateral, A-P open mouth and Nasium. Detailed leg checks were performed utilizing the modified Prill leg check system to determine which cervical vertebrae to adjust, and when to adjust it. Thermographic pattern work was done using the TyTron C-3000. X-rays were analyzed using the Blair technique.

Results: One hundred thirty out of one hundred and thirty nine patients had inferior and posterior listings with laterality on the opposite side of their involved ear. After one or two specific cervical adjustments, one hundred and thirty six out of the one hundred and thirty nine patients presented with balanced legs and an absence or dramatic reduction of symptoms, especially vertigo. After two years, on a scale of 0 to 10, with 0 representing the absence of the symptom and 10 being the worst imaginable, vertigo was lowered from an average of 8.5 to 1.4.

Conclusion: Prior to the onset of symptoms, all one hundred and thirty nine cases suffered cervical traumas; most from automobile accidents, resulting in previously undiagnosed whiplash injuries. It is unlikely coincidental that one hundred and thirty out of one hundred and thirty nine consecutive Meniere's patients would present with a posterior and inferior atlas listing with laterality on the opposite side of the involved ear. More research on Meniere's and chiropractic is needed.

Key Words: *Meniere's disease (syndrome), vertigo, upper cervical specific chiropractic, atlas subluxation, whiplash.*

Introduction

The Prosper Meniere Society's list of symptoms was used to describe Meniere's disease (MD).¹ Vertigo is the most distressing symptom of Meniere's disease. Vertigo is a sensation of rotation or spinning. The vertigo can last from ten minutes to 24 hours. It may also be associated with nausea and vomiting. After the vertigo has gone away, most patients have imbalance and fatigue for one to three days until returning to normal. Hearing loss is also an associated symptom of Meniere's disease. Hearing loss usually fluctuates. In most cases hearing loss is only in one ear, but in rare instances,

hearing loss can be in both ears. The hearing loss is typically in the low tones. If left untreated, hearing can drop until there is permanent loss in that ear. Pressure and fullness in the diseased ear are another complaint. This can occur before or during an attack. Tinnitus is common. This is often a result of the hearing loss.

Meniere's disease is a subjective diagnosis. The American Academy of Otolaryngology and Head and Neck Surgery's requirements were used for patient inclusion in this study.²

1. Private Practice – Grand Rapids, MI. USA

For a definite diagnosis of Meniere's disease, the patient must experience two or more definitive spontaneous episodes of vertigo lasting twenty minutes or longer, have audiometrically documented hearing loss on at least one occasion, experience tinnitus or aural fullness in the involved ear and finally, have other causes excluded, especially a cranial tumor by MRI. An electronystagram (ENG) is often performed, injecting alternating hot 111° F and cold 86° F water and air into the ear. This test typically causes the patient to become nauseous. Electrocochleography is often considered the most objective test for Meniere's disease.³ A needle is inserted through the eardrum and wired to an oscilloscope. A series of ticks are introduced into the ear through a headphone and a graph of the response is made. The glycerol dehydration test involves ingesting glycerol and observing for a change of symptoms and a measurable improvement in hearing.

The Merck Manual states that the cause of Meniere's disease is unknown, and the pathology is poorly understood.⁴ The disease is named after Dr. Prosper Meniere, Chief of Medicine at the Imperial Institute for Deaf Mutes in Paris France from 1838 until his death in 1862. He wrote the first paper on the disease in 1861. Ironically, the young female patient that his paper focused on, after histopathologic postmortem examination, no longer is believed to have suffered from Meniere's disease. Prior to the publication of Meniere's paper, the only medical treatment for the condition was bloodletting.⁵ The incidence of Meniere's has been estimated to range from 0.5 to 7.5 per 1000, most commonly affecting people in their 40s and 50s.⁶ Patients diagnosed with Meniere's are advised to restrict salt in their diets to less than 2000 milligrams per day, and to avoid nicotine and caffeine. Although some patients increased their salt intake after an improvement in symptoms, most, realizing the related health benefits, did not.

Diuretics such as Dyazide may be prescribed to reduce the fluid load on the inner ear. Antivert is prescribed for the vertigo. Antihistamines are routinely used to reduce head congestion. Anticholinergics are used to allay nausea. Some combination of barbiturates, antidepressants or sleeping pills is generally prescribed. Gentamicin may be injected into the middle ear to destroy hair cells. Unfortunately, Gentamicin can also make hearing worse. For this reason, steroids are now more commonly used.^{7, 8} Although most patients in the study discontinued the use of these drugs with the improvement in their symptoms, a small percentage continued to take them as needed.

During the year 2005, ninety four percent of the ENT surgeons in the United Kingdom prescribed the vestibular suppressant Serc to their Meniere's patients. In 1999 the FDA concluded that although there is no evidence that Serc is harmful, there is little evidence that it has any therapeutic effect.⁹

If symptoms are not controlled with drugs, surgery may be considered. Endolymphatic subarachnoid shunting is the least invasive surgery available. At two years post surgery, it is found to be 38% effective in controlling vertigo, similar to a placebo. The long term results of hearing function tests show no improvement.¹⁰ Vestibular neurectomy may be performed. This is an intercranial procedure that requires several days of hospitalization. The patient will have extreme vertigo after the procedure followed by weeks of imbalance. Labyrinthectomy

(inner ear destruction) is effective in eliminating symptoms, but also totally destroys hearing. The Meniett device is a small machine that provides low-pressure pulses through a ventilation tube placed in the eardrum. It has not been proven to be more effective than "pumping" your ear with the cup of your hand.¹¹

Since 1938, the term endolymphatic hydrops has been used interchangeably with Meniere's disease and Meniere's syndrome in the literature.¹² Although the underlying etiology of Meniere's is unknown; a consistent finding is hydrops to indicate dilation of the endolymphatic spaces. It appears that fluid build-up in the endolymphatic space, caused either by overproduction or reduced absorption, exposes hair cells responsible for sensing movement and balance to progressive damage or paralysis.¹³ However, many temporal bones with hydrops came from people without a history of vertigo or hearing loss during their lifetime.¹⁴ But the important question is what would cause this overproduction? (We did not have access to the equipment necessary to measure these fluids before and after the adjustment.) Subluxation between the superior articular surface of atlas and Occiput can cause swelling in the immediate area, putting pressure on the nucleus of CN VIII and/or the auditory (Eustachian) tube.¹⁵

Another theme in reports on etiology and pathology of Meniere's disease is an increase in immunoglobulins both in the endolymphatic fluid and in serum. This would suggest an underlying infection, probably viral, or autoimmune component with this condition.¹⁶ (One theory is that infection tends to set in at weakened areas of the body, for instance, areas of vertebral subluxation.)

Both the vestibular and cochlear nerves join the internal auditory meatus to form CN VIII, which enters the brain stem at the cerebello-pontine angle. Meniere's is considered a common peripheral ailment, however it is often overlooked that although within the substance of the brain itself, the root entry zone of the eighth cranial nerve is considered a peripheral vestibular structure.¹⁷ An atlas subluxation may irritate this nerve root by compromising the size of the neural canal space.¹⁸ Rosenberg reported a case of cervical cord impingement observed with magnetic resonance imaging, bringing on signs and symptoms of medulla compression.¹⁹ Dizziness related to perturbations in information received from proprioceptors in the neck that feed into the vestibular system is not usually taken into consideration.²⁰ Such proprioceptive insult is a common result of even minor whiplash injuries.

One theory has proposed that irritation of sympathetic nerves can elicit spasms within the vertebral artery, leading to decrease in blood flow to the brain stem.²¹ The vertebral arteries reach the interior of the skull by ascending through the transverse foramina of the cervical vertebrae, turning medially along the upper surface of the posterior arch of atlas and then penetrating the posterior atlanto-occipital membrane and the underlying dura to enter the subarachnoid space.²² Subluxation of the atlas may diminish blood flow through the vertebral arteries and their intracranial branches which supply the spinal cord, CN VIII, medulla, cerebellum and inner ear via the labyrinthine artery.²³

Twice as many Meniere's patients suffer from migraine than the general population. Additionally, many of the same symptoms are present in MD and migraine. PET scans of cerebral blood flow in acute migraine show changes in the brainstem and Trigeminal ganglion, areas that may be irritated by an upper cervical subluxation complex.^{24,25} Other symptoms commonly experienced by MD patients include nystagmus, cervicalgia, sinusitis and brain fog.

When the left ear is stimulated, the eyes will be made to move to the right. A stimulated canal generally pushes the eyes in the opposite direction. There is a constant push-pull relationship between the labyrinth and the eyes. That there are eight vestibular nuclei, four on each side of the brainstem, attests to the complexity of computing movements over time. A second component of eye movement comes from the cerebral cortex. Noting deviation of the eyes, it will make a rapid corrective movement. In the Meniere's patient, this can cause nystagmus.²⁶

Finally, internal pressures of the body, specifically that of the cerebrospinal fluid, are rarely taken into consideration. The fluid spaces of the inner ear are connected to the CSF by the cochlear aqueduct, believed to be patent in most humans. Thus pressure changes in CSF are transmitted directly to the ear.²⁷ The tensor veli palatini and salpingopharyngeus muscles control the auditory tubes, responsible for equalizing pressure in the middle ears with the atmosphere.²⁸ These muscles are innervated by the pharyngeal nerve plexi, which have a contribution from Cranial Nerve XII. The hypoglossal canal lies under cover of the middle area of each occipital condyle, intimate to atlas. Therefore, an atlas subluxation could furthermore interfere with a tubal function.

Most normal individuals cannot appreciate the devastating impact of vertigo. The patient perceives that the world is spinning around them. Vertigo disrupts every aspect of life since the patient loses the ability to do anything normally, especially when movement is involved. It can totally incapacitate the individual, often confining them to bed.²⁹ Vertigo is to dizziness what migraine is to headache. This report describes the results of 139 patients suffering from Meniere's who were diagnosed by Ear, Nose and Throat medical specialists. Upon neurological examination and cervical x-ray analysis, all 139 subjects showed evidence of whiplash trauma. Patient histories suggested that the injuries were incurred an average of fifteen years prior to the onset of MD symptoms. It is important to note that most did not list the injury on the original case history paperwork. It was only remembered after lengthy questioning, often by the spouse as opposed to the patient.

Methods

The technique utilized is based on the work of BJ Palmer DC, as developed at his Research Clinic at Palmer Chiropractic College in Davenport, IA, from the early 1930s until his death in 1961.^{30,31,32} Techniques also include the vertebral subluxation pattern work of his clinic director, Lyle Sherman DC, for whom Sherman College of Straight Chiropractic, Spartanburg, SC is named.³³ In each case a detailed case history was taken on the first visit (average 45 minute discussion), followed by a spinal examination. A report of

findings was given, recommending a minimum set of three cervical x-rays when evidence of an upper cervical subluxation was discovered in each patient. X-rays and analysis of the upper cervical vertebrae based on the work of William G Blair DC were used to determine chiropractic listings of subluxation.

Lateral cervical, A-P Open Mouth and Nasium x-rays were taken. Lateral films were analyzed to determine evidence of whiplash injuries. Posterior atlas listings (anterior occipital listings), along with the lack of proper cervical curve, were considered evidence of a history of neck trauma in this study. The A-P Open Mouth view was used to study lateral deviations of the neural rings, which may cause neurological irritation. With the Nasium x-rays the antero-lateral (distal) margins of each of the articulations were clearly classified as being either juxtaposed, overlapped where the atlas lateral mass margin was more anterolateral than condyle margin, or underlapped where lateral mass margin was less antero-lateral than condyle margin. Overlapping is synonymous with anterior and superior atlas listings with laterality of the side of the overlap, underlapping indicates posterior and inferior C1 listings on the opposite side of the underlap. These appositional judgments of each articulation may then be combined to deduce the actual unilateral or ambilateral misalignment pathways of atlas in relation to Occiput, and an anatomically accurate misalignment listing and adjustive formula may thus be derived.³⁴ When three x-rays were not sufficient to determine upper cervical listings, complete sets of custom Blair x-rays, including individual protracto views of both atlanto-occipital articulations, were taken. There are only four atlas listings under this system— anterior and superior on either the right or left, or posterior and inferior on either the right or left. Using the anterior tubercle of atlas as the reference point, considering the rocker configuration of the atlanto-occipital articulation, if atlas moves posterior then it must also move inferior.³⁵

Leg length inequality checks were performed on each patient visit, utilizing the work of J Clay Thompson DC and Clarence Prill DC.^{36, 37} Dr Thompson, with the help of Romer Derifield DC, popularized the cervical syndrome check for the upper cervical subluxation complex in the 1940's. Since then, no one has come up with a reason relative leg length would change when a patient gently turns their head from side to side, while either prone or supine, thus not under the effects of gravity, except upper cervical subluxation. What causes one leg to appear shorter than the other and to change relative length when the head is turned, taking into consideration that the patient is lying down, not under the effects of gravity? One subluxation complex hypothesis proposes that the mechanism of fixation involves impingement of the atlanto-occipital intra-articular fat pad causing reflexive guarding contraction of the suboccipital muscles. Stimulation of the spindles in these muscles are thought to be involved in the initiation of tonic neck reflexes that alter global extensor muscle tone to achieve proper body balance in response to head movement.³⁸

A conservative approach in determining evidence of subluxation was used. That is, when in doubt no adjustment was given. The leg checks were the main criterion used to decide when to adjust or not. To determine whether the major subluxation was at the level of atlas or axis, Prill modified leg

length tests were utilized.³⁹ With patient prone, patient was instructed to gently and steadily raise their feet toward the ceiling, while the doctor resisted such movement with his hands. The peripheral nerves were being tested, those that innervate the postural muscles holding one upright in gravity, so it was imperative that the patient only lift their legs slightly and maintain this pressure for at least two seconds. This test was for atlas, the top cervical vertebra. Instructing patients to rotate their feet while the doctor provided resistance and checking relative leg length was used to test axis. Some clinicians prefer to have the toes rotate outward. I had the patients pull their heels together. This corresponds to the rotation of the head on the neck, 50% of which occurs at the level of C2.

Thermographs of the cervical spine were utilized using a Tytron C-300 instrument. These were used to develop a pattern of subluxation in order to determine when to adjust. A graph reading that is static and persistent over time is considered to be the patient's pattern.^{40,41} When it was determined that the patient was in a pattern of subluxation, a toggle recoil adjustment was performed on atlas, with the patient in a side-posture position, or a Pierce technique adjustment was performed with the patient prone. Side posture was used when laterality was the main component of the subluxation. The term used for this type of misalignment is translation, and most often occurs with a side impact trauma, for instance, a "T-bone" type of automobile accident. When posteriority was the major component of the subluxation, the prone position was favored. This misalignment usually is the result of the typical "rear ended" type of automobile accident.

A Thuli chiropractic table, using the cervical drop piece was utilized. For side posture adjustments the headpiece was set to drop straight down, and with prone adjustments, it was set to drop down and forward. The patient was then rested for fifteen minutes and rechecked, to make sure that the pattern had been broken. All 139 patients were adjusted on the second visit, after it was found that they were in a pattern of subluxation. They were rested, rechecked, and 133 out of 139 were found to be balanced. The six that were not balanced were adjusted again, rested and balanced when rechecked a second time. Most are now under maintenance care, being checked on a monthly basis.

All patients completed a questionnaire (developed by the first author) prior to their first adjustment. (Table 1) They were asked to rate the three major symptoms of Meniere's; vertigo, loss of hearing and tinnitus, and seven secondary symptoms; nausea and/or vomiting, ear pressure, migraines, headaches, brain fog, neck stiffness and/or pain and sinus pressure and/or pain. These symptoms were rated numerically between 0 and 10, with 0 representing the absence of that symptom and 10 representing that that symptom was the worst the patient could possibly imagine. The questionnaire was filled in again after six weeks and one year during an office visit.⁴² One hundred and seventy three questionnaires were mailed out to MD patients that received their first cervical specific adjustment a minimum of two years and a maximum of eight years prior. Of these, 139 were returned (80.3%).

The data lacked a normal distribution for the POST survey responses (skew of 1.40). Consequently, the Wilcoxon Signed

Ranks test was performed for differences between PRE and POST (in SPSS, Chicago, IL, v. 14.0) using a two-tailed alpha level for statistical significance.

Results

Although all symptoms included in the questionnaire averaged lower scores at six weeks, one year and two years, only vertigo and the associated nausea and vomiting were lowered dramatically. Vertigo averaged 8.5 before cervical specific chiropractic adjustments. Most patients reported an inability to function, i.e., drive, work or socialize, at a rating above 5. After six weeks it lowered to a mean of 3.0, after one year it was down to a mean of 2.3, and after two years it was down to 1.4. Many patients noticed an improvement before they left the office after their first adjustment. Except for the three patients that discontinued care after six weeks due to a lack of improvement, the longest it took for a patient to report a noticeable improvement was fourteen weeks. After two years, nausea and/or vomiting was lowered from 7.0 to 1.3. The only negative side effect noted was an increase in the frequency and magnitude of headaches in three patients. For them headaches increased an average of 2.3 to 5.7. (Figure 1) Two years after initiation of care, 88 out of 139 patients (63%) reported a score of 0 or 1 (on a scale of 0-10, 10 being the worst) for vertigo, dizziness and lack of balance. The average response for vertigo on the PRE survey was 8.47 and for POST (two years later), 1.39, a statistically significant difference ($p = 0.000$). Statistically significant improvements ($P = 0.000$) were also seen between: a) PRE versus 6 weeks, b) PRE versus 1 year, c) 6 weeks versus 1 year, d) 6 weeks versus 2 years, and e) 1 year versus 2 years (Figure 2).

Example of a Typical Case History with Results

Patient #24 first presented with left sided Meniere's on June 11, 2001. He was diagnosed by an Ear, Nose and Throat specialist based on the results of a normal MRI of the brain, positive audiological examination for hearing loss, and an abnormal bithermal caloric test (ENG). He was referred to the Michigan Ear Institute, where endolymphatic sac decompression surgery was recommended. He declined surgery and received a letter recommending that he apply for disability benefits, which were granted by the State of Michigan.

Case history included a rear ended type of automobile accident at 45 mph in 1980. Meniere's symptoms started in 1994 with frequent bouts of vertigo lasting from one day to one week, accompanied by nausea and vomiting. Complaints included constant ear fullness and tinnitus, and frequent concomitant cervicalgia and headaches. He had open heart surgery in 1998.

He presented with a 1" short left leg relative to his right, 1/2" right cervical syndrome and positive C1 and C5 Prill tests. Cervical x-ray analysis provided a listing of PIR for atlas and posterior C5. He was adjusted twice during his first week of care. The next week he presented balanced and was vertigo free. His wife said that his voice had changed. He reported being able to walk four times as far.

At six weeks, according to his Meniere's questionnaire, vertigo was down to 2 from 10, nausea/vomiting down to 0

from 10 and ear pressure 1 from 10. He went just over one year with no vertigo. After one adjustment, he was vertigo free for an additional two and one half years. His next adjustment held for an additional year and one half. He has not needed an adjustment for the past two and one half years.

Example of a Typical Pre and Post Cervical X-ray and Thermograph

This photograph (Figure 3) of a cervical A-P Open Mouth X-ray demonstrates an atlas that is posterior and inferior on the left. Notice that the lateral edge of the superior surface of the right articulation of atlas underlaps its articulation with Occiput, creating a subluxation with the listing PIL. This symptomatic patient has right unilateral Meniere's.

The photo to the right was taken six weeks post initial adjustment. Two upper cervical adjustments were performed. Atlas appears to be in juxtaposition. The patient was off all medications and symptom free. Their pattern cervical thermograph and post adjustment graph are shown in Figure 4.

Discussion

The improvements in these patients made a difference for 136 out of 139 patients, affecting whether or not they could work, drive and/or have a positive relationship with their spouse. (Health Talk II DVD's of Meniere's patients discussing these changes are available.) They might get dizzy, but would not have vertigo. They might get nauseas, but would no longer vomit. For those that still had attacks, they occurred less often, lasted for a shorter duration and were not as intense. Recovery time was also significantly shorter.

All 139 patients showed evidence of upper cervical subluxation upon neurological examination, and all exhibited both evidence of a history of whiplash and an existing atlas subluxation in radiographs. One hundred thirty out of 139 patients had posterior and inferior atlas listings, with atlas laterality on the opposite side of the involved ear. It took an average of fifteen years from the time of the head/neck trauma until the onset of Meniere's type symptoms.

Meniere's disease not only includes the symptom complex consisting of attacks of vertigo, low-frequency hearing loss and tinnitus, but comprises symptoms related to the Eustachian tube, the upper cervical spine, the temporomandibular joints and the autonomic nervous system.⁴³ The major clinical features of MD, unilaterality and the onset of symptoms in adulthood are compatible with an acquired event. From eleven countries, many clinicians both chiropractic and medical report cases in which cervical manipulation to correct functional spinal pathology has cured tinnitus and improved hearing, often in cases where the auditory problems have followed motor vehicle whiplash injuries. The great majority of cases involve the upper cervical spine.⁴⁴ Medical and chiropractic research has established a connection between spinal trauma and numerous neurological conditions besides Meniere's disease, including multiple sclerosis, Parkinson's disease, amyotrophic lateral sclerosis, Trigeminal neuralgia, epilepsy and migraine headache.^{45, 46, 47, 48}

Chiropractors are well acquainted with the correlation between

cervical spine dysfunction and neuro-otological symptoms such as tinnitus, vertigo, neuralgia and sudden hearing loss.⁴⁹

Physicians often make the mistake of thoroughly examining only the area of chief complaint. When relevant, I believe it is prudent to start at the nucleus of the cranial nerve or center that supplies function to that area. For example, the brain stem for balance disorders (CN VIII), irritable bowel syndrome (CN X, Vagus), high blood pressure (vasomotor center) and sleep disorders (reticular formation).

One study of 133 patients diagnosed with Meniere's disease that were referred to ear surgeons determined that eight years later, 70% of the 83 that got endolymphatic subarachnoid shunt surgery were vertigo free, but of the 50 that declined the surgery, 57% had "complete control" of their vertigo after two years.⁵⁰ In another study of 243 consecutive patients with a Meniere's disease diagnose that varied from recent to 41 years, no difference was found in the frequency, intensity or duration of vertigo attacks. Seventy five percent of patients who had MD for more than 20 years considered their vertigo attacks severe and 36% still had attacks 1 to 4 times per week. Nausea associated with vertigo was most common among those with a long history of the disease.⁵¹

Although statistics and percentages are useful for dealing with large numbers of patients, because Meniere's disease symptoms and prognosis vary so greatly for each individual patient, they are useless when it comes to one particular patient. Some doctors say Meniere's burns itself out. Burnout refers to a condition where Meniere's disease has progressed to the point where it has finally destroyed the entire vestibular function in the affected ear. Although the patient may compensate for this loss in other ways and become rotational vertigo free, the other symptoms continue to worsen. The Merck Manual states that this progression of hearing loss averages ten to fifteen years.

It is possible that when the top cervical vertebra partially slips off from one of its two articulations, it puts a small amount of pressure on the spinal cord where it meets the medulla oblongata, irritating it and creating swelling in the area after a period of time. This inflammatory edema could irritate the lower cranial nerves and/or partially block the adjacent auditory tube. In the case of whiplash, the symptoms are usually exaggerated by an additional lower cervical subluxation.⁵²

Conclusion

A case study is limited in its ability to provide conclusions. It is possible that the patients recovered through spontaneous remission or because they believed their problems had been discovered and improved, creating a placebo effect. The average time span before chiropractic intervention and the long-term clinically-documented neurophysiological improvements after initial adjustments weigh against such possible effects. In addition, these were 136 consecutive Meniere's patients, of which one hundred and thirty had posterior and inferior atlas listings with laterality on the opposite side of ear involvement.

All patients with a history of vertigo should be questioned

about a history of trauma, especially whiplash from an automobile accident, contact sports injury, or serious falls. Patients often forget these accidents, thinking that they were not hurt because they did not break any bones and were not bleeding. Patients with a history of both vertigo and trauma should be referred to an upper cervical specific chiropractor for examination.

References

- Prosper Meniere Society, Dept. of Otolaryngology, Head and Neck Surgery, University of Arkansas for Medical Science, Little Rock, AR.
- Cowan A & Makishima T. Treatment for Meniere's Disease. UTMB, Dept. of Otolaryngology, Dec 13, 2006.
- Gibson W, Ramsde, R, Moffa, D. Clinical Electrocochleography and Diagnosis and Management of Meniere's Disorder. *Audiology* 1977; 16:389-401.
- The Merck Manual, Sixteenth Edition. Berkow MD, Robert Rahway, NJ: Merck Research Laboratories, Merck & Co., Inc., 2006.
- Meniere P. Pathologie auriculaire: Mémoires sur de lésions de l'oreille intern donnant lieu a des symptoms de congestion cerebrale apoplectiforme. *Gaz Med Paris* 1861; 16:597-601.
- Pfaltz & Matefi. Sac Enhancement Surgery in Patients with Meniere's Disease. 1981.
- Garduno-Anaya M, De Toledo H, Pane-Pianese C. Dexamethasone Inner Ear Perfusion by Intratympanic Injection in Unilateral Meniere's Disease: Six Years of Prospective Follow-Up. 26th Politzer Society Meeting 2007; Cleveland Clinic, Cleveland, OH.
- Dodson K, Sismanis A, Kyrodimos E. Intratympanic Dexamethasone Perfusion for the Treatment of Meniere's Disease. 26th Politzer Society Meeting 2007; Cleveland Clinic, Cleveland, OH.
- Smith W, Sankar V, Pfleiderer A. A National Survey amongst UK Otolaryngologists regarding the Treatment of Meniere's disease. *Laryngol Otol.* 2005; 119(2):102-5
- Myeong Sang Yu, Kwang-Sun Lee, Jong Woo Chung. Long term results of endolymphatic mastoid shunt surgery in patients with intractable Meniere's disease. *Otolaryngology-Head and Neck Surgery*, Feb 2009, Vol 141; pp 237-242.
- Feijen R, Wit H, Albers F. Treatment of Meniere's Disease with Intermittent Middle Ear Pressure. Fifth International Symposium on Meniere's Disease & Inner Ear Homeostasis Disorders 2005; Los Angeles, CA.
- Yamakawa, K. Uber die pathologische Veranderung bei einem Meniere-Kranken. *J Otorhinolaryngol Soc Jpn.* 1938; 4:2310-2312.
- Knox G. Surgical Management of Meniere's Syndrome. *Grand Rounds Archives* 1994.
- Gates, G. Unresolved Clinical Issues with Meniere's Disease. Fifth International Symposium on Meniere's Disease & Inner Ear Homeostasis Disorders, House Ear Institute 2005; Los Angels, CA.
- Burkhard Franz, Colin Anderson. The Potential Role of Joint Injury and Eustachian Tube Dysfunction in the Genesis of Secondary Meniere's Disease. *International Tinnitus Journal*; 2007, Vol. 13, No. 2, pp. 132-137.
- [Savastano M](#) . [Giacomelli L](#) , [Marioni G](#) . Non-specific Immunological Determinations in Meniere's disease: any role in clinical practice? [Eur Arch Otorhinolaryngol.](#) 2007; Jan;264(1):15-9. Epub 2006 Oct 11.
- Furman, J, Whitney, S. Central Causes of Dizziness. *Physical Therapy* 2000; 80:2.
- Terrett A. Cerebral Dysfunction: a theory to explain some of the Effects of Chiropractic therapy. *Chiropr Tech* 1993; 5:168-73.
- Rosenberg W, Salame K, Shumerick K, Tew J. Compression of the Upper Cervical Spinal Cord causing symptoms of Brainstem compromise. A Case Report. *Spine* 1998; 23:1497-500.
- Fitzgerald D. Head trauma: Hearing loss and Dizziness. *J Trauma.* 1996; 40:3,488-496.
- Biesinger E. Vertigo caused by Disorders of the Cervical Vertebral Column; Diagnosis and Treatment. *Adv Otorhinolaryngol.* 1998; 39:44-51.
- Hollinshead W, Rosse C. *Textbook of Anatomy*, Fourth Edition. Philadelphia: Harper & Row, 1995.
- Hulse M. The Cervical Vertebra as a Cause of Hearing Disorders. German HNO Conference, Muenster 1993, 42:604613.
- Radtke A. Migraine and Meniere's Disease: Is There a Link? *Neurology*, 2002; 59(11):1700-1704.
- Teixido M. Migraine Management for the Otolaryngologist. 13th International Symposium and Workshops on Inner Ear Medicine and Surgery, Zell im Zillertal, Austria 2008.
- Yanofsky C. Pennsylvania Neurological Associates, www.pneuro.com.
- Salt A. A Survey of the Effects of Pressure on Meniere's Disease Symptoms. 2000: [URL:http://oto.wustl.edu/men/pressure](http://oto.wustl.edu/men/pressure).
- Burkhard F, Anderson C. Autonomic Control of Eustachian Tube Function in the Anaesthetized Rat. The 25th Anniversary of the Prosper Meniere Society 2006; Zell im Zillertal, Austria.
- Burcon M. Upper Cervical Protocol for Ten Meniere's Patients, Upper Cervical Subluxation Complex. A Review of the Chiropractic and Medical Literature, Kirk Ericksen, 2004; Lippincott, Williams & Wilkens, Baltimore, MD, pp 284-286.
- Palmer, BJ. *The Subluxation Specific, The Adjustment Specific*. Davenport, Iowa: Palmer School of Chiropractic, 1934.
- Palmer, BJ. *Chiropractic Clinical controlled Research*. Volume XXV. Davenport, IA: The BJ Palmer Chiropractic Clinic, 1951.
- Palmer, BJ. *History in the Making*. Volume XXXV. Davenport, Iowa: Palmer School of Chiropractic, 1957.
- Sherman L. Neurocalometer-neurocalographneurotempometer Research. Eight BJ Palmer Chiropractic Clinic Cases. Davenport, IA: Palmer School of Chiropractic; 1951.
- Addington E. Blair Cervical Spinographic Analysis. Conference of Research and Education, Monterey, CA June 21-23, 1991.
- Blair W. Blair upper Cervical Spinographic Research; primary and adaptive malformations; procedures for solving malformation problems; Blair principle of occipito-atlanto misalignment. Davenport, IA: Palmer College of Chiropractic; 1968.
- Burcon M. Parkinson's disease, Meniere's syndrome, Trigeminal neuralgia and Bell's palsy: One cause, One

- Correction, Dynamic Chiropractor. 2003; 21(11).
37. Prill, C. The Prill Chiropractic Spinal Analysis Technique. 2001.
 38. Knutson G. Tonic Neck Reflexes, Leg Length Inequality and Atlanto-occipital Fat Pad Impingement: An Atlas Subluxation Complex Hypothesis. *Chiropr Res J* 1997; 4(2):64-76.
 39. Burcon M, Olsen E. Modified Prill Leg Check Protocol. 11th Annual Vertebral Subluxation Research Conference, Sherman College of Straight Chiropractic, Spartanburg, SC 2003.
 40. Hart J, Boone R. Pattern Analysis of Paraspinal Temperatures: A Descriptive Report. *J Vert Sublux Res* 1999-2000:3(4).
 41. Burcon M. BJ's \$50,000 'Timpograph still captures our imagination after more than fifty years. *Chiropractic Economics*, Nov/Dec 1995.
 42. Burcon M. Cervical Specific Protocol and Results for 100 Meniere's Patients. 26th Politzer Society Meeting, Oct 13-16 2007; Cleveland Clinic, Cleveland, OH.
 44. Franz B, Anderson C. The potential role of joint injury and Eustachian Tube Dysfunction in the Genesis of secondary Meniere's disease. *Int Tinnitus J*. 2007; 13(2):132-7.
 45. Terrett A. Vertebrogenic Hearing Deficit, the Spine, and Spinal Manipulation Therapy: A Search to Validate the D.D. Palmer/Harvey Lillard Experience, *Chiropr J Aust* 2002; 32(1):14-26.
 46. Elster E. Sixty Patients with Chronic Vertigo Undergoing Upper Cervical Care to Correct Vertebral Subluxation: A Retrospective Analysis. *Journal of Vertebral Subluxation Research* 2006.
 47. Elster E. Upper Cervical Protocol for Five Multiple Sclerosis Patients. *Today's Chiropractic* November 2000.
 48. Kessinger R, Boneva D. Vertigo, Tinnitus, and Hearing Loss in the Geriatric Patient. *J Manipulative Physiol Ther* 2000; 23:5.
 49. Ericksen K. Editorial Comment. p 280, *Upper Cervical Subluxation Complex, A Review of the Chiropractic and Medical Literature*, Lippincott, Williams & Wilkins, 2004.
 50. Silvestein H, Smouha E, Jones R. Natural history vs. surgery for Meniere's disease. *Otolaryngol Head Neck Surg*, 1989; 100(1):6-16.
 51. Havia M, Kentala E. Progression of Symptoms of Dizziness in Meniere's disease. *Arch Otolaryngol Head Neck Surg*, 2004; 130(4):431-50. Table 1 Meniere's Questionnaire
 52. Burcon M. Upper Cervical Protocol and Results for 100 Meniere's Patients. 25th Anniversary of the Prosper Meniere Society and the 12th International Symposium and Workshops on Inner Ear Surgery and Medicine, 2006; Zell am Zimmer, Austria.

MENIERE'S QUESTIONNAIRE

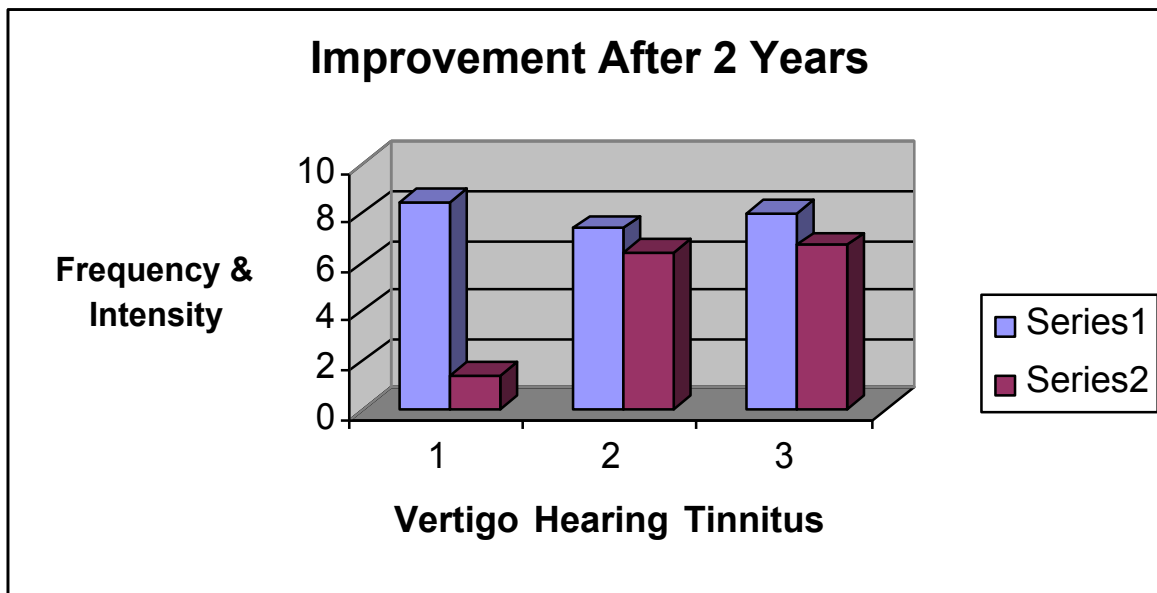
Thank you for participating in our Meniere's study. Please answer the following questions and return this form to Burcon Chiropractic. Answer questions with a number between 0 and 10, with 0 representing that you do not have that problem, 10 representing that the problem is the worst you can imagine.

In column A put the number for how you felt before your first adjustment at Burcon Chiropractic. In column B put the number for how you have been feeling since your last adjustment.

Patient Name _____ Today's date _____

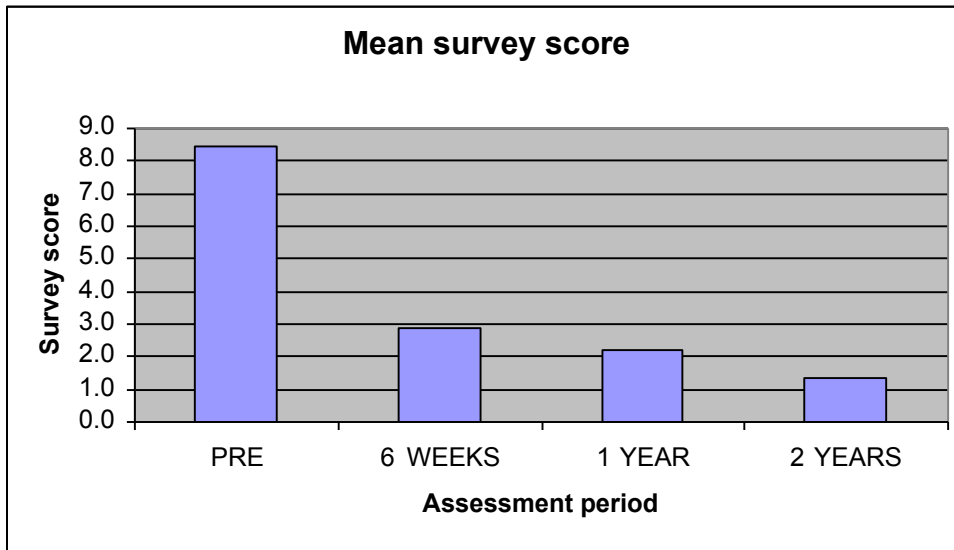
Major Symptoms	A	B
1. Vertigo, dizziness or lack of balance:	_____	_____
2. Loss of hearing:	_____	_____
3. Tinnitus (ringing in the ears):	_____	_____
Secondary Symptoms		
4. Nausea/vomiting:	_____	_____
5. Ear Pressure:	_____	_____
6. Migraines:	_____	_____
7. Headaches:	_____	_____
8. Brain fog:	_____	_____
9. Neck stiffness/pain:	_____	_____
10. Sinus pressure/pain:	_____	_____

Figure 1



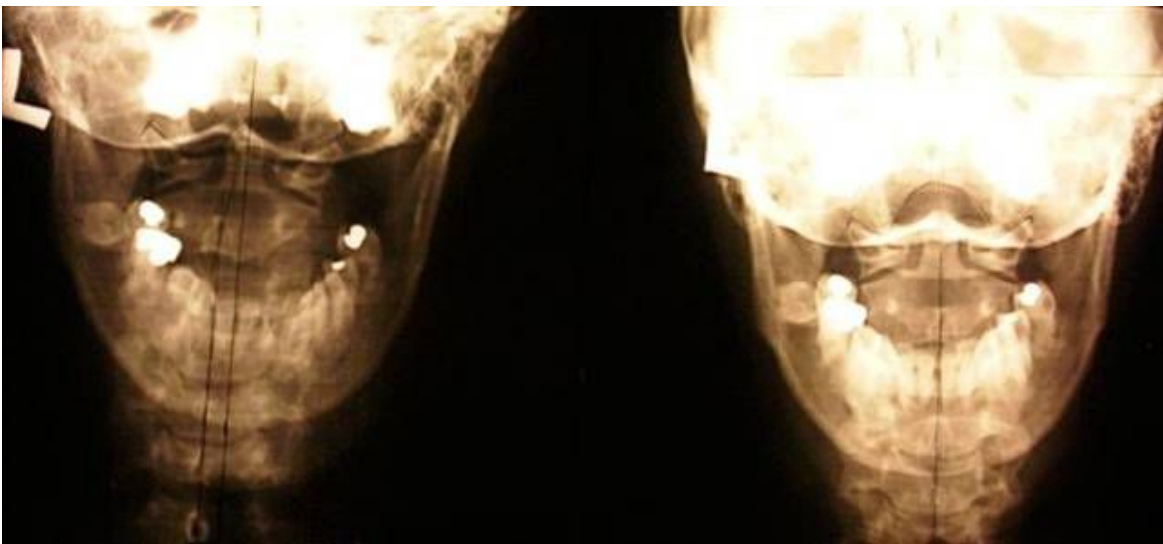Mean improvements of 139 Meniere's patients in vertigo (1), hearing (2) and tinnitus (3) under cervical specific chiropractic care. Series 1 is pre first adjustment. Series 2 is a minimum of two years post first adjustment. Frequency and intensity were determined by patient questionnaire on a scale of 0 to 10.

Figure 2. Mean survey scores for vertigo.



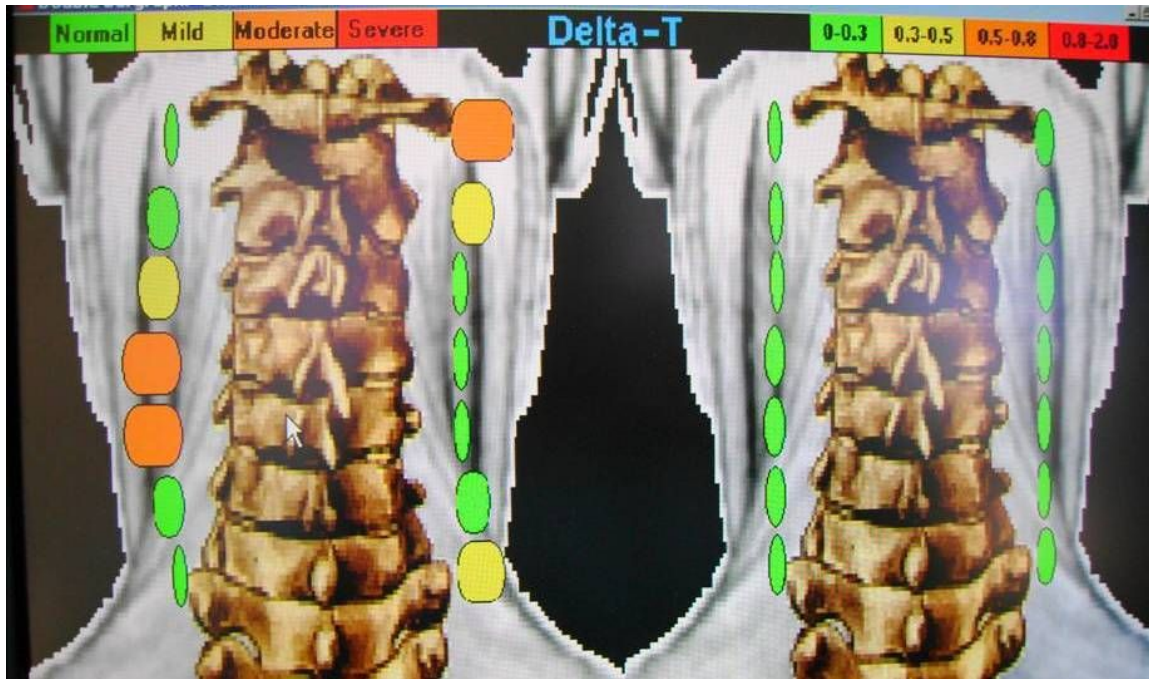
Survey scores for vertigo at the beginning of care (PRE), at 6 weeks, 1 year and 2 years. There were statistically significant differences ($P = 0.000$) between: a) PRE versus 6 weeks, b) PRE versus 1 year, c) 6 weeks versus 1 year, d) 6 weeks versus 2 years, and e) 1 year versus 2 years.

Figure 3



A-P Open Mouth X-ray on left taken of a patient with right unilateral Meniere's disease. Pre adjustment. X-ray on the right was taken six weeks later of the same patient who received two upper cervical specific chiropractic adjustments to correct PIL listing.

Figure 4. Fifty three year old female.



The thermograph on the left shows this patient's established pattern. The first two pre adjustment graphs were identical. This demonstrates a typical finding for a patient with right unilateral Meniere's disease. The atlas level is orange on the side of the involved ear. If pattern returns it is usually yellow. The C5 level usually appears yellow or orange on the contra lateral side. This is often indicative of a whiplash type injury. The graph on the right was taken fifteen minutes post PIL adjustment.