


OPHTHALMOLOGY

HOW TO EXAMINE AN EYE



Visual Acuity

Use a Snellen chart. Test each eye separately at 6 meters. Allow the patient to use glasses.

If acuity reduced use a pinhole (corrects refractive error).

If no improvement with pinhole the problem is not refractive.

Document: distance in meters/number of line read

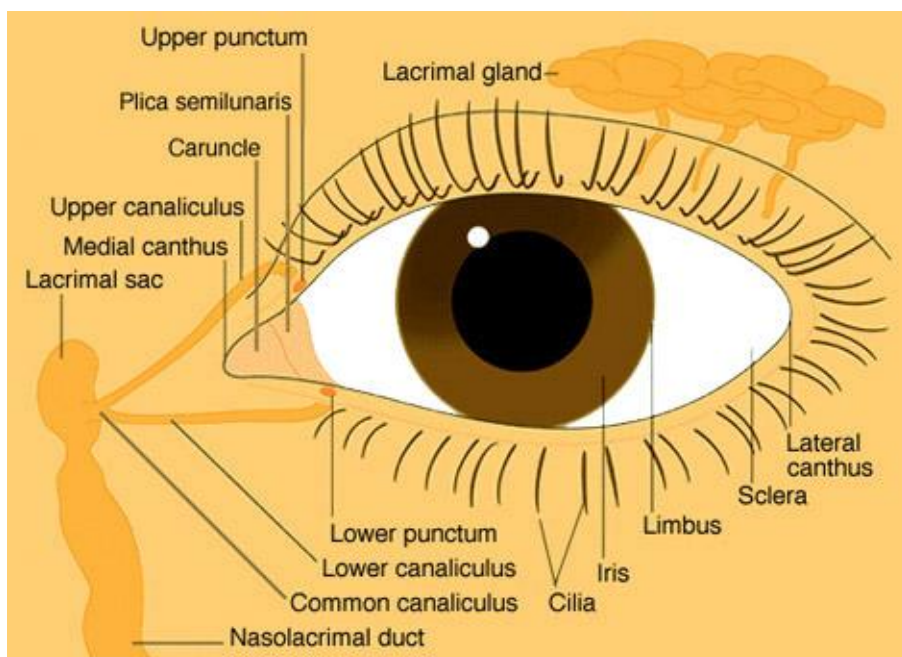
If unable to read at 6m try 3m.

Try counting fingers if unable to read at 3m.

Check if hand movements are seen if unable to count fingers.

Cranial Nerve Examination

Pupillary responses, visual fields and eye movements.



External Eye

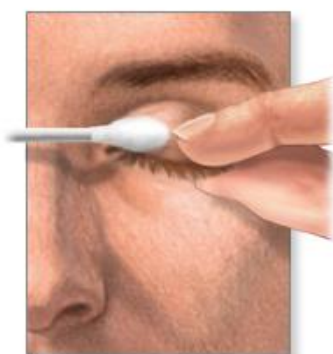- Inflammation.
- Discharge, tearing.
- Signs of trauma.
- Foreign body.

Evert the eyelid if possible foreign body but nil seen on external exam.

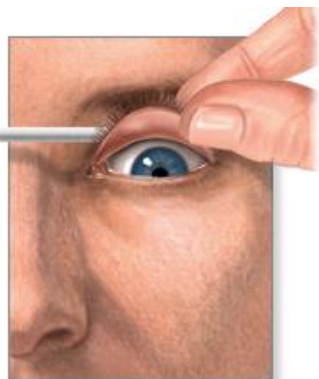
Everting the Eyelid

Give local anaesthetic eye drops prior.

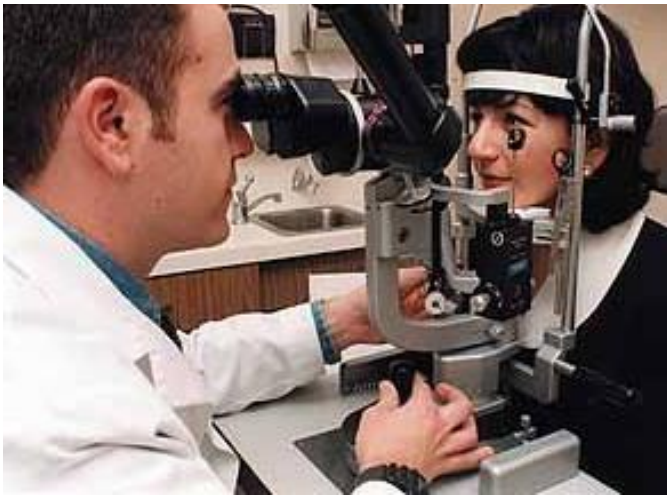Ask the patient to look down throughout. Press on the upper eyelid with cotton bud. Rotate eyelid upwards over cotton bud.



Twist cotton-tipped swab upward

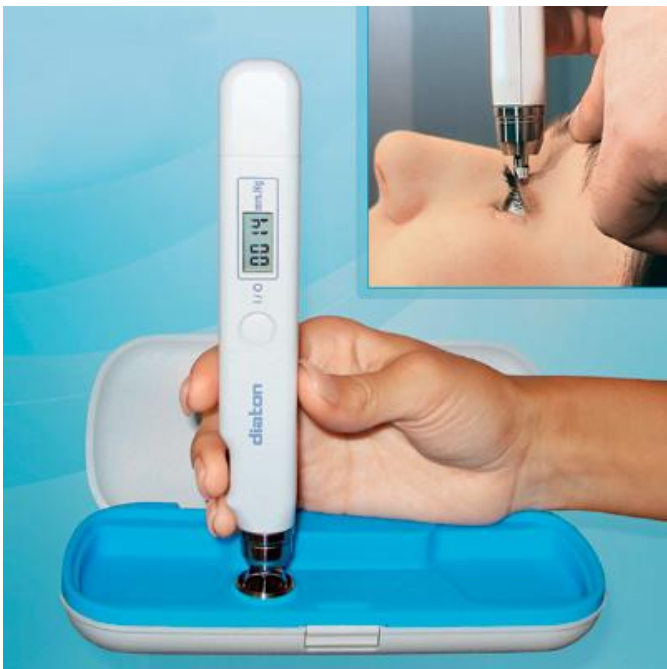

Look downward



Slit Lamp Examination

- Forehead on headrest, chin on chinrest.
- Adjust height so you/patient comfortable.
- Adjust beam width/light colour with knob above eyepieces.
- Focus by moving the joystick.
- Elevate/depress view by rotating joystick.
- Examine eyelashes, lids (and evert), conjunctiva/sclera, cornea, anterior chamber, iris, pupil and lens.



Tonometry

Palpating intraocular pressure by hand is unreliable but can give a vague impression.

Apply the point of the tonometer to the eyelid with gentle pressure.

Take three readings.

Many departments have no tonometer and if you are unsure how to use it may be best to leave this to the ophthalmologist.



Fundoscopy

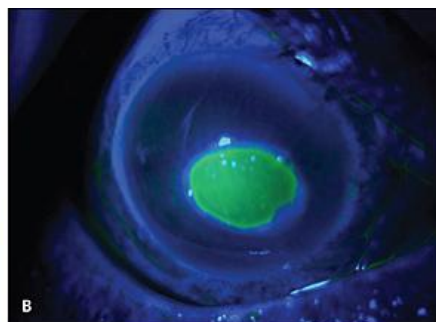
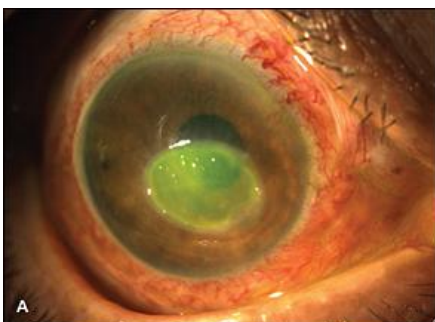Do not dilate the pupil if head injury or iris trauma.

Red reflex.

Optic disc - swelling, pallor

Macula

Retina and vessels



Fluorescein

Pools in corneal defects.

Defects green with blue light.

May help locating FB.

Stains clothes – catch spills!