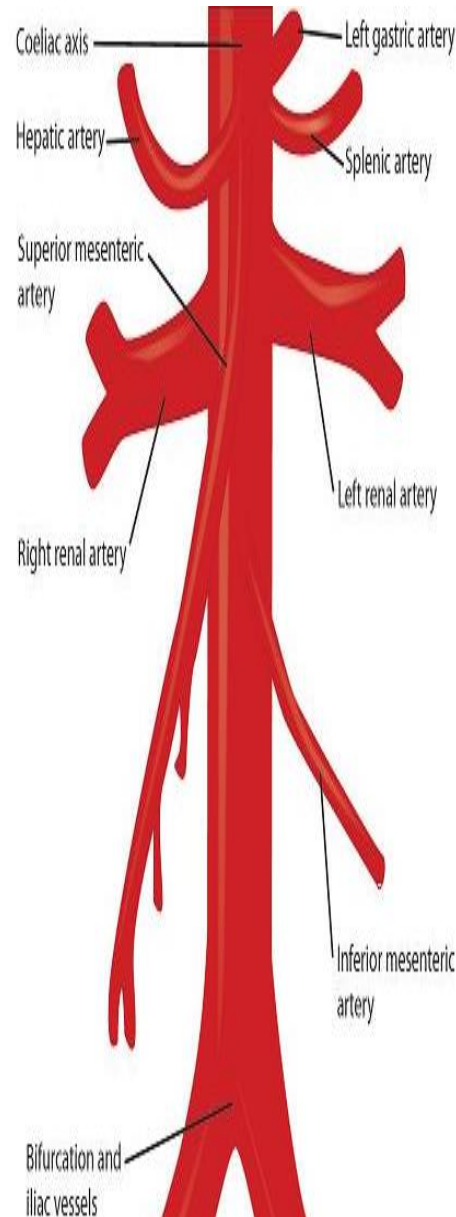
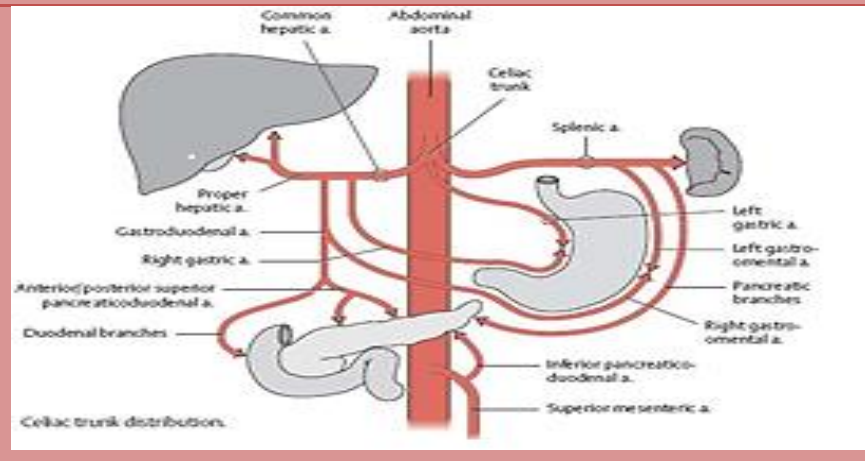


ABDOMINAL

ABDOMINAL BLOOD SUPPLY

Coeliac Trunk supplies the foregut

Artery	Branches	Supplies
Left Gastric		Oesophagus (lower) Stomach (Lesser curve)
Common Hepatic	Left & Right Hepatic	Liver
	Right Gastric	Stomach (Lesser curve)
	Gastroduodenal - S. Pancreaticoduodenal	Duodenum & Pancreas
	- Right Gastro-omental	Stomach (Greater curve) Greater Omentum
Splenic	Dorsal Pancreatic	Pancreas
	Short Gastrics	Stomach (Greater curve)
	Left gastro-omental	Stomach (Greater curve) Greater Omentum
	Greater Pancreatic	Pancreas (body & tail)



Superior Mesenteric supplies the midgut

Artery	Supplies
I. Pancreaticoduodenal	Pancreas (head) Duodenum
Intestinals	Ileum & Jejunum
Ileocolic*	Terminal ileum Caecum & Appendix
Right colic*	Ascending colon
Middle colic*	Transverse colon

Inferior Mesenteric supplies the hindgut

Artery	Supplies
Left colic*	Descending colon
Sigmoid branches	Sigmoid colon
S. rectal	Rectum

*These arteries anastomose to form the Marginal Artery which runs along the inferior surface of the
^Middle & Inferior Rectal arteries branch from internal iliac & internal pudendal arteries respectively

