

Case Study

Resolution of Chronic Constipation, Fecal Incontinence, and Abdominal Pain in an 8 Year Old Child Following Chiropractic Care: A Case Study & Selective Review of the Literature

H. Kala Eulitt, D.C.¹
Vivian Giannakakis, D.C.²

1. *Private Practice of Chiropractic, Conroe, TX*
2. *Private Practice of Chiropractic, New York, NY*

Abstract

Objective: To report on the resolution of symptoms of chronic constipation, fecal incontinence, and abdominal pain in an 8 year old male after undergoing chiropractic care.

Clinical Features: An 8 year old boy with a history of chronic constipation since birth with associated fecal incontinence and abdominal pain.

Interventions and Outcomes: Paraspinal thermography was used to assess the neurological component of the patient's vertebral subluxations and autonomic nervous system. Diversified technique, with high-velocity, low-amplitude adjustments, was administered to correct specific levels of vertebral subluxation. After 12 visits, the mother reported the patient having daily bowel movements with decreased abdominal pain. The patient was also able to voluntary control bowel movements.

Conclusions: The resolution of symptoms in a patient with chronic constipation, fecal incontinence, and abdominal pain was achieved after introducing chiropractic care to reduce vertebral subluxations. Further research on constipation and fecal incontinence in child and chiropractic is warranted.

Keywords: *chiropractic, constipation, vertebral subluxation, children, fecal incontinence, encopresis, Diversified technique, abdominal pain*

Introduction

In the general worldwide population, the prevalence of constipation ranges from 0.7% to 29.6% in children.¹ A study by Liem et al, which used the Medical Expenditure Panel Survey, found an estimated 1.7 million children in the United States reporting constipation in a 2 year period from 2003 to 2004.² According to a study done in February 2011, constipation accounts for 2.5 million physician visits annually in the United States, costing \$3362 per treated child.¹ Relative to the general pediatric population, children with constipation add approximately a \$3.9 billion cost to the US health care system.²

Constipation has been defined as a delay or difficulty in defecation, for 2 or more weeks.³ The normal frequency of bowel movements for children age 1-3 years is 4-21 movements per week, and 3-14 movements per week for children more than 3 years of age.³ A comprehensive history and digital rectal exam to determine rectal tone and impaction

of feces is used to formulate a diagnosis.⁴ If rectal exam is not possible, abdominal radiographs may be considered.⁴

Constipation among children must be differentially diagnosed as either organic or functional constipation. Organic causes may include Hirschsprung's disease, spinal cord abnormalities, metabolic causes, cystic fibrosis, congenital anorectal malformations, neurological disorders, cystic fibrosis, and heavy-metal poisoning.⁴ The North American Society for Pediatric Gastroenterology, Hepatology and Nutrition state functional, idiopathic constipation is "most commonly caused by painful bowel movements with resultant voluntary withholding of feces by a child who wants to avoid unpleasant defecation."³ It is the most common form of constipation in children, accounting for more than 95% of children older than one year.⁴

Accepted methods of treatment for constipation may include family education, behavioral therapy, laxatives, rectal suppositories, enemas, polyethylene glycol 3350, biofeedback therapy, and dietary changes including fiber supplementation and trial of withholding milk.³⁻⁵ Surgery is considered only in long standing constipation where medical therapy failed.⁵ Long term prognosis studies have shown that 30% to 50% of children continue to have intermittent constipation even after years of medical treatment.³

It is recognized within the pediatric population the coexistence of constipation and fecal incontinence. Fecal incontinence is defined as the voluntary or involuntary passage of feces into the underwear or in socially inappropriate places in a child of at least 4 years.⁶ This can be further differentiated as constipation-associated fecal incontinence or functional fecal incontinence, and non-retentive fecal incontinence. According to Nurko and Scott, functional fecal incontinence occurs secondary to “overflow” from fecal compaction.⁶

Nurko and Scott report that 1-4% of school age children present with functional fecal incontinence.⁶ Moreover, fecal incontinence was found in >85% of children with a diagnosis of fecal impaction, and is more frequent in boys than girls.^{6,7} A study conducted by Loening-Baucke, which included 482 children, found the prevalence rate of fecal incontinence to be 4.4% in which 95% was associated with “fecal incontinence with constipation.”⁸ In general, successful treatment of constipation, such as those involving laxatives, will control the coexisting fecal incontinence.⁶ However, Nurko and Scott propose that fecal incontinence can be a common side effect of laxatives and should be taken into account when treating a child with constipation.⁶

The purpose of this paper is to report the chiropractic management of an 8 year old boy presenting with complaints of chronic constipation and associated fecal incontinence.

Case Report

History

Patient is an 8 year old male with a history of chronic constipation since birth. He would have a bowel movement once a week with an associated involuntary release of fecal material when he did. The patient also experienced severe abdominal pain due to his constipation. He refrained from outside activities and did not enjoy recess at school due to his discomfort. The mother received weekly calls from his school reporting “accidents” he would have.

The mother reported no complications during pregnancy and delivery. He was born two weeks early at 7.11 lbs and 22 inches length. She breast feed until one year of age and introduced solid foods at 6 months. She also reported he had no previous history of injuries or trauma.

The patient was seen by his pediatrician and a gastroenterologist. The patient was administered medications for his condition however they did not resolve his symptoms. An x-ray of the lower GI was performed but failed to demonstrate a cause. The next step of treatment suggested was exploratory surgery; however the mother did not want that to

happen.

Examination

At the time of examination the patient was an 8 year old male that appeared reserved and quiet. Range of motion of the spine was within normal limits. Motion palpation revealed restricted segments within the cervical, lumbar and sacral regions. Radiographs were taken of the cervical, thoracic, and lumbar spine to rule out any pathological processes. An anterior head carriage was viewed in the cervical spine with no other findings.

Paraspinal thermography scans were performed on the patient that revealed severe dysautonomia at C1, T9, T10, and T12-L5 shifted to the right. Also, moderate dysautonomia at T2, T8, T11 and mild dysautonomia at T1 were present. (See Figure 1)

Paraspinal thermography has been used to determine overall autonomic function, and detect any abnormalities.⁹ Alterations in skin temperature patterns indicate dysfunction of the sympathetic nerves innervating the vascular beds of the skin.⁹ Thermal scans are analyzed according to standard deviations from normal that range from mild, moderate to severe. Mild asymmetry is 1 to 2 standard deviations. Moderate asymmetry is 2 to 3 standard deviations, and severe asymmetry is greater than 3 standard deviations. These are also identified by color bars of green, blue, and red respectively. Asymmetries are referred to as differences between left and right of the spine. McCoy et al. have determined excellent evidence of inter-examiner and intra-examiner reproducibility using commercially available paraspinal thermography.⁹

Intervention

Following the initial examination the patient was advised to be seen 3 times a week for two months. Dietary changes to increase water intake and decrease sugars were also recommended. Adjustments were administered using Diversified technique with high-velocity, low-amplitude (HVLA) thrusts. Specific vertebral levels of subluxation in the cervical, thoracic, lumbar, and sacral regions were adjusted at different times throughout care. Good describes “Diversified technique” as a collection of spinal adjustments, discovered by various practitioners, that all utilize a “prestress” to tissues in order to obtain joint tension to determine which joints will be affected by the thrust administered.¹⁰ Diversified technique is a commonly used technique among chiropractic practitioners. A survey by Mykietiuik et al. showed that 86% of post graduate practitioners selected Diversified technique when asked which technique system they used primarily for patient care.¹¹

Cervical adjustments were administered with the patient lying supine. The contact point was taken on the side of involvement while the other hand stabilized the opposite side of the head. The HVLA thrust was given with the head lateral flexed toward and rotated away from the contact point. Thoracic adjustments were administered with the patient prone on the table. Contact was taken with bilateral thenar or crossed pisiform over the thoracic transverse processes. The thrust would be given in an anterior and superior direction. Lumbar and sacral adjustments were given with the patient lying on

there side with their top knee bent and bottom leg straight. The patient was rolled toward the doctor with the superior hand stabilizing the patient and the inferior hand used to contact the segment.

An electrical percussive instrument was used to stimulate and massage the abdominal wall of the patient approximately four times over the course of initial treatment. Research shows that abdominal massage can help relieve symptoms of constipation by stimulating peristalsis and increasing frequency of bowel movement.¹²⁻¹⁴ A randomized control trial conducted by Lamas et al. concluded abdominal massage to be effective in significantly decreasing gastrointestinal symptoms and increasing frequency of stool.¹⁴ However, they reported the massage did not lead to decrease laxative intake and should be used as a complement to treatment.¹⁴

Outcome

After 12 visits, another paraspinal thermal scan was performed. Results showed a dramatic decrease in dysautonomia as compared to the original scan with only a mild left deviation at L3. (See Figure 2) The patient's mother reported he was having regular bowel movements daily and no longer had associated abdominal pain. He also no longer had symptoms of fecal incontinence and reports from his school of such "accidents" ceased. After several more visits of care the mother reported the child enjoyed outdoor activities and playing sports such as soccer. The patient continued to maintain regular chiropractic care.

Discussion

Chiropractic Literature

There are several reports within the literature that show favorable outcomes in constipation secondary to chiropractic care. A search of the chiropractic literature revealed 17 previous cases that reported on constipation, two of which reported with associated fecal incontinence. Moreover, another two cases were found solely on fecal incontinence also known as encopresis. Of these cases, age ranged from 2 weeks of age to 64 years of age with 12 cases being female. Techniques used included Chiropractic biophysics, Thompson, Diversified, Logan basic, Activator, Cranial, Gonstead, Upper Cervical and Grostic. Table 1 outlines the clinical characteristics of these previous reports.

Marko reported on a case of a 10 month old female with a complaint of constipation since 6 months of age due to change in diet from breastfeeding to solid foods. The child's parents stated she would have one bowel movement every week to ten days. Chiropractic Biophysics technique was administered for care and results showed a decreased in symptoms with the child having regular bowel movements after two weeks of care.¹⁵ Marko also described a case of a seven year old female that presented with constipation, asthma, and headaches. Adjustments were given according to chiropractic biophysics technique that resulted in successful management of symptoms.¹⁶

Quist and Duray reported on an 8 year old male with complaint of chronic constipation since birth. Treatment

included sacral adjustments using a drop adjustment and external manual massage of the abdomen. The patient saw immediate results with resolution of symptoms after a month of care.¹⁷

Hewitt reported a 7 month old female with chronic constipation that was treated with cranial and spinal adjustments. After 8 weeks from initial treatment, her mother reported the child having one to two consistent bowel movements per day.¹⁸ A case by Ericksen reported the significant improvement of bowel function in a five year old female with chronic constipation after the administration of Grostic upper cervical technique.¹⁹

Killinger and Azad described a case of 11 month old male with complaints of colic, constipation, restless sleep and developmental delays. Upper cervical adjustments were administered on a Toggle-Recoil table. The parents reported, after 10 days, the child began having bowel movements without the aid of enemas.²⁰ Gossett reports a case of a 13 year old female presenting with neck and back soreness after an automobile accident. The child was also diagnosed with Rett Syndrome and reported only 1-2 bowel movements per week. The mother reported the child experiencing regular bowel movements during the course of 12 weeks of care.²¹ Hunt reports of a 3 month old female with irregular bowel function. The child would go up to more than one week without any bowel movement. The parents were advised to administer suppositories to stimulate defecation by their pediatrician. Upper cervical adjustments were administered using the Laney instrument. At the sixth visit the parents reported no complaints of irregular bowel habits.²²

Batte described a case of a two week old male with symptoms of colic, constipation, and sleep disturbance. He reported the successful resolution of symptoms of constipation after chiropractic treatment using Logan Basic technique and cervical adjustments.²³ Horkey described treatment of spinal adjustments and dietary recommendations to a 6 year old female with complaints of chronic constipation and neck pain. He reported successful resolution of symptoms after 13 visits of care.²⁴ Swaminathan and Hanson described a five month old female with constipation, gastroesophageal reflux and deformational plagiocephaly. After treatment of spinal and cranial adjustments, the patient's symptom of constipation resolved at 9 months of age.²⁵

A case series by Alcantara and Mayer showed improved results of chronic constipation with chiropractic care in three children. The first case was of a 21 month old male with complaint of constipation since birth that reported resolution of symptoms after 2 months of care. The second case was a 7 month old female that had a complaint of constipation since 2 moth of age. The patient's mother reported immediate results after the first treatment. The third case was a 21 month old female with complaint of constipation and encopresis since 10 months old that reported immediate results with resolution of symptoms after 3 months of care.²⁶

Ressel and Rudy conducted a study of the analysis of 650 children under chiropractic care. The authors suggested a correlation between the subluxation and somatic, visceral and immune complaints. They found 96 % of the children had

subluxations within the pelvis. The incidence of constipation/diarrhea among the children was 12.9% with a larger percentage occurring in toddler year.²⁷

A review of the literature by Holbrook, revealed chiropractic care may be an effective treatment for childhood constipation. However, the author stated the study was limited on a few number of cases making it hard to generalize the effectiveness of chiropractic care for this condition.²⁸

The effect of chiropractic care on the symptoms of constipation has also been cited in the adult population. Redly describes a 64 year old female with chronic constipation. The patient reported regular and consistent bowel movements after several weeks of care.²⁹ Falk reported of a 40 year male with lumbar spine pain radiating into the left thigh and associated constipation since onset of pain. He was treated with low volt sign wave, manual muscle stimulation, and adjustment to L5. Patient reported regular bowel movements after 3 days of care.³⁰

According to Nurko and Scott, fecal incontinence in children is frequently described by terms of “encopresis” and “fecal soiling”.⁶ There are very limited studies within the chiropractic literature on fecal incontinence.

Patterson described a seven year old male with encopresis where medical treatment showed no improvement of symptoms. The child was adjusted in the cervical and lumbar spine and given dietary recommendations. After one month of care his mother reported significant improvement in symptoms and had discontinued all of the child’s medications.³¹ Barber and Ring describe a 6 year old female with fecal incontinence since age 3. There was relief of symptoms with the administration of cervical and lumbar adjustments. The patient experienced rapid return of symptoms when discontinuing care and recurring relief of symptoms when returning for care.³²

Kamrath reported a 5 year old boy with both urinary and fecal incontinence with prior surgery for the correction of lumbar meningocele, spinal lipoma, and tethered spinal cord. The child’s treatment included adjustments with the Activator adjusting instrument and shortwave diathermy to the sacrum and lumbar spine. After 5 visits results showed significant improvement of symptoms.³³

Chiropractic Mechanism

Gastrointestinal function is controlled by the autonomic nervous system in a balance between sympathetic and parasympathetic stimulation. Holbrook acknowledged that the sympathetic nervous system decreases peristalsis activity causing vasoconstriction of the gut and sphincter contraction, while the parasympathetic nervous system does the opposite.²⁸ Tougas stated increased sympathetic activity or decreased vagal tone is associated with decreased gastrointestinal motility.³⁴

Kent and Seaman discuss dysafferentation as a model of subluxation offering a link between the vertebral subluxation causing an increase in stress to the sympathetic nervous system.^{35,36} Biomechanical dysfunction can cause alteration in nociception and mechanoreception input causing aberrant

afferent input to the central nervous system. Kent states “if afferent input is compromised, efferent response may be qualitatively and quantitatively compromised”.³⁵

Similarly, Korr proposes that every motor activity also involves the simultaneous, coordinated activity of the sympathetic nervous system and the tissues and processes regulated by it.³⁷ His theory proposes that somatic dysfunction presents a bombardment of altered afferent impulses that produces increased facilitation of neuronal pathways. This can cause hyperactivity of the sympathetic nervous system. Thus, segmental somatic dysfunction can produce functional changes in viscera.³⁷

Chiropractic adjustments remove somatic dysfunctions by restoring proper biomechanical motion between intervertebral segments. Therefore, afferent pathways are stabilized, decreasing sympathetic stimulation and alleviating related visceral symptoms such as constipation. Although it is too generalized to state chiropractic can cure constipation or fecal incontinence, there is a suggested relation.

Conclusion

This case reports on the successful resolution of symptoms of a child with chronic constipation and fecal incontinence through chiropractic care. Subluxations were detected and corrected to restore proper biomechanical and neurological function. This case contributes to an already existing body of case studies within the chiropractic literature. However, further research is warranted in the efficacy of chiropractic care on children with chronic constipation and fecal incontinence.

References

1. Mugie SM, Benninga MA, Di Lorenzo C. Epidemiology of constipation in children and adults: a systematic review. *Best Pract Res Clin Gastroenterol.* 2011 Feb;25(1):3-18.
2. Liem O, Harman J, Benninga M, Kelleher K, Mousa H, Di Lorenzo C. Health utilization and cost impact of childhood constipation in the United States. *J Pediatr.* 2009 Feb;154(2):258-62.
3. Constipation Guideline Committee of the North American Society for Pediatric Gastroenterology, Hepatology and Nutrition. Evaluation and treatment of constipation in infants and children: recommendations of the North American Society for Pediatric Gastroenterology, Hepatology and Nutrition. *J Pediatr Gastroenterol Nutr.* 2006 Sep;43(3):e1-13.
4. Biggs WS, Dery WH. Evaluation and treatment of constipation in infants and children. *Am Fam Physician.* 2006 Feb 1;73(3):469-77.
5. Rajindrajith S, Devanarayana NM. Constipation in children: novel insight into epidemiology, pathophysiology and management. *J Neurogastroenterol Motil.* 2011 Jan;17(1):35-47.
6. Nurko S, Scott SM. Coexistence of constipation and incontinence in children and adults. *Best Pract Res Clin Gastroenterol.* 2011 Feb;25(1):29-41.

7. Dobson P, Rogers J. Assessing and treating faecal incontinence in children. *Nurs Stand*. 2009 Sep 16-22;24(2):49-56.
8. Loening-Baucke V. Prevalence rates for constipation and faecal and urinary incontinence. *Arch Dis Child*. 2007 Jun;92(6):486-9. Epub 2006 Jul 20.
9. McCoy M, Campbell I, Stone P, Fedorchuk C, Wijayawardana S, Easley K. Intra-examiner and inter-examiner reproducibility of paraspinal thermography. *PLoS One*. 2011 Feb 11;6(2):e16535.
10. Good CJ. An analysis of diversified (legeartis) type adjustments based upon the assisted-resisted model of intervertebral motion unit prestress. *Chiropr Tech*. 1992 Nov;4(4):117-123.
11. Mykietiuik C, Wambolt M, Pillipow T, Mallay C, Gleberzon BJ. Technique Systems used by post-1980 graduates of the Canadian Memorial Chiropractic College practicing in five Canadian provinces: a preliminary survey. *J Can Chiropr Assoc*. 2009 Mar;53(1):32-9.
12. McClurg D, Lowe-Strong A. Does abdominal massage relieve constipation? *Nurs Times*. 2011 Mar 29-Apr 4;107(12):20-2.
13. Lämås K. Using massage to ease constipation. *Nurs Times*. 2011 Feb 1-7;107(4):26-7.
14. Lämås K, Lindholm L, Stenlund H, Engström B, Jacobsson C. Effects of abdominal massage in management of constipation—a randomized controlled trial. *Int J Nurs Stud*. 2009 Jun;46(6):759-67.
15. Marko SK. Case study: the effect of chiropractic care on an infant with problems of constipation. *Chiropr Pediatr*. 1994 Dec;1(3):23-24.
16. Marko SK. Case study: seven year old female with asthma, constipation and headaches among other symptoms. *Chiropr Pediatr*. 1998 Oct;4(1):14-15.
17. Quist DM, Duray SM. Resolution of symptoms of chronic constipation in an 8-year-old male after chiropractic treatment. *J Manipulative Physiol Ther*. 2007 Jan;30(1):65-8.
18. Hewitt EG. Chiropractic treatment of a 7-month-old with chronic constipation: a case report. *Chiropr Tech*. 1993 Aug;5(3):101-103.
19. Eriksen K. Effects of upper cervical correction on chronic constipation. *CRJ*. 1994; 3(1):19-22.
20. Killinger LZ, Azad A. Chiropractic care of infantile colic: a case study. *J Clin Chiropr Pediatr*. 1998 Aug;3(1):203-206.
21. Gossett LJ. The effect of chiropractic care on Rett Syndrome: a case report. *J Clin Chiropr Pediatr*. 1999 May;4(1):248-252.
22. Hunt JM. Upper cervical chiropractic care of an infant with irregular bowel function: a case study. *J Clin Chiropr Pediatr*. 2000;5(1):312-314.
23. Batte S. Resolution of colic, constipation and sleep disturbance in an infant following chiropractic care to reduce vertebral subluxation. *J Pediatr Matern & Fam Health - Chiropr*. 2010 Win;2010(1):Online access only p 1-5.
24. Horkey M. Resolution of chronic constipation and neck pain following chiropractic care in a 6-year-old female. *J Pediatr Matern & Fam Health - Chiropr*. 2010 May 10;2010(2):51-55.
25. Swaminathan R, Hanson L. Improvement in a child with gastroesophageal reflux disease, constipation, and deformational plagiocephaly undergoing chiropractic care. *J Pediatr Matern & Fam Health - Chiropr*. 2011 Jan 28; 2011(1):9-13.
26. Alcantara J, Mayer DM. The successful chiropractic care of pediatric patients with chronic constipation: a case series and selective review of the literature. *Clin Chiropr*. 2008 Sep;11(3):138-147.
27. Ressel O, Rudy R. Vertebral subluxation correlated with somatic, visceral and immune complaints: an analysis of 650 children under chiropractic care. *J Vert Sublux Res*. 2004 ;OCT(18):Online access only 23 p.
28. Holbrook B. Chiropractic treatment of childhood constipation: A review of the literature. *J Clin Chiropr Pediatr*. 2005 ;6(3):427-431.
29. Redly M. The effects of chiropractic care on a patient with chronic constipation. *J Can Chiropr Assoc*. 2001; 45(3): 185-191.
30. Falk JW. Bowel and bladder dysfunction secondary to lumbar dysfunctional syndrome. *Chiropr Tech*. 1990 May;2(2):45-48.
31. Patteron D. Encopresis in a seven-year-old: a case study. *Res Forum*. 1986 Spr;2(3):79-82.
32. Barber VA, Ring TS. Encopresis: A case study of the response of pediatric fecal incontinence while under chiropractic care. *Top Clin Chiropr*. 2002 Mar;9(1):68-72.
33. Kamrath KR. Chiropractic management of a 5-year-old boy with urinary and bowel incontinence. *J Chiropr Med*. 2010 Mar;9(1):28-31.
34. Tougas G. The autonomic nervous system in functional bowel disorders. *Gut*. 2000 Dec;47 Suppl 4:iv78-80.
35. Kent C. Models of vertebral subluxation: a review. *J Vert Sublux Res*. 1996 ;1(1):11-17.
36. Seaman DR, Winterstein JF. Dysafferentation: a novel term to describe the neuropathophysiological effects of joint complex dysfunction. A look at likely mechanisms of symptom generation. *J Manipulative Physiol Ther*. 1998 May;21(4):267-80.
37. Korr IM. The spinal cord as organizer of disease processes: some preliminary perspectives. *J Am Osteopath Assoc*. 1976 Sep;76(1):35-45.

Table 1 Clinical Characteristics of Previous Reports					
Author	Age	Sex	Chief Complaint	Technique	Regular BM*
Marko ¹⁵	10 mo.	Female	Constipation	Chiropractic Biophysics	2 weeks
Marko ¹⁶	7 yr.	Female	Constipation, Asthma, Headaches	Chiropractic Biophysics	2 visits
Quist & Duray ¹⁷	8yr.	Male	Chronic Constipation	Thompson Drop	1 month
Hewitt ¹⁸	7 mo.	Female	Chronic Constipation	Diversified, Cranial	3 visits
Ericksen ¹⁹	5 yr.	Female	Chronic Constipation	Grostick Upper Cervical	2 visits after last fall
Killinger & Azad ²⁰	11 mo.	Male	Colic, Constipation, Sleep Disturbances	Toggle Upper Cervical	10 days
Gossett ²¹	13 yr.	Female	Rett Syndrome, Neck pain, Constipation	Diversified	12 weeks
Hunt ²²	3 mo.	Female	Irregular Bowel Function	Upper Cervical	6 visits
Batte ²³	2 wk.	Male	Constipation, Colic, Sleep Disturbance	Logan Basic	5 visits
Horkey ²⁴	6 yr.	Female	Chronic Constipation, Neck Pain	Diversified	13 visits
Swaminathan & Hanson ²⁵	5 mo.	Female	GERD, Constipation, Plagiocephaly	Sustained Contact, Cranial	4 months
Alcantara & Mayer ²⁶	21 mo.	Male	Chronic Constipation	Diversified, Activator	2 months
Alcantara & Mayer ²⁶	7 mo.	Female	Constipation	Activator	2 visits
Alcantara & Mayer ²⁶	21 mo.	Female	Constipation, Encopresis	Diversified	3 mo.
Redly ²⁹	64 yr.	Female	Chronic Constipation	Diversified	5 weeks
Falk ³⁰	40 yr.	Male	Low Back Pain, Sciatica, Constipation	Diversified	2 visits
Barber & Ring ³²	6 yr.	Female	Encopresis, Constipation	Diversified, Thompson	20 months
Patterson ³¹	7 yr.	Male	Encopresis	Diversified, Gonstead	10 months
Kamrath ³³	5 yr.	Male	Bowel and Bladder Incontinence	Activator	5 visits

*BM Bowel Movement

Figure 1- Thermal- Pre Scan

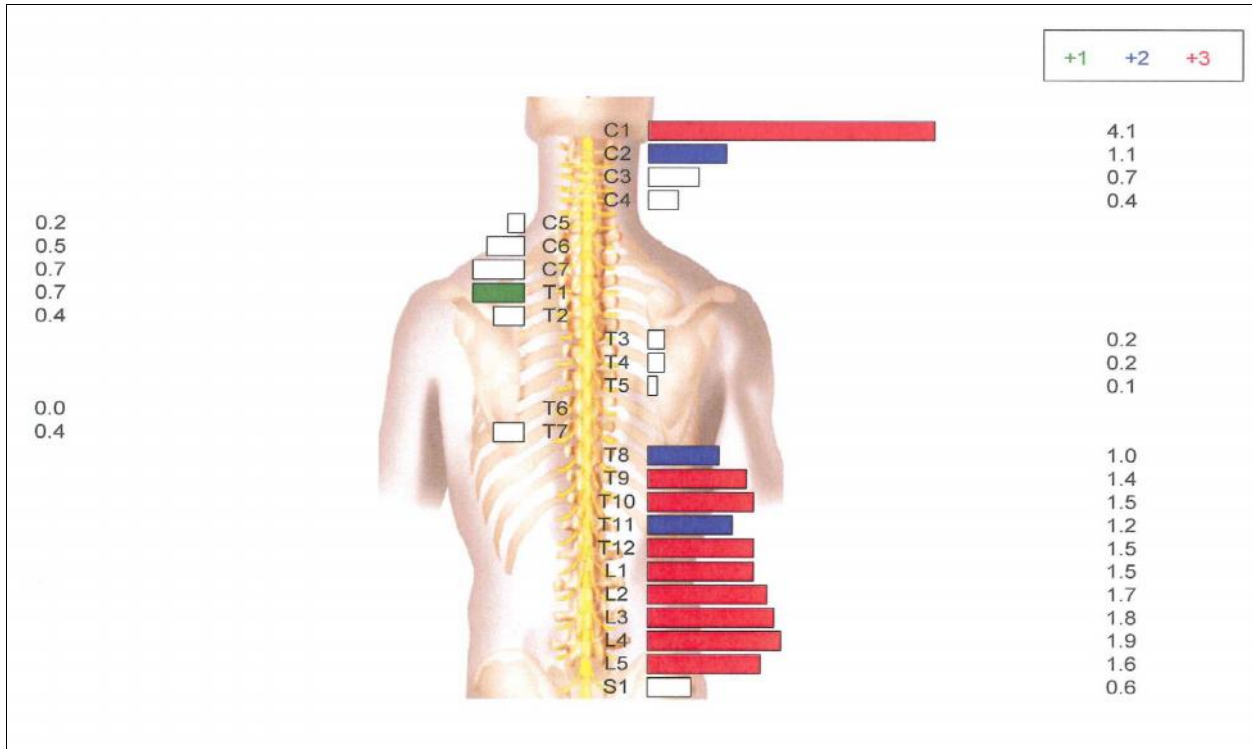


Figure 2- Thermal- Post Scan

