


**AOS**<sup>TM</sup>

ADVANCED ORTHOPAEDIC SOLUTIONS

*Antegrade*



*Magellan*<sup>TM</sup>

FEMORAL NAIL SYSTEM

*Surgical Technique*

Advanced Orthopaedic Solutions  
3203 Kashiwa Street  
Torrance, CA 90505

T: 310.533.9966  
F: 310.533.9876  
[www.aosortho.com](http://www.aosortho.com)



P/N: 9076 Rev B  
©2016 Advanced Orthopaedic Solutions. All rights reserved.



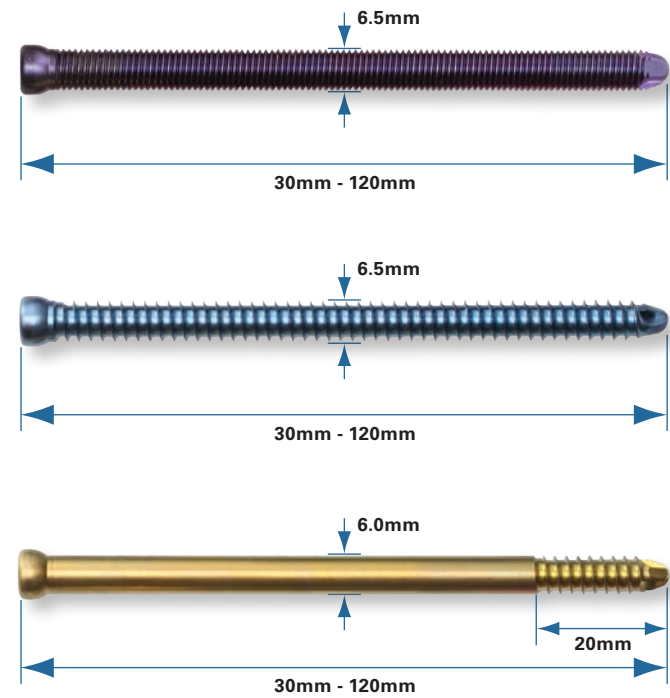
# Contents

IMPLANT FEATURES	2
1. INDICATIONS	3
2. PRE-OPERATIVE PLANNING	3
3. PATIENT POSITIONING	3
4. INCISION	4
5. ENTRY POINT	4
6. GUIDE WIRE INSERTION & FRACTURE REDUCTION	5
7. NAIL SELECTION	5
8. NAIL ASSEMBLY AND INSERTION	6
9. PROXIMAL TARGETING (TRANSVERSE INTERLOCKING)	8
10. PROXIMAL TARGETING (RECONSTRUCTION INTERLOCKING)	12
11. SCREW INSERTION	14
12. PROXIMAL TARGETING (ANTEGRADE INTERLOCKING)	16
13. DISTAL TARGETING - FREEHAND TECHNIQUE	17
14. END CAP INSERTION	18
15. POSTOPERATIVE CARE	18
16. NAIL EXTRACTION	18


This Surgical Technique sets forth detailed recommended procedures for using AOS devices and instruments. It offers guidance, but as with any such technical guide, each surgeon must consider the particular needs of each patient and make appropriate adjustments when and as required. Surgeons must always rely on their own professional clinical judgement when deciding which products and surgical treatments to use with their patients. Refer to package insert for information on indications, warnings, precautions and contraindications.

# Antegrade Implant Features

## Captured Cortical and Cancellous Screws (Proximal)



## Captured Cortical Bone Screw (Proximal and Distal)



## Locking Spacer



## Captured End Caps

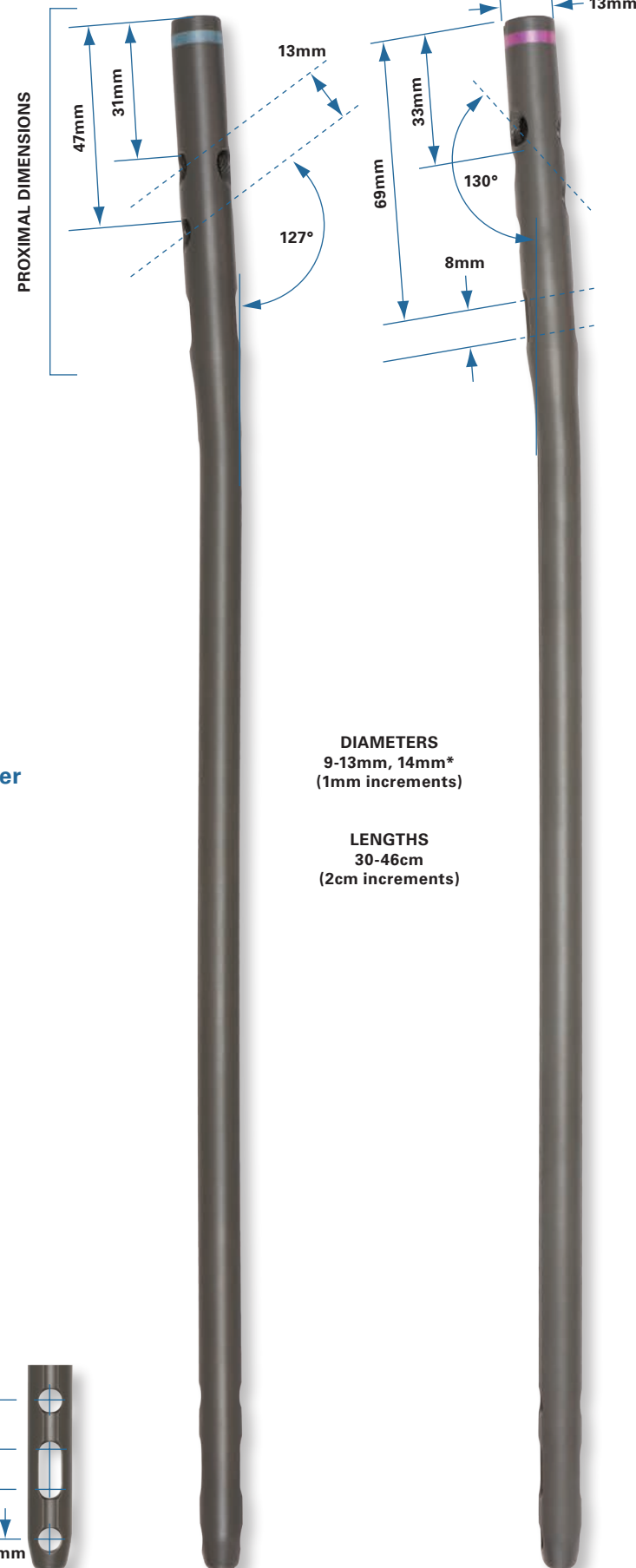


## Recon Locking End Cap



## Left Nail

## Right Nail



\* Special Request

# Magellan™ Antegrade Femoral Nail System Surgical Technique

## 1. Indications

The AOS Antegrade Femoral Nail is intended for use in intramedullary fixation of fractures of the femur to include the following:

- Open and closed femoral fractures
- Pseudoarthrosis and correction osteotomy
- Pathologic fractures, impending pathologic fractures, and tumor resections
- Bone lengthening
- Fractures proximal to a total knee arthroplasty or prosthesis
- Proximal/subtroch with intertroch extension
- Nonunions and malunions
- Fractures resulting from osteoporosis

## 2. Preoperative Planning

Preoperative planning is recommended before beginning the surgical procedure. A/P and Lateral x-rays of the injured femur should be taken preoperatively and evaluated for nail length, canal size, expected amount of reaming, and screw length. A/P and Lateral x-rays of the contralateral uninjured femur can also be used to provide insight into the anatomy of the pre-injured femur.

## 3. Patient Positioning

The patient should be positioned in a supine position on a fracture table or radiolucent table (Fig. 1 and Fig. 2). A bump should be placed beneath the patient's trunk, just above the iliac crest to allow greater access to the incision site. The use of a fracture table can be beneficial during fracture reduction by providing in-line traction and facilitating intraoperative imaging with a C-arm (Fig.1). The C-arm should be positioned to allow for imaging of the femur in both planes along the entire length of the bone. If reconstruction screws are planned, the C-arm must allow for lateral imaging of the femoral head and neck. Adduction of the femur can be helpful when locating the appropriate entrance point.

Drape the patient appropriately to allow the surgeon to work from the hip to just below the knee.



Fig. 2

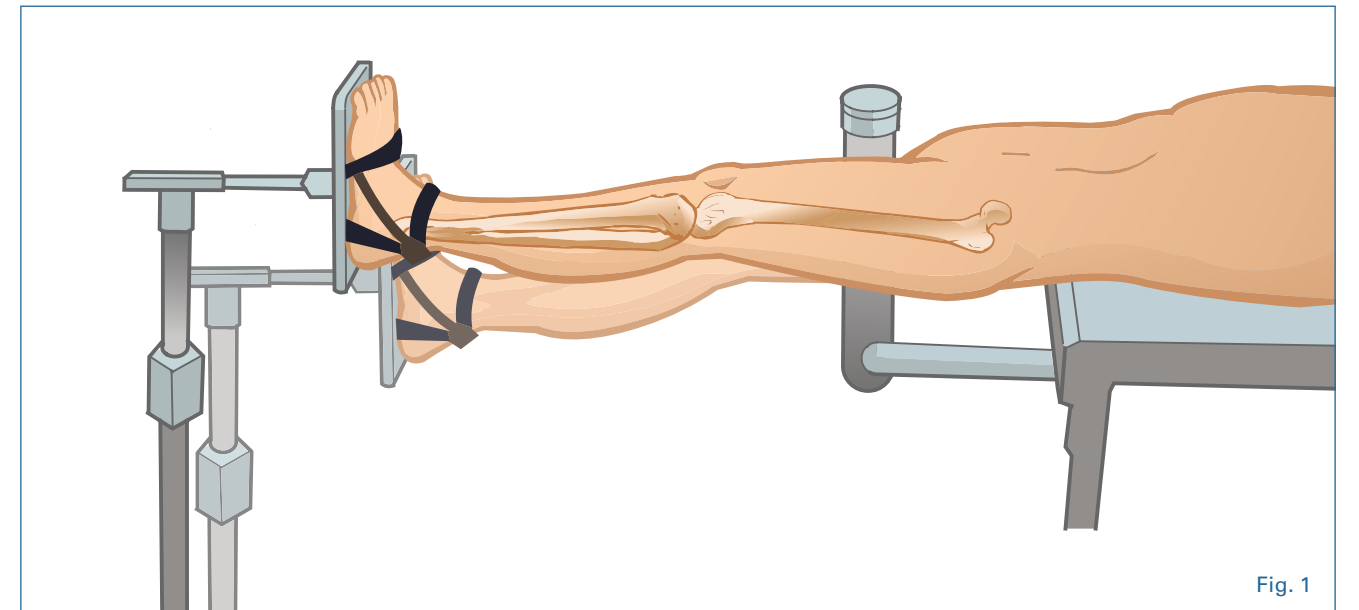


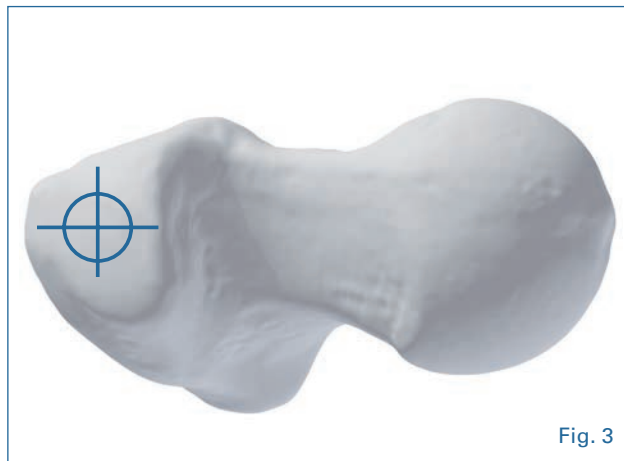
Fig. 1

#### 4. Incision

Make a 3-5cm skin incision depending on the size of the patient, proximal to the greater trochanter. The incision is carried down through the skin and subcutaneous tissue. Then, split the tensor fascia in line with its course.

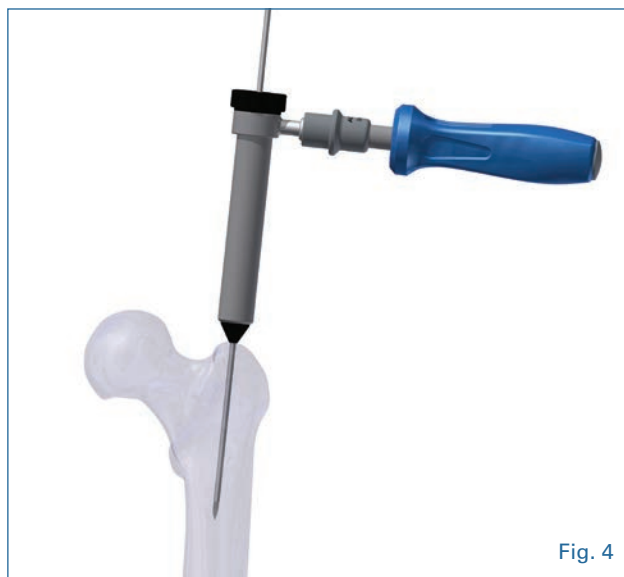#### 5. Entry Point

The entry point for the nail is located on the greater trochanter (Fig. 3). On the A/P image, the starting point should be on the tip of the greater trochanter. On the lateral image, the starting point should be near the junction of the anterior and middle third of the greater trochanter, as seen on a lateral C-arm image.



#### Option 1:

Place the **3.2mm Pin Guide** and **Soft Tissue Protector** through the incision. Align the soft tissue protector in line with the femoral shaft on the A/P and lateral image views. Insert a

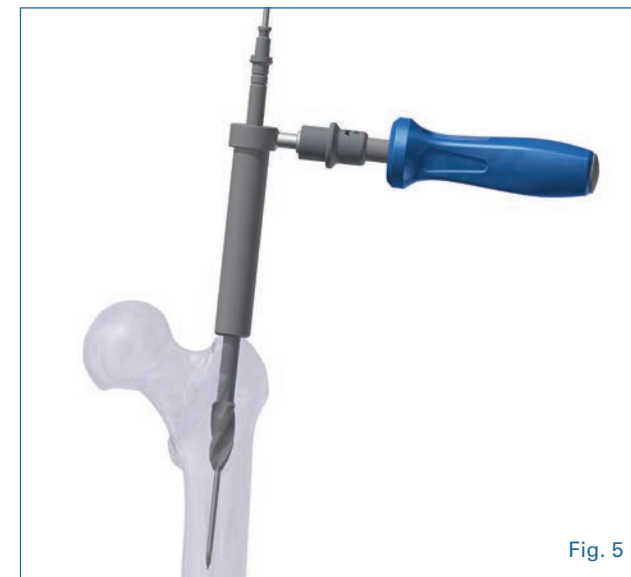

**3.2mm Guide Pin** through the tip of the greater trochanter down the level of the lesser trochanter, aligning it with the femoral shaft in the A/P and lateral image views (Fig. 4).

Place the **13.5mm Cannulated Entry Reamer** over the **Guide Pin** and ream the proximal fragment of the femur through the soft tissue protector (Fig. 5). This leaves 0.5mm clearance around the proximal portion of the nail. The entry reamer has depth indication grooves which are read from the top of the soft tissue protector. The depth grooves allow for the nail to be placed flush or 5.0mm deep. The C-arm should be used to visualize the depth of the reamer in the proximal femur. Care should be taken to keep the reamer in line with the shaft of the femur to avoid reaming through the medial or the posterior cortices of the femur.

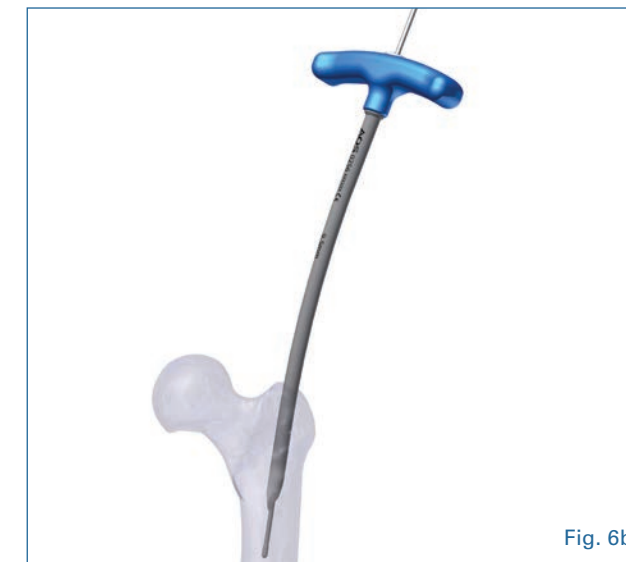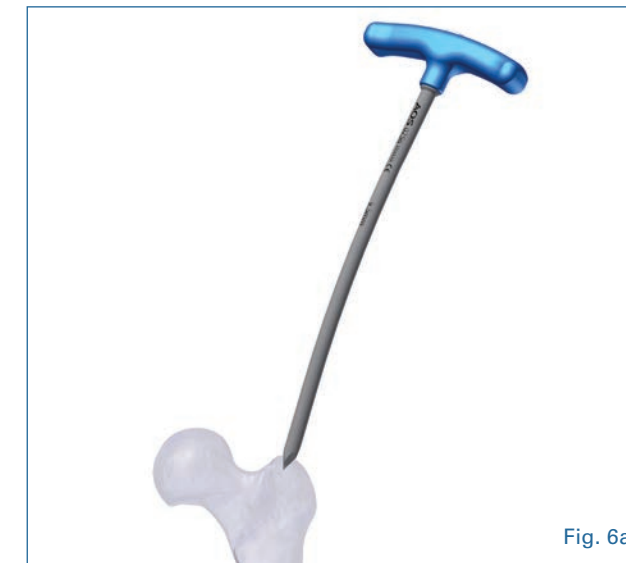#### NOTE: For use of a 14.0mm Antegrade Femoral Nail

The 14.0mm diameter femoral nail has a proximal diameter of 14.0mm. If this nail size is required, a shaft reamer should be used over the guide wire to create a proximal opening of at least 14.0- 14.5mm in diameter. This will allow the head of the nail to be safely inserted into the bone, without causing damage to the proximal femur.



#### Option 2:

Alternatively, the surgeon may open the greater trochanter with a **Cannulated Curved Awl** followed by a **3.0mm Ball Nose Guide Wire** that is placed through the curved awl down to the desired depth (Fig. 6a and 6b). The curved awl is then removed from the bone allowing the guide wire to stay properly positioned.

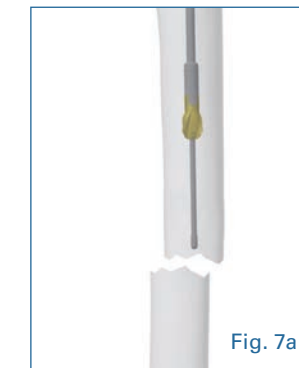


#### 6. Guide Wire Insertion and Fracture Reduction

It is critical to achieve anatomic reduction before beginning any of the steps to place the nail. Traction should be used as necessary to help achieve fracture reduction.

To assist in fracture reduction, a **Curved Reduction Tool** can be utilized. Introduce the **3.0mm Ball Nose Guide Wire** by means of the **Guide Wire Gripper** to the level of the fracture (Fig. 7a). Confirm its containment within the femur by means of A/P and lateral views. Insert the **Curved Reduction Tool** over the guide wire down to the level of the fracture and reduce the proximal fragment to the distal fragment. Advance the guide wire across the fracture until it is centered within the distal fragment (Fig. 7b). Verify containment of the guide wire within the femur with image intensification.

**NOTE:** It may be necessary to utilize flexible reamers to accommodate insertion of the **9.5mm Curved Reduction Tool** into the proximal femur. Use flexible reamers to open up the intramedullary canal down to the level of the fracture.

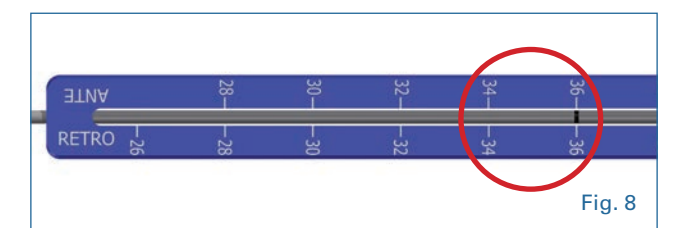


For reamed applications use the **Flex Shaft and Reamer Heads (9.5mm-16.5mm)** over the **3.0mm Ball Nose Guide Wire**. Ream the entire femur in 0.5mm increments until a desired diameter of at least 1.0-1.5mm larger than the anticipated nail diameter is achieved. The **3.6mm Obturator** can help prevent the guide wire from backing out of the femur during reaming.

**NOTE: Never insert a nail that has a larger diameter than the last reamer used.**

#### 7. Nail Selection

The proper nail length is determined by sliding the **Guide Wire Depth Gauge** over the guide wire down to the greater trochanter and reading the appropriate length directly from the calibrated line on the guide wire (Fig. 8). Alternatively, a **Radiographic Ruler** used with the C-arm may be used to estimate nail length.



## 8. Nail Assembly and Insertion

If a static transverse hole or controlled intraoperative compression is desired in the proximal segment of the nail, a **Compression Spacer** should be inserted using a **5.0mm Compression Hex Driver** and **T-Handle**, prior to nail assembly onto the targeting guide.

Attach the **Antegrade Radiolucent Targeting Guide** to the nail using the **T-Handle** and **Ball Hex Driver** (Fig. 9a). Note the correct orientation of the targeter with red and blue color-coded sides. The **Impactor Pad** should be used if impaction is necessary.

The antegrade nails have color-coded bands to indicate the

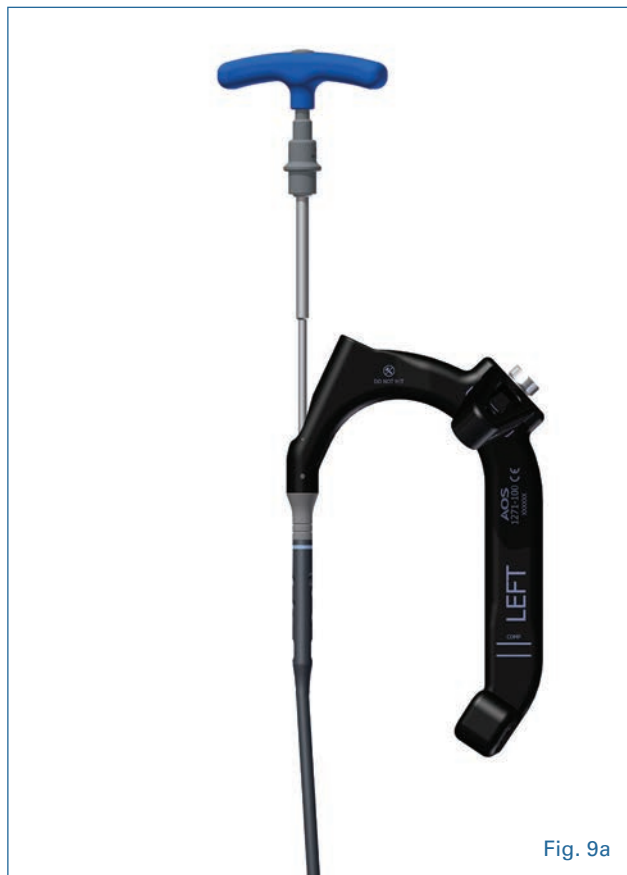

Fig. 9a



Fig. 10



Fig. 9b



Fig. 9c

**NOTE:** Line the arrow on the targeter with the correct label on the **Antegrade Targeting Module** (L for Left and R for Right).

Introduce the nail into the proximal femur using the **Antegrade Radiolucent Targeting Guide**. If a guide wire is used, pass the nail over the guide wire (Fig. 11). If the nail does not enter the femur easily, apply a gentle blow to the **Impactor Pad** with the use of a mallet. It is very important to **NEVER HIT** directly on the radiolucent targeting guide. Monitor the progression of the nail using the C-arm, especially as the nail is passing through or near the fracture site.

**NOTE:** Avoid the use of excessive force when inserting the nail, which may produce comminution of the femoral shaft.

If the nail will not advance with impaction, remove the nail and ream the canal to a larger diameter in 0.5mm increments or consider using a smaller diameter nail. Place the top of the nail in line with or below the surface of the entry point, depending on the anticipated interlocking screw location.

Remove the ball tip guide wire from the nail using the **Guide Wire Gripper**. If possible, the guide wire should be removed before the nail is completely seated to reduce the potential of the wire getting caught in the nail. If the wire is difficult to remove, rotate the wire 90° with the guide wire gripper while pulling the wire.

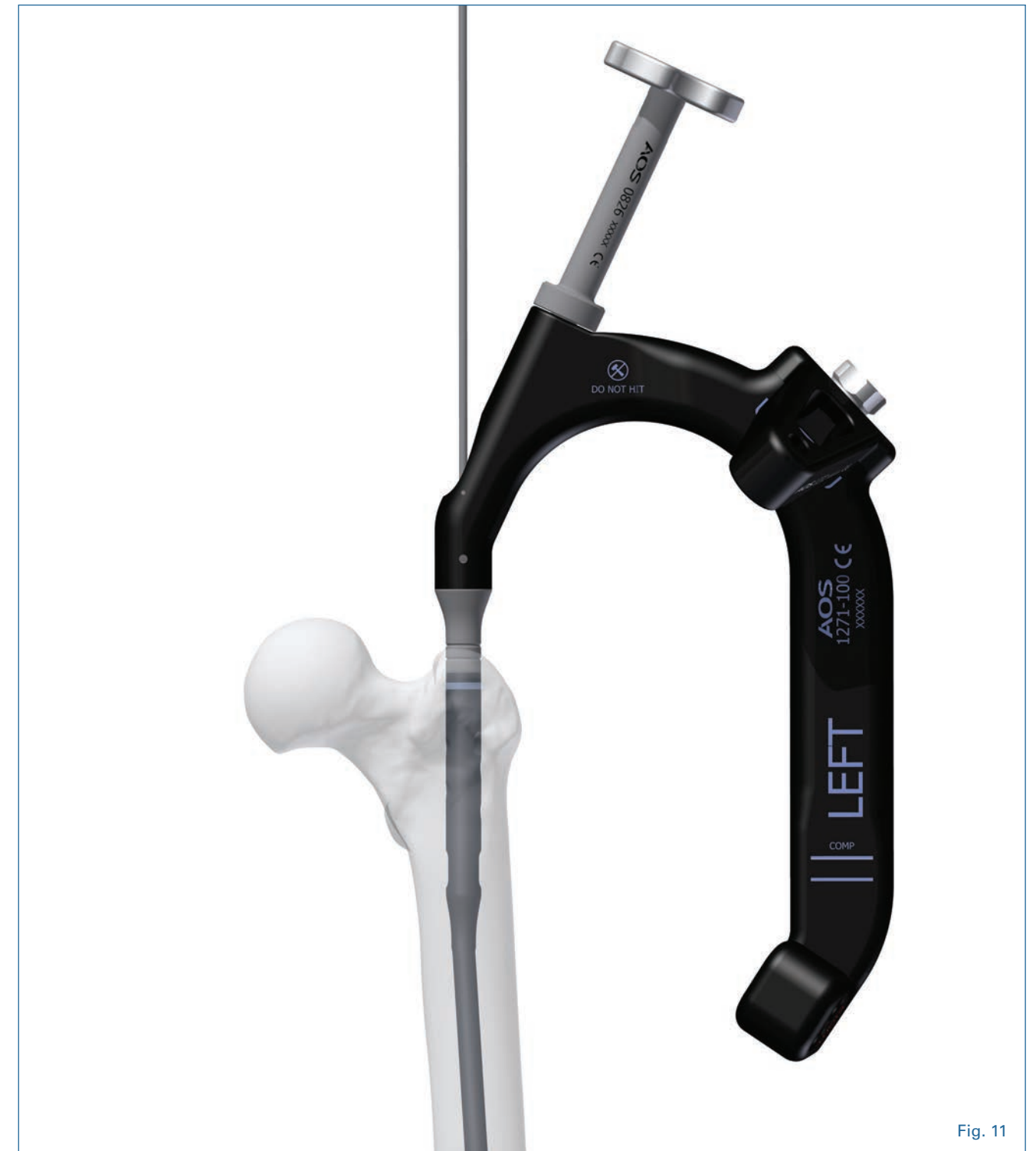

Fig. 11



### 9. Proximal Targeting (Transverse Interlocking)

A proximal dynamic slot has been incorporated into the nail. It will allow up to 8.0mm of controlled compression. It can also be used for dynamic locking or for static locking in either the proximal or distal aspect of the slot.

**WARNING:** If use of the nail with the compression feature is desired, counter-sink the nail into the proximal femur by approximately 10.0mm. This will prevent the nail from backing out of the proximal femur during compression of the fracture site.

Proximal transverse interlocking involves the use of **5.0mm Cortical Screw** placed through the **Antegrade Radiolucent Targeting Guide** (Table 1, Pg. 13).

Place the **Screw Sheath**, **4.0mm Drill Guide**, and **4.0mm Obturator** through the appropriate transverse hole in the targeting guide and mark the skin. Make a small incision and place the sheath, drill guide, and obturator through the incision, down onto the lateral cortex of the bone (**Fig. 12a**).

Remove the obturator and drill the bone using **4.0mm Calibrated Drill** and measure the screw length from the end of the **Drill Guide** using the calibration on the drill (**Fig. 12b**).

Assemble the **5.0mm Cortical Screw** onto the **Captured Hex Driver System**. The **Captured Hex Driver System** is assembled by placing the screw onto the **5.0mm Hex Driver** then engaging the **Capturing Rod**. The captured construct is then connected to the **T-Handle** (**Fig. 13**). Remove the drill and drill guide and place the screw directly through the sheath using the **Captured Hex Driver System** (**Fig. 14**).

**NOTE:** It is recommended that a **5.0mm Cortical Transverse Screw** be accompanied by a **6.5mm Cortical or Cancellous Screw** in the proximal end of the nail to assure good fixation of

the proximal femur. This can be placed in the reconstruction configuration, the antegrade configuration, or both if two 6.5mm screws are used.



Fig. 13

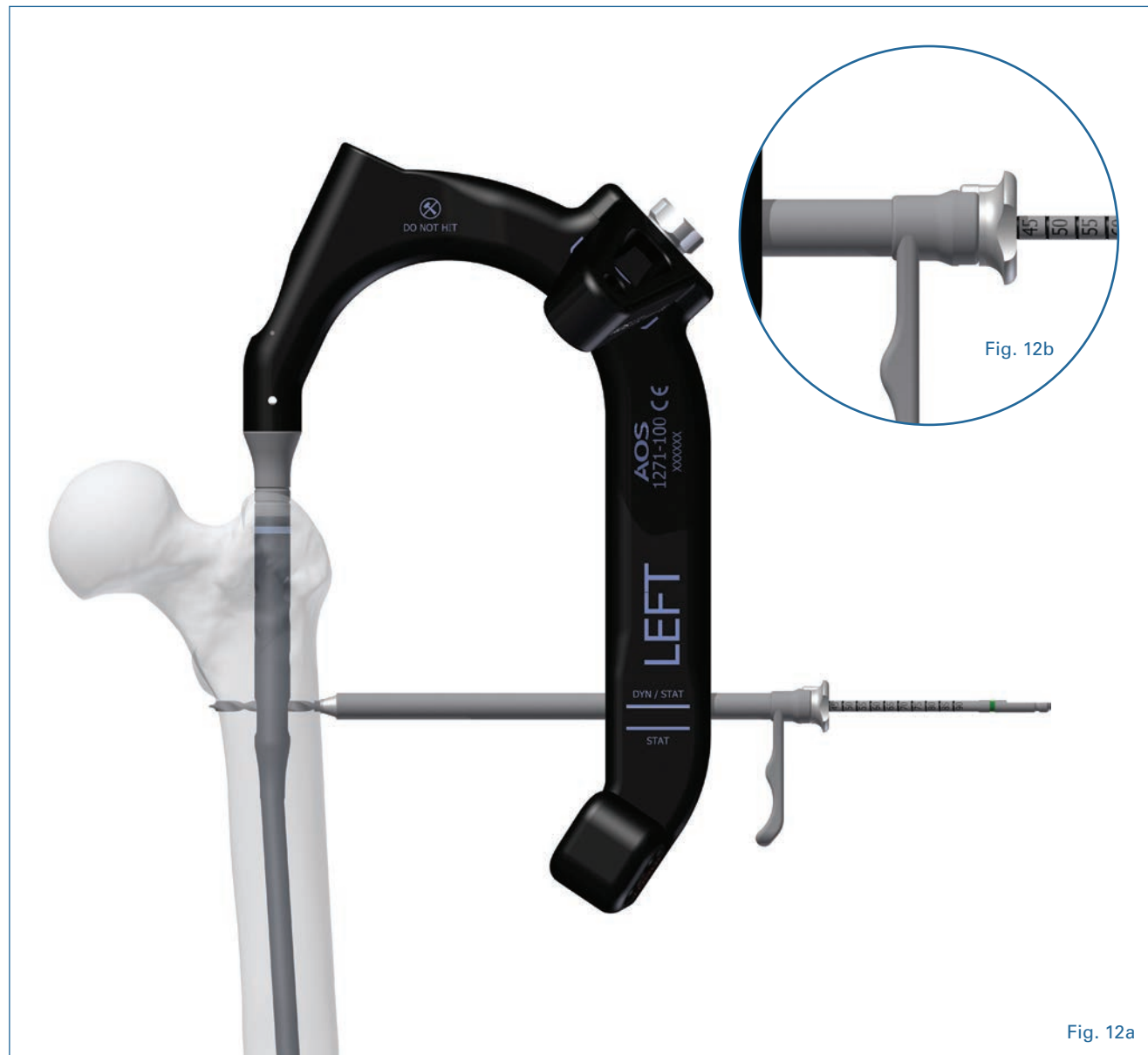


Fig. 12a

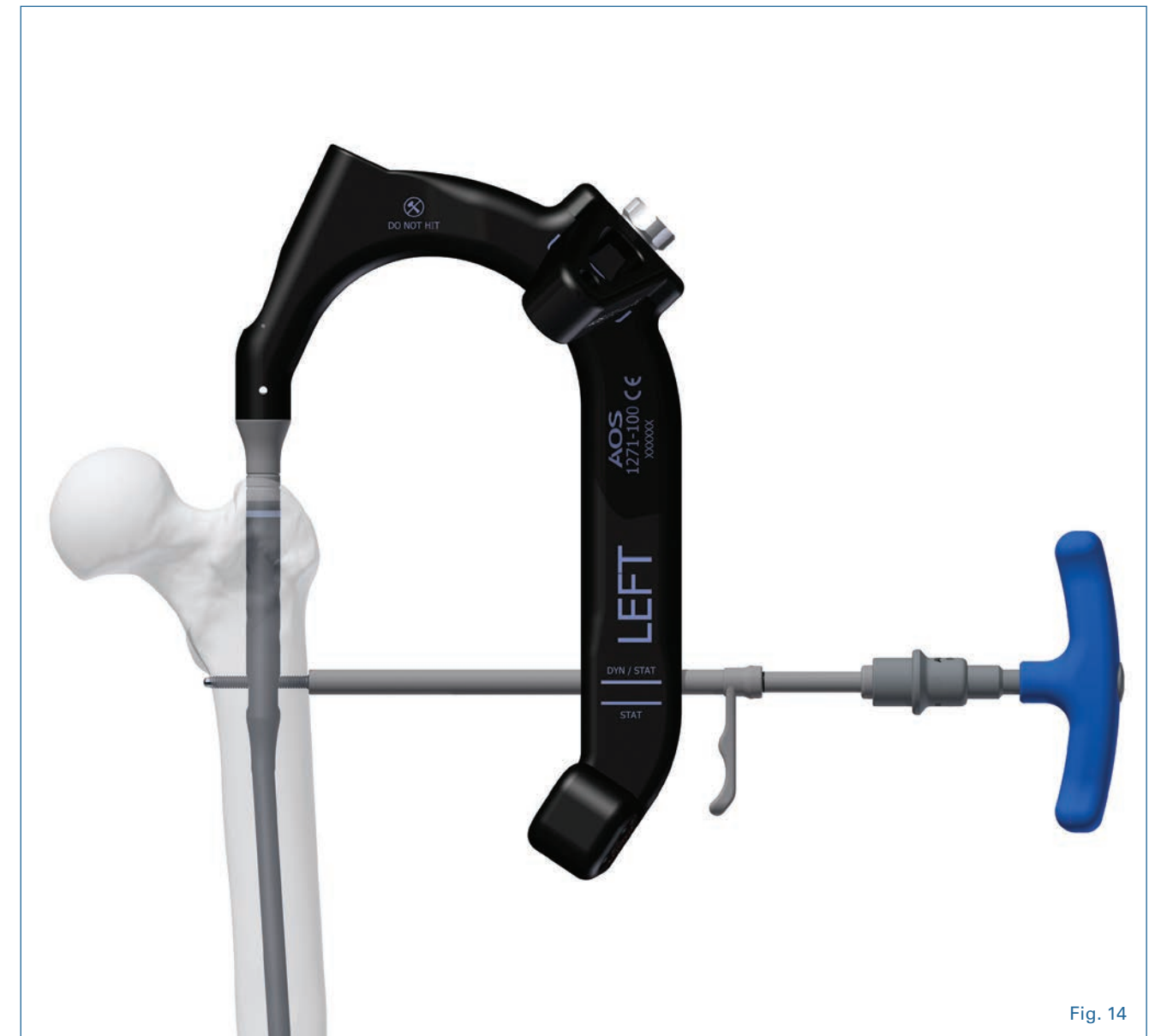


Fig. 14

There are 4 different ways to utilize the proximal dynamic slot when performing Transverse Interlocking:

### Option A: Controlled Compression

If controlled compression at the fracture is desired, insert the Compression Spacer so that it rests just above the dynamic slot (Fig. 15). Insertion of the compression spacer must occur before nail insertion. Conduct transverse locking within the dynamic slot using the DYN/STAT hole on the targeting guide. Next, perform distal interlocking at the distal aspect of the nail under fluoroscopy when using the compression feature. [See Distal Targeting – Freehand Technique (Pg.16)].



Then, use the 5.0mm Compression Hex Driver to drive the Compression Spacer down against the proximal screw within the slot. By pushing down onto the proximal screw, the nail will be reversed, moving the distal femoral segment towards the fracture site, allowing for controlled compression of up to 8mm (Fig 16a).

**WARNING:** Do not over-tighten or force the compression spacer during intraoperative compression as this may damage or deform the proximal screw. Monitor the fracture site and the transverse screws at the proximal and distal ends of the nail under fluoroscopy when using the compression feature.



### Option B: Dynamic


If dynamic locking of the nail is desired with the use of the proximal dynamic slot, conduct transverse locking through the DYN/STAT hole on the targeting guide. The Compression Spacer would not be needed in this instance. Note: a 6.5mm screw either in reconstruction or antegrade mode cannot be used with this option as it would prohibit the dynamic function of the nail (Fig. 16b).



**WARNING:** This configuration of interlocking is only recommended for rotationally stable, transverse midshaft fractures without comminution.

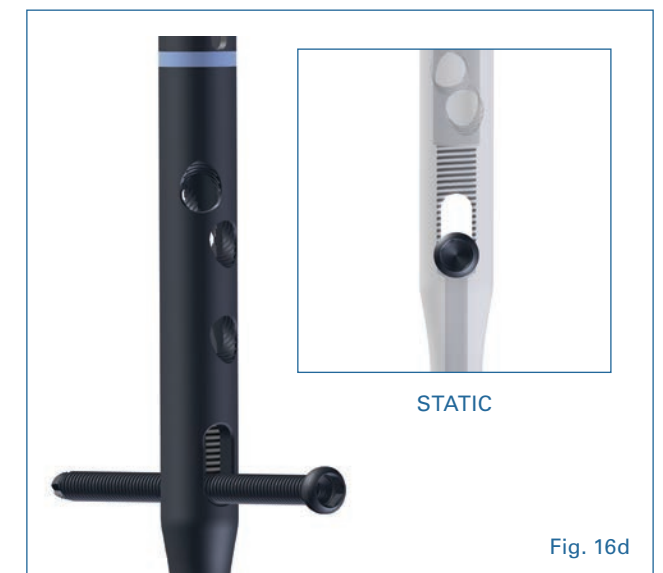
### Option C: Static with Spacer

If static locking is desired through the proximal aspect of the dynamic slot, insert the Compression Spacer down to the distal aspect of the dynamic slot. Insertion of the compression spacer must occur prior to nail insertion. Conduct transverse locking through the DYN/STAT hole on the targeting guide (Fig. 16c).



### Option D: Static

If static locking is desired through the distal aspect of the dynamic slot, conduct transverse locking through the STAT hole on the targeting guide. (Fig. 16d). The Compression Spacer would not be needed in this instance.



## 10. Proximal Targeting (Reconstruction Interlocking)

Options for proximal interlocking in a reconstruction position are the **6.0mm Partially Threaded Cancellous Screw (GOLD)**, **6.5mm Fully Threaded Cancellous Screw (BLUE)**, and/or the **6.5mm Fully Threaded Cortical Screw (PURPLE)** (Table 1). Any of these three proximal screws can be used in the reconstruction position.

**NOTE:** The **6.5mm Fully Threaded Cancellous Screw** and **6.5 Fully Threaded Cortical Screws** both thread into the reconstruction and antegrade proximal holes, preventing screw backout.

There are two techniques for insertion of the **6.5mm Fully Threaded Cancellous Screw (BLUE)** and **6.5mm Fully Threaded Cortical Screw (Purple)**.

### Option A:

Use a solid drill to pre-drill for the screw. If using a **6.5mm Fully Threaded Cortical Screw (PURPLE)** or a **6.5mm Fully Threaded Cancellous Screw (BLUE)** a **5.5mm Calibrated Drill** will be used.

Once the nail has been correctly placed, insert the **Screw Sheath**, the **Drill Guide**, and the **Obturator** through the targeting module and mark the incision location on the skin. Make a small incision, insert the sheath, drill, and obturator until it contacts the cortex of the femur (Fig. 17).

Remove the obturator and drill the bone using the **5.5mm Calibrated Drill** to the desired depth. Determine the screw length by reading the drill calibrations against the drill guide. Be certain that the sheath is against the lateral cortex so that the proper length will be indicated. Remove the drill and drill

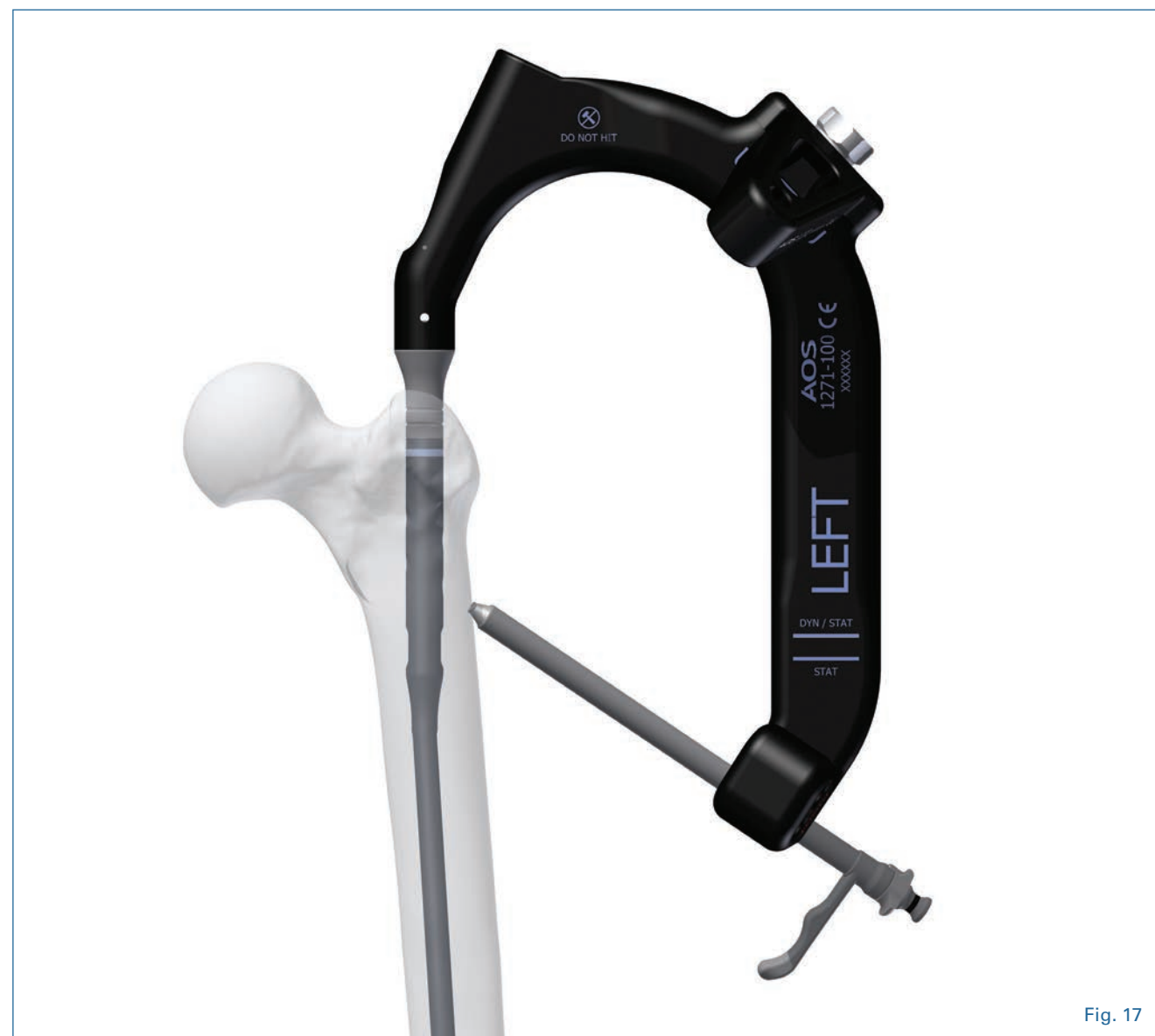


Fig. 17

TABLE 1	Type	Diameter	Drill
	Partially Threaded Cancellous	6mm	4.8/6.0mm Calibrated Step (Yellow)
	Fully Threaded Cancellous	6.5mm	5.5mm (Blue/Purple)
	Fully Threaded Cortical	6.5mm	5.5mm (Blue/Purple)
	Fully Threaded Cortical	5.0mm	4.0mm (Green)

guide. Assemble the 6.5mm screw onto the **Captured Screw Driver System** and **T-Handle**. Advance the chosen screw through the screw sheath.

### Option B:

This option allows the use of guide pins to plan the location of the screws prior to drilling with a cannulated drill. Once the nail has been correctly placed, insert the **3.2mm Pin Guide** and **3.2mm Obturator** through the targeting module and mark the incision location on the skin. Make a small incision,

insert the sheath, pin guide, and obturator until it contacts the lateral cortex of the femur (Fig. 17).

Place the **3.2mm Guide Pin** into the **Pin Guide** and insert it into the femoral head (Fig. 18). The location of the Guide Pin should be checked on both A/P and lateral views. The position of the guide pin in the femoral head on the A/P view will be based on the desired proximal screw configuration (Fig. 19). A lateral view of the femoral head is then taken to ensure the **Guide Pin** has been placed centrally. In both A/P and Lateral views the tip of the guide pin should be approximately 5.0mm from the subcondylar bone.

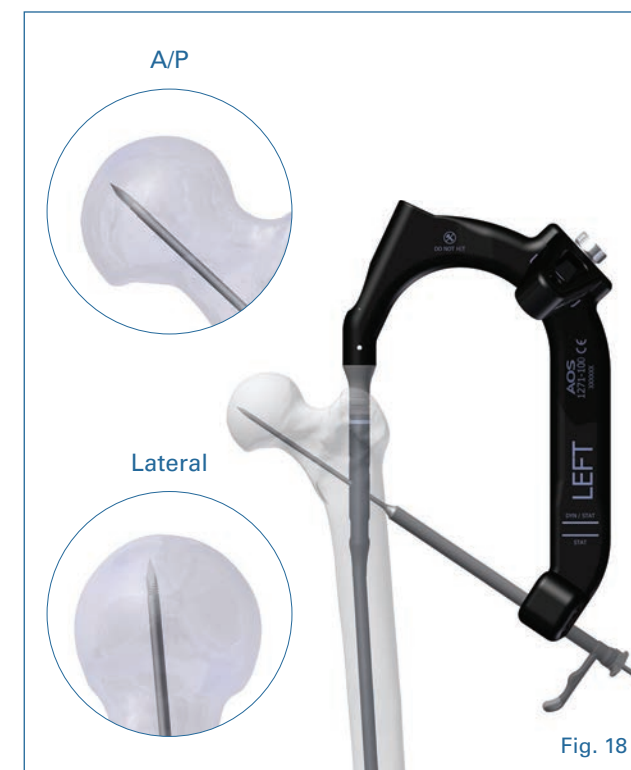

Fig. 18

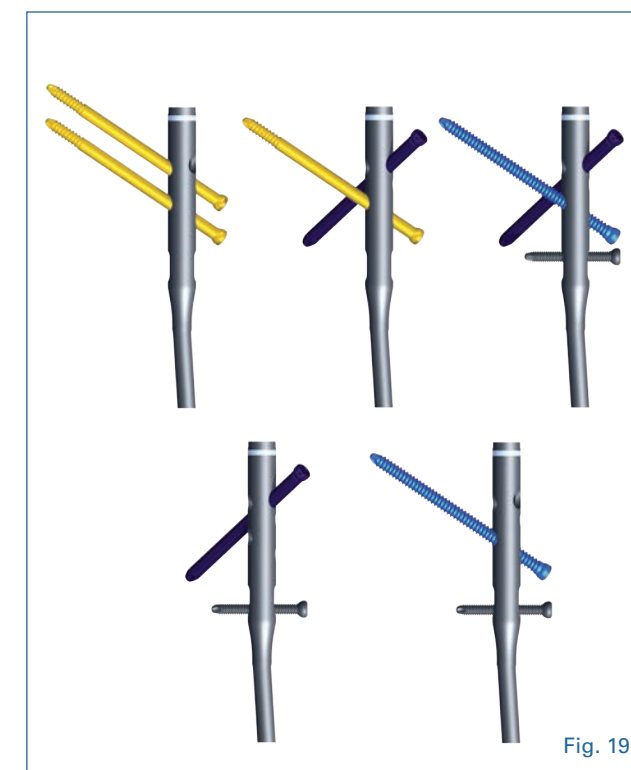
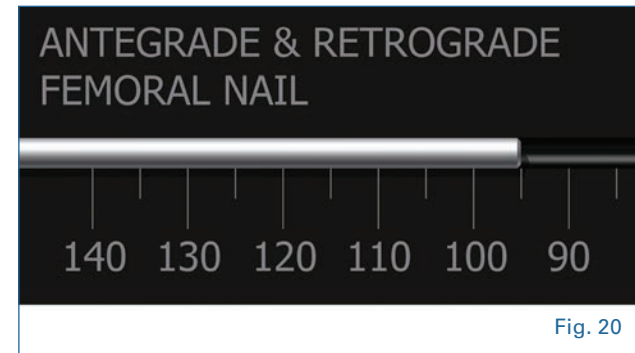


Fig. 19



## 11. Screw Insertion

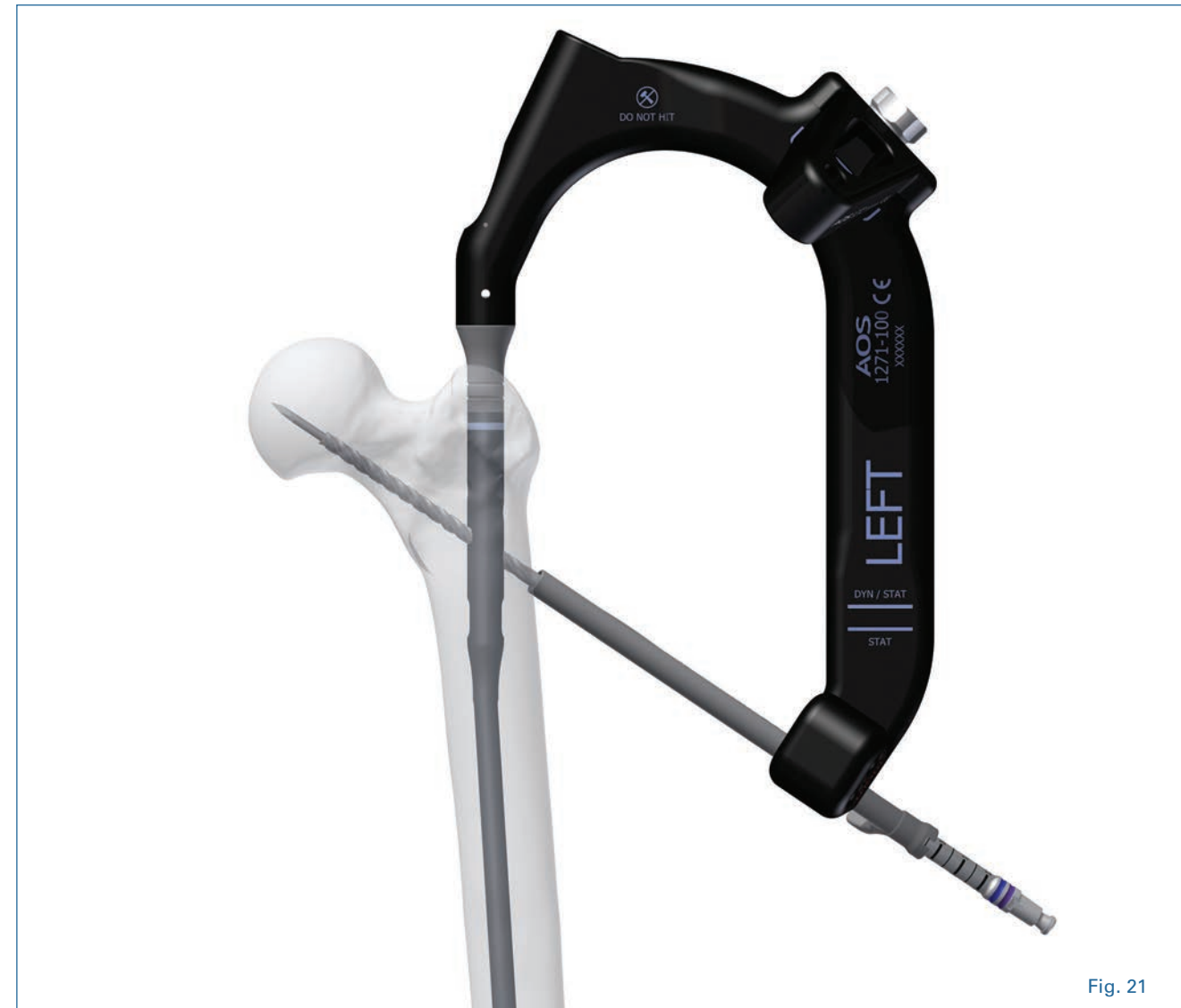Place the **Guide Pin Depth Gauge** under the **3.2mm Guide Pin** and against the Pin Guide. Read the required length from the **Depth Gauge**, assuring that the sheath is touching the bone (**Fig. 20**). The **Pin Guide** is then taken out of the screw sheath and a **5.5mm**



**Calibrated Cannulated Drill (BLUE/PURPLE)** is inserted over the guide pin. The femoral head is then drilled to the appropriate depth, measuring the screw length off of the calibration lines (**Fig. 21**).

**NOTE:** Care should be taken to advance the drill through the femoral head into the hip joint.

In dense bone, it is advisable to tap the femoral head before placing the proximal screws. After drilling, remove the **3.2mm Guide Pin** and tap the bone using the **6.0mm Calibrated Cancellous Tap** or **6.5mm Calibrated Cortical Tap**.



Assemble the appropriate screw onto the **Captured Screw Driver System** and **T-Handle** as shown in (**Fig. 22**). Remove the 3.2mm guide pin out of the screw sheath and advance the selected screw into the femoral head using the T-Handle and 5.0mm long capturing hex driver.

Repeat this technique to place additional proximal screws as necessary.

**For use of 6.0mm Partially Threaded Cancellous Screw (GOLD)**

After inserting the **Screw Sheath**, the **Drill Guide**, and the **Obturator**, mark the incision location on skin. Make a small incision, insert sheath, pin guide, and obturator until contacts the cortex of the femur (**see Fig. 17**).

Remove the obturator and drill using the **4.8mm/6.0mm Calibrated Step Drill**. Select the appropriate screw length by measuring off of the calibration lines. Insert the selected screw as above.



## 12. Proximal Targeting (Antegrade Interlocking)

Proximal antegrade interlocking involves the use of a **6.5mm Fully Threaded Cortical Locking Screw (PURPLE)**, **6.5mm Fully Threaded Cancellous Screw (BLUE)**, or a **Partially Threaded Cancellous Screw (YELLOW)**. Any of these three

screws can be used in the antegrade interlocking position (Fig. 23).

See Proximal Targeting (Reconstruction Interlocking, Paragraph 10, Pg. 12) for instructions on insertion of each of these screw types.

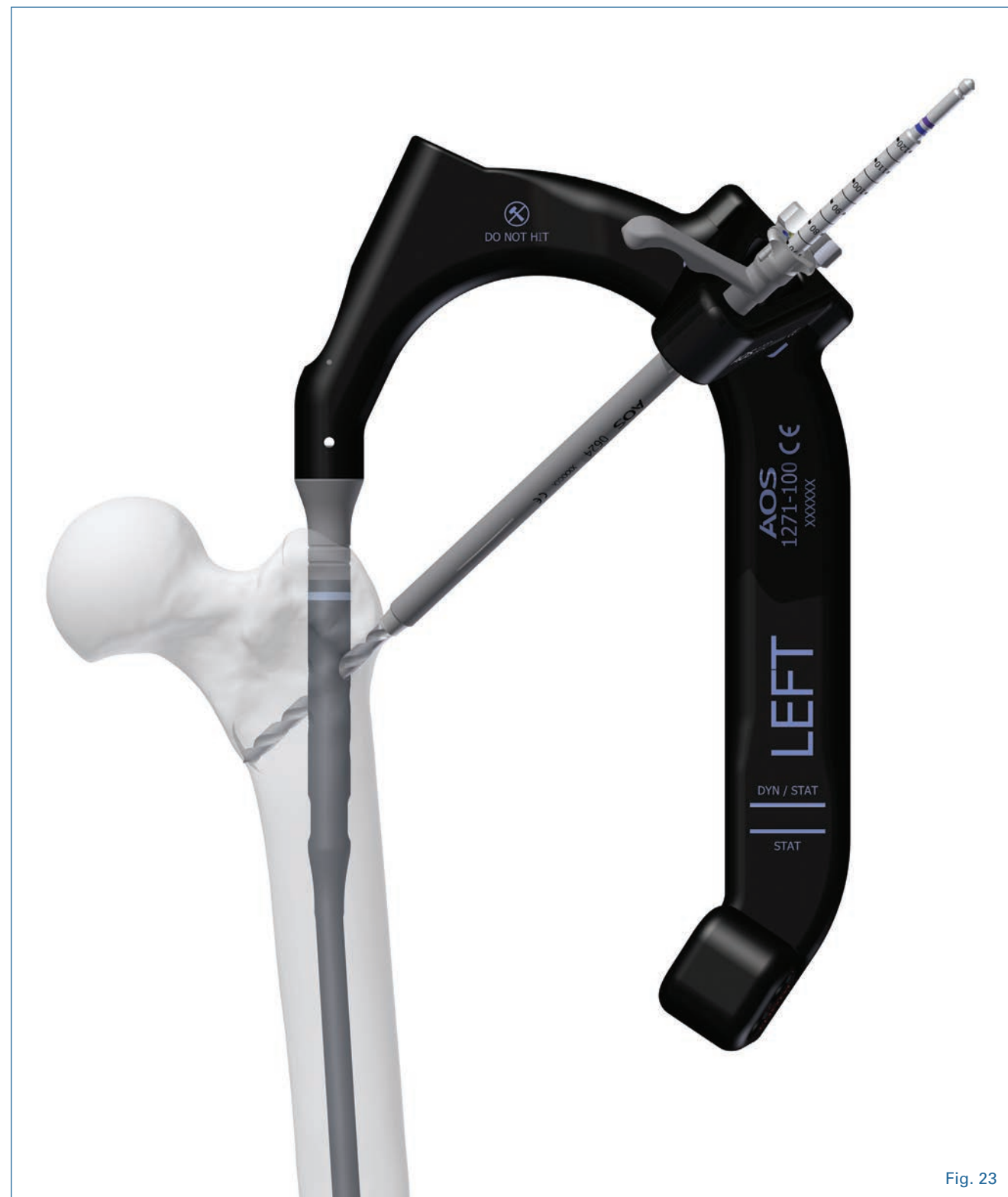

Fig. 23

## 13. Distal Targeting – Freehand Technique

Distal locking includes two static transverse holes and a dynamic slot (Fig. 24).

Rotational alignment must be checked prior to insertion of the screw.

All nails use **5.0mm Cortical Screws with a 4.0mm drill bit**, (see table 1 Pg. 13) distally. Distal locking is accomplished using the freehand technique. Accurate C-arm position is



Fig. 24

confirmed when the distal nail hole appears to be a perfect circle on the lateral C-Arm image. Once correct placement has been verified fluoroscopically, make a small incision laterally through the skin, subcutaneous tissue, and iliotibial band in direct alignment with the distal hole. Drill until the second cortex is penetrated. Verify the drill bit position fluoroscopically prior to taking any measurements.

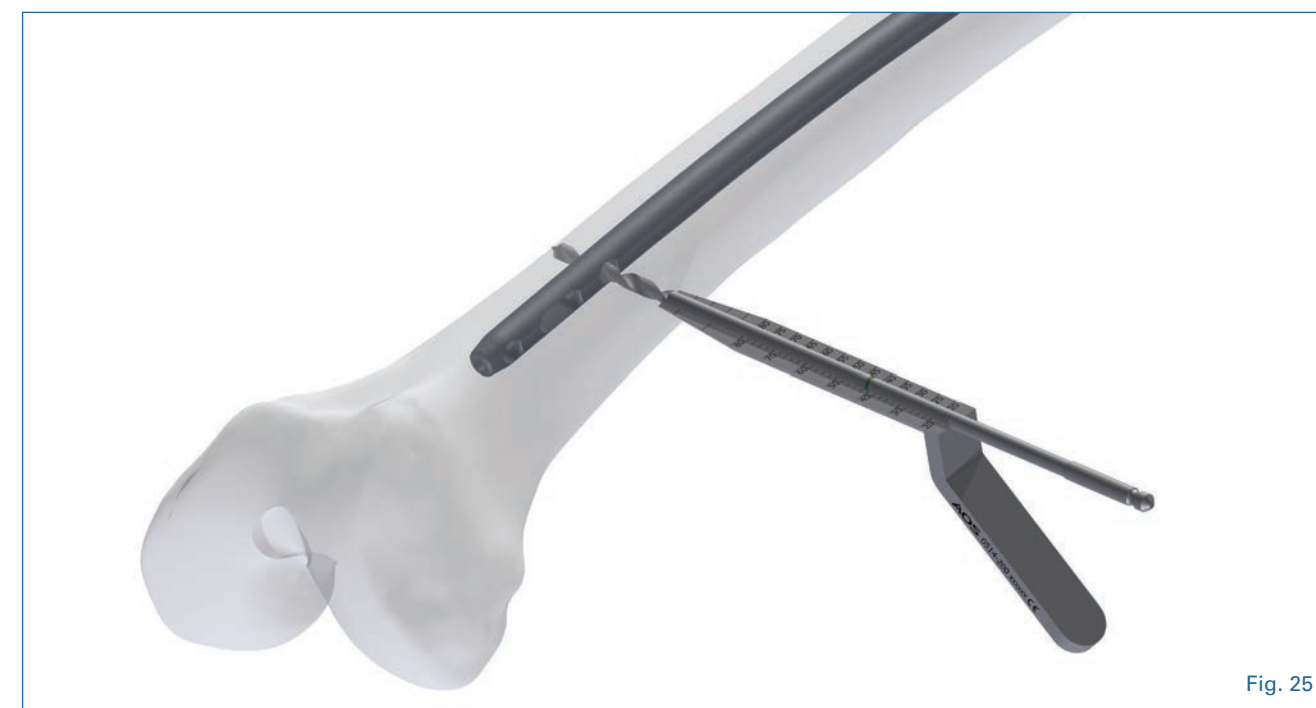

Fig. 25

Using the freehand technique the screw length is confirmed from the calibrated line on the **4.0mm Short Drill** using the **Distal Depth Gauge (Fig. 25)**. Alternatively, the **Hook Tip Depth Gauge** may be used. Use the **Short** or **Long 5.0mm Captured Hex Driver System** to insert the cortical screw.

The antegrade femoral nail can also be used in a dynamic locking mode only when the fracture pattern permits. Dynamic locking may be utilized for transverse or rotationally stable fractures patterns without comminution. This is performed by placing a **5.0mm Cortical Screw** in the dynamic (distal) position of the oblong hole. This allows the nail to move and the fracture to settle while torsional stability is maintained. If immediate dynamization of the nail is desired do not fill any of the static holes.



## 14. End Cap Insertion

If use of an end cap is desired, determine the amount that the nail is countersunk using a C-arm image. Use the **5.0mm Captured Hex Driver System** to capture the end cap. Insert the appropriate end cap through the proximal incision and into the nail. **0mm, 5.0mm, 10.0mm, Non-Locking End Caps** are available.

If a **6.0 Partially Threaded Cancellous Screw** is used in the most proximal reconstruction locking hole of the nail, a **Locking End Cap** may be used to prevent lateral migration of the proximal screw (**Fig. 26**).

**Warning:** Use of the locking end cap is only recommended with the use of a 6.0mm Partially Threaded Cancellous Screws.

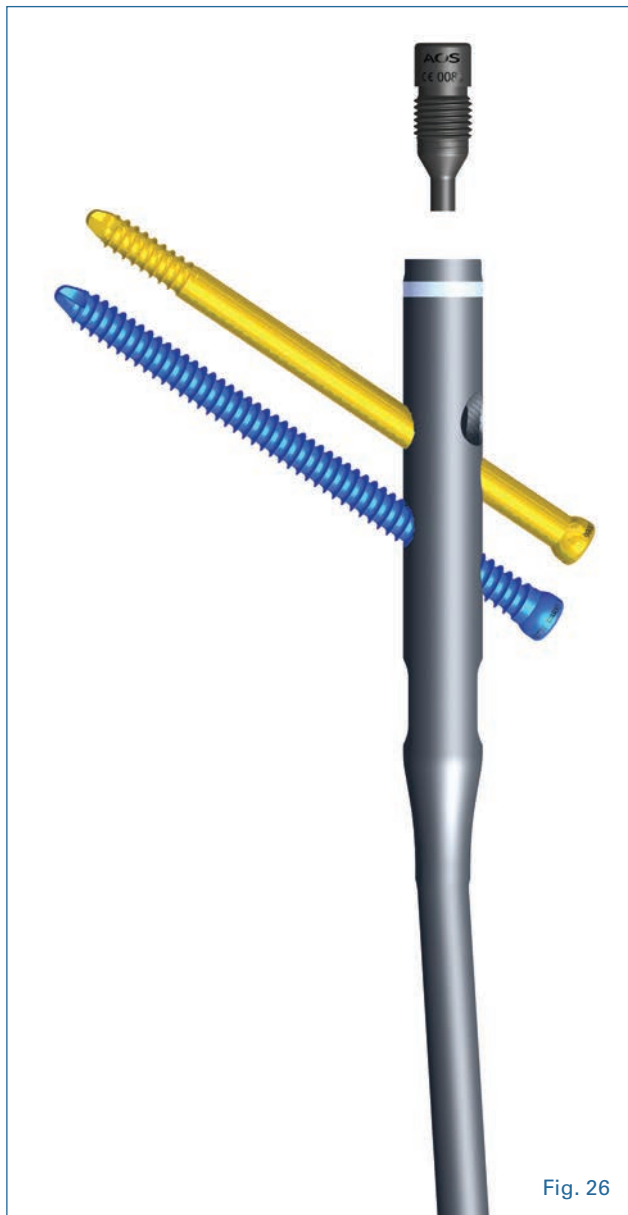


Fig. 26

## 15. Postoperative Care

Early range of motion of the hip and knee and mobilization of the patient are encouraged. Allow weight bearing to progress to full weight bearing as indicated by fracture pattern and radiographic healing.

It is the responsibility of the surgeon to determine the most suitable postoperative care.

## 16. Nail Extraction

Locate the proximal end of the nail and use the **5.0mm Hex Screwdriver** to remove the end cap if one was inserted. Insert the **Extraction Bolt** in the proximal end of the nail (Note: attachment of the **Extraction Bolt** is recommended prior to removal of interlocking screws). Use the C-arm to locate any distal screws. Expose the screws and use a **5.0mm Hex Screwdriver** to remove them. If bone has grown into any of the screws, nail cap, or nail that would inhibit implant removal, use instruments such as rongeurs, dental picks, or small curettes to remove bone before attempting implant removal. Take care not to damage the implants while removing ingrown bone.

To extract the nail attach the **Impactor Pad** to the **Extraction Bolt**. Then apply gentle backward blows with a mallet. Be careful to avoid levering the nail/extractor assembly during removal. Use the C-arm to visualize removal of the nail to avoid unnecessary damage to the femur.