



hNIS Imaging Data from a First-in-Human Trial of the Oncolytic Virus CF33-hNIS-AntiPD-L1 in Patients with Triple Negative Breast Cancer

Jamie Rand¹, Dave Yamauchi², Shyambabu Chaurasiya¹, Jianying Zhang³, Raju Pillai⁴, Colt Egelston⁵, Jonathan Kessler², Badri Modi¹, Leslie Chong⁶, Amanda Seiz⁶, Giovanni Selvaggi⁶, Nick Ede⁶, Mireya Murga⁷, Norma Martinez⁷, Wichanee Borisuthirattana⁷, Hans Meisen⁸, Susan E. Yost⁷, James Waisman⁷, Daphne Stewart⁷, Joanne Mortimer⁷, Yuman Fong¹, Yuan Yuan⁹

¹Department of Surgery, ²Department of Radiology, ³Department of Statistics, ⁴Department of Radiology, ⁴Department of Pathology, ⁵Department of ImmunOncology, City of Hope, ⁶Imugene Limited, Sydney NSW 2000 Australia, ⁷Department of Medical Oncology & Therapeutics Research, ⁸Department of Translational Development, City of Hope National Medical Center, Duarte, CA 91010; ⁹Cedars Sinai Medicine, Los Angeles, CA



BACKGROUND

- CF33-hNIS-antiPD-L1 (CHECKvacc) is a novel chimeric orthopoxvirus with robust anti-cancer activity in triple negative breast cancer (TNBC) xenografts.
- Human sodium-iodide symporter (hNIS) is a human cell-surface protein normally expressed in thyroid cells that allows cells to take up iodine, making them visible by non-invasive imaging.
- hNIS gene transfer allows tracking of virus by 99mTc single-photon emission computed tomography (SPECT) or positron emission tomography (PET).
- Our animal studies demonstrated that tumor cells infected with CF33-hNIS-antiPD-L1 successfully secrete functional hNIS and single-chain variable fragment (scFv) against programmed death ligand-1 (PD-L1) and are visible using hNIS imaging techniques.
- In pre-clinical studies, CF33-hNIS-antiPD-L1 administered by intratumoral (IT) injection was safe and well-tolerated.

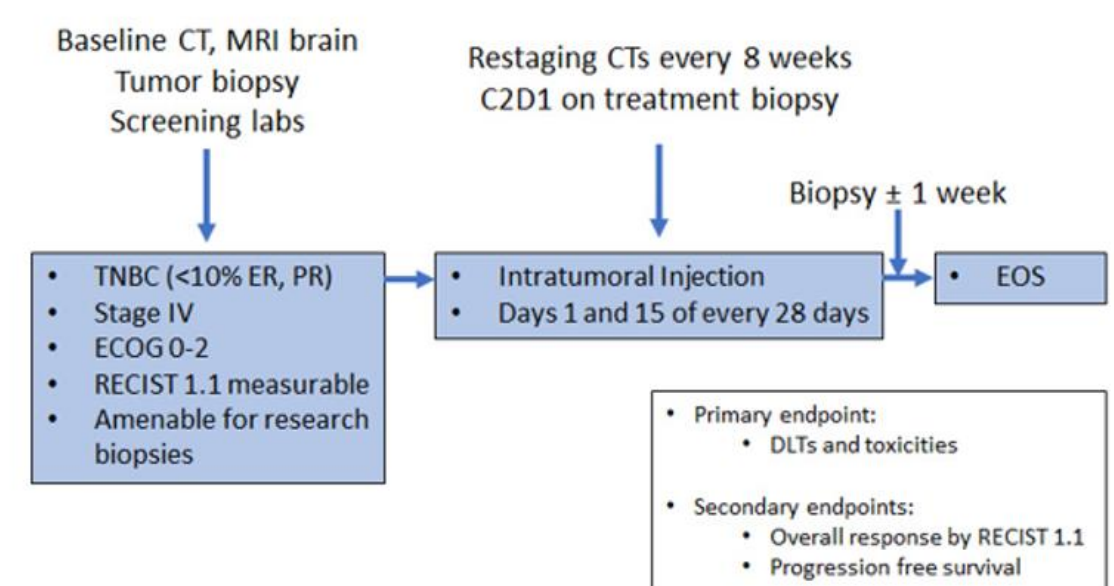


Figure 1. Study schema. Primary endpoints are DLT and toxicities by CTCAE v5.0.; Secondary endpoints are response rates by RECIST 1.1 and irRECIST 1.1, PFS, and OS.

CT, computerized tomography; MRI, magnetic resonance imaging; C2D1, cycle 2 day 1; ECOG, Eastern Cooperative Oncology Group; RECIST, Response Evaluation Criteria in Solid Tumors; EOS, end of study; DLT, dose limiting toxicity; CTCAE, common terminology criteria for adverse events

Table 1. Dose Levels.

Dose Level	Dose (PFU)	# of Doses
1	1x10 ⁵	6
2	3x10 ⁵	6
3	1x10 ⁶	6
4	3x10 ⁶	6
5	1x10 ⁷	6
6	3x10 ⁷	6
7	1x10 ⁸	6
8	3x10 ⁸	6

RESULTS

- From October 2021 to October 2022, 8 patients were enrolled in this ongoing study and received at least 1 dose of CF33-hNIS-antiPD-L1 injection at one of the first 3 dose levels (1 x 10⁵, 3 x 10⁵, or 1 x 10⁶ PFU), and all patients underwent 99mTc SPECT imaging for virus tracking at C1D8.
- The IT CF33-hNIS-anti-PD-L1 injections were well tolerated and no DLTs were observed. Treatment related AEs included: fatigue, injection site reaction, lymphocyte count decrease, and injection site pain or discoloration (Table 2).
- 75% of patients (6/8) had uptake at the site of injection on 99mTc SPECT imaging.
 - Of these, 4/4 (100%) patients with injection sites at metastatic subcutaneous nodules, intramuscular masses, or axillary lymph nodes had uptake at the injection site. Figure 2 shows imaging from 2 representative patients.
 - 2/4 patients (50%) with injection sites at matted dermal metastatic lesions had uptake on SPECT imaging
- Multiplex immunofluorescence shows an increase in CD8+ T-cells and PD-L1 expression (Figure 3).

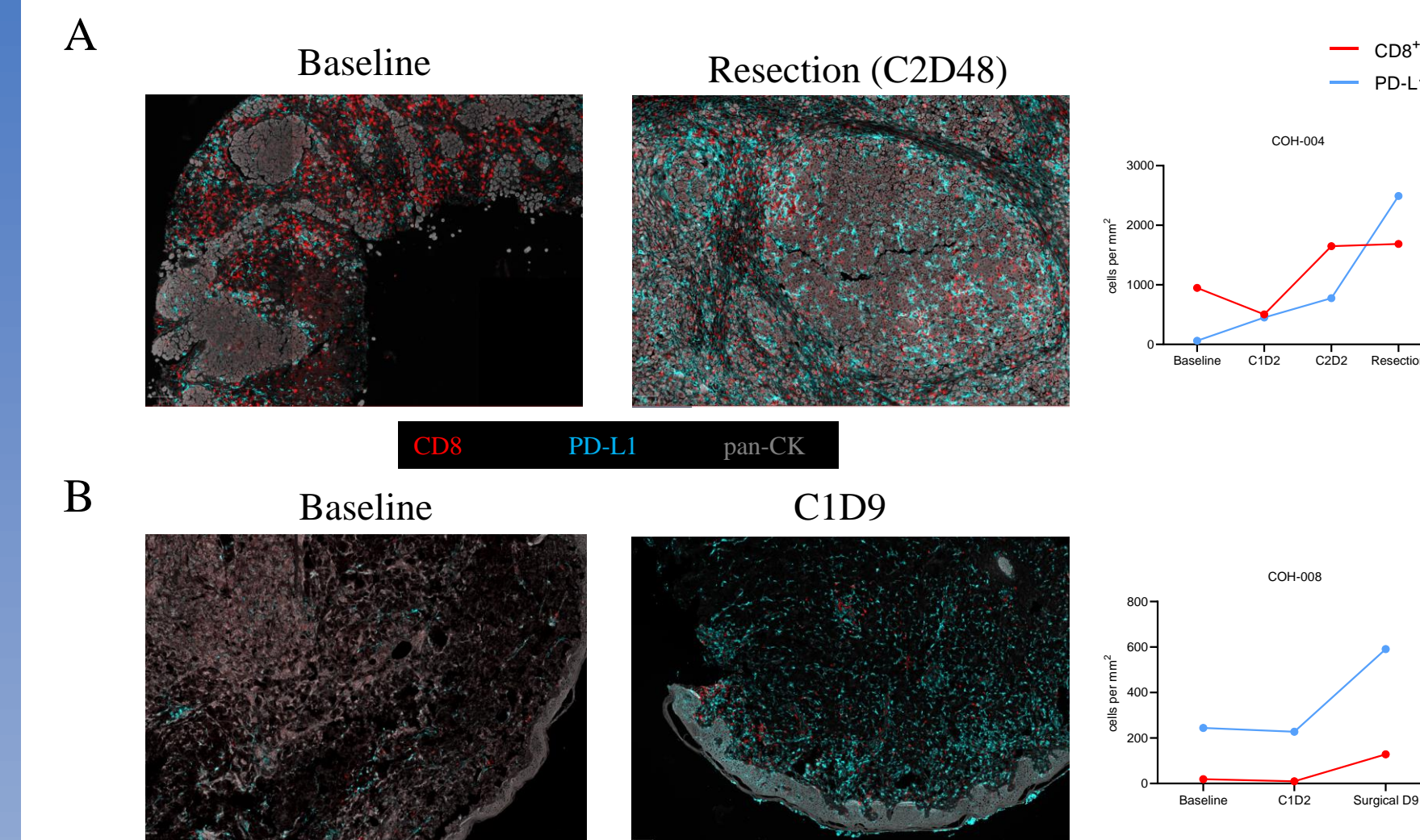


Figure 3. Multiplex immunofluorescence shows increase in CD8+ T-cells and PD-L1 expression following IT injection with CF33-hNIS-antiPD-L1.

A) Patient COH-004 had notable increase in PD-L1 expression post-treatment. Analysis of CD8+ T-cells is limited as this is nodal tissue with high T-cell populations at baseline.

B) Patient COH-008 had increase in CD8+ T-cells and increase in PD-L1 expression following treatment.

CONCLUSIONS

- CF33-hNIS-antiPD-L1 is safe and well tolerated at dose levels 1 through 3.
- SPECT imaging after treatment with CF33-hNIS-antiPD-L1 administered by IT injection in patients with mTNBC showed enhancement in 75% of injected lesions, suggesting local viral replication and hNIS expression.
- There was improved SPECT imaging enhancement in subcutaneous nodules, intramuscular nodules, and lymph nodes when compared to matted dermal metastasis.
- Further analysis will evaluate the correlation of SPECT imaging results with pathologic immune cell infiltrate, viral staining, and tumor response. Preliminary evaluation suggests increased CD8+ T-cell infiltration and increased PD-L1 expression following IT injection of CF33-hNIS-antiPD-L1.
- This is the first known report of successful hNIS-based imaging to track oncolytic poxvirus replication in humans.

ACKNOWLEDGEMENTS

- We thank the patients and their families for participating in this study.
- Funding was provided by Imugene.
- This presentation is the intellectual property of the authors. Please contact Dr. Rand at jrand@coh.org for permission to reprint and/or distribute. Clinical trial NCT05081492

METHODS

- This study is a first-in-human phase I, single center, single arm clinical trial evaluating the safety and tolerability of CF33-hNIS-antiPD-L1 intratumoral (IT) injection in patients with metastatic TNBC (mTNBC)
- Following a Phase I Queue (IQ) 3+3 design, eligible patients receive IT CF33-hNIS-antiPD-L1 at 1 of 8 assigned dose levels (from 1 x 10⁵ PFU to 3 x 10⁸ PFU) on Days 1 and 15 of each 28-day cycle for a total of 3 cycles of treatment.
- Non-invasive SPECT whole body imaging is performed 7 days after administration of CF33-hNIS-antiPD-L1, at Cycle 1 Day 8 (C1D8) and Cycle 2 Day 8 (C2D8).
- Correlative aims include assessing viral kinetics, viral plaque assay, 99mTc SPECT imaging for virus tracking, peripheral blood and tumor tissue for antiviral immune activation, and tumor microenvironment changes in association with response to therapy.

OBJECTIVES

- Primary objectives are to evaluate the safety and tolerability of CF33-hNIS-antiPD-L1 by CTCAE v5.0 criteria
- Secondary objectives include evaluation of antitumor activity by RECIST1.1 and irRECIST, determining the recommended Phase 2 dose (RP2D), and evaluating therapeutic efficacy [progression free survival (PFS) and overall survival (OS)]
- Exploratory objectives include assessing viral infection of tumor using hNIS-based SPECT imaging and viral titers of CF33-hNIS, evaluating antiviral immune activation [expression of PD-1, PD-L1, or CTLA-4 and CD8+ T-cells], and determining optimal biologic dose (OBD)

KEY ELIGIBILITY CRITERIA

- Histologically confirmed unresectable or metastatic TNBC, defined as ER and PR ≤ 10% by IHC, and HER2 negative per ASCO/CAP guidelines
- Patients must have progressed or been intolerant of at least 2 prior lines of systemic chemotherapy for advanced/metastatic disease
- ECOG 0 – 2
- Measurable disease by RECIST 1.1
- Must have a superficial tumor (cutaneous, subcutaneous), breast lesion or nodal metastases amenable to safe repeated intratumoral injections per treating physician and interventional radiologist review.

KEY EXCLUSION CRITERIA

- Chemotherapy within 14 days
- Vaccination within 30 days, active infections
- Surgery or radiation within 28 days
- Pregnant or breast feeding.
- Uncontrolled brain metastasis

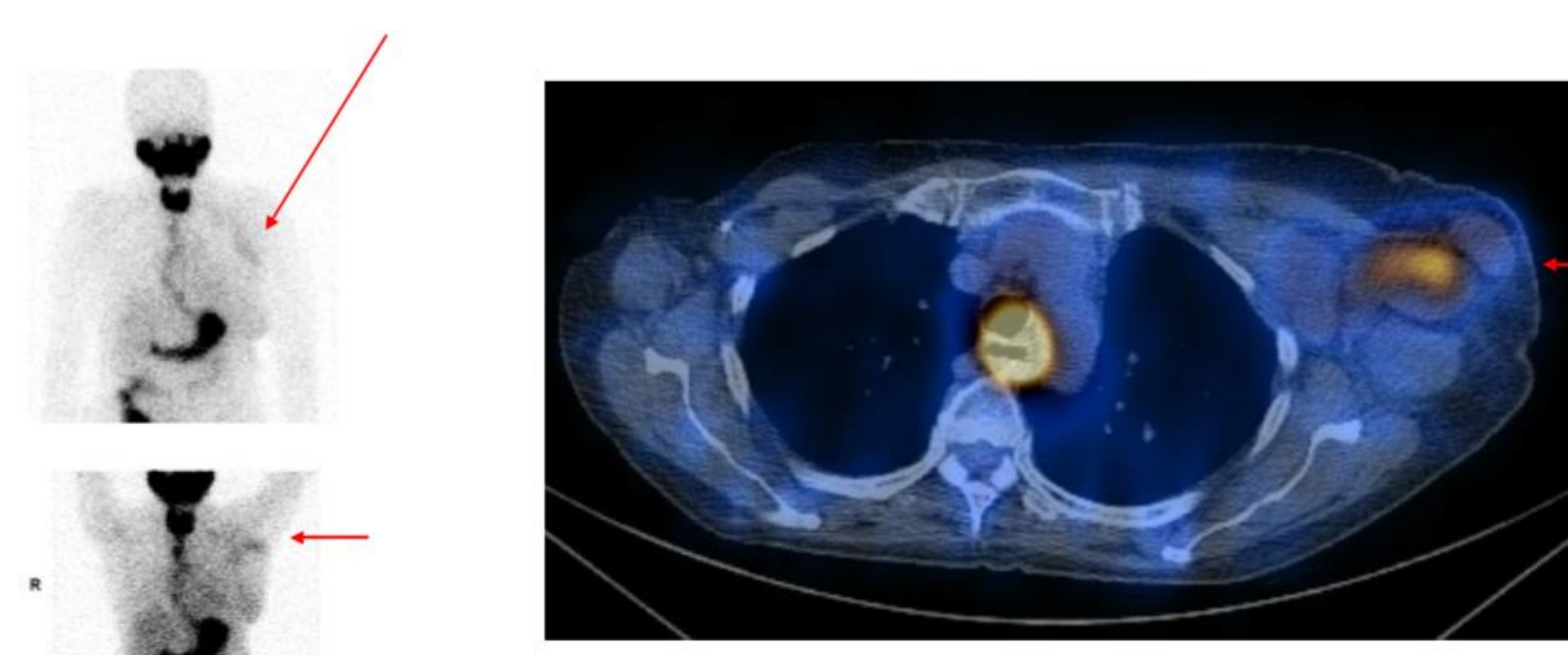
STATISTICAL DESIGN

- First 3 subjects will be enrolled sequentially, each receiving 1 injection and completing 4-week safety period before next is treated.
- At least 3 subjects must complete the first evaluation period (or have DLT) before a dose escalation decision can be made.
- DLT is defined as any Grade 3 or 4 toxicities that are possibly related to CF33-hNIS-antiPD-L1 (excluding some Grade 3 injection site reactions, rashes, fatigue, GI symptoms, and transient lab abnormalities).

Table 2. Toxicity Summary for Dose Level 3.

Dose level	Category	Adverse Event	Count Per AE Grade		
			1	2	3
Dose Level 3: 10 ⁶ (n=2)	General disorders and administration site conditions	10016256-Fatigue	0	1	0
		10022095-Injection site reaction	0	0	1
		10033371-Pain	0	1	0
		CHEST WALL ERYTHEMA	0	0	1
	Infections and infestations	CELLULITIS	0	0	1
	Investigations	10025256-Lymphocyte count decreased	0	0	1
Neoplasms benign, malignant and unspecified (incl cysts and polyps)	10045158-Tumor pain	0	1	0	
	Skin and subcutaneous tissue disorders	10037087-Pruritus	1	0	0

A



B

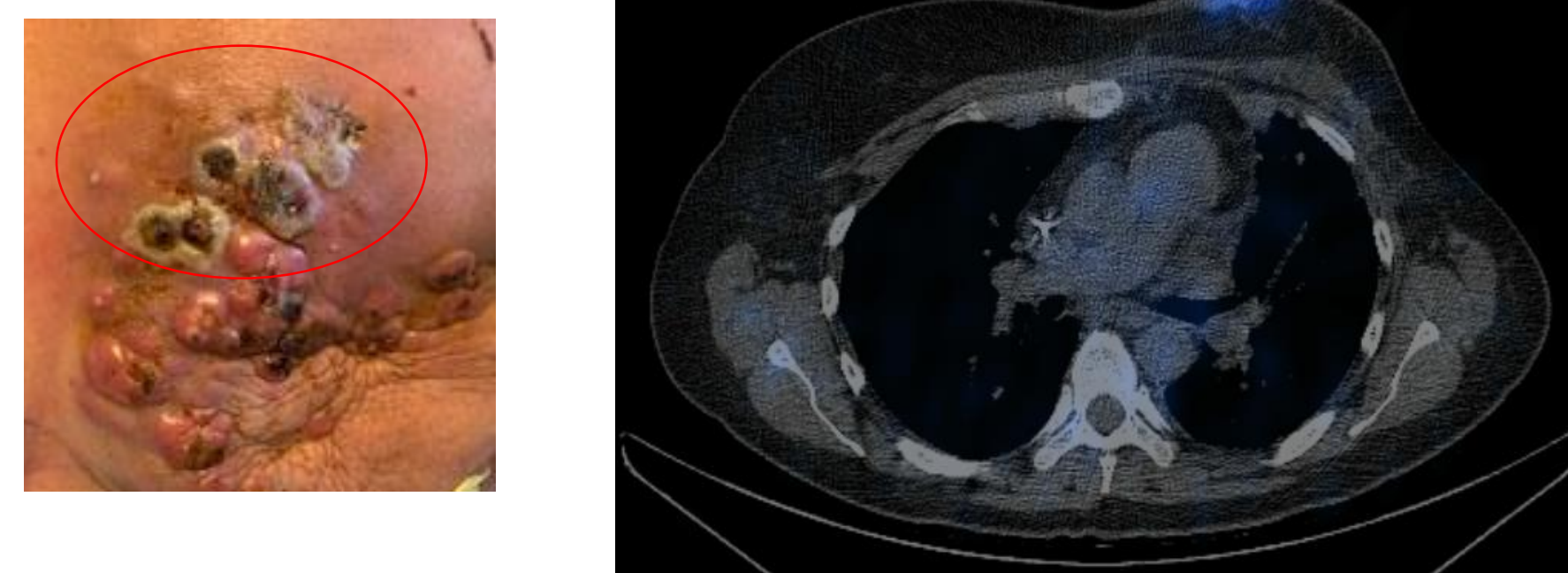


Figure 2. SPECT imaging using Technetium-99m.

A) Patient COH-004 received CF33-hNIS-antiPD-L1 at DL2 (3x10⁵ PFU). Injected lesion was left axillary lymph node. SPECT imaging showed enhancement of injected lymph node (red arrow).

B) Patient COH-008 received CF33-hNIS-antiPD-L1 at DL3 (1x10⁶ PFU). Injected lesions were superior left chest wall nodules. Injected nodules demonstrated necrosis on clinical exam (red oval). SPECT imaging showed enhancement of injected nodules (red arrow).