

DR. DJ HAEUSSLER

VETERINARY
OPHTHALMOLOGY

The Essentials of Veterinary Ophthalmology



5



Contents

Anatomy and Physiology of the Cornea 3

Conditions Commonly Related to a Reduction in Canine Corneal Health 5

Hyaluronic Acid: Can We Use This To Better Canine and Feline Corneal Health? 7

Understanding corneal ulceration 9

Understanding Normal versus Abnormal retinas 11

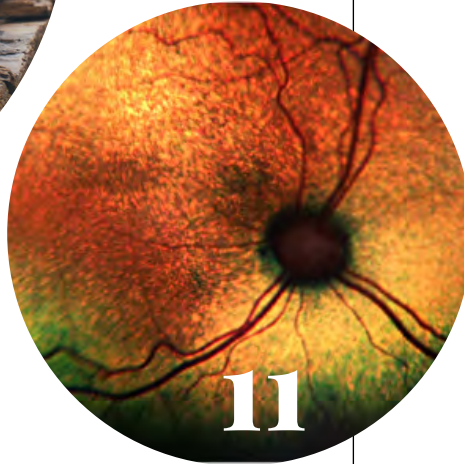
Anterior Uveitis in Small Animals 14

Keeping Vision in Focus: Diseases and Surgery of the Lens 17

Common Eyelid Diseases in Small Animal Patients 20

Under pressure: Glaucoma Recognition and Treatment 23

11



17



23



VET CANDY

DR. HAEUSSLER

DR. JILL LÓPEZ
Editor-in Chief

ANTONIO LÓPEZ
Creative Director

M. ALAUDDIN
Graphic Design Editor

AMANDA COFFIN
Copy and Research Editor

Published by
VET CANDY MEDA

Chief Executive Officer
DR. JILL LÓPEZ

Vet Candy trademark and logo are owned by
VET CANDY, LLC.
Copyright © 2021

myvetcandy.com

All rights reserved. No part of this publication may be reproduced, distributed, or transmitted in any form or by any means, including photocopying, recording, or other electronic or mechanical methods, without the prior written permission of the publisher, except in the case of brief quotations embodied in critical reviews and certain other noncommercial uses permitted by copyright law. For permission requests, write to: info@myvetcandy.com

BioHAnce™ Technology

Learn about the innovative technology that sets Sentrx ophthalmology and epidermal repair products apart from any others in pet healthcare.

- **Patented and proprietary:** BioHAnce technology uses advanced bioengineering to create a molecular matrix of crosslinked hyaluronic acid (HA) that can be specifically modified for each formulation and particular tissue environment, including ocular and skin surfaces. It produces a cellular scaffolding with unique physical and chemical properties that enhances hydration, accelerates the body's own healing processes and extends duration in tissue.
- **Bioengineered for effectiveness and duration:** HA is a naturally occurring substance throughout the body of humans and animals that plays a key role in hydration, tissue lubrication and healing processes. Before BioHAnce, the rapid degradation of naturally occurring HA limited its clinical applications and efficacy in the real world. This patented technology makes it possible to chemically modify the HA so it is more resistant to degradation, while providing an ideal environment to enhance natural healing processes and unique muco-adhesive properties that extend hydration and lubrication. The concentration of BioHAnce may vary based on the intended use.
- **Products with no active ingredient, yet actively support healing and hydration:** The unique crosslinking process creates a hydrogel that acts as a molecular scaffolding material. Therefore, our ocular and dermal products DO NOT have an active ingredient, but instead are scaffold materials that allow the natural healing process to occur more quickly.



- **How our crosslinked HA compares to traditional crosslink alternatives:** Our BioHAnce technology is a purified product. There are no side components that have any detrimental or toxic byproducts or irritating effects. Traditional crosslink technologies use a process that can result in poor biocompatibility, an elevated immune response or inflammation.

How it's made:

BioHance is created by making two modifications to hyaluronic acid. We purchase medical grade hyaluronic acid made by a fermentation process that is free of animal products, which is modified and purified prior to use in our dermal and ocular formulations. Certificates of Analysis for all raw materials are kept at our manufacturing facility in Salt Lake City, Utah. Following the final purification, the solution of BioHance is sterile filtered and aseptically crosslinked to form the final HA gel product.

Learn more at sentrxanimalcare.com/products/biohance-technology/

Key Benefits of Crosslinked HA:

- Extends duration in ocular and dermal surfaces
- Accelerates the body's own healing process
- Enhances hydration and lubrication in tissue
- Creates a thin barrier that soothes and protects
- Can be tailored to match the specific tissue environment
- Unlike some veterinary products that are derived from human treatments, Sentrx BioHance products are designed and developed to support pets

Crosslinked vs. Non-Crosslinked HA Products

- **Crosslinking creates a more viscous lubrication at a lower concentration.** It also has muco-adhesive properties that a base HA molecule does not. For this reason, it stays on surfaces longer and does not get cleared from the eye during blinking like traditional HA eye drops do.
- **Once you crosslink HA, it changes the chemical and physical properties of HA.** As a result, you can't compare the concentration of an HA product to the concentration of a crosslinked HA product. The crosslinking process effectively creates an infinite molecular weight and thus the physical properties are different.
- The higher the molecular weight of a product the harder it is to get into solution. **Our crosslinked formulation nearly creates an infinite molecular weight but allows for scaling, purification, and sterile filtration.**

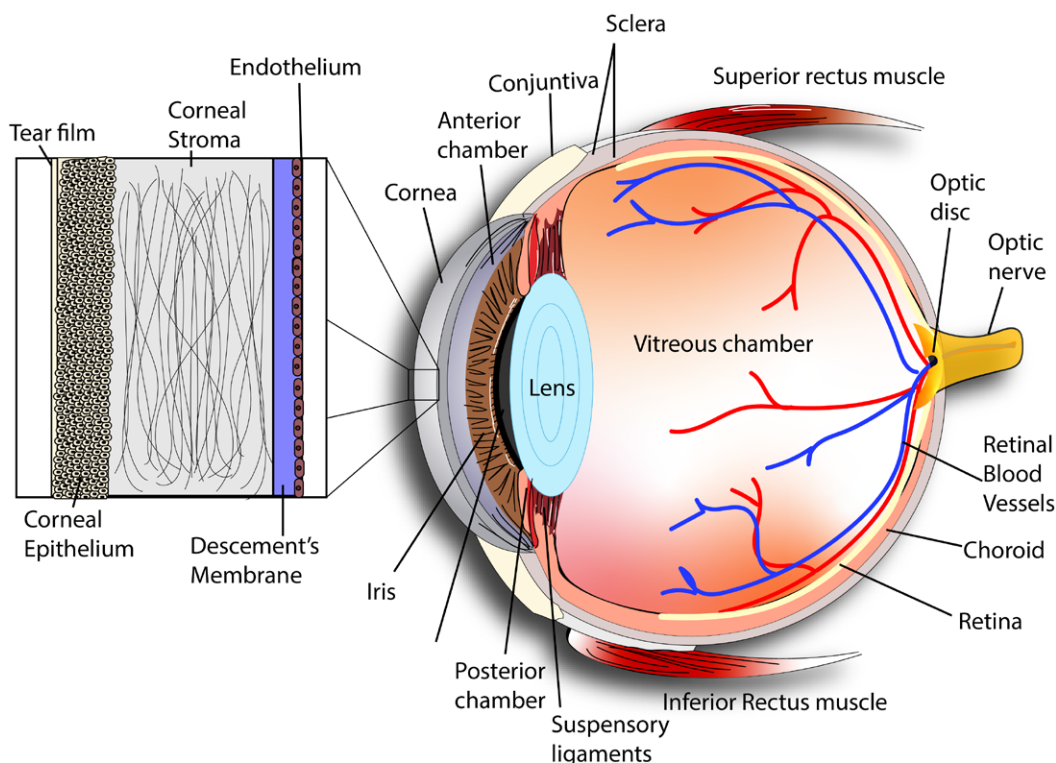
See case studies!

[Sentrxanimalcare.com/casestudies](https://sentrxanimalcare.com/casestudies)



- Taylor Wickware, BS, DVM
- DJ Haeussler, Jr., BS, MS, DVM, DACVO

ANATOMY AND PHYSIOLOGY OF THE CORNEA



Dog eye anatomy

The cornea is composed of four layers; the outer epithelium, stroma, Descemet's membrane, and endothelium. The healthy cornea should be clear in order to refract sufficient quantity and quality of light into the eye. This light is then focused to form an image on the retina. Clarity is maintained by specific characteristics of each of the four layers.

Epithelium

The corneal epithelium is composed of non-keratinized stratified squamous cells. The epithelium is lipophilic, working as a barrier to the underlying stroma to maintain clarity. Absence of pigment, and vessels are also important for maintaining clarity and vision in the cornea. The entire epithelium has a turnover rate of approximately seven days

and undergoes a constant cycle of proliferation and shedding in a healthy state. Healing of the entire corneal epithelium can occur within 72 hours in some species when damaged. Damage to this layer can result in focal or diffuse corneal edema from a decreased barrier to fluid. Chronic inflammation may result in vascularization or pigmentation of the cornea, thus impacting vision.

Stroma

The corneal stroma makes up approximately 90% of corneal thickness. This layer is hydrophilic and will swell with water uptake, reducing clarity. Blood vessels should not be present, though there is sensory innervation to the outer third of the cornea. This innervation is the cause of extreme pain for corneal ulceration. This layer is made of collagen



fibrils arranged in a parallel fashion. Stromal replacement occurs after the epithelium works to cover defects. Over time, proliferation of collagen occurs to restore the corneal curvature. Disorganized arrangement upon healing may result in scarring and decreased vision and inflammation leading to vascularization of this layer may also impact vision.

Descemet's Membrane

Descemet's membrane is the basal lamina of the endothelial layer. This layer has mild elastic properties and does not retain fluorescein dye. In health, this layer becomes thicker throughout an animal's life and during corneal healing, endothelial cells are able to produce new Descemet's membrane after several weeks of healing for full thickness injuries.

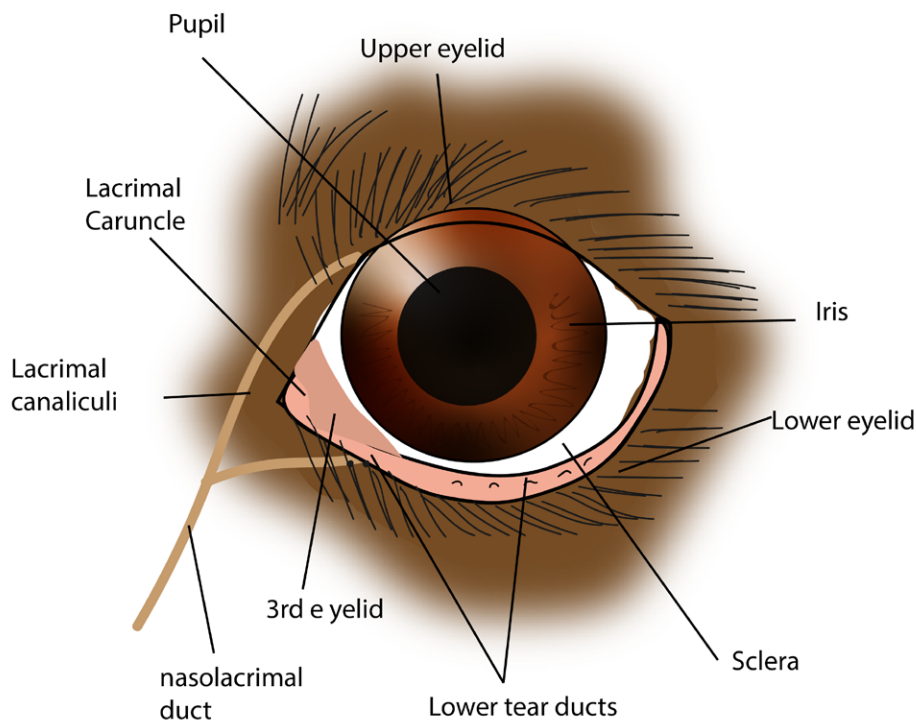
Endothelium

The endothelium is the last layer consisting of a monolayer of hexagonal cells that do not undergo mitosis. Similarly to the epithelium, this layer is a barrier to the stroma to

maintain corneal clarity which is aided by tight cellular junctions. Healing of this layer is accomplished via cell enlargement and migration or sliding. This results in decreased cell density of the endothelium after healing and with age. The endothelium contains Na⁺,K⁺-ATPase ion pumps which work to remove fluid from the stroma to regulate its hydration. Thinning or damage of the endothelium can affect clarity as the hydration status of the stroma increases, resulting in corneal edema. Corneal endothelial dystrophy is an inherited condition leading to corneal stromal and epithelial edema. This can cause bullae, painful ulceration, and pigmentation in addition to the edema that reduces clarity and vision. Similar sequelae can be observed in older dogs that develop corneal epithelial degeneration as this corneal layer thins with age.

References

1. Gelatt, Kirk N. *Veterinary Ophthalmology*. Blackwell, 2013.
2. Gelatt, Kirk N., and Janice P. Gelatt. *Veterinary Ophthalmic Surgery*. Saunders Ltd., 2011.
3. Maggs, David J., et al. *Slatter's Fundamentals of Veterinary Ophthalmology*. Saunders Elsevier, 2008.



Dog eye anatomy



- Erica Bono, BS, DVM
- DJ Haeussler, Jr., BS, MS, DVM, DACVO

CONDITIONS COMMONLY RELATED TO A REDUCTION IN CANINE CORNEAL HEALTH

Corneal health starts at the adnexa of the eye. Every eye exam should begin with a thorough gross examination of the patient at rest, along with appropriate preliminary diagnostics. Good eyelid conformation, as well as appropriate tear production and quality, are crucial for the lasting health of the cornea. There are many breed related conditions, especially in the dog, that should be addressed by a veterinary ophthalmologist early on for treatment to prevent the development of corneal damage and promote the lasting health of the cornea. The following are some examples of such conditions:

Keratoconjunctivitis Sicca (KCS) is a quantitative tear film deficiency disorder that is most commonly seen in dogs as an immune mediated condition. KCS can also be neurogenic, drug-induced, or secondary to systemic disease, such as distemper or other metabolic diseases, such as hypothyroidism, diabetes mellitus, or Cushing's disease. This is a common disorder diagnosed in dogs, which is why it is crucial to perform a Schirmer Tear Test (STT) on every patient presenting with an ocular complaint. In a normal dog, a STT should exceed 15mm in 60 sec. Diagnosis of KCS is based on a STT of <10mm/min; however, a STT of 11-14 mm/min is suspicious of the disorder. Clinical manifestations of KCS include conjunctival hyperemia, mucoid to muco-purulent discharge, keratitis, blepharitis, and even corneal ulceration. Patients with underlying systemic disease, such as diabetes mellitus, are at an even higher risk of developing severe corneal ulceration due to presence of decreased corneal sensitivity in addition to KCS. Therapy for KCS includes lacrimostimulants (i.e., Cyclosporine A or Tacrolimus), lacrimomimetics (i.e., HA containing ophthalmic ointments), prophylactic antimicrobials, mucinolytic agents (i.e., Acetylcysteine), and anti-inflammatories (i.e., topical steroids, if no concurrent ulceration is present). The use of tear replacement ointments containing HA or cross-linked HA can be helpful in the prevention of severe corneal ulcerations in these cases, especially during the initial four weeks of treatment due to the delayed onset of action of the lacrimostimulants. Severe cases, such as neurogenic KCS or cases which are refractory to medical management, may ultimately require a Parotid Duct Transposition in order to maintain appropriate



lubrication of the cornea to prevent the development of severe corneal ulcers secondary to KCS.

Euryblepharon (aka Macropalpebral Fissure) is a congenital condition where the eyelid fissure is larger than normal and causes increased scleral exposure. This condition is commonly seen in both large breed dogs and small brachycephalic dogs. Euryblepharon is commonly associated with lagophthalmos, pigmentary keratitis (brachycephalic dogs), and entropion/ectropion (large breed dogs). In canines, the length of the eyelid fissure when stretched should measure approximately 33 mm. For the diagnosis of euryblepharon, the fissure will measure 5 to 15 mm longer. Referral to a veterinary ophthalmologist is recommended for evaluation and surgical correction, which might involve a medial and/or lateral canthoplasty, keeping in mind that other more extensive blepharoplasty procedures might be indicated depending on the severity of the condition. Eye lubrication with HA-containing



ophthalmic ointments can be helpful in the management of severe cases, or cases where lagophthalmos is present, until the condition is able to be surgically corrected.

Ectropion is a developmental condition where the eyelid margin is everted. This condition is most commonly seen along the inferior lid and is often diagnosed in large and medium breed dogs with accompanying secondary euryblepharon or canthal ligament laxity. Ectropion can also be an acquired condition often caused by other disease processes such as facial nerve paralysis, scar tissue formation secondary to previous trauma, or overcorrection from a previous entropion surgery. Ectropion predisposes the cornea to exposure keratitis, which can ultimately lead to corneal ulceration. Referral to a veterinary ophthalmologist for evaluation and appropriate surgical correction is recommended.

Entropion is most commonly a developmental condition where the eyelid margin is inverted, potentially leading to secondary trichiasis, blepharospasm, epiphora, enophthalmos, secondary conjunctivitis, and ulcerative keratitis. Entropion is frequently seen in young, large breed dogs secondary to their eyelid conformation; however, it can also be an acquired condition secondary to marked blepharospasm. Entropion arises due to excessive eyelid length (i.e. euryblepharon), lack of support of the eyelids by the globe (i.e. enophthalmos, microphthalmos, phthisis bulbi), excessive skin on the forehead and subsequent upper lid ptosis, and increased tone of the orbicularis oculi muscle (i.e. spastic entropion). Referral to a veterinary ophthalmologist is recommended for evaluation and surgical correction via the Hotz-Celsus surgical technique, and/or more extensive blepharoplasty procedures depending on the extent of the condition. Puppies can also develop a transient entropion during growth. The use of temporary tacking sutures can be utilized to save the cornea while they are growing. Permanent procedures are recommended if the entropion persists once they are full grown.

Trichiasis is a developmental condition where the eyelid hairs, or facial hairs, are abnormally positioned towards the cornea. This is especially common in brachycephalic breeds. Clinical manifestations include epiphora, pigmentary keratitis, chronic conjunctival hyperemia, and occasionally corneal ulceration. For severe cases, referral to a veterinary ophthalmologist is recommended for evaluation and appropriate surgical correction depending on the type of trichiasis that is present. Some less severe cases may be able to be managed successfully with the long-term use of eye lubrication using HA-containing ointments and proper grooming.

Distichiasis is a condition where there is abnormal growth of cilia through the meibomian gland openings of the eyelid margin. It is one of the most common inherited eyelid diseases in the dog and can involve both the upper and lower eyelid, and can be a unilateral or bilateral disease. Distichiasis can be difficult to appreciate without the use of biomicroscopic examination. Some of these cases can be subclinical; however, if there is resulting keratitis, then referral to a veterinary ophthalmologist for evaluation and potential cryoepilation or electroepilation of the abnormal cilia is recommended.

Ectopic Cilia is a condition where there is abnormal growth of cilia through the palpebral conjunctiva. Ectopic cilia can appear on the superior or inferior eyelid and can involve one or both eyes. Clinical manifestations include blepharospasm, increased blink rate, epiphora, and are commonly associated corneal ulceration. Diagnosis of this condition can be challenging and requires the use of biomicroscopic examination. Treatment includes referral to a veterinary ophthalmologist for en-bloc resection +/- cryotherapy of the abnormal cilia due to the high likelihood of corneal ulceration and ocular pain that they can cause.


References:

1. Gelatt KN., Gilger BC., Kern TJ. *Veterinary Ophthalmology*. 5th ED. 2013
2. Maggs DJ, Miller PE, Ofri, R. *Slatter's Fundamentals of Veterinary Ophthalmology*. 6th ED. 2018



- Erica Bono, BS, DVM
- DJ Haeussler, Jr., BS, MS, DVM, DACVO

HYALURONIC ACID: CAN WE USE THIS TO BETTER CANINE AND FELINE CORNEAL HEALTH?



What is it:

Hyaluronic Acid (HA) is found in many commercial topical tear film replacement therapies. It is a high molecular weight glycosaminoglycan that is naturally occurring in the body that helps support the wound healing process. HA has been found to have ameliorative effects in cases of keratoconjunctivitis sicca (KCS)¹. HA-containing artificial tear products can recreate the viscous nature of natural tears due to its mucus-adhesive properties, while at the same time containing properties that facilitate the natural blinking process¹. Ultimately, HA helps stabilize pre-corneal tear film and improves corneal hydration and lubrication. HA has also been shown to stimulate corneal epithelial cell migration and adhesion²⁻⁴.

Why cross-linked HA: The main limitation of non-cross-linked HA containing tear replacement therapies is the frequency at which owners need to apply the medication (4 to 6 times daily) in order to achieve an appropriate response to treatment. It has been found that cross-linked HA formulations have increased the amount of time HA exists on the cornea, thus leading to the same benefits that regular HA solutions provide, with the added benefit of decreased dosing frequencies^{5,6}. Cross-linked HA has also been found to aid in the faster healing of some corneal ulcers when compared to non-cross-linked HA⁷⁻⁹. This added benefit of cross-linked HA makes these types of tear film replacements superior when choosing between a product to use for patients with existing corneal damage.



How does it work:

Cross-linking is a chemical strategy that links HA molecules to one another, creating a polymer network. This process extends the retention properties of HA and decreases its susceptibility to enzymatic degradation, which ultimately reduces the number of times it needs to be re-applied to the cornea during the day^{5,6}. The increased tissue scaffolding matrix that is formed secondary to cross-linking is also conducive for re-epithelialization over corneal defects⁷⁻⁹. There have been multiple studies performed evaluating the safety and efficacy of the use of cross-linked HA in both KCS treatment and corneal wound treatment. In one study, evaluating exaggerated dosing in rabbits for 28 days, it was concluded that cross-linked HA is very safe. The same study also evaluated the use of cross-linked HA for treatment of acute ulcer healing in dogs and cats. It was found that acute ulcers treated with cross-linked HA healed significantly faster when compared to those treated with non-cross-linked HA⁹. These findings provide insight that, when used appropriately, cross-linked HA can aid in the healing of certain corneal ulcers due to its properties on epithelial cell migration and adhesion.

Clinical Application: Lacrimomimetics, such as HA containing ophthalmic ointments, are crucial when it comes to treating patients with KCS, as well as in patients where lagophthalmos, amongst other eyelid disorders, is present. These conditions predispose the cornea to significant ulceration, which sometimes require emergency conjunctival grafting procedures by a veterinary ophthalmologist to save the eye. Applying a tear replacement ointment to the eye throughout the day can help sustain the health of the cornea and help prevent ulcers from occurring. However, owner compliance is important for the efficacy of these medications. Cross-

linked HA has shown benefits in both the healing of corneal ulcers, as well as increased owner compliance due the decreased frequency of application. This type of tear replacement therapy may be a good choice for patients suffering from tear film deficiency disorders, as well as other disorders that predispose the cornea to ulceration.

References:

1. Hamano T, Horimoto K, Lee M, Komemushi S. *Sodium hyaluronate eye drops enhance tear film stability*. Jpn J Ophthalmol. 1996; 40(1):62–65
2. Gomes, J.A.P.; Amankwah, R.; Powell-Richards, A.; Dua, H.S. *Sodium hyaluronate (hyaluronic acid) promotes migration of human corneal epithelial cells in vitro*. Br. J. Ophthalmol. 2004; 88: 821–825.
3. Inoue, M.; Katakami, C. *The effect of hyaluronic acid on corneal epithelial cell proliferation*. Investig. Ophthalmol. Vis. Sci. 1993; 34: 2313–2315.
4. Nishida, T.; Nakamura, M.; Mishima, H.; Otori, T. *Hyaluronan stimulates corneal epithelial migration*. Exp. Eye Res. 1991; 53: 753–758.
5. Williams, D.L.; Mann, B.K. *Efficacy of a crosslinked hyaluronic acid-based hydrogel as a tear film supplement: A masked controlled study*. PLoS ONE. 2014; 9: 1-6.
6. Williams, D.L.; Mann, B.K. *A crosslinked HA-based hydrogel ameliorates dry eye symptoms in dogs*. Int. J. Biomater. 2013; 2013.
7. Fallacara, A.; Vertuani, S.; Panozzo, G; et. al. *Novel Artificial Tears Containing Cross-Linked Hyaluronic Acid: An IN Vitro Re-Epithelialization Study*. Molecules. 2017; 22: 1-13.
8. Nishida, T.; Nakamura, M.; Mishima, H.; Otori, T. *Hyaluronan stimulates corneal epithelial migration*. Exp. Eye Res. 1991; 53: 753–758.
9. Williams, D.L.; Wirostko, B.M.; Gum, G.; Mann, B.K. *Topical cross-linked HA-based hydrogel accelerates closure of corneal epithelial defects and repair of stromal ulceration in companion animals*. Investig. Ophthalmol. Vis. Sci. 2017; 58: 4616–4622.





- **Taylor Wickware**, BS, DVM
- **DJ Haeussler, Jr.**, BS, DVM, DACVO

UNDERSTANDING CORNEAL ULCERATION

Corneal ulcers are an erosion or wound on the surface of the cornea resulting in loss of the corneal epithelium. Corneal ulcers can be considered simple or complicated. Simple ulcers involve the corneal epithelium and typically heal within one week's time. Complicated ulcers are defined by an ulcer that involves the stroma, persists for over one week, or becomes infected.

Diagnosing a corneal ulcer

Determining the etiology for corneal ulcerations is important for guiding the treatment plan. A full ophthalmic examination should be performed including Schirmer tear testing, fluorescein staining, and close assessment for adnexal abnormalities, palpebral fissure size, globe movement and position, trauma, or foreign material.

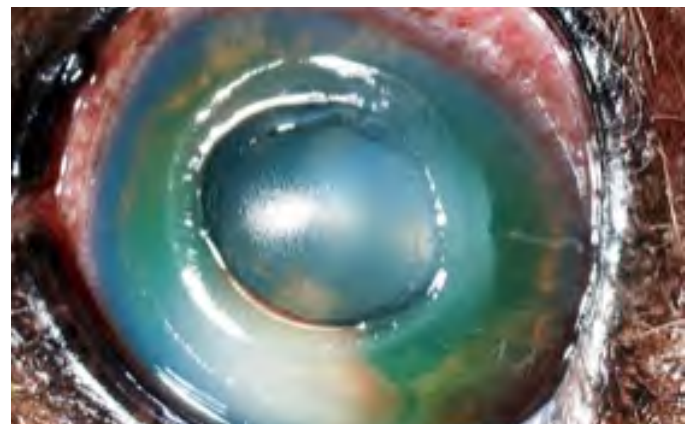
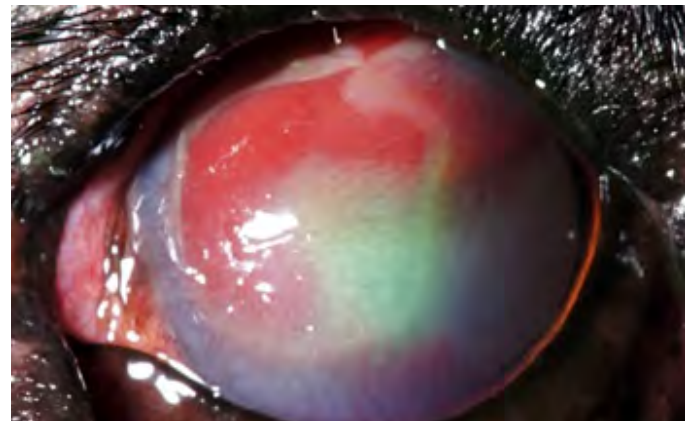
Cranial nerves (CN) should also be tested to evaluate blink response (CN V and VII) and if the affected eye is visual and light responsive with menace and pupillary light reflex (PLR) testing (CN II and III). If a primary cause is noted for the ulcer, it will likely increase the risk of the ulcer becoming complicated or indicate the need for referral for additional therapeutic procedures in the future (i.e. adnexal surgery, diamond burr debridement, dry eye management, conjunctival grafting).

Careful attention to fluorescein stain uptake patterns will also indicate if referral is necessary. Superficial ulcers have distinct borders and show positive stain uptake on the "floor" of the ulcer. As ulcers become deeper, the walls will have positive stain uptake with occasional diffusion into the nearby stroma, creating less distinct margins. Continuing to progress, descemetocelles will not stain at the center of the ulcer, though the stroma surrounding the defect will show positive stain uptake.

An ulcer at any depth should be examined for possible infection. Signs of infection can be as mild as a subtle yellowish green discoloration surrounding the defect to loss of rigidity of the corneal surface resulting in a dissolution of the stroma ventrally (melting corneal ulcer).

Simple ulcers

If no persistent inciting cause is found, or is removed (i.e. superficial foreign material), treatment may be initiated for simple, superficial corneal ulcers. Broad spectrum



topical antibiotics every 6 hours (neomycin, polymyxin B, bacitracin), pain relief via topical atropine once daily, oral pain medications (NSAIDs or gabapentin), tear stimulants if warranted, hyaluronic acid tear supplements, and an E-collar to prevent self-trauma.

Re-evaluation is recommended within 5-7 days for superficial ulcers or sooner if the owner notes worsening signs at home. If the ulcer is not healed, refer for further evaluation for anatomical abnormalities (ectopic cilia, palpebral fissure size, globe and eyelid conformation), more aggressive medical management, debridement of indolent ulcer, or possible surgery if the ulcer has progressed.

Complicated ulcers

Referral to a board-certified ophthalmologist is recommended for deep stromal ulcers, descemetocelles, and melting corneal ulcers. Referral will allow for closer



monitoring and aggressive care including collecting samples for culture and sensitivity to adjust medical management as the ulcer is monitored if surgical intervention is not initially warranted. Surgical intervention is beneficial for stabilizing stromal ulcers affecting greater than half of the corneal thickness, descemetocoeles, melting corneal ulcers, or already perforated globes. Perforation can be identified by visualizing synechia in the anterior chamber involving the defect or bulging of the iris (iris prolapse) as it aids to plug the corneal defect. These lesions are intricately repaired with various corneal grafts using surgical microscopes.

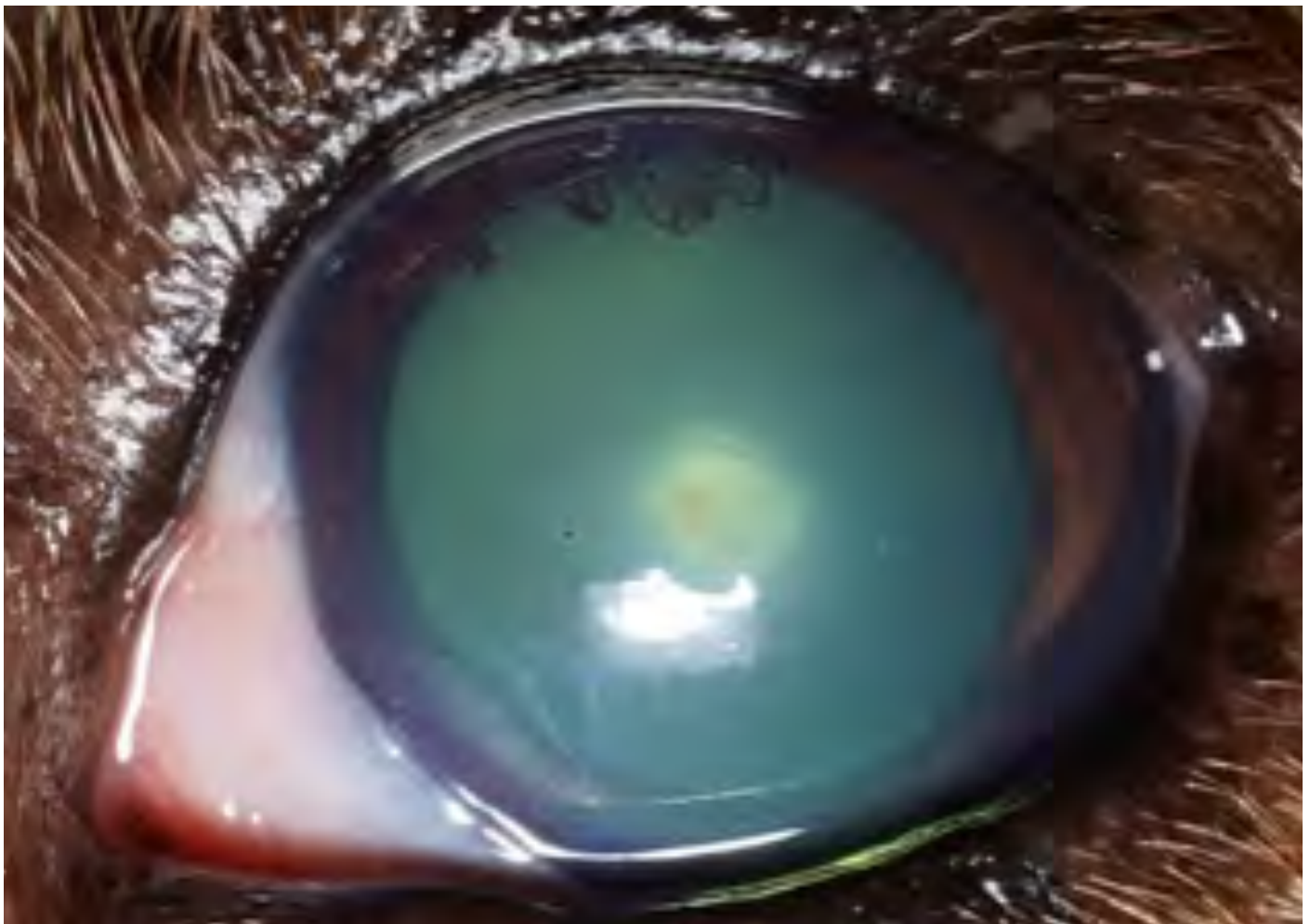Owners should be counseled on the risks for rapid progression if treating complicated ulcers medically. Follow up should be scheduled within 24-48 hours of initiating aggressive treatment to monitor for corneal perforation. Antibiotics with additional gram negative and bactericidal coverage (fluoroquinolones, cephalosporins, aminoglycosides) should be used in complicated ulcers.

Application every 2-4 hours for very deep ulcers in the initial 24-48 hours is recommended along with avoiding ointments due to the risk of uveitis if corneal perforation occurs. Anticollagenase products should also be added to

this protocol. Topical serum every 2-4 hours acts locally to prevent the proteolytic properties of bacteria while oral doxycycline (10mg/kg/day) acts systemically for its antibiotic, anti-inflammatory, and anti-collagenase properties. Both will act to prevent worsening infection and a melting corneal ulcer. Hyaluronic acid containing tear supplements can also be used to improve healing.

References

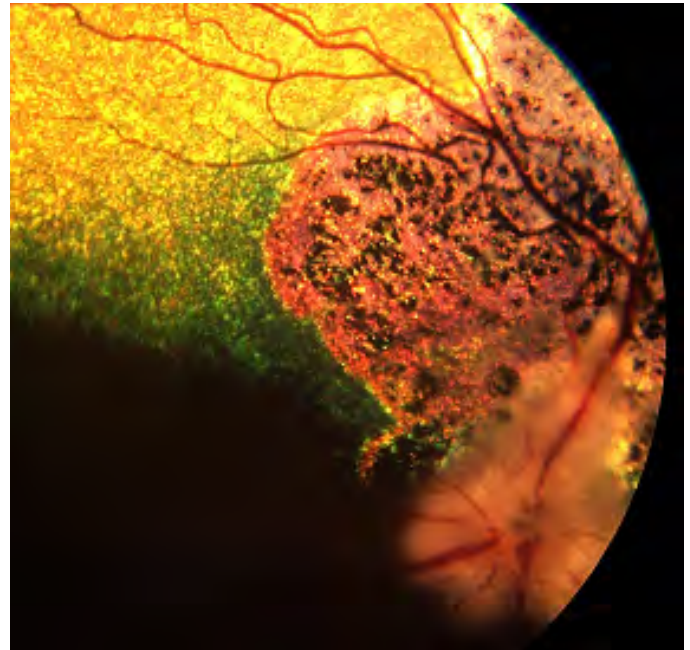
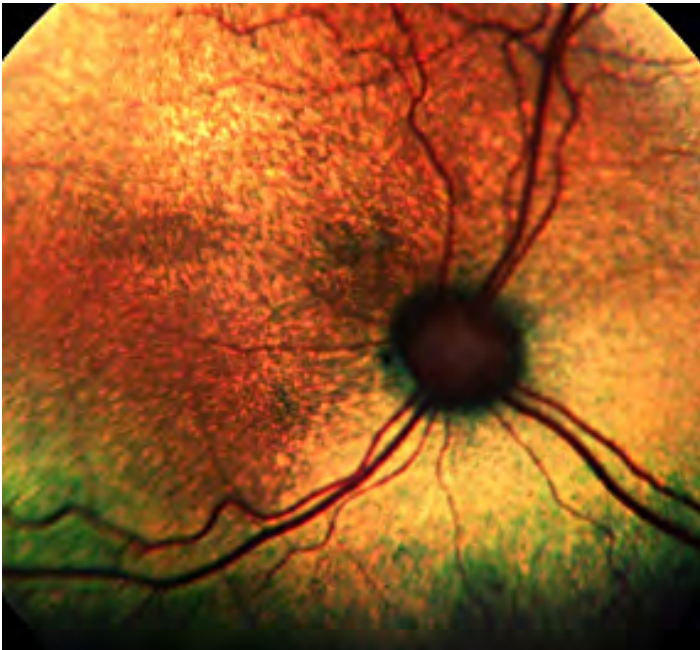
1. Gelatt, Kirk N. *Veterinary Ophthalmology*. Blackwell, 2013.
2. Gelatt, Kirk N., and Janice P. Gelatt. *Veterinary Ophthalmic Surgery*. Saunders Ltd., 2011.
3. Maggs, David J., et al. *Slatter's Fundamentals of Veterinary Ophthalmology*. Saunders Elsevier, 2008.





■ **DJ Haeussler, Jr., MS, DVM, DACVO**

UNDERSTANDING NORMAL VERSUS ABNORMAL RETINAS



The retina is a layer at the back of the eyeball containing cells that are sensitive to light and that trigger nerve impulses that pass via the optic nerve to the brain, where a visual image is formed. There are several diseases that affect the retina.

Proper Equipment

- Direct Ophthalmoscope
 - Poor view of retina
 - ◆ 5-degree field of view of retina
 - Good for optic nerve evaluation
 - Slit beam to detect aqueous flare
 - Cobalt light to detect fluorescein stain uptake
- Panoptic Ophthalmoscope
 - Better view of retina as compared to the direct ophthalmoscope
 - ◆ 25 degree field of view
 - o Better working distance from patient as compared to the direct ophthalmoscope
- Indirect Ophthalmoscope
 - Best view of retina by far
 - Welch Allyn has a nice 20D lens for \$100 (model 12300)
 - View of retina is superior compared to direct

ophthalmoscope

- Remember that the image is upside down and reversed
- Finoff Transilluminator
 - Halogen
 - Focal Light Source
 - Evaluation of pupillary light reflexes
 - Light source for indirect ophthalmoscopy

Fundus

- Consists of:
 - Tapetum
 - Non-tapetum
 - Optic Nerve
 - Retina
- The canine and feline eye are incredibly difficult to evaluate due to the number of normal variants

Feline Fundus

- Much less variation than the canine fundus
- Optic nerve head is poorly myelinated
- Much broader tapetum
- Nontapetum can be pigmented or poorly pigmented
- Normal variants



Sudden Acquired Retinal Degeneration Syndrome (SARDS)

- Typically affects middle aged (7-9 year old) dogs
- Owners presenting complaints: dilated pupils, blindness
- Frequently, PU/PD/PP
- Completely unknown cause
- Minimal retinal abnormalities
 - Patchy tapetal hyperreflectivity
 - Retinal vascular arteriolar "box carrying"
- Definitive diagnosis is through an electroretinogram (ERG)
 - Separates retinal disease from optic nerve/CNS disease
- No treatment

Progressive Retinal Atrophy

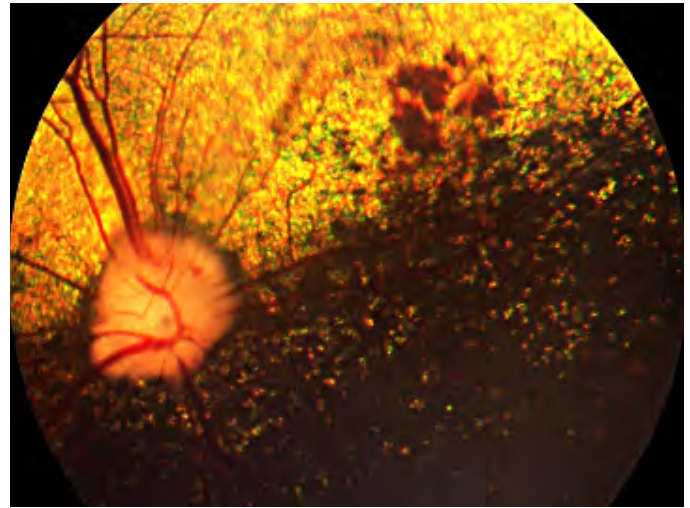
- Variable Age (typically 6+ year old)
- Progressive vision loss
- Night blindness first, then day blindness
- Cataract formation typically comes later
- Increased risk of glaucoma due to lens induced uveitis from the cataract as well as retinal degeneration
- Clinical Abnormalities:
 - Tapetal hyperreflectivity
 - Vascular attenuation
 - Optic nerve pallor
 - +/- Cataracts
- Subretinal Petechiae
- Can take months to resolve even when the underlying cause is corrected

Feline Retinal Detachment

- Presenting clinical signs typically include dilated pupils and acute blindness
- Average age is 10 years old and older
- In cases of retinal detachment, posterior segment blood, or acute blindness in cats a blood pressure is always indicated
- Normal systolic blood pressure in cats is 120mmHg
- Diastolic is not considered accurate
- Treatment
 - Amlodipine 2.5mg: 1/4 tablet orally once daily until recheck
 - Enalapril? Benazapril? Methimazole? Telmisartan?

Canine Retinal Detachment

- Common Causes:
 - Hypertension
 - Neoplasia
 - Subretinal Infiltrate
 - Vitreoretinal Dysplasia
 - Hypermature Cataract
 - Post Phacoemulsification



Optic Neuritis

- Presentation:
 - Acute vision loss
 - Dilated pupils
- Clinical Abnormalities
 - Papilledema
 - Swollen optic disc
 - Loss of physiologic cup
 - +/- Optic disc hemorrhages
- Causes:
 - Intracranial neoplasia
 - Optic nerve neoplasia
 - Distemper
 - Tick-borne encephalitis
 - Blastomycosis
 - Histoplasmosis
 - Cryptococcosis
 - Ehrlichiosis
 - Toxoplasmosis
 - Idiopathic
 - Vitamin A deficiency
 - Orbital neoplasia
 - Necrotizing Meningoencephalitis
 - Granulomatous Meningoencephalitis
- Diagnosis:
 - Typically made on clinical presentation
 - Etiology based on CSF and/or MRI
- Treatment:
 - Steroids
 - ◆ Treating underlying cause
 - Doxycycline
 - Other immunosuppressants?
- Prognosis:
 - Poor



Optic Nerve Coloboma

- Optic nerve colobomas are congenital malformations of the optic nerve head and peripapillary retina that enlarge or distort the optic nerve circumference (Curtis et al, Rubin et al.)
- They appear as though they have a deep hole or excavation within the nerve head
- The visual field disturbance is unknown and likely variable
 - Difficult to determine in animals due to our rudimentary evaluation of vision
- Can be associated with retinal detachments
- One of the abnormalities seen with Collie Eye Anomaly

What about Puppies?

- The tapetum continues to develop 4 months postnatally
- A blue tapetum is normal for the first four months in the dog as the animal matures

Retinal Dysplasia

- Linear folding of the sensory retina and formation of rosettes composed of variable numbers of neuronal retinal layers around a central lumen
- Potential causes include viral infections, vitamin A deficiency, X-ray irradiation, certain drugs, intrauterine trauma, hereditary
- May be unilateral or bilateral
- Three types:
 - Focal or multifocal retinal dysplasia
 - ◆ Seen as areas of reduced tapetal reflectivity
 - ◆ Green dots or linear streaks
 - ◆ Typically occurs dorsal to optic disc and around dorsal retinal vessel
 - ◆ Does not seem to affect vision
 - Geographic retinal dysplasia
 - ◆ Horseshoe-shaped area most often seen in the central tapetal fundus
 - ◆ Gray or black area encircles the area
 - ◆ Central aspect may be elevated
 - ◆ Can cause visual impairment
 - Complete retinal dysplasia with detachment
 - ◆ Retina is floating in the vitreous, attached at the optic nerve head
 - ◆ Leukocoria is sometimes seen
 - ◆ Wandering or rotary nystagmus is seen
 - ◆ Causes complete blindness

- Multifocal retinal dysplasia
 - Most lesions do not change with time
 - Sometimes they become less obvious
 - Sometimes they become more demarcated
- Geographic retinal dysplasia
 - Lesion never disappears
 - Becomes more demarcated with time
- Complete retinal dysplasia with detachment
 - Complications such as secondary cataract, glaucoma, and hyphema may develop

Hereditary spontaneous retinal dysplasia:

- Bedlington Terrier
- Sealyham Terrier
- Yorkshire Terrier
- Rottweiler
- English Springer Spaniel
- American Cocker Spaniel
- Labrador Retriever
- Golden Retriever
- Geographic retinal dysplasia:
 - King Charles Spaniel
 - Golden Retriever
- Labrador Retriever can develop all three types

Optic Nerve Hypoplasia

- Optic nerves that are less than two standard deviations from the mean diameter are considered statistically abnormal
- If the number of axons is so low that visual and pupillary light reflex deficits are present, this is optic nerve hypoplasia
- Afferent reflex is abnormal
- Efferent reflex is normal
- Pupil is generally partially dilated
- Electroretinogram will be normal
- Heritability has been reported as recessive, dominant, and undefined in Miniature and Toy Poodles

Optic Nerve Aplasia

- Complete absence of retinal ganglion cells and the optic nerve
- No retinal vessels are present
- Seen in these breeds:
 - Beagle
 - Irish Wolfhound

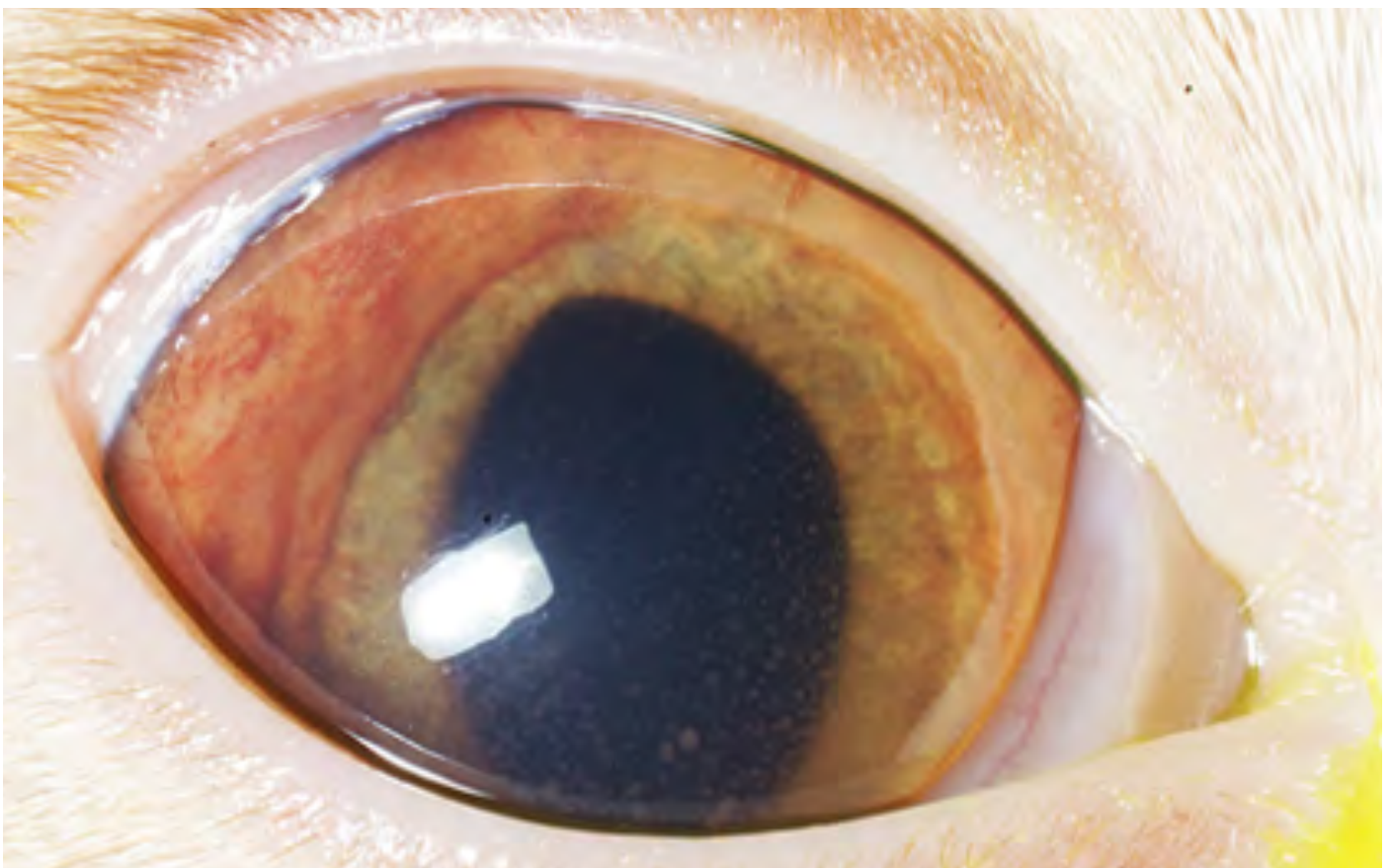


DJ Haeussler, Jr., BS, MS, DVM, DACVO

ANTERIOR UVEITIS IN SMALL ANIMALS

Uveal Anatomy

- Structure
 - Variably Pigmented/Fibrovascular Layer
 - ♦ Highly vascular – nourishment and cooling
 - ♦ Fibrocytes and melanocytes
 - Anterior vs. Posterior
 - ♦ Anterior – iris and ciliary body
 - ♦ Posterior – choroid
 - ♦ Anterior and posterior are continuous
 - Muscular Layer
 - ♦ Iris sphincter and dilator
 - ♦ Ciliary body muscle
- Composed of:
 - Iris
 - Ciliary body
 - Choroid
- Function:
 - Nourishment
 - ♦ Main intraocular vascular supply
 - ♦ Oxygen to highly metabolic retina
 - ♦ Produces aqueous humor
 - ♦ Clear ultrafiltrate
 - Regulates Light
 - ♦ Pupillary aperture
 - Accommodation
- Anterior Uveitis: general points
- Anterior Uveitis: inflammation of the iris and/or ciliary body
- Clinical signs
 - Blepharospasm/photophobia
 - Conjunctival hyperemia/episcleral injection
 - Epiphora
 - Miosis – prostaglandin release





- Aqueous flare – Tyndall effect
- Iritis/rubeosis iridis
- Hyphema
- Corneal edema
- Corneal neovascularization – deep stromal vessels
- Keratic precipitates
- Intraocular pigment dispersion
- Pathophysiology
 - Tissue injury to uveal tract
 - Increased blood flow
 - Inflammatory cell infiltrate
 - ♦ Lymphoplasmocytic, suppurative, granulomatous
 - Vascular permeability – breakdown of blood aqueous barrier
 - Cytokine and prostaglandin release/activation
 - Plasmoid/Fibrinoid aqueous
 - Pre-iridal fibrovascular membrane formation (PIFM)

Ocular Sequelae

- Synechia
 - ♦ Anterior/posterior
 - ♦ Iris bombe
- o Glaucoma
 - ♦ PIFM
 - ♦ Peripheral anterior synechia
- Cataract
- Retinal detachment

Anterior Uveitis: diagnosis

- Diagnosing Anterior Uveitis
 - The classic eye with uveitis
 - ♦ Blepharospasm/photophobia
 - ♦ Conjunctival hyperemia/episcleral injection
 - ♦ Aqueous flare
 - ♦ Miosis
 - ♦ Corneal edema – mild
 - ♦ Rubeosis iridis
 - ♦ Hypotony – compare to contralateral eye
 - ♦ Complete ophthalmic exam
 - ♦ Thorough history
 - ♦ Examine at arms length
 - ♦ Assess menace, dazzle and PLR
 - ♦ Retroillumination – strong pen light or transilluminator
 - ♦ IOP
 - ♦ Fluorescein stain
 - ♦ Schirmer tear test
 - Aqueous flare - essentially pathognomonic for uveitis
 - Golden Retriever Uveitis (Pigmentary Uveitis)
 - ♦ Highly underrecognized in this breed
 - ♦ Must dilate the pupil to see most of the lens capsule
 - ♦ If the patient has radial streaking on the lens capsule, this is typically indicative of this disease
 - ♦ Patients have very low grade, nonpainful uveitis which leads to cataracts
 - ♦ Cataracts will cause additional uveitis and this leads to glaucoma
 - ♦ At minimum, these patients should be managed on topical flurbiprofen or diclofenac once to twice daily and rechecked every 4 months
- Cataracts
 - ♦ Cataracts are one of the leading causes of uveitis in dogs
 - ♦ Diabetic cataracts progress very quickly and this leads to not only uveitis but also leads to lens capsule ruptures
 - ♦ Lens capsule ruptures result in intense uveitis which can lead to retinal detachments and glaucoma
 - ♦ One should not wait on performing surgery on diabetics
 - ♦ Topical anti-inflammatory treatment with diclofenac or flurbiprofen should be utilized once to twice daily
- Ulcerative Keratitis
 - ♦ Corneal ulceration can lead to a reflex uveitis
 - ♦ It is important to not only manage the ulcer but also the uveitis
 - ♦ Atropine helps these patients quite a bit and can be dosed at once to twice daily
 - ♦ In this patient, consider topical antibiotics such as ofloxacin and terramycin, topical anti-inflammatories such as diclofenac, oral anti-inflammatories such as carprofen and topical atropine
 - ♦ Do not use topical steroids with corneal ulceration
- Neoplasia
 - ♦ Tumors can be primary intraocular tumors or secondary as distant metastasis
 - ♦ □Primary intraocular tumors generate very low grade uveitis that is not typically witnessed by the client or the veterinarian
 - ♦ Secondary tumors typically create intense inflammation and secondary glaucoma that is able to be seen by the client and veterinarian
- Fungal
 - ♦ Blastomycosis, Aspergillosis, Histoplasmosis, Coccidiomycosis
 - ♦ In many cases, the eye is the only clinical abnormality
 - ♦ The patient may not be sick...yet
 - ♦ Important to obtain an etiologic diagnosis in order to not only treat the eye appropriately, but also to potentially save the patient's life



- ◆ Solitary ocular lymphoma
- Secondary (metastatic)
 - ◆ Lymphoma
 - ◆ Adenocarcinoma
 - ◆ Fibrosarcoma
 - ◆ Others

Anterior Uveitis: work up

- Approach following diagnosis
 - Questions to ask
 - ◆ Primary or secondary uveitis?
 - ◆ Corneal ulcer, cataract, mass, etc...
 - ◆ Is my patient systemically ill?
 - ◆ Vomiting/diarrhea, coughing, etc
 - ◆ Are lymph nodes enlarged?
 - ◆ Lymphoma is a common cause of uveitis
 - ◆ Check mucus membranes
 - ◆ Petechiae, jaundice, depigmentation, etc

Canine

- Physical Examination
 - ◆ Help direct/prioritize testing
- Routine Labs
 - ◆ CBC, serum biochemistry, urinalysis
- Disease specific testing
 - ◆ Snap 4DX – tick titers
 - ◆ Fungal urine and serology
 - ◆ Lymph nodes aspirates
 - ◆ +/- Leptospirosis
- Imaging
 - ◆ X-rays and ultrasound
- Biopsy
- Aqueocentesis/vitreocentesis
- Enucleation
- Feline
 - Physical Examination
 - ◆ Help direct/prioritize testing
 - Routine Labs
 - ◆ CBC, serum biochemistry, urinalysis
 - ◆ Disease specific testing
 - ◆ FeLV/FIV
 - ◆ Coronavirus titer
 - ◆ Toxoplasmosis titer
 - ◆ Fungal serology
 - Imaging
 - ◆ X-rays and ultrasound
 - Biopsy
 - Aqueocentesis/vitreocentesis
 - Enucleation

Anterior Uveitis: treatment

- Topical
 - First line for anterior segment
 - Corticosteroids
 - ◆ Only if corneal fluorescein stain negative
 - ◆ Every 8-6 hours, then taper
 - Non-Steroidal
 - ◆ Generally safe with corneal ulceration
 - ◆ Every 6-8 hours, then taper
 - Mydriatics
 - ◆ Atropine
 - ◆ Every 8-12 hours, taper quickly
 - ◆ DO NOT use if IOP is high or high normal
 - ◆ Do not use atropine if concurrent KCS
 - ◆ Use atropine ointment in cats
- Systemic
 - Use if posterior segment involvement, or if topical alone ineffective
 - Corticosteroids
 - IMPORTANT to rule out systemic mycosis first
 - Dose and taper is cause/disease dependent
 - Non-Steroidal Anti-Inflammatories
 - ◆ Carprofen and meloxicam preferable
 - Analgesia
 - ◆ NSAIDs and tramadol quite effective
 - Antimicrobials
 - ◆ Disease dependent
 - Immunosuppressants
 - ◆ May be required in autoimmune cases

Concurrent Disease

- Manage underlying/concurrent disease
 - ◆ Ulcerative keratitis
 - ◆ Cataract
 - ◆ Glaucoma
 - ◆ Etc, etc
- Management
 - Recheck early in the beginning
 - ◆ 1 week, 2 weeks maximum for initial recheck
 - ◆ Irreversible intraocular changes can happen quickly
 - ◆ High likelihood of glaucoma if inflammation persists
 - Initially a guarded prognosis
 - ◆ Underlying cause
 - ◆ State of eye at presentation
 - ◆ Response to treatment
 - Often a chronic disease
 - ◆ Educate clients
 - ◆ Recheck periodically
 - ◆ Medication adjustments likely



■ **DJ Haeussler, Jr., BS, MS, DVM, DACVO**

KEEPING VISION IN FOCUS: DISEASES AND SURGERY OF THE LENS

Lens:

- Anterior Epithelium
- Posterior Epithelium
- Equator
- Cortex
- Nucleus

Intraocular Pressures

- If a patient has any concern for lenticular disease, you should be obtaining intraocular pressures

Nuclear Sclerosis

- Normal age-related change in dogs
- Seen in dogs 6 years of age and older
- The nucleus becomes more dense, but does not restrict vision
- The dog should not be experiencing vision problems
- The veterinarian should be able to obtain a clear fundus examination
- This is NOT a cataract

Cataract

- Opacity to the lens that causes vision impairment
- Occurs in any age of dog
- Occurs in any purebred or mixed-breed dog

Causes of Cataract Formation

- Inherited
- Diabetes Mellitus
- Senile
- Radiation
- Nutritional (Hypocalcemia)
- Progressive Retinal Atrophy
- Lens Luxation
- Uveitis
- Electrocutation
- Drugs/Toxins (Ketoconazole)
- Trauma

What to Expect

- According to a study by Klein et al., Postoperative





complications and visual outcomes of phacoemulsification in 103 dogs (179 eyes): 2006-2008:

- 83% functionally visual at the end of the study
 - ♦ 10% blind
 - ♦ 7% decreased vision
- Complications:
 - ♦ Post-Operative Ocular Hypertension
 - ♦ Corneal Lipid
 - ♦ Uveitis
 - ♦ Intraocular Hemorrhage
 - ♦ Retinal Detachment
 - ♦ Glaucoma
 - ♦ Boston Terriers have a higher complication rate
- According to a study by Sigle et al., Long-term complications after phacoemulsification for cataract removal in dogs: 172 cases (1995-2002):
 - 90% success rate
 - Complications:
 - ♦ Posterior Capsule Opacification
 - ♦ Retinal Detachment (1-2%)
 - ♦ Glaucoma (<10%)
 - ♦ Prevalence of failure was less than 10% at 3 year follow up
 - ♦ Boston Terriers, Cocker Spaniels, Cocker-Poodle, Shih Tzus at a more increased risk of glaucoma
 - ♦ Hypermature cataracts increased the complication rate (refer earlier!)
- According to a study by Lim et al., Cataracts in 44 dogs (77 eyes): A comparison of outcomes for no treatment, topical medical management, or phacoemulsification with intraocular lens implantation:
 - Failure of non-treated eyes compared to medically managed eyes: 65 times higher in non-treated eyes
 - Failure of non-treated eyes compared to surgically managed eyes: 255 times higher in non-treated eyes
 - Failure of medically managed eyes compared to surgically managed eyes: 4 times higher in medically managed eyes
 - Mature and hypermature cataracts had a higher failure rate (refer earlier!)
 - Failure: Glaucoma, severe corneal disease, hyphema,

uveitis

- Diagnostics
- Complete Blood Count
- Biochemical Profile
- Urinalysis
- Urine Culture (if diabetic)
- Blood Pressure
- Electroretinogram
 - To cut or not to cut
 - Normal?
 - Progressive Retinal Atrophy?
 - Sudden Acquired Retinal Degeneration Syndrome?
- Ultrasound
 - Size of Lens
 - Retinal Detachment
 - Lens Capsule Rupture
 - Vitreal Consolidation
 - Intraocular Tumor

Surgical Procedure

- 3mm incision made at the limbus
- Anterior chamber replaced with viscoelastic
- Anterior capsulotomy and capsulectomy performed
- Lens removed via phacoemulsification
- Lens epithelial cells removed from the capsule via irrigation and aspiration
- IOL inserted into the capsule
- Viscoelastic removed with irrigation/aspiration
- Incision closed with 9-0 Vicryl

After Care

- Topical antibiotics (Ofloxacin)
- Oral antibiotics (Clavamox)
- Topical NSAIDs (Flurbiprofen or Diclofenac)
- Oral NSAIDs (Carprofen)
- Topical Lubricant (Optixcare)
- Protective E-collar
- Restricted Activity
- Recheck in 2 weeks
- Reduction of medications over time
- Life-long follow up and medications
- Low fat diets and low fat treats for diabetics

When to Refer?

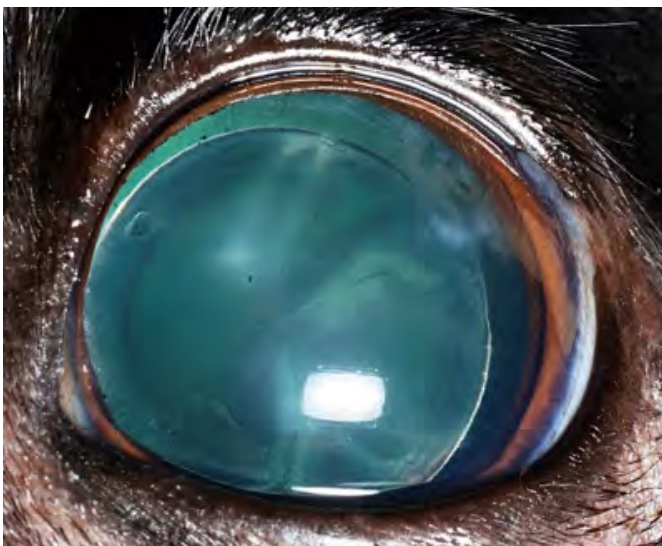
- The sooner, the better outcome
- Allowing the lens to mature, or "ripen" is no longer appropriate
- Diabetics especially need to be referred quickly due to the risk of lens capsule rupture, retinal detachment, glaucoma, and uveitis
- Diabetic Schnauzers need to be referred very quickly due to the risk of lens capsule rupture

What Can You Do?

- Place each patient with cataracts on topical flurbiprofen or diclofenac (topical NSAIDs)

Lens Subluxation

- Many causes of lens subluxations:
 - Congenital

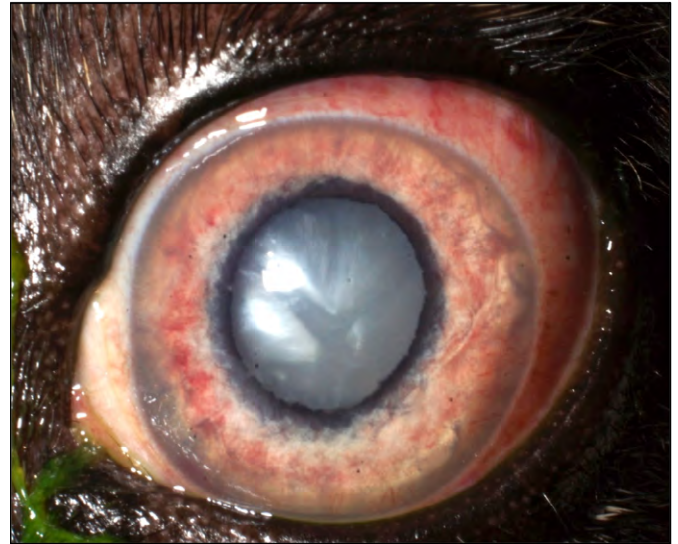




- Primary
 - ♦ Inherited (between 3-6 years of age)
- Secondary
 - ♦ Glaucoma
 - ♦ Uveitis
- Trauma
- According to a study by Oberbauer et al., Inheritance of cataracts and primary lens luxation in Jack Russell Terriers:
 - Inherited in Jack Russell Terriers
 - Due to a mutation in the HSF4 gene
 - Other breeds found to have inherited primary lens luxation
 - ♦ Sealyham
 - ♦ Wire-haired Fox
 - ♦ Mini Bull Terrier
 - ♦ Terrier crosses
 - ♦ Tibetan Terrier
 - ♦ Shar Pei
- Ideal management of lens subluxations is surgical removal of the lens with or without IOL placement
- Alternatively, a miotic can be used if the lens is posteriorly subluxated
 - Latanoprost
 - Demecarium Bromide
- According to a study by Binder et al., Outcomes of nonsurgical management and efficacy of Demecarium bromide treatment for primary lens instability in dogs: 34 cases (1990-2004):
 - At 4-6 weeks and 3 months post diagnosis of lens instability, 100% of dogs retained vision
 - At 1 year post diagnosis, 80% retained vision
 - At 2 years post diagnosis 11/19 (58%) retained vision

Anterior Lens Luxation

- Primary lens luxation in the dog
- Occurs as a hereditary defect in collagen composition of the lens zonules
- Anterior lens luxation may present from mild to severe discomfort,
- conjunctival hyperemia, slight cloudiness to the eye
- Anterior lens luxation constitutes an emergency as a rapid rise in intraocular pressure can result in permanent blindness
- Treatment
 - Lens extraction via intracapsular lens extraction
 - 160 degree corneal incision
 - Vitreal attachments severed
 - Partial vitrectomy performed
 - Large incision increases risk of infection
 - Ongoing risk of retinal detachment due to vitreal degeneration
 - Risk of glaucoma
 - Aphakic (see distance items, struggle with near-field vision)
- What can you do?
 - Start patient on dorzolamide or dorzolamide-timolol TID if intraocular pressures are greater than 25mmHg
 - DO NOT GIVE ANY MIOTICS!



- ♦ Latanoprost
- ♦ Demecarium Bromide
- ♦ Pilocarpine
- Flurbiprofen or Diclofenac SID to decrease subclinical uveitis caused by the lens bumping into intraocular structures
- Refer immediately
- What else can be done?
 - Is the patient visual?
 - Does the patient have a dazzle response?
 - If patient is painful, has increased intraocular pressures, no menace, no dazzle, and referral is not an option:
 - ♦ Enucleation
- If nothing is done, the intraocular pressures are normal, and the lens remains anteriorly luxated, endothelial decompensation can occur
 - This can result in corneal rupture

Posterior Lens Luxation

- Difficult to remove surgically, depending on which technique you prefer
 - I personally prefer to viscofloat the lens with 1.8% viscoelastic or 3% if that does not work
- High risk of retina detachment if the lens is removed or if the lens stays in the vitreous
- High risk of glaucoma if the lens migrates anteriorly
 - If the lens is posteriorly luxated, prescribe a topical miotic (latanoprost) to "trap" the lens into the posterior segment
- These patients typically do not see well, but comfort can be maintained for longer than an anterior lens luxation patient



■ **DJ Haeussler, Jr., BS, MS, DVM, DACVO**

COMMON EYELID DISEASES IN SMALL ANIMAL PATIENTS

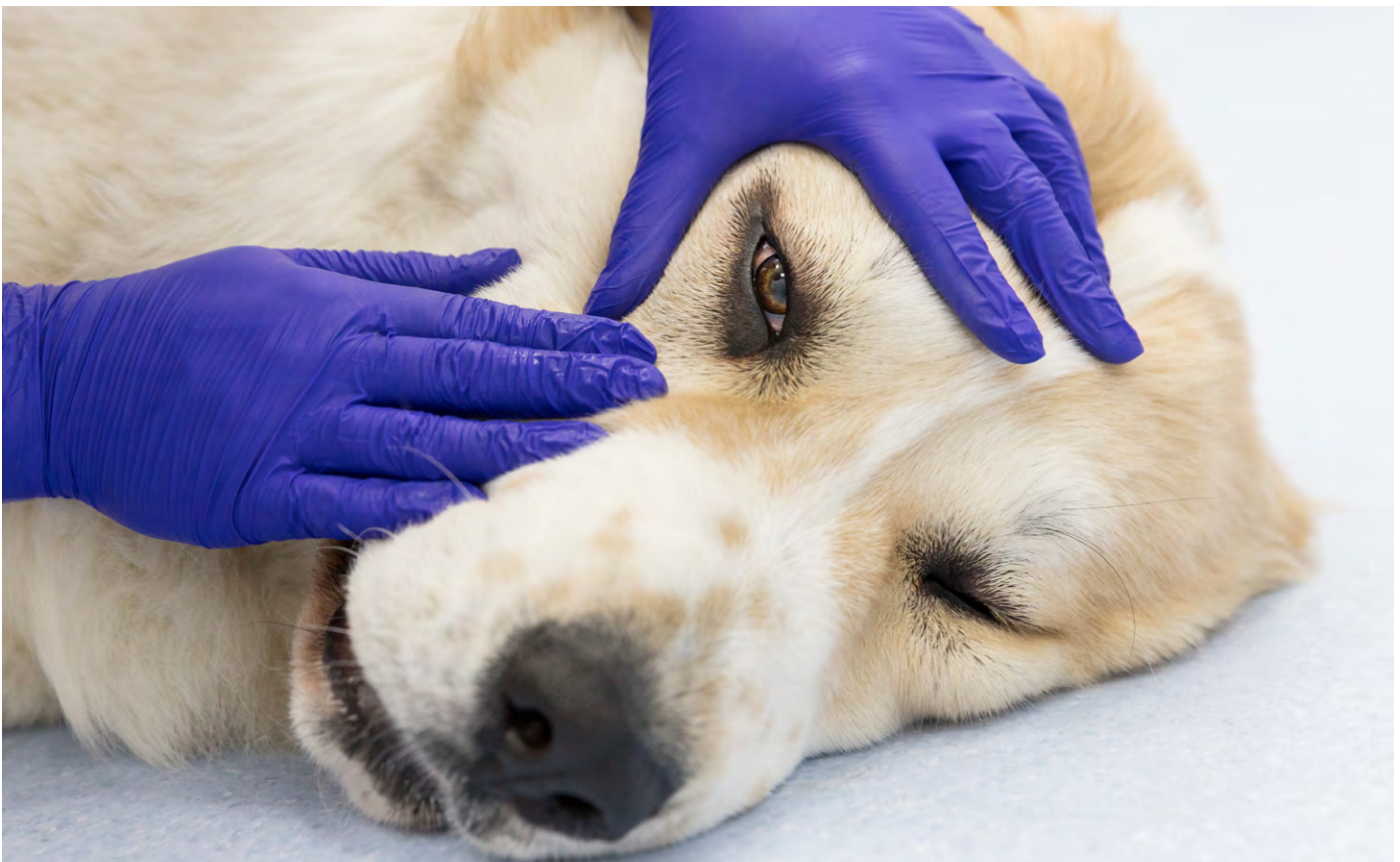Eyelid Anatomy

- Modified skin
 - Epidermis/Dermis
 - ◆ Most domestic species is haired
 - Muscular layer
 - ◆ Orbicularis oculi
 - ✦ Closes the eyelids
 - ◆ Levator palpebrae superioris
 - ✦ Opens the eyelids
 - Tarsal Layer
 - ◆ Meibomian Glands
 - ✦ Modified sebaceous glands
 - ◆ Glands of Moll
 - ✦ Modified sweat glands
 - ◆ Tarsal Plate
 - Conjunctiva
 - ◆ Vessels, nerves, lymphatics
- Function

- Protects the globe
 - ◆ Palpebral reflex
 - ◆ Removes surface debris
- Contributes to tear film
 - ◆ Meibomian glands – lipid layer
 - ◆ Blinking distributes tear film
- Regulates light entering the globe
 - ◆ Squinting

Entropion

- Inward rolling of the eyelid
- Highly breed associated in dogs
 - Usually secondary to excessive eyelid length and prominent facial fold
- Cats
 - Intact males with “stud jowls”
 - Older cats with retrobulbar fat atrophy
 - Cicatricial





- Lower lateral and medial eyelids (dogs) most common
- Upper eyelids less common
 - Shar-Pei, Chow Chow
 - Cicatricial (scarring from previous infection, surgery, or trauma)
- Surgical therapy is indicated for resolution
 - Lateral canthoplasty, modified Hotz-Celsus
- Prior to surgery, it is recommended that patient receive a lubrication with hyaluronic acid
 - Improves patient comfort
 - Reduces risk for corneal ulceration

Distichiasis

- Hairs arising from the eyelid margin
 - Often arise from meibomian openings
 - Single or multiple tufts of hair
- Sequelae
 - Epiphora, mucus discharge
 - Corneal ulceration
 - Squinting
- Surgical therapy involves follicular cryoablation
 - Freezing of the eyelid margin in order to kill the hair follicle and prevent regrowth
- If they are continuously epilated, they will continue to regrow
- Short term medical therapy involves using topical lubrication gel with hyaluronic acid multiple times per day

Ectopic Cilia

- Hairs emerging through palpebral conjunctiva
 - Direct corneal contact
- Sequelae
 - Marked discomfort – blepharospasm
 - Corneal ulceration with keratitis
- Treatment
 - Prior to surgery treat with topical lubrication gel with hyaluronic acid
 - ♦ Utilize antibiotics if there is concurrent corneal ulceration
 - Surgical excision of follicle with cryoablation

Trichiasis

- Normal hairs that are misdirected and contact conjunctiva and cornea
- Common locations:
 - Nasal Folds
 - ♦ Brachycephalics
 - ♦ Component of macropalpebral fissure syndrome
 - Caruncular
 - Upper lateral eyelid
- Sequelae
 - Irritation – blepharospasm, epiphora, mucus discharge
 - Corneal ulceration – especially when a component of entropion
- Treatment
 - Surgical
 - ♦ Nasal Fold Removal
 - ♦ Medial Canthoplasty
 - ♦ Modified Hotz-Celsus
 - ♦ Blepharoplasty
 - Medical

- ♦ Topical lubrication gel with hyaluronic acid
- ♦ Antibiotics if concurrent corneal ulceration

Eyelid Agenesis

- Underdeveloped eyelid margin – partial or complete
 - Most commonly seen in felines
- Sequelae
 - Exposure keratitis
 - Trichiasis
 - Corneal Ulceration
- Treatment
 - Cryotherapy
 - Reconstructive blepharoplasty
 - ♦ Lip-to-Lid
 - ♦ Switch flap

Inflammatory Disease

- Blepharitis
 - Inflammation of the eyelids
 - ♦ Generalized/diffuse or focal
 - Eyelids solely, or component of larger disease process (autoimmune skin disorders)
 - Varying degrees of inflammation, ulceration, alopecia, pruritis
- Etiologies
 - Bacterial, immune-mediated, parasitic, mycotic, pharmacologic (especially in cats), viral (cats with FHV), traumatic
- Immune-Mediated Blepharitis (Primary)
 - Marginal Blepharitis
 - ♦ Eyelids only, meibomian glands
 - ♦ Hypersensitivity to normal meibomian secretions/flora
- Immune-Mediated Blepharitis (Secondary)
 - Component of immune-mediated skin disease
 - Pemphigus (vulgaris, foliaceus), discoid lupus, uveodermatologic syndrome
- Mycotic Blepharitis
 - Microsporium canis, trichophyton, blastomycosis (rare)
 - Generalized condition in young/immunocompromised
 - Alopecia and erythema common
 - Trichogram can be useful in diagnosis
- Parasitic Blepharitis
 - Demodex and Sarcoptes
 - Generalized condition in young/immunocompromised
 - Alopecia, erythema, and pruritis
 - Skin scraping useful in diagnosis
- Viral Blepharitis
 - Feline herpes virus blepharoconjunctivitis
- Parasitic Blepharitis
 - Demodectic blepharitis
- Pyogranulomatous Blepharitis
 - Distinct granulomas centered over meibomian glands
 - Etiology not clearly understood – rupture of meibomian glands, autoimmune, folliculitis, bacterial component
- Blepharitis
 - Sequelae
 - ♦ Ulceration, depigmentation, scarring, necrosis (severe)
 - ♦ Entropion/ectropion – cicatricial
 - ♦ Keratitis – exposure, contiguous with blepharitis



- Treatment
 - ♦ Identify/eliminate any underlying cause
 - ♦ Antimicrobial therapy – ideally based on culture/sensitivity, cytology/skin scraping/trichogram
 - ♦ Corticosteroids – if not mycotic, parasitic, or systemically contraindicated
 - ♦ Biopsy of focal lesions
 - ♦ Surgical correction of entropion/ectropion
 - Chalazion/Hordeolum
 - Focal, non-painful swelling of meibomian gland
 - Various etiologies
 - ♦ Meibomian gland dysplasia, neoplasia, infection
 - Sequelae
 - ♦ Rupture, inflammation, ulceration, secondary infection
 - ♦ Keratitis/ulceration – with large masses and corneal contact
 - Treatment
 - ♦ Monitor if incidental or subclinical
 - ♦ Lance and curettage - +/- cryotherapy
 - ♦ Address neoplasia (excision, debulk/cryoablation)
 - ♦ Antimicrobial therapy
 - ♦ Corticosteroids – typically not indicated, can do topical if inflammation/irritation is present
 - Can regress with no treatment (viral)
 - ♦ Eyelid skin/margin and palpebral conjunctiva
 - Cats
 - ♦ Rare
 - Melanoma
 - Dogs
 - ♦ Two forms
 - ✦ Solitary raised mass – may be multiple
 - ✦ Flat, diffuse mass at eyelid margin (Vizslas overrepresented)
 - ♦ Middle aged to older dogs
 - ♦ Locally aggressive, but low potential for metastasis (primary conjunctival are more aggressive)
 - Cats
 - ♦ No reports of primary eyelid melanoma in cats (conjunctival and nictitating membrane)
 - Mast Cell Tumor
 - Middle-aged to older patients
 - Solitary masses of varying size
 - Ulceration and inflammation common
 - Can spread systemically
 - ♦ Not reported to be common, but seen clinically
 - Can shrink considerably with medical management
 - ♦ Corticosteroids, diphenhydramine
 - Patnaik grading scale not always indicative of behavior or potential for recurrence
 - Squamous Cell Carcinoma
 - Cats
 - ♦ Most common eyelid neoplasm
 - ♦ Older cats – usually older than 11 years old
 - ♦ Depigmented skin, light coat color predisposed
 - ♦ Ulcerative, vascular, expansile epithelial neoplasm
 - ♦ Lower eyelid most common location
 - ♦ Locally aggressive with a fairly high recurrence rate
 - ♦ Metastasis to local lymph nodes in advanced cases
 - ♦ Aggressiveness correlated with cellular pleomorphism
 - Dogs
 - ♦ Rare – represents < 2% of eyelid neoplasms
 - ♦ Locally aggressive with a fairly high recurrence
 - Sequelae
 - Distort/disrupt eyelid function
 - Ulceration with secondary infection/chalazion
 - Keratitis and corneal ulceration from direct contact and poor eyelid function
 - Local recurrence and metastasis
 - Treatment
 - Monitor (presumed benign, small, incidental, subclinical masses)
 - Debulking and cryotherapy
 - ♦ Recurrence rate dependent on species and type of neoplasia
 - Surgical excision – malignant or benign >25% of eyelid
 - ♦ Large masses may require extensive eyelid reconstruction
 - Adjunctive therapy (systemic or local chemotherapy, cryotherapy, radiation, intralesional corticosteroids, etc)
 - Enucleation/exenteration in severe cases
- ### Eyelid Neoplasia
- General Points
 - Dogs
 - ♦ Overwhelmingly benign (>85%)
 - ♦ Generally older (>10 years)
 - ♦ Meibomian adenomas/adenocarcinomas > papillomas > melanomas > all the rest (MCT, histiocytoma, fibroma, SCC, etc.)
 - Cats
 - ♦ Majority malignant (55-70%)
 - ♦ Generally older (>9 years)
 - ♦ SCC > MCT > hemangiosarcoma > adenocarcinoma > all the rest (lymphoma, fibrosarcoma, peripheral nerve sheath tumor, etc)
 - Meibomian Adenoma/Adenocarcinoma
 - Dogs
 - ♦ Most common eyelid neoplasia
 - ♦ Older dogs (>10 years old)
 - ♦ Behave benignly regardless of adenoma or adenocarcinoma (no reports of metastasis)
 - ✦ Adenocarcinoma more likely to recur locally
 - ♦ Upper eyelid most common
 - ♦ Vary in appearance and coloration (pink to darkly pigmented)
 - ♦ Often have associated chalazion
 - Cats
 - ♦ Extremely rare
 - Papilloma
 - Dogs
 - ♦ Bimodal distribution
 - ✦ Young dogs (<3 years old) - viral in origin
 - ✦ Older dogs (squamous papilloma)
 - ♦ Pedunculated, thin stalk, pink to heavily pigmented
 - ♦ Reach a growth maximum



■ **Dr. DJ Haeussler, Jr., BS, MS, DVM, DACVO**

UNDER PRESSURE: GLAUCOMA RECOGNITION AND TREATMENT

Glaucoma

- Glaucoma is an increase in the IOP to a level that is incompatible with the health of the eye
- Glaucoma is the single most common cause of blindness in dogs
- Always the result of a decrease in outflow

Tonometry

- Only way to definitively diagnose glaucoma
- All red, blind, painful, blue eyes should have IOP checked
- All eyes with fixed and dilated pupils should have IOP checked
- All eyes with anisocoria or anterior uveitis should have IOP checked
- All predisposed breeds should have IOP checked during routine examination

Intraocular Pressure

- Normal Intraocular Pressure for a dog is 15-25mmHg.
 - ♦ 10-20 is a good normal range
- Glaucoma pressures will be >25-30mmHg

Aqueous Humor

- Produced by the ciliary body

- Produced by a combination of:

- Active Production (50%)
- Passive Diffusion
- Ultrafiltration

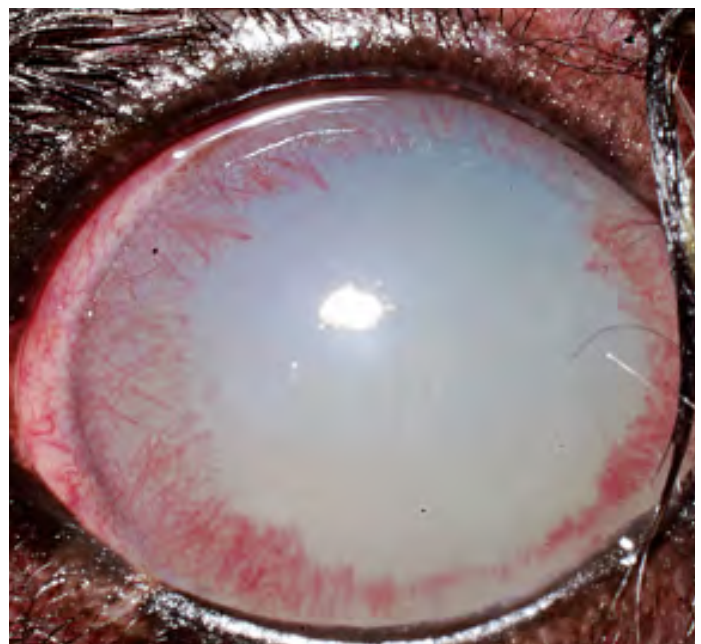
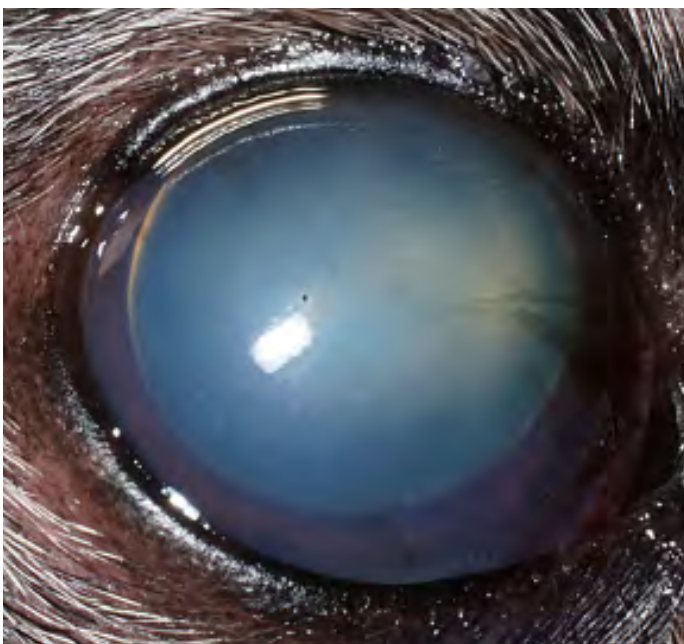
- Active portion is dependent on carbonic anhydrase

Flow of Aqueous

- 1 Ciliary Epithelium
- 2 Between Iris and Lens
- 3 Through Pupil
- 4 Iridocorneal Angle
- 5 Pectinate Ligaments
- 6 Trabecular Meshwork
- 7 Blood Venous System

ABCDs of Primary Glaucoma

- Artic Breeds (Malamute, Husky, Elkhound, Samoyed)
- Beagles
- Basset Hound
- Bouvier
- Bull Mastiff
- Cocker





- Chow Chow
- Dalmation
- Great Dane

Primary Glaucoma


- Not associated with any other ocular disease
- Generally seen in predisposed breeds
- 50% will present bilateral within 2 years
- Check IOP every 3-4 months
- Preventive therapy for “good eye” (Dorzolamide BID)

Pupillary Light Response

- Mydriasis
 - IOP >40mmHg
 - Retinal Degeneration/Detachment
 - Iris Atrophy
- Miosis
 - In combination with increased IOP suggests concurrent uveitis

Secondary Causes

- Anterior Lens Luxation
 - Never give these animals pilocarpine or latanoprost
 - ◆ These medications cause miosis
 - ◆ Causes a pupillary block restricting the normal flow of aqueous
 - ◆ Increases intraocular pressure, causes pain, and potentially will blind the patient
 - Treatment is emergency surgical removal of the lens
 - Terriers have an inherited zonular dysgenesis that causes a lens luxation between 4-8 years old
- Uveitis
 - The most common cause of secondary glaucoma
 - Lens induced, idiopathic/immune mediated, mycoses, bacteremia, septicemia, viremia, infectious, neoplastic, VKH, SLE
 - ◆ Must ascertain and treat underlying uveitis
- Hyphema
 - Retinal detachment and tear
 - Clotting disorders



- Trauma
- Hypertension
- Intraocular Neoplasia
- According to a study by Jinks et al., Causes and Outcomes of dogs presenting with hyphema to a referral hospital in Colorado: a retrospective analysis of 99 cases:
 - ✦ 32.9% due to local ocular disease
 - ✦ 26.1% due to trauma
 - ✦ 4.5% idiopathic
- ◆ Poor Outcomes
 - ✦ Neoplasia
 - ✦ Chronic Uveitis
 - ✦ Trauma
- ◆ Poor Prognostic Indicators
 - ✦ Absent dazzle response
 - ✦ Absent consensual pupillary light response
 - ✦ Elevated IOP
 - ✦ Unilateral hyphema
 - ✦ Complete hyphema

- Hypopyon
 - Inflammatory cells (white) that accumulate in the ventral anterior chamber
 - Corneal Ulceration
 - Septicemia
 - Bacteremia
- Neoplasia
 - Primary
 - Metastatic

Pre-Iridal Fibrovascular Membrane

- PIFM
 - Fibrovascular membrane that grows on the anterior face of the iris and then obstructs the iridocorneal angle
- Secondary to:
 - Retinal Detachment
 - Uveitis
 - Neoplasia

Acute Glaucoma

- Corneal Edema
- Dilated Pupil/Sluggish PLR
- Decreased or absent menace
- Pain
- Episcleral Injection

Chronic Glaucoma

- Corneal Edema
- Absent PLR
- Absent Menace
- Blepharospasm
- Corneal Striae
- Retinal Degeneration
- Engorged Episclera
- Cupped Optic Disc
- Buphthalmia

Mannitol

- Acute glaucoma



- Given IV
- 0.5-1.0gm/kg (over 15-20min)
- Withhold water 3-4 hours
- 20-30min onset; 4-6 hour duration
- Dehydrates vitreous
- Avoid in patients with dehydration, CHF, subdural hemorrhage

Carbonic Anhydrase Inhibitors

- Carbonic anhydrase is required for active production of aqueous
- Methazolamide (2-5mg/kg) (Oral)
 - 20-30% aqueous secretion reduction
 - BID-TID
 - Side Effects: Metabolic acidosis, panting, depression, vomiting, diarrhea
- Dorzolamide 2% (Topical)
 - 20-30% aqueous secretion reduction
 - TID
 - Avoids systemic side effects
 - Can prophylactically treat other eye in primary glaucoma

Autonomic Agents

- Timolol 0.5% (Beta Blocker)
 - Decrease IOP by 5%
 - BID-TID
 - Reduces aqueous production
 - Side effects of bronchoconstriction and bradycardia (potentially)
- Pilocarpine 2% (parasympathomimetic)
 - BID-TID (topically)
 - Constricts ciliary muscles and increases outflow by opening trabecular meshwork
 - Miosis
 - Contraindicated in anterior uveitis
 - Irritating to cornea
 - No longer commonly used
 - Absolutely do NOT use in cases with an anterior lens luxation

Combination Medications

- Dorzolamide-Timolol
 - Lowered IOP by 8.4mmHg in glaucomatous dogs
 - Can decrease heart rate
 - TID in affected eyes, BID prophylactically
- Summary
- Timolol BID
 - 3.75mmHg reduction
- Dorzolamide TID
 - 7.5mmHg reduction
- Dorzolamide-Timolol BID
 - 8.42mmHg reduction

Prostaglandin Analogue

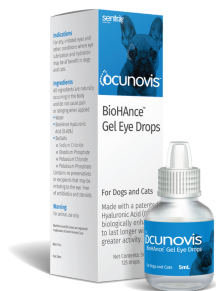- Latanoprost 0.005%
 - Significantly decreases IOP within 1 hour
 - Causes miosis
 - Alters outflow pathway to the uveoscleral pathway
 - BID

- Avoid in patients with uveitis
- Absolutely do NOT use in cases with an anterior lens luxation

Surgical Therapy

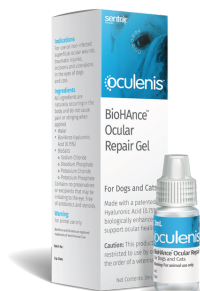- Client Communication
 - Blind vs. Painful
- Cyclocryosurgery
 - Freezes portion of ciliary body to decrease aqueous production
 - High risk
 - Rarely used any more
- Trans-Scleral Cyclophotocoagulation
 - Laser energy destroys ciliary body
 - Energy delivered outside the eye
 - Complications include hemorrhage, uveitis, cataract, worsening glaucoma
- Gonioimplantation
 - Filtering Procedures
 - ◆ Alternate outflow pathway through the sclera draining aqueous to subconjunctival space
 - ◆ Risk of failure due to fibrosis
 - According to a study by Sapienza et al., Long-term evaluation of the use of Ahmed gonioimplants in dogs with primary glaucoma: none cases (2000-2008):
 - ◆ 8 cases were visual with controlled IOP at 1 year post-op
- TSCPC and Gonioimplantation (Combination Procedure)
 - According to a study by Sapienza et al., Combined transscleral diode laser cyclophotocoagulation and Ahmed gonioimplantation in dogs with primary glaucoma: 51 (1996-2004):
 - ◆ 49% Visual at 6 months
 - ◆ 41% Visual at 12 months
 - ◆ 76% had controlled IOP at 12 months
 - ◆ Short term complications
 - Fibrin
 - Hyphema
 - Corneal Ulcer
 - Retinal Detachment
- Endolaser
 - Intraocular visualization of ciliary processes where energy is delivered
 - Complications include hemorrhage and uveitis
 - Has to be combined with removal of the lens in order to visualize the ciliary processes
- Enucleation
 - No further follow-up on this eye
- Intraocular Silicone Prosthesis
 - Removes internal contents and leaves fibrous tunic
 - Silicone sphere inserted
 - Cornea vascularizes in 2-4 weeks
 - Need to maintain corneal health

ocunovis
BioHance™ Gel Eye Drops



Lubrication designed to last longer

oculenis
BioHance™ Ocular Repair Gel



Corneal Repair Gel

episanis
BioHance™ Skin and Wound Gel



Accelerates Healing

See why veterinarians rate Sentrx products 4.5/5 stars¹

See more reviews on Vetcove.com

**Ilia Medina,
DVM**



My personal dog has KCS and one of the most upsetting things about the disease is the constant mucoid discharge. I feel typical eye lubes only add to this globbing of discharge but the Sentrx products not only didn't add to the globs but my pet's tear film improved and became less mucoid. I also have to apply these drop less frequently than other products. I know my clients will be happy with this product because I have first hand experience using it and am happy with the results.

**Traci Teabo,
Vet Tech**



The wound care product (Episanis) is amazing!



Sentrxanimalcare.com | [@sentrxanimalcare](https://www.instagram.com/sentrxanimalcare)

1. Data from 128 veterinarians on VetCove.com on file as of 4/1/2021

Disclaimer: Sentrx BioHance products do not treat or cure diseases and do not contain antibiotics. These products are based on a patented crosslinked hyaluronic acid technology which creates a cellular matrix that uniquely provides longer lasting lubrication and supports accelerated healing. Sentrx products are meant to support a standard treatment protocol.

About the Author



DR. DJ HAEUSSLER

Dr. DJ Haeussler received his DVM from the Ohio State University. He then went to New Jersey where he finished two internships at Garden State Veterinary Specialists and then returned to his alma mater, The Ohio State University to complete his residency.

While at Ohio State University for his residency, he completed a Master of Science degree and earned the top award for professional student research at Ohio State as well as the top resident award for professional research at the annual American College of Veterinary Ophthalmologists (ACVO) in 2010.

Dr. Haeussler is a board certified diplomate of the American College of Veterinary Ophthalmologists (ACVO). Dr. Haeussler also serves on the ACVO Public Relations committee as the committee chair and is a member of the Cincinnati Veterinary Medical Association Board of Trustees.