

**Osteological Analysis**  
**12-18 Swinegate, 14 Little Stonegate**  
**& 18 Back Swinegate**  
**York**  
**North Yorkshire**

Site Code: 1989/90.28 & 1990.1  
NGR: SE 6030 5198 & SE 6033 5199

Report No 1815  
December 2015

**Prepared for**

York Archaeological Trust for Excavation &  
Research Ltd  
47 Aldwark  
York  
YO1 7BX

**Prepared by**

Katie Keefe & Malin Holst  
York Osteoarchaeology Ltd  
75 Main Street  
Bishop Wilton  
York YO42 1SR

© Copyright York Osteoarchaeology Ltd

Registered in England No 4982542

**TABLE OF CONTENTS**

|            | <b>CONTENTS</b>                           | <b>Page</b> |
|------------|---|-------------|
|            | <b>Summary</b>                            | iii         |
|            | <b>Acknowledgements</b>                   | iii         |
| <b>1.0</b> | <b>INTRODUCTION</b>                       | <b>1</b>    |
| 1.1        | AIMS AND OBJECTIVES                       | 1           |
| 1.2        | METHODOLOGY                               | 1           |
| <b>2.0</b> | <b>OSTEOLOGICAL ANALYSIS</b>              | <b>1</b>    |
| 2.1        | PRESERVATION                              | 1           |
| 2.2        | MINIMUM NUMBER OF INDIVIDUALS             | 5           |
| 2.3        | ASSESSMENT OF AGE                         | 6           |
| 2.4        | SEX DETERMINATION                         | 7           |
| 2.5        | ANCESTRY                                  | 7           |
| 2.6        | METRIC ANALYSIS                           | 7           |
| 2.6.1      | Stature                                   | 7           |
| 2.6.2      | Platymeric and Platycnemic Indices        | 8           |
| 2.6.3      | Cranial Indices                           | 8           |
| 2.7        | NON-METRIC TRAITS                         | 9           |
| 2.8        | CONCLUSION                                | 10          |
| <b>3.0</b> | <b>PATHOLOGICAL ANALYSIS</b>              | <b>10</b>   |
| 3.1        | CONGENITAL CONDITIONS                     | 11          |
| 3.1.1      | Cranial Asymmetry                         | 11          |
| 3.1.2      | Variation in Number of Vertebral Segments | 11          |
| 3.1.3      | Cleft Neural Arches                       | 13          |
| 3.1.4      | Other Spinal Anomalies                    | 14          |
| 3.1.5      | Anomalies of the Ribs                     | 13          |
| 3.1.6      | Anomalies of the Sternum                  | 14          |
| 3.1.7      | Retroversion of the Shoulder              | 14          |
| 3.2        | METABOLIC CONDITIONS                      | 14          |
| 3.2.1      | <i>Cribra Orbitalia</i>                   | 15          |

|            |   |           |
|------------|---|-----------|
| 3.3        | TRAUMA  | 15        |
| 3.3.1      | Ante-Mortem Fractures                                   | 16        |
| 3.3.2      | Ossified Haematoma                                      | 16        |
| 3.3.3      | <i>Osteochondritis Dissecans</i>                        | 17        |
| 3.3.4      | Calcaneus Lesions                                       | 17        |
| 3.4        | JOINT DISEASE   | 17        |
| 3.4.1      | Degenerative Joint Disease                              | 18        |
| 3.4.2      | Schmorl's Nodes   | 18        |
| 3.4.3      | Miscellaneous Joint Disease                             | 19        |
| 3.5        | MISCELLANEOUS PATHOLOGY                                 | 20        |
| 3.6        | CONCLUSION  | 21        |
| <b>4.0</b> | <b>DENTAL HEALTH</b>                                    | <b>21</b> |
| 4.1        | DENTAL WEAR   | 22        |
| 4.2        | CALCULUS  | 22        |
| 4.3        | PERIODONTAL DISEASE                                     | 22        |
| 4.4        | DENTAL CARIES   | 23        |
| 4.5        | ABSCESSSES AND PERIAPICAL LESIONS                       | 23        |
| 4.6        | DENTAL ENAMEL HYPOPLASIA                                | 23        |
| 4.7        | ENAMEL CHIPS  | 23        |
| 4.8        | DENTAL ANOMALIES  | 24        |
| 4.8.1      | Crowding  | 24        |
| 4.8.2      | Congenitally Absent and Impacted Teeth                  | 24        |
| 4.9        | DENTAL CONCLUSIONS                                      | 24        |
| <b>5.0</b> | <b>DISCUSSION AND SUMMARY</b>                           | <b>25</b> |
|            | <b>References</b>                                       | <b>27</b> |
|            | <b>Plates</b>   |           |
| 1          | Sk 3381 asymmetry of the occipital                      | 11        |
| 2          | Sk 14071 cranial border shift                           | 12        |
| 3          | SK 14071 bifid spinous process to first sacral vertebra | 13        |

---

|    |  |    |
|----|--|----|
| 4  | Sk 3381 incomplete transverse foramen                                      | 13 |
| 5  | Sk 3381 asymmetry of the first ribs  | 14 |
| 6  | Sk14071 fracture to the distal shaft of the left ulna                      | 16 |
| 7  | Sk 14071 bilateral calcaneal lesions                                       | 17 |
| 8  | Sk 3381 changes to third lumbar vertebra                                   | 19 |
| 9  | Sk 7016 billowed appearance of superior and inferior vertebra body         | 20 |
| 10 | Sk 7016 new bone formation on the anterior surface of the vertebral bodies | 20 |

### **Tables**

|   |   |   |
|---|---|---|
| 1 | Summary of osteological and palaeopathological analysis | 3 |
|---|---|---|

### **Appendices**

|   |   |   |
|---|---|---|
| A | Osteological And Palaeopathological Catalogue | A |
|---|---|---|

## Summary

York Osteoarchaeology Ltd was commissioned by the York Archaeological Trust for Excavation and Research Ltd to carry out the osteological analysis of seven skeletons from St Benet's, Churchyard, York, North Yorkshire, (SE 6030 5198 & SE 6033 5199). The skeletons were excavated during archaeological evaluations at 12-18 Swinegate, 14 Little Stonegate and 18 Back Swinegate. The excavations took place between 1989 and 1990 and revealed a cemetery associated with St Benet's Church. Radiocarbon dates from three of the analysed skeletons dated them to the 10<sup>th</sup>-11<sup>th</sup> centuries. The seven skeletons were a small sample of a larger cemetery, from which around 100 burials were excavated. Approximately half of the burials within the cemetery were placed in wooden coffins one of which consisted of a wooden plank placed over a juvenile burial (Sk 14007) with a nine-men's-morris board carved into the top.

Osteological analysis revealed that this group included three mature adult males, one young middle adult female, one older middle adult female, one older adolescent who was tentatively sexed as male and a juvenile. The excellent preservation of the skeletal remains meant it was possible to estimate the age, sex and stature of all of the adults. Generally the adults were below the average stature seen in early medieval Britain but fell within the ranges for the period. One of the mature adult males may have been of African or mixed ancestry and may have migrated to York or descended from those that did.

All five adults exhibited some joint degeneration, which was more prolific in the mature adults and was probably age-related. Schmorl's nodes in the spine indicative of herniated discs hinted at the potentially heavy physical work carried out by these individuals, probably from a young age, as these lesions were also noted in the older adolescent. Moderate levels of trauma were identified, some of which may have been the result of a physically strenuous life; two of the males had crush fractures in their spine. One of the mature adult males also had a well-healed fracture to his ulna, which may have occurred when protecting his face or body from a blow, and another had an ossified blood clot on his left shin.

Minor developmental anomalies were common, but none appear to have been serious. Cribra orbitalia was observed in an adult male and female, and the juvenile, which may be an indication of the general poor health of the population. Grooves in the teeth of all five of the adults also revealed that they were affected by periods of stress in childhood. The older adolescent suffered from what may have been a fungal infection. The disease could not be positively diagnosed and would benefit from further research.

An unusually high prevalence of calculus was observed in the dentitions from St Benet's, which exceeded the average for the period, suggesting that their oral hygiene had not been adequate and diet may have been high in protein. The prevalence rate of caries in the St Benet population was lower than expected for the period, which may suggest that the diet was low in fruits, honey and processed carbohydrates.

## Acknowledgements

York Osteoarchaeology Ltd would like to thank Jane McComish, Rachel Cubitt, Sarah Maltby and Christine McDonnell from the York Archaeological Trust for Excavation and Research for their help and support.

## 1.0 INTRODUCTION

In September 2015, York Osteoarchaeology Ltd was commissioned by the York Archaeological Trust for Excavation and Research Ltd to carry out the osteological analysis of seven skeletons. The skeletons had been excavated between October 1989 and July 1990 during an archaeological evaluation at 12-18 Swinegate, 14 Little Stonegate and 18 Back Swinegate, York, North Yorkshire, (SE 6030 5198 & SE 6033 5199). A total of fifteen trenches were excavated, from which human remains were recovered from eight.

The site revealed evidence of activity dating from the Roman to the post-medieval period. Finds recovered from the site included 38 excellently preserved wooden coffins, all of which were constructed using wooden dowels. Two 14<sup>th</sup> century writing tablets were also recovered. The finds from this site are of international significance.

The seven skeletons represent a small sample of a larger cemetery that contained approximately 100 burials, all of which were placed in individual graves and around half were coffined. The burial orientation varied from north-north-east to south-south-west, north-east to south-west and east-north-east to west-south-west. Two distinct phases of burial were discernible; those that were sealed by a metal surface and those that truncated it.

### 1.1 AIMS AND OBJECTIVES

The aim of the skeletal analysis was to determine the age, sex and stature of the skeletons, as well as to record and diagnose any skeletal manifestations of disease and trauma.

### 1.2 METHODOLOGY

The skeletons were analysed in detail, assessing the preservation and completeness, calculating the minimum number of individuals present as well as determining the age, sex and stature of the individuals. All pathological lesions were recorded and described.

## 2.0 OSTEOLOGICAL ANALYSIS

Osteological analysis is concerned with the determination of the identity of a skeleton, by estimating its age, sex and stature. Robusticity and non-metric traits can provide further information on the appearance and familial affinities of the individual studied. This information is essential in order to determine the prevalence of disease types and age-related changes. It is crucial for identifying sex dimorphism in occupation, lifestyle and diet, as well as the role of different age groups in society. A summary of the osteological and palaeopathological data for the articulated skeletons is given in Table 1, with a detailed catalogue of skeletons provided in Appendix A.

### 2.1 PRESERVATION

Skeletal preservation depends upon a number of factors, including the age and sex of the individual as well as the size, shape and robusticity of the bone. Burial environment, post-depositional disturbance and treatment following excavation can also have a considerable impact on bone condition (Henderson 1987, Garland and Janaway 1989, Janaway 1996, Spriggs 1989). Preservation of human skeletal remains is assessed subjectively, depending upon the severity of bone surface erosion and post-mortem breaks, but disregarding completeness. Preservation is important, as it can have a large impact on the quantity and quality of information that it is possible to obtain from the skeletal remains.

Surface preservation, concerning the condition of the bone cortex, was assessed using the seven-category grading system defined by McKinley (2004), ranging from 0 (excellent) to 5+ (extremely poor). Excellent preservation implied no bone surface erosion and a clear surface morphology, whereas extremely poor preservation indicated heavy and penetrating erosion of the bone surface resulting in complete loss of surface morphology and modification of the bone profile. Surface preservation could be variable throughout an individual skeleton, so the condition of the majority of bones in the skeleton was taken as the preservation grade for the whole skeleton. The degree of fragmentation was recorded, using categories ranging from 'minimal' (little or no fragmentation of bones) to 'extreme' (extensive fragmentation with bones in multiple small fragments). Finally, the completeness of the skeletons was assessed and expressed as a percentage: the higher the percentage, the more complete the skeleton.

All seven of the skeletons were in very good condition (Table 1). They exhibited minimal erosion and had suffered very little from post-mortem fragmentation.

Table 1 Summary of osteological and palaeopathological results

| Sk No | Grave type | Position                                    | Preservation | Completeness | Age   | Age Group | Sex    | Stature                 | Pathology  |
|-------|------------|---|--------------|--------------|-------|-----------|--------|-------------------------|--|
| 3379  | Coffined   | Supine extended?<br>(incomplete)            | 1            | 60%          | 46+   | MA        | Male   | 171.31<br>+/- 4.43      | DJD in the cervical, thoracic and lumbar vertebrae, manubrium, medial clavicle, glenoids, humeral heads and distal right radius. Schmorl's nodes in the thoracic and lumbar spine. <i>Cribræ orbitalia</i> . Crush fracture of T11 and T10. Slight retroversion of glenoids. Bilateral notches on the inferior margin of the zygomas, at insertion of the masseter. Spinous process of C4 deviates laterally to left. C6 exhibits asymmetry of the transverse foramen. |
| 3381  | Coffined   | Supine extended, wrists crossed over pelvis | 1            | 95%          | 26-35 | YMA       | Female | 152.2<br>cm +/-<br>3.55 | <i>Cribræ orbitalia</i> , Schmorl's nodes in the thoracic and lumbar spine. DJD in the lumbar spine, left mandible, right manubrium, right acetabulum, auricular surfaces, distal joint of the proximal phalanx for the 5th metacarpal. Supernumerary vertebrae at the lumbar-thoracic border. C2 has an incomplete left   |



|       |                                      |  |   |     |       |     |        |                   |   |
|-------|--------------------------------------|--|---|-----|-------|-----|--------|-------------------|---|
|       |                                      |  |   |     |       |     |        |                   | transverse foramen. OD on the proximal articulation of the left proximal foot phalanx for MT1. Slight cranial asymmetry; the right occipital protrudes further posteriorly than the left. Manubrium fused to sternum. The superior anterior margin of L3 appears porotic but retains the annular ring. The anterior margin of the superior body of L5 has an eroded annular ring, with lacy osteophytic lipping around the lateral margins. Asymmetry of the 1st ribs.  |
| 3492  | Plain                                | Supine extended, arms crossed on stomach                     | 1 | 80% | 36-45 | OMA | Female | 157.8 cm +/- 4.24 | Schmorl's nodes in the thoracic and lumbar spine, DJD in the cervical, thoracic and lumbar spine, manubrium, right capitata, hamate, lunate, scaphoid and trapezium, left acetabulum and left and right auricular surface. Small ossified nodule of bone on the lateral margin of the mental eminence of the right mandible. The anterior portion of the inferior body of T9 potentially has an avulsion of the endplate and a possible crush fracture. T10, 11 and 12 have asymmetrical body shapes. The left os coxa has an extension to the inferior margin of the left auricular surface, which corresponds to an extension on the left sacro iliac joint on the sacrum. The distal end of the sternum is wider than the proximal end. The sacrum is slightly asymmetrical. |
| 7061  | Coffined                             | Supine extended, right hand on pelvis left hand by left side | 1 | 80% | 17-18 | Ad  | ?Male  | -                 | Dorsal surface of the manubrium exhibits expanded porotic lesions, the body of the third sacral vertebrae exhibits the same lesions on the ventral surface of the body. The anterior bodies of T2-L5 also exhibit similar porotic lesions. T3-11 and L2-5 exhibit a very billowed appearance around the margins of the inferior and superior bodies. T3-L5 exhibit a thickened layer of bone on the anterior surface of the bodies - possibly the result of a fungal infection. Schmorl's nodes in the thoracic and lumbar spine. Bilateral notches on the inferior margins of the zygomas at the insertion of masseter.  |
| 14007 | Beneath wooden plank with nine men's | Disarticulated   | 1 | 80% | 1-2.5 | J   | -      | -                 | Cribrra orbitalia. Aging techniques suggest a disparity in the individual's age   |

|       | morris<br>board<br>carved on<br>top |   |   |     |     |    |      |                   |  |
|-------|-------------------------------------|---|---|-----|-----|----|------|-------------------|--|
| 14071 | Plain                               | Supine<br>extended right<br>arm across left<br>arm by left side | 1 | 80% | 46+ | MA | Male | 163.8<br>+/- 2.99 | Schmorl's nodes in thoracic spine. DJD in cervical, thoracic, lumbar and sacral spine, left mandible, manubrium, medial clavicles, right scapula, left distal radius, and ulna, acetabuli, auricular surfaces, right proximal femur, both distal femora, the distal articulation of the right 1st metatarsal, and distal articulations of the right 4th and 5th metatarsals, the proximal articulation of the proximal phalanx for the left 1st metatarsal. Fusion of the xiphoid to sternum. Border shifting in the vertebral column - the 1st coccygeal vertebrae fused to the base of the sacrum. Crush fractures at T3-T7. A healed fracture to distal shaft of left ulna. Retroversion of glenoids. Short clavicles. OD on right cuneiform. The right distal articulations of the 2nd and 3rd metatarsals are missing the medial extensions to their plantar joints. Bilateral calcaneus lesions. |
| 15042 | Plain                               | Supine<br>extended  | 1 | 90% | 46+ | MA | Male | 172.9<br>+/- 2.99 | Schmorl's nodes in thoracic spine. DJD in the thoracic spine, medial right clavicle, left proximal humerus, left and right distal radii, proximal right ulna, left and right acetabulum, and distal end of the proximal phalanx for MC2. OA in the left temporomandibular joint. Bifid spinous process on S1. A healed fracture of distal right radius. Border shift at thoracic lumbar border. Muscle excavations on left and right clavicle at insertion of costo-clavicular ligament. Ossified haematoma on left tibia.   |

**Key:** SP = Surface preservation: grades 0 (excellent), 1 (very good), 2 (good), 3 (moderate), 4 (poor), 5 (very poor), 5+ (extremely poor) after McKinley (2004a); C = Completeness; F = Fragmentation: min (minimal), sli (slight), mod (moderate), sev (severe), ext (extreme)

Non-adult age categories: f (foetus, <38weeks *in utero*), p (perinate, c. birth), n (neonate, 0-1m), i (infant, 1-12m), j (juvenile, 1-12y), ad (adolescent 13-17y)

Adult age categories: ya (young adult, 18-25y), yma (young middle adult, 26-35y), oma (old middle adult, 36-45y), ma (mature adult, 46+y), a (adult, 18+y)

Skeletons 7061, 3492 and 3779 all partially extended beyond the limit of excavation and were incomplete as a result.

## 2.2 MINIMUM NUMBER OF INDIVIDUALS

A count of the 'minimum number of individuals' (MNI) recovered from a cemetery is carried out as standard procedure in osteological reports on inhumations in order to establish how many individuals are represented by the articulated and disarticulated human bones (without taking the archaeologically defined graves into account). The MNI is calculated by counting all long bone ends, as well as other larger skeletal elements recovered. The largest number of these is then taken as the MNI. The MNI is likely to be lower than the actual number of skeletons which would have been interred on the site, but represents the minimum number of individuals which can be scientifically proven to be present.

The presence of five right adult humeri an adolescent right femur and a juvenile right femur suggested a MNI of seven individuals.

## 2.3 ASSESSMENT OF AGE

Age was determined using standard ageing techniques, as specified in Scheuer and Black (2000a; 2000b) and Cox (2000). For non-adults age was estimated using the stage of dental development (Moorrees *et al.* 1963a; 1963b), dental eruption (Ubelaker 1989), measurements of long bones and other appropriate elements, and the development and fusion of bones (Scheuer and Black 2000b). In adults, age was estimated from stages of bone development and degeneration in the pelvis (Brooks and Suchey 1990, Lovejoy *et al.* 1985) and ribs (modified version of methods developed by İşcan *et al.* 1984; 1985 and İşcan and Loth 1986 provided in Ubelaker 1989), supplemented through examination of patterns of dental wear (Brothwell 1981).

The individuals were divided into a number of age categories. Non-adults were subdivided into 'foetuses' (f: where the age estimate clearly fell below 38-40 *weeks in utero*), 'perinates' (p: where the age estimates converged around birth), 'neonates' (n: where the age estimate suggested 0-1 month), 'infant' (i; 1-12 months), juvenile (j; 1-12 years), and adolescent (ad; 13-17 years). Adults were divided into 'young adult' (ya; 18-25 years), young middle adult (yma; 26-35 years), old middle adult (oma; 36-45 years), and mature adult (46+ years). A category of 'adult' (a) was used to designate those individuals whose age could not be determined beyond the fact that they were eighteen or older.

For each skeleton as many criteria as possible (preservation allowing) were used to estimate age. However, it is important to note that several studies (for example Molleson and Cox 1993, Molleson 1995, Miles *et al.* 2008) have highlighted the difficulty of accurately determining the age-at-death of adults from their skeletal remains, with age-at-death frequently being underestimated for older individuals. The categories defined here should be taken as a general guide to the relative physiological age of the adult, rather than being an accurate portrayal of the real chronological age.

In the four adult skeletons, age was established using dental wear, and the deterioration of the pelvic joints. It was noted during analysis that the dental age for each individual was consistently younger than the age suggested by the deterioration of the pelvis. The rate at which dental enamel wears away is multifactorial and can be affected by diet, the quality of the enamel, the use of teeth as tools and habitual

grinding. As a result, the ages as indicated by the degenerative changes in the pelvis were taken to be a more accurate reflection of an individual's age. Analysis revealed that all three males had reached mature adulthood, while one female died in her young middle adulthood and the other in her old middle adulthood.

The development of the teeth and fusion of the joints was used to establish age in the two non-adults (see Table 1). While the ageing criteria corresponded in Skeleton 7061 (aged between seventeen to eighteen years), they differed in Skeleton 14007. The dentition and metrical analysis of this individual indicated that it was between twelve and fourteen months old, whereas the bone fusion suggested a wider age range; the anterior fontanelle was still open, which should fuse between one and two years, however; the metopic suture had already fused which occurs between two to four years of age. The lumbar arches had also fused to the bodies, which occurs between the ages of two to three years. The evidence suggests that this is a young juvenile aged between one and two and a half years. The disparity between the ageing criteria could not be accounted for, as usually the dental development is a more reliable indicator of age than long bone length and bone fusion, as it is least affected by environmental and physiological stress.

## 2.4 SEX DETERMINATION

Sex determination was carried out using standard osteological techniques, such as those described by Mays and Cox (2000). Assessment of sex involves examination of the shape of the skull and the pelvis and can only be carried out once sexual characteristics have developed, during late puberty and early adulthood. Evidence from the pelvis was favoured as its shape is directly linked to biological sex (the requirements of childbirth in females) whereas the shape of the skull can be influenced by factors such as age (Walker 1995). Measurements of certain bones were used to supplement the morphological assessment.

In all four adults cranial and pelvic traits along with metric analysis corresponded and revealed that the three mature adults (Skeletons 3379, 14071 and 15042) were males, while the two younger adults (Skeletons 338 and 3492) were female.

Although it is normally not possible to determine the sex in adolescent remains, the metric analysis of many of the long bones and the shape of the pelvis suggested that Skeleton 7061 was likely to have been male.

## 2.5 ANCESTRY

The term 'ancestry' is used to describe the genetic background of individuals. An attempt was made to determine the ancestry of each individual based on the visual appearance of traits in the cranial skeleton, as described by Byers (2010, 154-165). Unfortunately, the expression of the various traits used to define ancestral groups can be ambiguous and assessing them is subjective; consequently, it can be very difficult to determine ancestry (*ibid*, 152-154).

Analysis of the facial characteristics of Skeleton 3379, a mature adult male, suggested that he had African

or mixed ancestry.

## 2.6 METRIC ANALYSIS

### 2.6.1 Stature

Stature depends on two main factors, heredity and environment; it can also fluctuate between chronological periods. Stature can only be established in skeletons if at least one complete and fully fused long bone is present, but preferably using the combined femur and tibia. The bone is measured on an osteometric board, and stature is then calculated using a regression formula developed upon individuals of known stature (Trotter 1970). Where possible, bones from the legs were used in preference to those of the upper limb as these carry the lowest error margin (*ibid*).

Both females were below the average mean stature for the period of 161cm, as calculated by Roberts and Cox (2003), but fell into the lower end of the stature range. Skeleton 3381 was 152.2cm  $\pm$ 3.55cm tall and Skeleton 3492 was 157.8cm  $\pm$ 4.2cm tall. Two of the males (Skeleton 3379 and 14071) fell below the average for the period of 172cm (*ibid*), Skeleton 14071 was 163.8cm  $\pm$ 2.99cm. The only individual that was of average height for the period was Skeleton 15042 (mature adult male) who measured 172.9cm. Different formulae have been developed for different ancestral groups (Trotter 1970). Consequently, the African formula was applied to Skeleton 3379 (mature adult male). Based on measurements of the right humerus, Skeleton 3379 was 171.13cm tall, with a standard error of  $\pm$ 4.43cm. The standard error was relatively great, because arm bones only provide a rough guide to stature. However, if this individual is not of African descent, then their stature would have been underestimated.

### 2.6.2 Platymeric and Platycnemic Indices

Leg measurements were obtained from the femora and tibiae of the adults and used to calculate the shape and robusticity of the femoral shaft (*platymeric* index) and the tibial shaft (*platycnemic* index; Bass 1987).

Only three male femora belonging to Skeleton 14071 and 15042 were available to measure for the *platymeric* index; two of these fell into the *platymeric* range (broad and flattened from front to back), while the third was *eurymeric* (rounded). The femora of the old middle adult female were also *platymeric*, while the femora of the young middle adult female were *eurymeric* (rounded).

The *platycnemic* index of the tibiae was calculated in order to establish the degree of tibial shaft flatness. Two adult males and one of the females had tibiae available to measure. Both of the tibial shafts of the young middle adult female were *eurycnemic* (broad). Three of the male tibial shafts were *eurycnemic* (broad) while one of the tibiae of Skeleton 14071, a mature adult male, was *mesocnemic* (average).

### 2.6.3 Cranial Indices

Standard measurements of the crania and mandibles were taken where preservation allowed. Skeleton 14071 (mature adult male) did not have a skull, however, measurements could be taken from the

remaining four adult skulls.

The cranial index describes the shape of the cranium. The crania belonging to the mature adult male and the young middle adult female were *mesocranic*, or of average shape, while the skull of the middle adult female was *brachycranial* (round headed).

The cranial breadth-height index expresses the relationship between the breadth and height of a skull as a percentage. The results revealed that the young middle adult female and both of the mature adult males had low skulls (*tapeinocranic*), while the old middle adult female had an average or medium skull (*metriocranic*).

The fronto-parietal index expresses the relationship between the minimum breadth of the frontal bone and the maximum cranial breadth. One of the mature adult males and the young middle adult male both had *metriometopic* (of average shape) skulls, while the skulls of the old middle adult female and the other mature adult male were *eurymetopic* (broad).

Further cranial indices pertaining to the facial skeleton revealed that both the mature adult males and the young middle adult both had *mesorrhinic* noses (average), while the mature adult female's nose was *leptorrhinic* (narrow). The orbital index revealed that the orbits of all four individuals were *chamaeconchic* (wide orbits). Both of the females had *brachyuranic* palates (broad), while one of the mature adult males had a *dolichuranic* palate (long or narrow palate) and the other had a mesuranic palate (average shape).

## 2.7 NON-METRIC TRAITS

Non-metric traits are additional sutures, facets, bony processes, canals and foramina, which occur in a minority of skeletons and are believed to suggest hereditary affiliation between skeletons (Saunders 1989). The origins of non-metric traits have been extensively discussed in the osteological literature and it is now thought that while most non-metric traits have genetic origins, some can be produced by factors such as mechanical stress (Kennedy 1989) or environment (Trinkhaus 1978).

A total of thirty cranial (skull) and thirty post-cranial (bones of the body and limbs) non-metric traits were selected from the osteological literature (Buikstra and Ubelaker 1994, Finnegan 1978, Berry and Berry 1967) and recorded. The majority of non-metric traits were observed on the skull. These were anomalies that would not have affected the individual. Only the results for the adult and adolescent skeletons are presented here.

The older adolescent Skeleton 7061 exhibited a *highest nuchal line* (ridge on the back of the skull). The adolescent, old middle adult female (skeleton 3492) and the mature adult male (Skeleton 3379) all had *parietal foramen* (small hole in the top of the skull). Skeleton 3492 had an ossicle in the *lambdoid suture* (small bone in suture at the back of the skull). The presence of ossicles in the lambdoid sutures has been related to deformation in the shape of the cranium, being found in studies of crania deliberately modified as a cultural practice and those deformed through premature fusion of a suture (O'Loughlin 2004,

Sanchez-Lara *et al* 2007). In theory, increased tension placed on the opposite side to the fused suture spreads the suture apart, encouraging the formation of ossicles within the suture to bridge the gap (Sanchez-Lara *et al* 2007). Skeleton 15042 had a small ossicle in his coronal suture.

All five individuals with skulls had small holes behind their ears, including *sutural mastoid foramen* and *mastoid foramen extrasutural* as well as at the base of their skulls such as a *foramen of Huschke*, an open *posterior condylar canal* and *double anterior condylar canals* (small holes in the base of the skull). The adolescent, young middle adult female and one of the mature adult males had an accessory *supraorbital foramen*, and the adolescent had an accessory *infraorbital foramen* (small holes in the skull below the eye). The young middle adult female (Skeleton 3381) had a *palatine torus*, a *maxillary torus* and a *mandibular torus*, (nodules of bone in the hard palate and jaw). The old middle adult female and both of the mature adult males had extra foramen in the maxillo-facial region of the skull, including accessory *lesser palatine foramen* and posterior *ethmoid foramen extrasutural*. These minor anomalies were probably genetic in origin.

Cranial traits are more likely to be genetic in origin than those noted on the remaining part of the skeleton, which can often be created by mechanical stress. The latter included *hypotrochanteric fossae*, which are depressed areas at the back of the femora at the attachments of the *gluteus maximus* bottom muscle. The raised areas are thought to reflect strain on the muscle.

Both females and one of the mature adult males had bipartite transverse foramen (extra holes on the sides of the vertebrae in the neck), and the older middle adult female had a double atlas facet (change in the shape of the articulation of the first vertebra in the neck). The old middle adult female (Skeleton 3492) and the mature adult male (Skeleton 14071) had a circumflex sulcus (depressions in the lateral border of the scapula for the circumflex scapular artery). Both mature adult males had partial suprascapular foramen (incomplete hole on the superior border of the scapula caused by the partial ossification of the superior transverse scapular ligament).

Other post-cranial traits observed included *exostosis in trochanteric fossa*, thought to reflect muscle strain in the older adolescent (Skeleton 7061). The females and the mature adult male (Skeleton 14071) had *third trochanters* (extra nodules of bone on the femur). Both of the mature adult males also had an acetabular crease (irregularity in the surface of the hip joint), and femoral plaque (characterised by bulging of the joint surface). The young middle adult female (Skeleton 3381) and the mature adult male (Skeleton 14071) had lateral *tibial squatting facets* (extension to the articular surface of the ankle). The young middle adult female (Skeleton 3381) exhibited changes to the shape of her kneecap, including a *vastus notch* and a *vastus fossa*. Both the mature adult males and the young middle adult female (Skeleton 3381) had small changes to the shape of their ankles, including a *peroneal tubercle*, absent *anterior calcaneal facet*, and *lateral talar facet* on the mature adult male (Skeleton 14071), bilateral medial squatting facets (extension to the distal tibial articular surface) in the other mature adult male (Skeleton 15042) and a double *anterior calcaneal facet* on the female. None of these traits would have caused any symptoms.

## 2.8 CONCLUSION

The preservation of the human remains from St Benet's was very good, however, the majority of skeletons were incomplete. Two of the individuals were non-adults, aged one to two and a half years and seventeen to eighteen years. Adults of both sexes were present. The three males survived into their mature adulthood, while both females died in their middle adulthood (one as a young middle adult, the other in older middle adulthood). It is probable that the adolescent was also male. The mean stature for all but one of the adults fell below the average, compared to national data for the early medieval period, but fell within the stature range. One of the males was possibly of African or mixed ancestry.

## 3.0 PATHOLOGICAL ANALYSIS

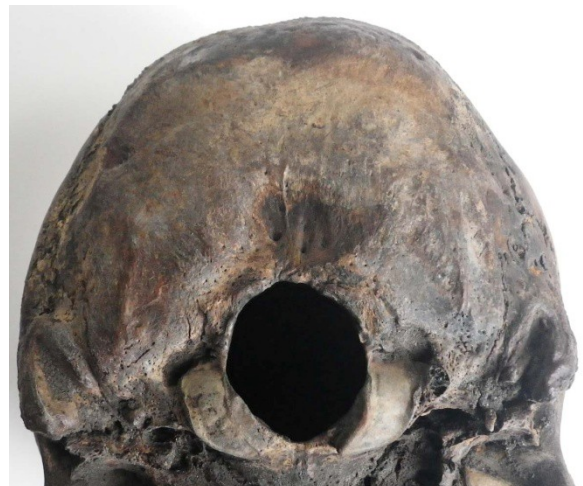Pathological conditions (disease) can manifest themselves on the skeleton, especially when these are chronic conditions or the result of trauma to the bone. The bone elements to which muscles attach can also provide information on muscle trauma and excessive use of muscles. All bones were examined macroscopically for evidence of pathological changes. Fuller descriptions of the pathological lesions observed can be found in Appendix A.

### 3.1 CONGENITAL CONDITIONS

Heredity and environment can influence the embryological development of an individual, leading to the formation of a congenital defect or anomaly (Barnes 1994). The most severe defects are often lethal, and if the baby is not miscarried or stillborn, it will usually die shortly after birth. Such severe defects are rarely seen in archaeological populations, but the less severe expressions often are, and in many of these cases the individual affected will have been unaware of their condition. Moreover, the frequency with which these minor anomalies occur may provide information on the occurrence of the severe expressions of these defects in the population involved (*ibid*), and may provide information on maternal health (Sture 2001).

#### 3.1.1 Cranial Asymmetry

The bones in the cranial vault meet at joints named sutures. Failure of a suture to develop is known as sutural agenesis, whereas premature fusion of a suture is known as craniosynostosis (Barnes 1994). Since the presence of sutures allows the cranium to expand in size during childhood to accommodate the growing brain, if a suture is absent or fuses too early it can prevent the cranium from growing in a certain direction. If other sutures are present and open then the brain and cranium will grow in that direction instead, and the end result will be a deformed cranium.



**Plate 1** Sk 3381 asymmetry of the occipital



Sutural agenesis can be hereditary and runs in families. Craniosynostosis can be caused by a variety of factors, including foetal cranial position *in utero*, birth trauma, infection whilst in the womb, endocrine dysfunction and metabolic disorders (such as rickets) (Jimenez *et al.* 1994). In general, craniosynostosis affects males more often than females (Aufderheide and Rodríguez-Martín 1998), although certain sutures (notably the coronal) are more commonly involved in females (Kimonis *et al.* 2007, Barnes 1994). Premature fusion of the sutures can occur as part of a congenital syndrome (Barnes 1994), and over 180 such syndromes associated with craniosynostosis have been recorded (Kimonis *et al.* 2007).

The back of the skull of the young middle adult female (Skeleton 3381) was slightly asymmetrical (Plate 1); the right side of the occipital protruded further posteriorly than the left. It appears that premature fusion of part of her left lambdoid suture may have occurred at points along the lateral portion of the suture, located closest to the temporal. However, the rest of her cranium appeared unaffected. The changes were relatively minimal and it is unlikely that she or others around her would have been aware of them.

### 3.1.2 Variation in Number of Vertebral Segments

The usual number of segments in the spine is 33, including seven cervical (neck) vertebrae, twelve thoracic vertebrae (bearing the ribs), five lumbar vertebrae (lower back), five fused segments in the sacrum (back of the pelvis), and four segments in the coccyx (tailbone). Occasionally the overall number of segments may vary. It is more common for an individual to have an additional vertebra than to have a reduction in the number of vertebrae (Barnes 1994, 78). Assessing the number of vertebrae in the spine of archaeological individuals can be difficult, due to the fact that skeletons may be incomplete, or because disarticulated bone can be present in the backfill of the grave and become intermixed with those of the articulated skeleton.

When additional vertebrae occur they often appear at the borders between the thoracic and lumbar spine, or between the lumbar vertebrae and sacrum. They may appear as a fully-fledged thoracic or lumbar vertebra, but frequently they will take on a mixture of the characteristics of the vertebrae on either side of the border, so appearing to be part-thoracic/ part-lumbar, or part-lumbar/ part-sacrum (Barnes 1994, 78). When this occurs they are described as 'transitional vertebrae'

Skeleton 3381 (young middle adult female) had an additional lumbar vertebra in her spine. The supernumerary vertebra was located at the lumbar-thoracic border and had lumbar facets and a general lumbar appearance, the right lamina had a small rib facet, and the left lamina was very enlarged and similar in appearance to the fifth lumbar vertebra. It is possible that the vertebral characteristics were the result of a border shift between the sacrum and the coccyx; unfortunately, the coccyx did not survive and was therefore unavailable for examination.



**Plate 2** Sk 14071 cranial border shift

The mature adult male (Skeleton 14071) exhibited border shifting at the sacro-coccygeal border, causing a cranial shift. The first coccygeal vertebra had fused to the base of the sacrum, along the anterior and posterior surface of the body (Plate 2). The cornu were still visible, neither of which had fused to the sacral neural arch of the fifth sacral vertebra. Another mature adult male (Skeleton 15042) also had a slight border shift at the thoracic-lumbar border of his spine; the man's twelfth thoracic vertebra had a lumbarised right superior articulating facet, which corresponded with a lumbarised right inferior articulating facet on his eleventh thoracic vertebra.

### 3.1.3 Cleft Neural Arches

The two halves of the neural arch normally surround and protect the spinal cord, but they can fail to unite during development leaving a cleft in the back of the vertebra. However, the spinal cord remains protected as the gap is bridged by a tough fibrous tissue (Barnes 1994, 117-120). Cleft neural arches are most common at the border regions between the vertebra types, especially in the sacrum where the entire bone may be involved (Barnes 1994, 119-120). Cleft sacral arches have often been termed '*spina bifida occulta*' in the palaeopathological literature, but the causes of cleft arches and true spina bifida are quite different, and cleft neural arches are not related to the more severe *spina bifida cystica* (*ibid*).

A bifid spinous process (part of the vertebra that protrudes posteriorly) was observed in two of the mature adult males (Skeleton 14071 and 15042). In both cases the spinous process of the first sacral vertebra had become bifurcated (Plate 3). Barnes (1994) states that various forms of neural arch clefting are common, especially at border regions (e.g. interface between thoracic and lumbar). In the case of the mature adult male from St Benet's, the observed changes in the spinous process are probably related to a discrepancy in the timing of the development between both halves of the neural arch.



**Plate 3** SK 14071 bifid spinous process to first sacral vertebra

### 3.14 Other Spinal Anomalies

The spinous process of the fourth cervical vertebrae of Skeleton 3379 deviated laterally to the left. The same individual also had asymmetrical transverse foramen on his sixth cervical vertebra. The right foramen was much larger than the left and was probably the result of the dominance of the vertebral artery on that side.

The young middle adult female (Skeleton 3381) had an incomplete left transverse foramen on her second cervical vertebra (Plate 4). Only a small spicule of bone was evident on the posterior-superior margin of the inferior articular facet, which did not meet with the posterior aspect of the transverse foramen, and may have been the result of the dominance of the vertebral artery on that side.

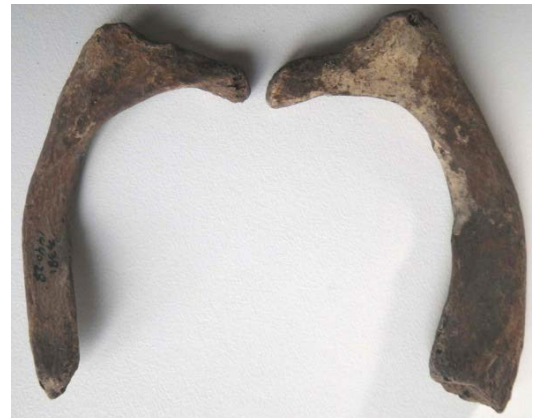

**Plate 4** Sk 3381 incomplete transverse foramen

Asymmetrical vertebral body shapes were noted in the spine of the mature adult female (Skeleton 3492). The bodies of the tenth, eleventh and twelfth thoracic vertebrae were irregular in shape; the right anterior margin of the bodies protruded further than the left. The alteration in the shape of the bodies may have been developmental, or a response to mechanical stress.

### 3.1.5 Anomalies of the Ribs

The young middle adult female (Skeleton 3381) exhibited asymmetry of the first ribs, both of which were very small. The right rib looked to be in proportion, whereas the left rib shaft was half the width of the right, however, it still articulated correctly and had a normal degree of curvature (Plate 5). Irregular segmentation of the sclerotomic tissue during embryonic development can manifest in a variety of ways including bifurcation, flaring, abnormal wideness, merging (fusion), bridging and partial bridging (Barnes 1994, 71).



**Plate 5** Sk 3381 asymmetry of the first ribs

### 3.1.6 Anomalies of the Sternum

The young middle adult female (Skeleton 3381) expressed another developmental anomaly. Her manubrium was fused to the sternum; the ventral and dorsal surfaces of the bones were smooth and continuous with the rest of the bone surface, the right lateral surface was also continuous between the manubrium and sternum, however, a cleft was visible on the left lateral surface between the two bones. The manubrium can become either partially or completely fused to the sternum as a result of a failure of the cartilaginous manubrio-mesosternal joint to develop (Barnes 1994). According to Barnes (1994) fusion can interfere with optimum respiration and has been associated with lung infections, however, the female skeleton did not show evidence for respiratory infection.

The inferior part of the sternum of Skeleton 3492 (older middle adult) was wider than the proximal end.

The proximal end measured 30.7mm wide and the distal end measured 47.4mm wide. According to Barnes (2012), this type of variation is one of the most common and is caused by the timing of the sternal bands joining together.

The xiphoid of the mature adult male (Skeleton 14071) had fused to the sternum. Fusion at the xiphoid-sternal border is known as xiphisternal joint fusion and is generally more common in males than females. (Barnes 1994).

### 3.1.7 Retroversion of the Shoulder

Excessive retroversion of the glenoid cavity results from a developmental deformity and is considered the primary aetiology of posterior instability of the shoulder (Brewer *et al.* 1986). A larger retroversion angle is consistent with an increased range of external rotation (Kronberg *et al.* 1990). Brewer *et al.* (1986) found that those suffering from retroversion had a significantly reduced ability in throwing a ball, swimming, arm blocking in football and bench-pressing weights.

Skeleton 14071 (mature adult male) exhibited retroversion of the shoulder joints; both of his glenoids were angled slightly posteriorly. The right glenoid was also affected by moderate osteophytic lipping, which may have been response to try to stabilise the joint. The individual had very short clavicles, which could also been a developmental anomaly. The other mature adult male (Skeleton 3379) also had slight retroversion of the glenoids, both being angled slightly posteriorly.

## 3.2 METABOLIC CONDITIONS

### 3.2.1 *Cribra Orbitalia*

*Cribra orbitalia* is a term used to describe fine pitting in the orbital roof which develops during childhood and often recedes during adolescence or early adulthood. Until recently, iron deficiency anaemia was the accepted cause of these lesions (Stuart-Macadam 1992), but a strong case has been made by Walker *et al.* (2009) for different types of anaemia as the causative factor. These include megaloblastic anaemia in the New World, suggesting a diet deficient in Vitamin B<sub>12</sub> (i.e. plant-based and lacking in animal products) and/or folic acid. Such dietary deficiency could have been exacerbated through poor sanitation leading to infection and infestation with gut parasites (*ibid*). In malarious areas of the Old World, haemolytic anaemia (e.g. sickle cell anaemia and thalassemia) may be important in the development of *cribra orbitalia* (*ibid*). However, for areas such as northern Europe they have proposed that *cribra orbitalia* may be more likely related to conditions such as scurvy (Vitamin C deficiency) or chronic infections (*ibid*). *Cribra orbitalia* is often used as an indicator of general stress (Lewis 2000; Roberts and Manchester 2005) and is often found associated with agricultural economies (Roberts and Cox 2003).

The mature adult male (Skeleton 3379), young middle adult female (Skeleton 3381) and juvenile (Skeleton 14007) all exhibited lesions in their orbital roofs indicative of *cribra orbitalia*. A crude prevalence rate of 7.6% of individuals from the early medieval period had *cribra orbitalia*, which was calculated using figures from Roberts and Cox (2003, Table 4.11, 187)

### 3.3 TRAUMA

The evidence for trauma in archaeological populations is restricted to that visible in the skeletal remains, unless soft tissue is preserved (Roberts and Manchester 2005, 85-86). Therefore, most of the soft-tissue injuries sustained by archaeological populations will be invisible, although occasionally soft tissue injuries can be inferred through ossification of the tissues at the site of damage, known as *myositis ossificans* (*ibid*). Much of the evidence for trauma in archaeological populations focuses on fractures to the bones (*ibid*, 84-85), although long standing well-healed fractures may be hard to detect (Jurmain 1999, 186).

Ante-mortem injuries occurred during life and show evidence for healing, whereas peri-mortem injuries occurred around the time of death and consequently no evidence for healing will be seen. Peri-mortem injuries did not necessarily occur at the instant of death. It takes time for evidence of healing to be visible in the bone following an injury, and also for bone to lose the physical characteristics it had in life following death. Therefore 'peri-mortem' really refers to a three-week window either side of death (Roberts and Manchester 2005, 114). Distinguishing between peri-mortem trauma and post-mortem damage can be difficult. Generally, post-mortem breaks will have a paler surface than the surrounding bone and broken edges will usually be perpendicular to the bone (*ibid*, 114-116; Lovell 1997, 145; Sauer 1998). Recent post-mortem breaks are usually easily distinguished, but breaks that occurred while the skeleton was in the burial environment and long before the skeleton was excavated may be much harder to identify as such.

#### 3.3.1 Ante-Mortem Fractures

Two of the mature adult males had ante-mortem long bone fractures. In Skeleton 14071 the fracture was located on the distal shaft of his left ulna and appears to have been oblique, but the two fragments appear to have reunited well with good apposition (Plate 6). The callous was generally smooth and well remodelled on its anterior, lateral and posterior surfaces, while bone formation along the interosseous border was more irregular and rugged in appearance. According to Dandy and Edwards (2003, 204), '...the ulna is vulnerable to direct trauma and is easily cracked by a direct blow when protecting the face from an impact or from missiles.' A crude prevalence rate of 1.3% of individuals from the early medieval period had fractured ulnae, which was calculated using figures from Roberts and Cox (2003, Table 4.27, 205)



**Plate 6** Sk14071 fracture to the distal shaft of the left ulna

Skeleton 15042 had a possible well healed fracture to the distal surface of his right radius. A hair line

fissure was present on the distal articular surface which travelled from the lateral anterior margin, where a cyst was located, at the posterior medial margin. It is possible that the man had suffered from a Barton fracture (Dandy and Edwards 1998, 210), which occurs when an individual lands on the wrist while it is flexed (*ibid*). According to Wedel and Galloway these fractures are commonly seen in elderly patients and motorcycle accidents (2014, 2223).

Both of the mature adult males had crush fractures in their spines. Skeleton 3379 had crush fractures to his tenth and eleventh thoracic vertebrae, while Skelton 14071 had crush fractures affecting his third to seventh thoracic vertebrae. The old middle adult female (Skelton 3492) also had crush fractures, which affected her ninth and tenth thoracic vertebrae. Crush fractures are often seen in the thoraco-lumbar region of elderly individuals who have slipped and landed on their bottom (Dandy and Edwards 2003), but could also occur in younger patients who fall from a height and land on their heels (*ibid*). A crude prevalence rate of 1.1% of individuals from the early medieval period had fractured vertebrae, which was calculated using figures from Roberts and Cox (2003, Table 4.27, 206).

### 3.3.2 Ossified Haematoma

Haematomas can result from direct blunt force trauma or the tearing of muscle fibres, causing blood to collect and clot (Aufderheide and Rodríguez-Martín 1998, 27). If the damaged muscle is exercised too soon following the injury, the blood clot may ossify, producing a bony lump at the site of the haematoma.

One of the mature adult males (Skeleton 15042) had a smooth solid bone nodule on the medial surface of the anterior spine of his left tibia mid-shaft. The lesion measured 18.6mm superior-inferiorly and 16.7mm anterior-posteriorly, and was well integrated into the bone surface. Skeleton 3492 (old middle adult female) had a small ossified nodule of bone on the lateral margin of the mental eminence of the right mandible. The lesion measured 6.5mm x 3.7mm and had a smooth appearance, which was continuous with the rest of the mandible and is likely to be an ossified haematoma. Alternatively, the lesion may have been the result of an osteoid osteoma, a lesion that rarely exceeds one centimetre in diameter, which can develop in a small cavity inside cancellous or cortical bone, and can cause severe pain out of proportion to their size (Dandy and Edwards, 2003). However; it is the long bones that are usually affected while the cranium seems to be largely spared (Ortner 2003). The lesion could also have resulted from a form of benign tumour known as an osteoma, which generally occur on the outer table of the skull vault, and form a small lesion typically less than one centimetre in diameter, and appear as a dense domed nodule of bone (Ortner 2003).

### 3.3.3 *Osteochondritis Dissecans*

Localised death (necrosis) of a small part of the joint surface can be caused by trauma. When this happens the damaged piece can become detached from the rest of the joint surface, known as *osteochondritis dissecans* (Roberts and Manchester 2005, 121). These lesions appear as roughly circular, porous depressions in the joint surfaces of skeletal remains. A small lesion thought to be *osteochondritis dissecans* was evident on the proximal articulation of the left proximal foot phalanx for the first metatarsal of Skeleton 3381 (young middle adult female) The right cuneiform of the mature adult male

(Skeleton 14071) also had a small lesion thought to be *osteochondritis dissecans* on the superior surface of the distal articulation. A crude prevalence rate of 1.5% of individuals from the early medieval period had osteochondritis dissecans, which was calculated using figures from Roberts and Cox (2003, Table 4.29, 210)

### 3.3.4 Calcaneus lesions



**Plate 7** Sk 14071 bilateral calcaneal lesions

Skeleton 14071, a mature adult male, had bilateral crescent shaped lytic lesions on the anterior-medial margin of both calcanei (Plate 7); the surface of the lesions had a roughened appearance. These lesions may be the result of avulsion fractures, usually caused through twisting the ankle in such a way that the bifurcate ligament is strained and the portion of the calcaneus to which it is anchored becomes detached (Daftary *et al* 2005, Robbins *et al* 1999). These fractures are difficult to detect in modern patients and as a result the detached portions usually fail to fuse (Daftary *et al* 2005). They are usually seen in males (*ibid*, Robbins *et al* 1999), however, there is a possibility these lesions are developmental, and further research is required. The same individual was also missing the medial extensions to their

plantar articular surfaces on the distal articulations of the right second and third metatarsals. Unlike the calcaneal lesions, the surface around the missing bone was smooth and unreactive, and may have had a developmental rather than traumatic origin.

## 3.4 JOINT DISEASE

The term joint disease encompasses a large number of conditions with different causes, which all affect the articular joints of the skeleton. Factors influencing joint disease include physical activity, occupation, workload and advancing age, which manifest as degenerative joint disease and osteoarthritis. Alternatively, joint changes may have inflammatory causes in the *spondyloarthropathies*, such as septic or rheumatoid arthritis. Different joint diseases affect the articular joints in a different way, and it is the type of lesion, together with the distribution of skeletal manifestations, which determines the diagnosis (Rogers 2000; Roberts and Manchester 2005).

### 3.4.1 Degenerative Joint Disease

The term joint disease encompasses a large number of conditions with different causes, which all affect the articular joints of the skeleton. Factors influencing joint disease include physical activity, occupation, workload and advancing age, which manifest as degenerative joint disease and osteoarthritis. Alternatively, joint changes may have inflammatory causes in the *spondyloarthropathies*, such as septic or rheumatoid arthritis. Different joint diseases affect the articular joints in a different way, and it is the type of lesion, together with the distribution of skeletal manifestations, which determines the diagnosis.

The most common type of joint disease observed tends to be degenerative joint disease (DJD). DJD is characterised by both bone formation (osteophytes) and bone resorption (porosity) at and around the articular surfaces of the joints, which can cause great discomfort and disability (Rogers 2001).

All four adults suffered from joint disease; the males were both affected to a greater degree, which is unsurprising considering they were the oldest individuals in the group. All four individuals exhibited degenerative changes in their manubrium. The two females and the mature adult male (Skeleton 14071), also revealed changes in their acetabulum (hip joint). Only the two mature adult males exhibited changes to the medial clavicles (which articulate with the manubrium), glenoids and proximal humeri (shoulder joint) and distal ulnae and radii (part of the wrist). The mature adult male (Skeleton 14071) revealed changes to both of his distal femora (part of the knee joint); while only the young middle adult female (Skeleton 3381) exhibited changes to her left temporomandibular joint. The young middle adult female and the mature adult male were affected by degenerative changes to metatarsals and foot phalanges.

The intervertebral discs are the 'shock absorbers' of the spine, but these can degenerate as a result of gradual desiccation (age-related drying), which then causes transmission of the stress from the vertebral discs to the articular facets and ligaments (Hirsh 1983, 123). Spinal osteophytes form to compensate for the constant stress that is placed on the spine as a result of human posture (Roberts and Manchester 2005, 106). Increasing stress or activity can therefore lead to increased size and prevalence of osteophytes (*ibid*).

Four of the adults also exhibited evidence for moderate joint disease in the spine (Skeleton 3379, 3381, 3492 and 14071). This was noted in over half of the mature adult males' vertebral bodies (56.4%) and many of the articular facets, whereas just over a quarter of the female vertebrae were affected. The vertebral bodies largely showed evidence for joint degeneration in the form of porosity and osteophyte formation, whereas the facets were more likely to be affected by osteophyte formation alone.

### 3.4.2 Schmorl's Nodes


Schmorl's nodes affect the spine. They manifest as indentations in the upper and lower surfaces of the vertebral bodies caused by the pressure of herniated vertebral discs (Aufderheide and Rodríguez-Martín 1998). Discs may rupture due to trauma, but vertebrae weakened by infection, osteoporosis or neoplastic disease may be more vulnerable (Roberts and Manchester 2005, 140-141). Schmorl's nodes are often associated with degenerative changes to the vertebral bodies (Aufderheide and Rodríguez-Martín 1998; Hilton *et al.* 1976) and are most commonly seen in the lower thoracic vertebrae (Hilton *et al.* 1976). However, recently, a correlation was found between the shape and size of vertebrae and the development of Schmorl's nodes, suggesting there may be a congenital aspect to their development (Plomp *et al.* 2012).

Schmorl's nodes affected all of the individuals from St Benet's apart from the juvenile. Skeleton 3379 (mature adult male) had Schmorl's nodes in his thoracic and lumbar spine, affecting eight of twelve of his thoracic vertebrae and one out of one lumbar vertebrae. Skeleton 15042 (mature adult male) had Schmorl's nodes in five out of eleven of his thoracic vertebrae. The young middle adult female (Skeleton



3381) also had Schmorl's nodes in her thoracic and lumbar spine, affecting two of twelve of her thoracic and five of her six lumbar vertebrae. Another mature adult male (Skeleton 14071) had Schmorl's nodes in his thoracic spine only, affecting four of twelve vertebrae. The adolescent possible male, (Skeleton 6051) had five out of twelve thoracic and two out of five lumbar vertebrae with Schmorl's nodes.

### 3.4.3 Miscellaneous Joint Disease



**Plate 8** Sk 3381 changes to third lumbar vertebra

Skeleton 3381 (young middle adult female) had slightly unusual changes to the superior surfaces of two of her lumbar vertebrae. The anterior margin of the superior body surface of her fifth lumbar had an eroded epiphyseal ring, with lacy osteophytic lipping around the lateral margins of the body. The superior anterior margin of the third lumbar vertebra appeared porotic, with a remodelled trabecular appearance (Plate 8). While examination of the lesion was complicated by taphonomic alteration, it was evident that the epiphyseal ring had been preserved. These changes may be related to degenerative joint disease in the spine; alternatively they may have been the result of a circulatory disorder. Scheuermann's disease, which is one possible cause, manifests during adolescence, affecting more males than females and tends to affect

the eighth to tenth thoracic vertebrae (Ortner 2003). Although the anterior parts of the vertebral bodies are affected in this skeleton, Scheuermann's disease also results in wedge-shaped vertebral bodies (*ibid*), and although there was an angulation to the vertebral bodies, neither were wedge-shaped. Due to the fact that the lesions were located in the lumbar region of the spine and that more than one vertebra was affected, it was not felt there was not enough evidence to verify Scheuermann's disease as a diagnosis, and the changes remain undiagnosed. With regards to the female's fifth lumbar vertebra it is possible that the lesion was the result of an avulsion of the lumbar apophyseal ring, however, these are typically located at the posterior margin of the body (Alvarenga *et al.* 2014, Dietemann *et al.* 1988).

The old middle adult female (Skeleton 3492) has an extension to the inferior margin of the auricular surface on her left os coxa, which corresponds to an extension on the left sacro-iliac joint on her sacrum, when the two bones were articulated they formed a kissing osteophyte.

## 3.6 MISCELLANEOUS PATHOLOGY

Pathological lesions were observed in the adolescent (Skeleton 7061), but the cause of the lesions remains unknown. Expanded smooth edged lesions with an absence of reactive periosteal bone formation were recorded on the dorsal surface of the manubrium and the ventral surface of the third sacral vertebrae; the anterior bodies of the second thoracic to fifth lumbar also exhibited similar porotic lesions.



**Plate 9** Sk 7016 billowed appearance of superior and inferior vertebral body

skeletal involvement as a result of them is even rarer (Ortner 2003). When skeletal manifestations do occur, they tend to be destructive in origin rather than proliferative. One possible aetiology may be actinomycosis, which is a rare bacterial infection that affects humans and cattle. It is most common in individuals between the ages of fifteen and 35 years (Aufderheide and Rodríguez-Martín 1998, 194). The bacterium is usually focused in the cervico-facial region, where lesions within the oral cavity may give rise to the necessary conditions for the bacterium to thrive. More rarely, it affects the gastrointestinal tract where it may manifest in the thoracic and lumbar regions of the spine (*ibid*, 194). Infection is usually

The third to eleventh thoracic vertebrae and second to fifth lumbar vertebrae had a billowed appearance around the margins of the inferior and superior bodies (Plate 9). Both of these features are part of normal development, but in this individual appeared to be beyond what is termed normal variation. The anterior bodies of the third thoracic to fifth lumbar vertebrae exhibited a thickened layer of bone along the central region, with remodelled porotic/vascular lesions within the new bone (Plate 10). It is possible that the lesions were the result of a fungal or respiratory infection. Fungal infections are rare and



**Plate 10** Sk 7016 new bone formation on the anterior surface of the vertebral bodies

the result of an injury to the tissues in regions of the body that the bacterium is usually found, namely the mouth and throat, gastrointestinal tract and the female genital tract (Ortner 2003, 319). The distribution of the lesions could be characteristic of aspirational and gastrointestinal actinomycosis (Ortner and Putschar 1981, 218).

Both the mature adult male (Skeleton 14071) and adolescent (Skeleton 7061) had notches on the inferior margins of their left and right zygomas at the insertion of the masseter muscle. It is possible that both individuals carried out similar habitual activities that resulted in the altered appearance of their zygomas; alternatively, they may both have shared the same developmental anomaly.

### 3.7 CONCLUSION

Evidence for joint degeneration was noted in all five adults, but was more prolific in the mature adults and was probably age-related. Trauma to the spine suggests that these individuals carried out heavy physical work, probably from a young age, as these lesions were also noted in the adolescent. Moderate levels of trauma were identified in the individuals from St Benet's, some of which may have been the result of a physically strenuous life. Two males had crush fractures in their spine, which may have resulted from slips and landing on their bottom, or a fall from a height and landing on their heels. One of the mature adult males also had a well-healed fracture to his ulna, which may have occurred when defending his face or body from a blow, and another mature adult male had a fractured distal right radius, possibly as a result of falling onto a flexed wrist. The same individual also had an ossified blood clot on his left shin.

Numerous minor developmental anomalies were evident in the population, with Skeleton 3381 (young middle adult female) seemingly the most affected. None of the developmental anomalies appear to have been serious, and would have not have caused the individuals any serious health problems. The mature adult male (Skeleton 3379), young middle adult female (Skeleton 3381) and juvenile (Skeleton 14007) all suffered from cribra orbitalia, which is likely an indication poor childhood health.

The adolescent possible male was suffering from what may have been a fungal infection that appears to have been active at the time of his death. The disease could not be positively diagnosed and would benefit from further research.

## 4.0 DENTAL HEALTH

Analysis of the teeth from archaeological populations provides vital clues about health, diet and oral hygiene, as well as information about environmental and congenital conditions (Roberts and Manchester 2005).

Skeleton 14071, a mature adult male, did not have a maxilla; as a result this individual only had sixteen of the 32 observable tooth positions. A total of 112 tooth positions were present in the adult's dentition, from which 94 teeth were recovered. Fifteen teeth had been lost post-mortem, and the remaining three were either impacted or congenitally absent.

The adolescent (Skeleton 7061) had 32 tooth positions present, 26 of which were in occlusion and four (the third molars) were erupting. The juvenile (Skeleton 14007) had twenty tooth positions, four of which were in occlusion, eight were unerupted and eight had been lost post-mortem. The juvenile did not reveal any dental pathology.

### 4.1 DENTAL WEAR

Dental wear tends to be more common and severe in archaeological populations than in modern teeth.

Severity of the dental wear was assessed using a chart developed by Smith (1984). Each tooth was scored using a grading system ranging from 1 (no wear) to 8 (severe attrition of the whole tooth crown). The surviving teeth showed moderate to heavy wear in the mature adult males and in the molars of the young middle adult female. The teeth of the adolescent and the old middle adult female exhibited little wear. The first maxillary molars of Skeleton 15042 (mature adult male) were heavily worn on the mesial-lingual cusps, to the point where the tooth wear extended onto the root. His incisors were also heavily worn, while the rest of his teeth exhibited relatively little wear. The uneven wear patterns observed in the man's dentition and symmetrical nature of that wear may reflect a habitual activity that involved using the teeth as a tool.

#### 4.2 CALCULUS

If plaque is not removed from the teeth effectively (or on a regular basis) then it can mineralise and form concretions of calculus on the tooth crowns or roots (if these are exposed), along the line of the gums (Hillson 1996, 255-257). Mineralisation of plaque can also be common when the diet is high in protein (Roberts and Manchester 2005, 71). Calculus is commonly observed in archaeological populations of all periods, although poor preservation or damage caused during cleaning can result in the loss of these deposits from the teeth (*ibid*, 64).

Calculus was observed in the majority of teeth (98.6%), and was slight to heavy. Notably, the adolescent suffered from extensive calculus deposits, suggesting that their oral hygiene had not been adequate. The calculus prevalence rate at this site was high, compared with the early medieval prevalence of 39.2% of teeth affected (Roberts and Cox 2003, 132). The high prevalence of calculus may be related to poor dental care, or a diet high in protein.

#### 4.3 PERIODONTAL DISEASE

Calculus deposits in-between and around the necks of the teeth can aggravate the gums leading to inflammation of the soft tissues (gingivitis). In turn, gingivitis can progress to involve the bone itself, leading to resorption of the bone supporting the tooth, and the loss of the periodontal ligament that helps to anchor the tooth into the socket (Roberts and Manchester 2005, 73). It can be difficult to differentiate between periodontal disease and continuous eruption (whereby the teeth maintain occlusion despite heavy wear) in skeletal material, since both result in exposure of the tooth roots (*ibid*, 74).

The presence/absence of periodontal disease could be observed for all five adults and was slight to moderate in the males, but moderate to considerable in the females. The old middle adult was the most severely affected, and exhibited the heaviest deposits of calculus, which may have caused the irritation of the gums. The adolescent did not show any evidence for periodontal disease despite the heavy calculus deposits observed.

#### 4.4 DENTAL CARIES

Dental caries (tooth decay) forms when bacteria in the plaque metabolise sugars in the diet and produce

acid, which then causes the loss of minerals from the teeth and eventually leads to the formation of a cavity (Zero 1999). Simple sugars can be found naturally in fruits, vegetables, dried fruits and honey, as well as processed, refined sugar; since the latter three contain the most sucrose they are most cariogenic. Complex sugars are usually less cariogenic and are found in carbohydrates, such as cereals. However, processing carbohydrates, including grinding grains into fine powders or cooking them, will usually increase their cariogenicity (Moynihan 2003).

Only the young middle adult female (Skeleton 3381) and mature adult male (Skeleton 15042) were affected by caries. The female had what appeared to be a small carious lesion on her left mandibular third molar; however it could potentially have also been a defect in the enamel. The mature adult male had a large carious lesion on the occlusal surface of his right first maxillary molar, and a small carious lesion on the occlusal surface of his second right maxillary molar, a medium sized carious lesion was identified on the mesial surface of his left maxillary first molar, and another similar sized lesion on the mesial surface of his right mandibular first molar. Overall 3.4% of teeth were affected by carious lesions in the individuals from St Benet's, which was slightly lower than the overall early medieval prevalence rate of 4.2% (Roberts and Cox 2003, 191). The two largest caries observed in Skelton 15042 were located on his left and right first maxillary molars, which were the two teeth that exhibited the heaviest wear (section 4.1). It is possible that some form of habitual activity lead to the advanced wear on these particular teeth, removing the enamel and making them vulnerable to cariogenic decay.

#### 4.5 ABSCESSSES AND PERIAPICAL LESIONS

Dental abscesses occur when bacteria enter the pulp cavity of a tooth causing inflammation and a build-up of pus at the apex of the root. Eventually, a hole forms in the surrounding bone allowing the pus to drain out and relieve the pressure. They can form as a result of dental caries, heavy wear of the teeth, damage to the teeth (e.g. fractures), or periodontal disease (Roberts and Manchester 2005).

Three of the adults were affected by abscesses. One mature adult male (Skeleton 3379) had five abscesses, which were largely located at the back of the mouth and the female had two abscesses in the molar region. Skeleton 15042 (mature adult male) also had five abscesses, one of which was so large it had penetrated the internal and external wall of the maxilla. All five of the man's abscesses were concentrated in the maxilla around the first molars, both of which were heavily worn and had large caries. The dental abscesses would have caused the individual extreme pain and made chewing food or talking difficult. Overall a prevalence rate of 8.3% is obtained, which is nearly three times higher than the overall early medieval prevalence rate of 2.8% (Roberts and Cox 2003, 192).

#### 4.6 DENTAL ENAMEL HYPOPLASIA

Dental enamel hypoplasia (DEH) is the presence of lines, grooves or pits on the surface of the tooth crown, and occurs as a result of defective formation of tooth enamel during growth (Hillson 1996). Essentially, they represent a period when the crown formation is halted, and they are caused by periods of severe stress, such as episodes of malnutrition or disease, during the first seven years of childhood. Involvement of the deciduous (milk) teeth can indicate pre-natal stress (Lewis 2007). Trauma can also

cause DEH formation, usually in single teeth.

All five adults were affected with DEH; Skeleton 3381 (young middle adult female) and Skeleton 15042 (mature adult male) had the greatest number of teeth affected (6) and the mature adult male (Skeleton 3379) had the least number of teeth affected (1). Overall females were more likely to be affected with DEH than males. It is possible that females suffered more childhood stress, or alternatively, that they were more successful at surviving stress than males. The prevalence rate of DEH at St Benet's was 11%, which was higher than the overall early medieval prevalence rate of 7.4% (Roberts and Cox 2003, 188).

#### 4.7 ENAMEL CHIPS

Small chips to the enamel usually occur along the labial/ buccal (lip/ cheek) side of the incisal/ occlusal (biting) surfaces of the teeth. Such enamel chips have been attributed to using the teeth as tools, or eating foods that might cause such minor damage to the teeth (Roberts and Manchester 2005, 81). The young middle adult female (Skeleton 3381) had small chips on the buccal surfaces of five of her teeth in her left maxilla. The mature adult male (Skeleton 3379) also had small chips on two of his left maxillary anterior teeth, and another mature adult male (Skeleton 15042) had chips on the labial surface of his central and lateral incisors.

#### 4.8 DENTAL ANOMALIES

##### 4.8.1 Crowding

Crowding and displacement of teeth was observed in the old middle adult female (Skeleton 3492) whose right mandibular canine anteriorly overlapped her lateral incisor. The dentition of the adolescent (Skeleton 7061) revealed a similar pattern of overcrowding with the right mandibular canine anteriorly overlapping the lateral incisor as did the right central incisor. Interestingly, the dentition of the mature adult male (Skeleton 3379) was widely spaced, with gaps between each tooth.

##### 4.8.2 Congenitally Absent and Impacted Teeth

Teeth can be absent from the erupted dentition due to a genuine failure of the tooth to develop (congenital absence), or because the tooth develops but fails to erupt (impaction). Full impaction means the tooth remains completely within the jaw, but teeth that erupt at an angle can be considered partially impacted. In well preserved archaeological skeletal remains it is usually impossible to tell without a radiograph whether a tooth has not erupted because it is impacted or because it is congenitally absent. Occasionally, it is possible to observe that a tooth is impacted if post-mortem damage exposes the impacted tooth. Since systematic radiographs were not taken of all the jaws from St Benet's, teeth that were absent from the erupted dentition were recorded as 'not present/ unerupted' unless there was definite evidence for impaction. The mature adult male (Skeleton 14071) had unerupted/congenitally absent third molars in his left and right mandible, while the old middle adult female (Skeleton 3492) had an unerupted/congenitally absent right maxillary third molar. Overall the prevalence of unerupted/congenitally absent teeth was 2.5%. The crude prevalence rate for impacted third molars

during the early medieval period was 2.4% (Roberts and Cox 2003, 214)

#### 4.9 DENTAL CONCLUSIONS

Analysis revealed that the majority of teeth (98.6%) were affected by deposits of calculus, which were slight to heavy. Notably, the adolescent suffered from extensive calculus deposits, suggesting that their oral hygiene had not been adequate. Periodontal disease was more advanced in the women, and most severe in the old middle adult woman, who also exhibited the heaviest deposits of calculus, which may have caused the irritation of the gums. However, the adolescent did not show any sign of periodontal disease despite the heavy calculus deposits observed. The prevalence rate of caries in the St Benet population was lower than expected for the period, which may suggest that the diet was low in fruits, honey and processed carbohydrates. The frequency of abscesses was considerably higher than the mean for the period and may have, in some cases, been the result of heavy wear, although in others no obvious cause was evident. All four of the adults were affected by periods of severe stress in their childhood, which had manifest as grooves in the surface of their teeth.

#### 5.0 DISCUSSION AND SUMMARY

The osteological analysis of the skeletal assemblage from St Benet's has provided a glimpse into the lives of the people buried there. The small group of skeletal remains included three mature adults, one old middle adult and a young middle adult. All three of the mature adults were male, and both survived into their mature adulthood, while the two women died in middle adulthood. Additionally, a juvenile and an adolescent were found; the adolescent is thought to have been male. The youngest individual was probably around one year of age; however, the age is tentative at best due to conflicting age estimates gained from different aspects of the skeletal remains. The stature of the males and females was generally below the national average for the period, but fell within the normal range. One of the mature adult males was possibly of African or mixed ancestry based on his cranial characteristics.

Evidence for joint degeneration was noted in all five of the adults, but was more prolific in the mature adults and was probably age-related. Schmorl's nodes in the spine indicative of herniated discs suggests that these individuals may have carried out heavy physical work, probably from a young age, as these lesions were also noted in the older adolescent. Moderate levels of trauma were identified in the individuals from St Benet's, some of which may have been the result of a physically strenuous life; two of the males had crush fractures in their spine, which may have resulted from slips and landing on their bottom or a fall from a height and landing on their heels. One of the mature adult males also had a well-healed fracture to his ulna, which may have occurred when protecting his face or body from a blow, and another had an ossified blood clot on his left shin and a distal radius fracture.

Numerous minor developmental anomalies were also evident amongst the population, Skeleton 3381 (young middle adult female) was seemingly the most affected. None of the developmental anomalies appear to have been serious and would have been unlikely to have caused the individuals any serious health problems. The mature adult male (Skeleton 3379), young middle adult female (Skeleton 3381)

and juvenile (Skeleton 14007) suffered from cribra orbitalia, which may be an indication of the general poor health of the population. Grooves in the teeth of all five of the adults also revealed that they were affected by periods of severe stress during their childhood.

The older adolescent suffered from what may have been a fungal infection, which appears to have been active at the time of his death. The disease could not be positively diagnosed and would benefit from further research.

An extremely high prevalence of calculus was observed amongst the dentitions from St Benet's, which exceeded the average for the period, suggesting that their oral hygiene had not been adequate. Some of the heaviest deposits were observed on the adolescent's teeth. Periodontal disease was more advanced in the females and may have been related to the frequency of calculus. However, caries were slightly lower in the St Benet's population than expected for the period, which may suggest that the diet was low in fruits, honey and processed carbohydrates. The prevalence of dental abscesses was higher than the medieval mean.



## References

- Alvarenga, J. A. L., Ueta, F. T. S., Del Curto, D., Salvioni Ueta, R. H., Martins D.E., Wajchenberg, M. and Puertas, E. B. 2014. 'Case report; Apophyseal ring fracture associated with two levels extruded disc herniation: case report and review of the literature', *Einstein* (online version) (12) 2; 230-231
- Aufderheide, A. C. and Rodríguez-Martín, C. 1998. *The Cambridge Encyclopedia of Human Paleopathology* (Cambridge)
- Barnes, E. 2012. *Atlas of Developmental Field Anomalies of the Human Skeleton: A Paleopathology Perspective* (Colorado)
- Barnes, E. 1994. *Developmental Defects of the Axial Skeleton in Paleopathology* (Niwot, Colorado)
- Bass, W. M. 1987. *Human Osteology: A Laboratory and Field Manual* (Columbia)
- Berry, A. C. and Berry, R. J. 1967. 'Epigenetic variation in the human cranium' *Journal of Anatomy* 101: 361-379
- Brewer, B. J., Wubben, R. C. and Carrera, G. F. 1986 'Excessive retroversion of the glenoid cavity. A cause of non-traumatic posterior instability of the shoulder' *The Journal of Bone and Joint Surgery* (American volume) 68(5):724-731
- Brooks, S. T. and Suchey, J. M. 1990. 'Skeletal age determination based on the os pubis: a comparison of the Acsádi-Nemeskéri and Suchey-Brooks methods' *Human Evolution* 5: 227-238
- Brothwell, D. R. 1981. *Digging Up Bones* (New York)
- Buikstra, J. E. and Ubelaker, D. H. (eds) 1994. *Standards for Data Collection from Human Skeletal Remains* (Fayetteville)
- Byers, S. N. 2010 *Introduction to Forensic Anthropology (International Edition)*, 3<sup>rd</sup> edition, (Boston)
- Cox, M. 2000. 'Ageing adults from the skeleton', in M. Cox and S. Mays (eds), *Human Osteology in Archaeology and Forensic Science* (London): 61-82
- Daftary, A., Haims, A. H. and Baumgaertner, M. R. 2005. 'Fractures of the calcaneus: A review with emphasis on CT' *RadioGraphics* 25: 1215-1226
- Dandy, D. J. and Edwards, D. J. 2003. *Essential Orthopaedics and Trauma* (Edinburgh)
- Dietemann, J.L., Runge, M., Badoz, A., Dosch, J.C., Beaujeux, R., Bonneville, J.F. and Wackenheim, A. 1988. 'Radiology of posterior lumbar apophyseal ring fractures: report of 13 cases' *Neuroradiology* 30(4):337-44
- Finnegan, M. 1978. 'Non-metric variation of the infracranial skeleton' *Journal of Anatomy* 125: 23-37
- Garland, A. N. and Janaway, R. C. 1989. 'The taphonomy of inhumation burials', in C. A. Roberts, F. Lee and J. Bintliff (eds) *Burial Archaeology: Current Research, Methods and Developments. British Archaeological Reports British Series* 211 (Oxford): 15-37
- Henderson, J. 1987. 'Factors determining the state of preservation of human remains', in A. Boddington, A. N. Garland and R. C. Janaway (eds) *Death, Decay and Reconstruction: Approaches to Archaeology and Forensic Science* (Manchester): 43-54
- Hillson, S. 1996. *Dental Anthropology* (Cambridge)
- Hilton, R.C., Ball, J. and Benn R.T. 1976. 'Vertebral end-plate lesions (Schmorl's nodes) in the dorsolumbar spine', *Ann Rheum. Dis.* 35: 127-132
- Hirsh, L. 1983. 'Cervical degenerative arthritis - possible cause of neck and arm pain', *Postgraduate Medicine* 74 (1): 123-130

- İşcan, M. Y. and Loth, S. R. 1986. 'Determination of age from the sternal rib in white females: a test of the phase method' *Journal of Forensic Sciences* 31: 990-999
- İşcan, M. Y., Loth, S. R. and Wright, R. K. 1984. 'Age estimation from the rib by phase analysis: white males' *Journal of Forensic Sciences* 29: 1094-1104
- İşcan, M. Y., Loth, S. R. and Wright, R. K. 1985. 'Age estimation from the rib by phase analysis: white females' *Journal of Forensic Sciences* 30: 853-863
- Janaway, R. C. 1996. 'The decay of buried human remains and their associated materials', in J. Hunter, C. A. Roberts and A. Martin (eds) *Studies in Crime: An Introduction to Forensic Archaeology* (London): 58-85
- Jimenez, D. F., Barone, C. M., Argamoso, R. V., Goodrich, J. T. and Shprintzen, R.J. 1994. 'Asterion region synostosis', *Cleft Palate Craniofacial Journal* 31: 136-141
- Jurmain, R. 1999. *Stories from the Skeleton* (London and New York)
- Kennedy, K. A. R. 1989. 'Skeletal markers of occupational stress', in M. Y. İşcan and K. A. R. Kennedy (eds) *Reconstruction of Life from the Skeleton* (New York): 129-160
- Kimonis, V., Gold, J-A., Hoffman, T. L., Panchal, J. and Boyadjiev, S. A. 2007. 'Genetics of craniosynostosis' *Seminars in Pediatric Neurology* 14: 150-161
- Kronberg, M., Broström, L. A. and Söderlund, V. 1990. 'Retroversion of the humeral head in the normal shoulder and its relationship to the normal range of motion', *Clinical Orthopedics and Related Research* (253):113-7
- Lewis, M. E. 2007. *The Bioarchaeology of Children: Perspectives from Biological and Forensic Anthropology* (Cambridge)
- Lewis, M. E. 2000. 'Non-adult palaeopathology: current status and future potential', in M. Cox and S. Mays (eds) *Human Osteology in Archaeology and Forensic Science* (London): 39-57
- Lovejoy, C. O., Meindl, R. S., Pryzbeck, T. R. and Mensforth, R. P. 1985. 'Chronological metamorphosis of the auricular surface of the ilium: a new method for the determination of adult skeletal age at death' *American Journal of Physical Anthropology* 68: 15-28
- Lovell, N. C. 1997. 'Trauma analysis in paleopathology', *Yearbook of Physical Anthropology* 40: 139-170
- Mays, S. and Cox, M. 2000. 'Sex determination in skeletal remains', in M. Cox and S. Mays (eds) *Human Osteology in Archaeology and Forensic Science* (London): 117-130
- McKinley, J. I. 2004. 'Compiling a skeletal inventory: disarticulated and co-mingled remains', in M. Brickley and J. I. McKinley (eds) *Guidelines to the Standards for Recording Human Remains. IFA Paper No. 7* (Southampton and Reading): 14-17
- Miles, A., Powers, N., Wroe-Brown, R. and Walker, D. 2008. *St Marylebone Church and Burial Ground in the 18th to 19th Centuries: Excavations at St Marylebone School, 1992 and 2004-6* (London)
- Molleson, T. 1995. 'Rates of ageing in the eighteenth century', in S. R. Saunders and A. Herring (eds) *Grave Reflections: Portraying the Past Through Cemetery Studies* (Toronto): 199-222
- Molleson, T. and Cox, M. 1993. *The Spitalfields Project. Vol 2. The Anthropology: The Middling Sort*, CBA Research Report 86 (York)
- Moorrees, C. F. A., Fanning, E. A. and Hunt, E. E. 1963a 'Formation and resorption of three deciduous teeth in children' *American Journal of Physical Anthropology* 21: 205-213
- Moorrees, C. F. A., Fanning, E. A. and Hunt, E. E. 1963b 'Age variation of formation stages for ten permanent teeth' *Journal of Dental Research* 42: 1490-1502

- Moynihan, P. 2003. 'Diet and dental caries', in J. J. Murray, J. H. Nunn and J. G. Steele (eds) *The Prevention of Oral Disease* (Oxford): 9-34
- O'Loughlin, V. D. 2004. 'Effects of different kinds of cranial deformation on the incidence of wormian bones', *American Journal of Physical Anthropology* 123: 146-155
- Ortner, D. J. 2003. *Identification of Pathological Conditions in Human Skeletal Remains* (Amsterdam)
- Ortner, D.J. and Putschar, W.G.J. 1985. *Identification of Pathological Conditions in Human Skeletal Remains* (Washington)
- Plomp, K. A., Roberts, C. A. and Viðarsdóttir, U. S. 2012. 'Vertebral morphology influences the development of Schmorl's nodes in the lower thoracic vertebrae', *American Journal of Physical Anthropology* 149: 572-582
- Robbins, M. I., Wilson, M. G. and Sella, E. D. 1999. 'MR imaging of anterosuperior calcaneal process fractures' *American Journal of Roentgenology* 172: 475-479
- Roberts, C. A. and Cox, M. 2003. *Health and Disease in Britain* (Stroud)
- Roberts, C. A. and Manchester, K. 2005. *The Archaeology of Disease (third edition)* (Stroud)
- Rogers, J. 2000. 'The palaeopathology of joint disease', in M. Cox and S. Mays (eds) *Human Osteology in Archaeology and Forensic Science* (London): 163-182
- Rogers, J. 2001. 'The palaeopathology of joint disease', in M. Cox and S. Mays (eds), *Human Osteology in Archaeology and Forensic Science* (London): 163-182
- Sanchez-Lara, P. A., Graham, J. M. J., Hing, A. V., Lee, J. and Cunningham, M. 2007. 'The morphogenesis of wormian bones: A study of craniosynostosis and purposeful cranial deformation' *American Journal of Medical Genetics. Part A* 143: 3243-3251
- Sauer, N. J. 1998. 'The timing of injuries and manner of death: distinguishing among antemortem, perimortem and postmortem trauma', in K. Reichs (ed) *Forensic Osteology: Advances in the Identification of Human Remains* (Springfield): 321-332
- Saunders, S. R. 1989. 'Non-metric variation', in M. Y. İşcan and K. A. R. Kennedy (eds) *Reconstruction of Life from the Skeleton* (New York): 95-108
- Scheuer, L. and Black, S. 2000a. 'Development and ageing of the juvenile skeleton', in M. Cox and S. Mays (eds) *Human Osteology in Archaeology and Forensic Science* (London): 9-22
- Scheuer, L. and Black, S. 2000b. *Developmental Juvenile Osteology* (San Diego)
- Smith, B.H. 1984. 'Patterns of molar wear in hunter-gatherers and agriculturalists', *American Journal of Physical Anthropology* 63: 39-56
- Spriggs, J. A. 1989. 'On and off-site conservation of bone', in C. A. Roberts, F. Lee and J. Bintliff (eds) *Burial Archaeology: Current Research, Methods and Developments. British Archaeological Reports British Series* 211 (Oxford): 39-45
- Stuart-Macadam, P. 1992. 'Anemia in past populations', in P. Stuart-Macadam and S. Kent (eds) *Diet, Demography and Disease: Changing Perspectives of Anemia* (New York): 151-170
- Sture, J. F. 2001. *Biocultural Perspectives on Birth Defects in Medieval Urban and Rural English Populations*, Unpublished PhD Thesis (Durham)
- Trinkhaus, E. 1978. 'Bilateral asymmetry of human skeletal non-metric traits' *American Journal of Physical Anthropology* 49: 315-318
- Trotter, M. 1970. 'Estimation of stature from intact long limb bones', in T. D. Stewart (ed) *Personal Identification in Mass Disasters* (Washington DC): 71-83
- Ubelaker, D. H. 1989. *Human Skeletal Remains; Excavation, Analysis, Interpretation* (Washington)

- Walker, P. L. 1995. 'Problems of preservation and sexism in sexing: some lessons from historical collections for palaeodemographers', in S. R. Saunders and A. Herring (eds) *Grave Reflections: Portraying the Past Through Cemetery Studies* (Toronto): 31-47
- Walker, P. L., Bathurst, P. R., Richman, R., Gjerdrum, T. and Andrushko, V. A. 2009. 'The causes of porotic hyperostosis and cribra orbitalia: a reappraisal of the iron-deficiency-anemia hypothesis' *American Journal of Physical Anthropology* 139: 109-125
- Zero, D. T. 1999. 'Dental caries process' *Dental Clinics of North America* 43: 635-664

## APPENDIX A: OSTEOLOGICAL AND PALAEOPATHOLOGICAL CATALOGUE

|                        |   |          |          |          |          |          |          |          |                |          |          |          |          |          |          |          |
|------------------------|---|----------|----------|----------|----------|----------|----------|----------|----------------|----------|----------|----------|----------|----------|----------|----------|
| <b>Skeleton Number</b> | <b>3379</b>   |          |          |          |          |          |          |          |                |          |          |          |          |          |          |          |
| Preservation           | Very good   |          |          |          |          |          |          |          |                |          |          |          |          |          |          |          |
| Completeness           | 60%   |          |          |          |          |          |          |          |                |          |          |          |          |          |          |          |
| Age                    | 46+ mature adult  |          |          |          |          |          |          |          |                |          |          |          |          |          |          |          |
| Sex                    | Male  |          |          |          |          |          |          |          |                |          |          |          |          |          |          |          |
| Stature                | 171.31 +/- 4.43 (African)   |          |          |          |          |          |          |          |                |          |          |          |          |          |          |          |
| Non-Metric Traits      | <i>Parietal foramen</i> (bilateral), <i>ossicle at parietal notch</i> (right), <i>sutural mastoid foramen</i> (bilateral), <i>posterior condylar canal open</i> (bilateral), <i>precondylar tubercle</i> , <i>double anterior condylar canal</i> (bilateral), <i>accessory lesser palatine foramen</i> (bilateral), <i>mandibular torus</i> (left), <i>accessory supraorbital foramen</i> (left), <i>posterior ethmoid foramen extrasutural</i> (right), <i>suprascapular foramen</i> (partial, bilateral)  |          |          |          |          |          |          |          |                |          |          |          |          |          |          |          |
| Pathology              | DJD in the cervical, thoracic and lumbar vertebrae, both sides of the manubrium and medial clavicle, the right lateral clavicle, both glenoids and humeral heads and the distal right radius. Schmorl's nodes in the thoracic and lumbar spine. <i>Cribrra orbitalia</i> . Crush fracture to T11 affecting the left side of the body; left side measures 18.5mm, right side 23.2mm si. T10 also affected; left side measures 20.6mm si, right side 23.7mm si. Slight retroversion of the glenoids, both angled slightly posteriorly. Bilateral notches on the inferior margin of the zygomas, at the insertion of the masseter. Spinous process of C4 deviates laterally to the left. C6 exhibits asymmetry of the transverse foramen, the right being much larger than the left. |          |          |          |          |          |          |          |                |          |          |          |          |          |          |          |
| Dental Health          | 29/32 teeth present, 32 tooth positions present, 0/32 teeth lost ante mortem, 3/32 teeth lost post mortem, 29/29 teeth affected by calculus flecks to heavy calculus, 0 caries, 1/29 teeth with DEH. Externally draining abscesses on the right maxilla at the root apex of M1, on the right maxilla at the root apex of M2, on the left maxilla at the root apexes of M1 and M2, and on the right mandible at the root apex of the central incisor; Slight periodontal disease on the left mandible and maxilla, and moderate on the right mandible and maxilla. Teeth widely spaced   |          |          |          |          |          |          |          |                |          |          |          |          |          |          |          |
|                        | Right Dentition   |          |          |          |          |          |          |          | Left Dentition |          |          |          |          |          |          |          |
| Present                | P   | P        | P        | P        | P        | P        | P        | P        | PM             | P        | P        | P        | P        | P        | P        | P        |
| Calculus               | Mb Sdl  | Mb Hl    | Mb       | Mdm      | Mdm      | Hb Sl    | Hb Sl    | Mb Slm   | -              | Fbl Sm   | Sl Sb    | Fb Sl    | Fb Sl    | Mb Ml    | Mb Ml    | Mbd Hl   |
| DEH                    | -   | -        | -        | -        | -        | -        | -        | -        | -              | -        | -        | -        | -        | -        | -        | -        |
| Caries                 | -   | -        | -        | -        | -        | -        | -        | -        | -              | -        | -        | -        | -        | -        | -        | -        |
| Wear                   | 4   | 6        | 6        | 4        | 4        | 3        | 3        | 4        | -              | 3        | 3        | 4        | 6        | 7        | 5        | 4        |
| Maxilla                | <b>8</b>  | <b>7</b> | <b>6</b> | <b>5</b> | <b>4</b> | <b>3</b> | <b>2</b> | <b>1</b> | <b>1</b>       | <b>2</b> | <b>3</b> | <b>4</b> | <b>5</b> | <b>6</b> | <b>7</b> | <b>8</b> |
| Mandible               | <b>8</b>  | <b>7</b> | <b>6</b> | <b>5</b> | <b>4</b> | <b>3</b> | <b>2</b> | <b>1</b> | <b>1</b>       | <b>2</b> | <b>3</b> | <b>4</b> | <b>5</b> | <b>6</b> | <b>7</b> | <b>8</b> |
| Present                | P   | P        | P        | P        | P        | P        | P        | P        | PM             | PM       | P        | P        | P        | P        | P        | P        |
| Calculus               | Sb  | Sb       | Sb       | Sb       | Mb       | Mbl      | Mbl      | Sm       | -              | -        | Sm       | Mb Sl    | Fb       | Mbfl     | Ml       | Ml       |
| DEH                    | -   | -        | -        | -        | -        | -        | -        | -        | -              | -        | G        | -        | -        | -        | -        | -        |
| Caries                 | -   | -        | -        | -        | -        | -        | -        | -        | -              | -        | -        | -        | -        | -        | -        | -        |
| Wear                   | 5   | 5        | 6        | 4        | 3        | 2        | 2        | 2        | -              | -        | 3        | 3        | 3        | 8        | 6        | 5        |

|                        |  |  |  |  |  |  |  |  |  |  |  |  |  |  |  |  |
|------------------------|--|--|--|--|--|--|--|--|--|--|--|--|--|--|--|--|
| <b>Skeleton Number</b> | <b>3381</b>  |  |  |  |  |  |  |  |  |  |  |  |  |  |  |  |
| Preservation           | Very good  |  |  |  |  |  |  |  |  |  |  |  |  |  |  |  |
| Completeness           | 95%  |  |  |  |  |  |  |  |  |  |  |  |  |  |  |  |
| Age                    | 26-35 young middle adult   |  |  |  |  |  |  |  |  |  |  |  |  |  |  |  |
| Sex                    | Female   |  |  |  |  |  |  |  |  |  |  |  |  |  |  |  |
| Stature                | 152.2 cm +/- 3.55  |  |  |  |  |  |  |  |  |  |  |  |  |  |  |  |
| Non-Metric Traits      | <i>Mastoid foramen extrasutural</i> (bilateral), <i>posterior condylar canal open</i> (bilateral), <i>palatine torus</i> , <i>maxillary torus</i> (bilateral), <i>mandibular torus</i> (right), <i>accessory supraorbital foramen</i> (right), <i>transverse foramen bipartite</i> (bipartite), <i>hypotrochanteric fossa</i> (bilateral), |  |  |  |  |  |  |  |  |  |  |  |  |  |  |  |

|               |  |       |        |        |       |       |       |       |                |       |       |       |       |       |       |        |
|---------------|--|-------|--------|--------|-------|-------|-------|-------|----------------|-------|-------|-------|-------|-------|-------|--------|
|               | <i>third trochanter</i> (bilateral), <i>vastus notch</i> (bilateral), <i>vastus fossa</i> (right), <i>lateral tibial squatting facet</i> (bilateral), <i>double anterior calcaneal facet</i> (left)  |       |        |        |       |       |       |       |                |       |       |       |       |       |       |        |
| Pathology     | <i>Cribra orbitalia</i> , Schmorl's nodes in the thoracic and lumbar spine. DJD in the lumbar spine. DJD in the left mandible and right manubrium, the right acetabulum, both auricular surfaces, and the distal articulation of the proximal phalanx for the 5 <sup>th</sup> metacarpal. Supernumerary vertebrae at the lumbar-thoracic border, the vertebra has lumbar facets and a general lumbar appearance, the right lamina has a small rib facet, the left lamina is very enlarged and similar in appearance to L5, it could be a border shift- the sacrum is complete but taphonomically altered and the coccyx doesn't survive. C2 has an incomplete left transverse foramen, only a small spicule is evident at the posterior/superior margin of the inferior articular facet which does not meet the posterior aspect of the transverse foramen either developmental or pathology. OD on the proximal articulation of the left proximal foot phalanx for MT1. Slight cranial asymmetry; the right occipital protrudes further posteriorly than the left. Manubrium fused to the sternum, the anterior and posterior surfaces are smooth and continuous with the surface of the rest of the bone, the right lateral surface is also continuous between the manubrium to sternum, in the left lateral surface there is a cleft between the two bones. The superior anterior margin of L3 appears porotic exhibiting a remodelled trabecular appearance; the area is taphonomically altered but retains the annular ring. Asymmetry of the 1 <sup>st</sup> left and right rib, both are very small, the right looks normally proportioned, whereas the left shaft is half the width of the right, but articulates correctly and has a normal degree of curvature. The anterior margin of the superior body of L5 has an eroded annular ring, with lacy osteophytic lipping around the lateral margins. |       |        |        |       |       |       |       |                |       |       |       |       |       |       |        |
| Dental Health | 32/32 tooth positions present, 29 teeth present, 3/32 lost post mortem, 29/29 teeth affected by calculus, 1 caries on 1/29 teeth or a small defect in the enamel, DEH affects 6/29 teeth, small chips on the buccal surface of the left maxillary dentition affecting central incisor, lateral incisor, canine, PM2 and M1. Moderate periodontal disease on the maxilla.   |       |        |        |       |       |       |       |                |       |       |       |       |       |       |        |
|               | Right Dentition  |       |        |        |       |       |       |       | Left Dentition |       |       |       |       |       |       |        |
| Present       | P  | P     | P      | P      | P     | P     | P     | PM    | P              | P     | P     | P     | P     | P     | P     | P      |
| Calculus      | Sbl Md   | Mb    | Mb     | Fb     | Fb Sd | Mb Sd | Fl    | -     | Mb             | Sb    | Mb Sd | Mb Sl | Fb Sl | Mb Sl | Mb Sl | Sbl Md |
| DEH           | -  | -     | -      | -      | -     | -     | -     | -     | -              | -     | G     | G     | -     | -     | -     | -      |
| Caries        | -  | -     | -      | -      | -     | -     | -     | -     | -              | -     | -     | -     | -     | -     | -     | -      |
| Wear          | 4  | 6     | 7      | 4      | 4     | 3     | 2     | -     | 4              | 3     | 4     | 4     | 4     | 7     | 6     | 5      |
| Maxilla       | 8  | 7     | 6      | 5      | 4     | 3     | 2     | 1     | 1              | 2     | 3     | 4     | 5     | 6     | 7     | 8      |
| Mandible      | 8  | 7     | 6      | 5      | 4     | 3     | 2     | 1     | 1              | 2     | 3     | 4     | 5     | 6     | 7     | 8      |
| Present       | P  | P     | P      | P      | PM    | P     | P     | P     | P              | P     | P     | PM    | P     | P     | P     | P      |
| Calculus      | Sbdl   | Sbmdl | Sl Mbd | Sbm MI | -     | HI Mb | MI Fb | Fb MI | Fb MI          | Sb MI | Sb MI | -     | Sbl   | Mbl   | Mb Sl | Sld Mb |
| DEH           | -  | -     | -      | -      | -     | -     | G     | G     | G              | -     | G     | -     | -     | -     | -     | -      |
| Caries        | -  | -     | -      | -      | -     | -     | -     | -     | -              | -     | -     | -     | -     | -     | -     | Sb?    |
| Wear          | 4  | 5     | 6      | 3      | -     | 3     | 3     | 4     | 4              | 4     | 4     | -     | 4     | 7     | 6     | 4      |

|                        |   |
|------------------------|---|
| <b>Skeleton Number</b> | <b>3492</b>   |
| Preservation           | Very good   |
| Completeness           | 80%   |
| Age                    | 36-45, old middle adult   |
| Sex                    | Female  |
| Stature                | 157.8 cm +/- 4.24   |
| Non-Metric Traits      | <i>Ossicle in lambdoid</i> (bilateral), <i>parietal foramen</i> (left), <i>ossicle in coronal</i> (bilateral), <i>mastoid foramen extrasutural</i> (bilateral), <i>sutural mastoid foramen</i> (right), <i>posterior condylar canal open</i> (bilateral), <i>accessory lesser palatine foramen</i> (left), <i>posterior ethmoid foramen extrasutural</i> (bilateral). <i>transverse foramen bipartite</i> (right), <i>double atlas facet</i> (right), <i>third trochanter</i> (bilateral) |
| Pathology              | Schmorl's nodes in the thoracic and lumbar spine, DJD in the cervical, thoracic and lumbar  |

|               |                 |   |      |      |      |        |     |         |                |       |     |     |        |       |        |    |
|---------------|-----------------|---|------|------|------|--------|-----|---------|----------------|-------|-----|-----|--------|-------|--------|----|
|               |                 | spine, both sides of the manubrium, the right capitate, hamate, lunate, scaphoid and trapezium, the left acetabulum, and the left and right auricular surface. Small ossified nodule of bone on the lateral margin of the mental eminence of the right mandible, measures 6.5mm x 3.7mm, the nodule has a smooth appearance which is continuous with the rest of the mandible, the anterior portion of the inferior body of T9 no longer has a visible annular ring, on the left side of the body is a shallow crescent shape visible on the left anterior margin- potentially avulsion of the endplate. The same vertebra also had a possible crush fracture anterior body height = 17.0mm six posterior body height = 20.9mm si, T10, anterior body height = 18.7mm si, posterior body height 21.6mm si. T10, 11 and 12 have asymmetrical body shapes; the right anterior margin of the body protrudes further than the left. The left os-coxa has an extension to the inferior margin of the left auricular surface, which corresponds to an extension on the left sacro iliac joint on the sacrum, when the two bones are articulated they form a kissing osteophyte. The distal end of the sternum is wider than the proximal end; proximal end measures 30.7mm, distal end measures 47.4. The sacrum is slightly asymmetrical- the right ala sits below the left. |      |      |      |        |     |         |                |       |     |     |        |       |        |    |
| Dental Health |                 | 32/32 tooth positions present, 23/32 teeth present, 8/32 lost post mortem, 23/23 teeth affected by calculus, slight to heavy deposits. DEH affects 4/23 teeth. 1/32 teeth NP. Considerable periodontal disease on the mandible and maxilla. External draining abscess on the right maxilla at the distal root apex of M2 and on the left maxilla at the distal root apex of M2.   |      |      |      |        |     |         |                |       |     |     |        |       |        |    |
|               | Right Dentition |   |      |      |      |        |     |         | Left Dentition |       |     |     |        |       |        |    |
| Present       | NP              | PM  | P    | P    | P    | P      | P   | P       | PM             | PM    | PM  | PM  | PM     | P     | P      | PM |
| Calculus      | -               | -   | Sdl  | Smdl | Sldb | Mb Smd | Mb  | Hb Sldm | -              | -     | -   | -   | -      | Sl Mb | Sm Slm | -  |
| DEH           | -               | -   | -    | -    | -    | G      | L   | -       | -              | -     | -   | -   | -      | -     | -      | -  |
| Caries        | -               | -   | -    | -    | -    | -      | -   | -       | -              | -     | -   | -   | -      | -     | -      | -  |
| Wear          | -               | -   | 6-   | 4    | 4    | 3      | 2   | 3       | -              | -     | -   | -   | -      | 5     | 3      | -  |
| Maxilla       | 8               | 7   | 6    | 5    | 4    | 3      | 2   | 1       | 1              | 2     | 3   | 4   | 5      | 6     | 7      | 8  |
| Mandible      | 8               | 7   | 6    | 5    | 4    | 3      | 2   | 1       | 1              | 2     | 3   | 4   | 5      | 6     | 7      | 8  |
| Present       | P               | P   | P    | P    | P    | P      | P   | P       | P              | P     | P   | P   | P      | P     | P      | PM |
| Calculus      | Sbdm            | Sbm Ml  | Mlbd | Mbl  | Mbl  | Hlb    | Hbl | Hbl     | Mbl            | Hb Ml | Hbl | Mml | Smd Ml | Mb Sl | Fbm Sl | -  |
| DEH           | -               | -   | -    | -    | -    | -      | -   | -       | -              | -     | L   | -   | L      | -     | -      | -  |
| Caries        | -               | -   | -    | -    | -    | -      | -   | -       | -              | -     | -   | -   | -      | -     | -      | -  |
| Wear          | 4               | 4   | 5    | 3    | 3    | 2      | 3   | 3       | 4              | 3     | 3   | 3   | 3      | 5     | 4      | -  |

|                        |   |
|------------------------|---|
| <b>Skeleton Number</b> | <b>7061</b>   |
| Preservation           | Very good   |
| Completeness           | 80%   |
| Age                    | 17- 18, adolescent  |
| Sex                    | ?Male   |
| Stature                | -   |
| Non-Metric Traits      | <i>Highest nuchal line (left), parietal foramen (right), foramen of Huschke (right), mastoid foramen extrasutural (bilateral), sutural mastoid foramen (bilateral), accessory supraorbital foramen (right), accessory infraorbital foramen (right). Allen's fossa (left), hypotrochanteric fossa (bilateral), exostosis in trochanteric fossa (bilateral).</i>  |
| Pathology              | Dorsal surface of the manubrium exhibits expanded porotic lesions, possibly as a result of vascular involvement; the body of the third sacral vertebrae exhibits the same lesions on the ventral surface of the body. The anterior bodies of T2-L5 also exhibit similar porotic lesions. T3-11 and L2-5 exhibit a very billowed appearance around the margins of the inferior and superior bodies. Both of these features are part of normal development, but appear to be beyond normal variation. T3-L5 exhibit a thickened layer of bone on the anterior surface of the bodies along the central region, with remodelled porotic/vascular lesions- possibly the result of a fungal infection. Schmorl's nodes in the thoracic and lumbar spine. Bilateral notches on the inferior margins of the zygomas at the insertion of masseter. |
| Dental Health          | 32/32 tooth positions present, 26/32 teeth present, 4/32 erupting, 2/32 lost post   |

|          |                 |   |          |          |           |          |          |          |                |          |          |          |          |          |          |          |
|----------|-----------------|---|----------|----------|-----------|----------|----------|----------|----------------|----------|----------|----------|----------|----------|----------|----------|
|          |                 | mortem, 25/26 teeth affected by calculus, flecks to heavy deposits. DEH affects 0/26 teeth. Slight dental overcrowding in the mandible; the lateral margin of the right central incisor overlaps the anterior surface of the right lateral incisor, the mesial margin of the right central incisor overlaps the anterior surface of the left central incisor. |          |          |           |          |          |          |                |          |          |          |          |          |          |          |
|          | Right Dentition |   |          |          |           |          |          |          | Left Dentition |          |          |          |          |          |          |          |
| Present  | E               | P   | P        | P        | P         | P        | P        | PM       | P              | P        | P        | P        | P        | P        | P        | E        |
| Calculus | -               | Sld<br>Fbl  | Sdb      | Sd<br>Fm | Fb<br>Smd | Fb<br>Sl | Sb<br>Sl | -        | Fb<br>Sl       | Fb<br>Sl | Sb       | Fb<br>Sl | -        | Sl       | Fb<br>Sl | -        |
| DEH      | -               | -   | -        | -        | -         | -        | -        | -        | -              | -        | -        | -        | -        | -        | -        | -        |
| Caries   | -               | -   | -        | -        | -         | -        | -        | -        | -              | -        | -        | -        | -        | -        | -        | -        |
| Wear     | -               | 2   | 3        | 2        | 2         | 2        | 2        | -        | 3              | 2        | 2        | 2        | 2        | 3        | 2        | -        |
| Maxilla  | <b>8</b>        | <b>7</b>  | <b>6</b> | <b>5</b> | <b>4</b>  | <b>3</b> | <b>2</b> | <b>1</b> | <b>1</b>       | <b>2</b> | <b>3</b> | <b>4</b> | <b>5</b> | <b>6</b> | <b>7</b> | <b>8</b> |
| Mandible | <b>8</b>        | <b>7</b>  | <b>6</b> | <b>5</b> | <b>4</b>  | <b>3</b> | <b>2</b> | <b>1</b> | <b>1</b>       | <b>2</b> | <b>3</b> | <b>4</b> | <b>5</b> | <b>6</b> | <b>7</b> | <b>8</b> |
| Present  | E               | P   | P        | P        | P         | P        | P        | P        | P              | PM       | P        | P        | P        | P        | P        | E        |
| Calculus | -               | Fbm   | Sl Fm    | Sl Fb    | Sl<br>Fd  | Hl<br>Mb | Hl<br>Fb | Ml<br>Fb | Mbl            | -        | Fb<br>Ml | Ml       | Ml       | Fm<br>Ml | Sl       | -        |
| DEH      | -               | -   | -        | -        | -         | -        | -        | -        | -              | -        | -        | -        | -        | -        | -        | -        |
| Caries   | -               | -   | -        | -        | -         | -        | -        | -        | -              | -        | -        | -        | -        | -        | -        | -        |
| Wear     | -               | 2   | 3        | 2        | 2         | 2        | 2        | 2        | 3              | -        | 2        | 2        | 2        | 3        | 2        | -        |

|                        |  |   |   |          |          |          |          |          |                |          |          |          |          |   |   |   |
|------------------------|--|---|---|----------|----------|----------|----------|----------|----------------|----------|----------|----------|----------|---|---|---|
| <b>Skeleton Number</b> | <b>14007</b>   |   |   |          |          |          |          |          |                |          |          |          |          |   |   |   |
| Preservation           | Very good  |   |   |          |          |          |          |          |                |          |          |          |          |   |   |   |
| Completeness           | 80%  |   |   |          |          |          |          |          |                |          |          |          |          |   |   |   |
| Age                    | 1-2.5 years, juvenile - disparity in ageing indicators   |   |   |          |          |          |          |          |                |          |          |          |          |   |   |   |
| Sex                    | -  |   |   |          |          |          |          |          |                |          |          |          |          |   |   |   |
| Stature                | -  |   |   |          |          |          |          |          |                |          |          |          |          |   |   |   |
| Non-Metric Traits      | -  |   |   |          |          |          |          |          |                |          |          |          |          |   |   |   |
| Pathology              | Cribra orbitalia. Aging techniques suggest a disparity in the individuals age- the anterior fontanelle is still open (fused by 1-2) however the metopic suture has fused (fused by 2-4 years). Metric analysis suggests 1-1.2 years. However the lumbar arches have also fused to the body (fuse 2-3 years). |   |   |          |          |          |          |          |                |          |          |          |          |   |   |   |
| Dental Health          | 20/20 tooth positions present, 4/20 teeth erupting, 8/20 teeth unerupted, 8/20 teeth lost post mortem.   |   |   |          |          |          |          |          |                |          |          |          |          |   |   |   |
|                        | Right Dentition  |   |   |          |          |          |          |          | Left Dentition |          |          |          |          |   |   |   |
| Present                | -  | - | - | UE       | E        | UE       | PM       | PM       | PM             | PM       | UE       | E        | UE       | - | - | - |
| Calculus               | -  | - | - | -        | -        | -        | -        | -        | -              | -        | -        | -        | -        | - | - | - |
| DEH                    | -  | - | - | -        | -        | -        | -        | -        | -              | -        | -        | -        | -        | - | - | - |
| Caries                 | -  | - | - | -        | -        | -        | -        | -        | -              | -        | -        | -        | -        | - | - | - |
| Wear                   | -  | - | - | -        | 2        | -        | -        | -        | -              | -        | -        | 2        | -        | - | - | - |
| Maxilla                | -  | - | - | <b>E</b> | <b>D</b> | <b>C</b> | <b>B</b> | <b>A</b> | <b>A</b>       | <b>B</b> | <b>C</b> | <b>D</b> | <b>E</b> | - | - | - |
| Mandible               | -  | - | - | <b>E</b> | <b>D</b> | <b>C</b> | <b>B</b> | <b>A</b> | <b>A</b>       | <b>B</b> | <b>C</b> | <b>D</b> | <b>A</b> | - | - | - |
| Present                | -  | - | - | P        | -        | -        | -        | -        | -              | -        | -        | -        | P        | - | - | - |
| Calculus               | -  | - | - | -        | -        | -        | -        | -        | -              | -        | -        | -        | -        | - | - | - |
| DEH                    | -  | - | - | -        | -        | -        | -        | -        | -              | -        | -        | -        | -        | - | - | - |
| Caries                 | -  | - | - | -        | -        | -        | -        | -        | -              | -        | -        | -        | -        | - | - | - |
| Wear                   | -  | - | - | 2        | -        | -        | -        | -        | -              | -        | -        | -        | 2        | - | - | - |

|                        |              |
|------------------------|--------------|
| <b>Skeleton Number</b> | <b>14071</b> |
|------------------------|--------------|



|                   |   |          |          |          |          |          |          |          |                |          |          |          |          |          |          |          |
|-------------------|---|----------|----------|----------|----------|----------|----------|----------|----------------|----------|----------|----------|----------|----------|----------|----------|
| Preservation      | Very good   |          |          |          |          |          |          |          |                |          |          |          |          |          |          |          |
| Completeness      | 80%   |          |          |          |          |          |          |          |                |          |          |          |          |          |          |          |
| Age               | 46+, Mature adult   |          |          |          |          |          |          |          |                |          |          |          |          |          |          |          |
| Sex               | Male  |          |          |          |          |          |          |          |                |          |          |          |          |          |          |          |
| Stature           | 163.8 +/- 2.99  |          |          |          |          |          |          |          |                |          |          |          |          |          |          |          |
| Non-Metric Traits | <i>Partial suprascapular foramen</i> (bilateral), <i>circumflex sulcus</i> (bilateral), <i>acetabular crease</i> (left), <i>femoral plaque</i> (right), <i>third trochanter</i> (left), <i>lateral tibial squatting facet</i> (bilateral) <i>peroneal tubercle</i> (bilateral), <i>absent anterior calcaneal facet</i> (bilateral), lateral talar extension (left).   |          |          |          |          |          |          |          |                |          |          |          |          |          |          |          |
| Pathology         | Schmorl's nodes in thoracic spine. DJD in the cervical, thoracic, lumbar and sacral spine, the left mandible both sides of the manubrium, the left and right medial clavicle, the right scapula, the left distal radius, and ulna, both acetabulum and auricular surfaces, the right proximal femur, both distal femurs, the distal articulation of the right first metatarsal, and the distal articulations of the right fourth and fifth metatarsals, and the proximal articulation of the proximal phalanx for the left 1 <sup>st</sup> metatarsal. Fusion of the xiphoid to the base of the sternum. Border shifting in the vertebral column- the 1 <sup>st</sup> coccygeal vertebrae was fused to the base of the sacrum, fused along the anterior and posterior surface of the body and appears well remodelled, the cornu were still visible, neither of which had fused to the sacral neural arch of the fifth sacral vertebra. Crush fractures in the individual's spine affected the third to seventh thoracic vertebrae, possibly resulting in the osteophyte formation. A healed fracture to the distal shaft of the left ulna, the callus was generally smooth and well remodelled on the anterior, lateral and posterior surfaces, while bone formation along the interosseous border was more irregular and rugged in appearance. The fracture appears to have been oblique, but with good apposition of the two fragments. Retroversion of the shoulder joints; both glenoids are angled slightly posteriorly; the right is also affected by moderate osteophytic lipping. The individual also has very short clavicles. OD on the right cuneiform on the superior surface of the distal articulation. The right distal articulations of the second and third metatarsals appear to missing the medial extensions to their plantar articular surfaces. Bilateral calcaneus secundaris, both the anterior margins of the calcaneus are rugged with smooth specular appearance. |          |          |          |          |          |          |          |                |          |          |          |          |          |          |          |
| Dental Health     | 13/16 teeth present, 16/32 tooth positions present 1/16 lost post mortem, 2/16 tooth positions NP, DEH affects 2/16 teeth, calculus on 13/16 teeth flecks to medium deposits. Moderate periodontal disease on the mandible.   |          |          |          |          |          |          |          |                |          |          |          |          |          |          |          |
|                   | Right Dentition   |          |          |          |          |          |          |          | Left Dentition |          |          |          |          |          |          |          |
| Present           | -   | -        | -        | -        | -        | -        | -        | -        | -              | -        | -        | -        | -        | -        | -        | -        |
| Calculus          | -   | -        | -        | -        | -        | -        | -        | -        | -              | -        | -        | -        | -        | -        | -        | -        |
| DEH               | -   | -        | -        | -        | -        | -        | -        | -        | -              | -        | -        | -        | -        | -        | -        | -        |
| Caries            | -   | -        | -        | -        | -        | -        | -        | -        | -              | -        | -        | -        | -        | -        | -        | -        |
| Wear              | -   | -        | -        | -        | -        | -        | -        | -        | -              | -        | -        | -        | -        | -        | -        | -        |
| Maxilla           | <b>8</b>  | <b>7</b> | <b>6</b> | <b>5</b> | <b>4</b> | <b>3</b> | <b>2</b> | <b>1</b> | <b>1</b>       | <b>2</b> | <b>3</b> | <b>4</b> | <b>5</b> | <b>6</b> | <b>7</b> | <b>8</b> |
| Mandible          | <b>8</b>  | <b>7</b> | <b>6</b> | <b>5</b> | <b>4</b> | <b>3</b> | <b>2</b> | <b>1</b> | <b>1</b>       | <b>2</b> | <b>3</b> | <b>4</b> | <b>5</b> | <b>6</b> | <b>7</b> | <b>8</b> |
| Present           | NP  | P        | P        | P        | P        | P        | P        | PM       | P              | P        | P        | P        | P        | P        | P        | NP       |
| Calculus          | -   | Sb<br>Ml | Mbl      | Fb       | Sb<br>Fl | Mb<br>Sl | Mb<br>Sl | -        | Fbl            | Fb<br>Ml | Sbl      | Fb<br>Ml | Ml       | Sb<br>Sl | Fm<br>Fl | -        |
| DEH               | -   | -        | -        | -        | -        | G        | -        | -        | -              | -        | P        | -        | -        | -        | -        | -        |
| Caries            | -   | -        | -        | -        | -        | -        | -        | -        | -              | -        | -        | -        | -        | -        | -        | -        |
| Wear              | -   | 6        | 7        | 5        | 5        | 5        | 5        | -        | 5              | 5        | 5        | 5        | 5        | 7        | 5        | -        |

|                        |                   |
|------------------------|-------------------|
| <b>Skeleton Number</b> | <b>14071</b>      |
| Preservation           | Very good         |
| Completeness           | 90%               |
| Age                    | 46+, mature adult |
| Sex                    | Male              |
| Stature                | 172.9 +/- 2.99    |

|                   |                 |  |          |          |          |          |          |          |                |          |          |          |          |          |          |          |
|-------------------|-----------------|--|----------|----------|----------|----------|----------|----------|----------------|----------|----------|----------|----------|----------|----------|----------|
| Non-Metric Traits |                 | <i>Ossicle in coronal suture (right), mastoid foramen extrasutural (bilateral), posterior condylar canal open (bilateral), double anterior condylar canal (right), bridging of supraorbital notch (bilateral), accessory supraorbital foramen (bilateral), transverse foramen bipartite (left), acetabular crease (left), Allen's fossa (left), medial tibial squatting facet (bilateral).</i>   |          |          |          |          |          |          |                |          |          |          |          |          |          |          |
| Pathology         |                 | Schmorl's nodes in thoracic spine. DJD in the thoracic spine, the medial right clavicle, the left proximal humerus, left and right distal radii, proximal right ulna, the left and right acetabulum, and the distal end of the proximal phalanx for MC2. OA in the left temporomandibular joint. Bifid spinous process on S1. A healed fracture to distal right radius. Border shift at thoracic lumbar border. Muscle excavations on left and right clavicle at insertion of costo-clavicular ligament. Ossified haematoma on left tibia. |          |          |          |          |          |          |                |          |          |          |          |          |          |          |
| Dental Health     |                 | 27 teeth present, 32/32 tooth positions present 1/32 lost post mortem, 32/32 tooth positions NP, 1/32 lost AM, DEH affects 6/27 teeth, calculus on 26/27 teeth flecks to medium deposits. Moderate periodontal disease on the mandible. and maxilla  |          |          |          |          |          |          |                |          |          |          |          |          |          |          |
|                   | Right Dentition |  |          |          |          |          |          |          | Left Dentition |          |          |          |          |          |          |          |
| Present           | P               | P  | P        | AM       | P        | P        | PM       | P        | P              | P        | P        | P        | P        | P        | P        | NP       |
| Calculus          | Mbd             | Fbd  | -        | -        | Fb       | Fb       | -        | Fb       | Fb             | Fb       | Fb       | Sb       | Sb       | Fb       | sbl      | -        |
| DEH               | -               | -  | -        | -        | -        | -        | -        | -        | -              | -        | -        | -        | -        | -        | -        | -        |
| Caries            | -               | So   | Lo       | -        | -        | -        | -        | -        | -              | -        | -        | -        | -        | Mm       | -        | -        |
| Wear              | 2               | 2  | -        | -        | 4        | 5        | -        | 7        | 7              | 5        | 4        | 3        | 3        | 5        | 3        | -        |
| Maxilla           | <b>8</b>        | <b>7</b>   | <b>6</b> | <b>5</b> | <b>4</b> | <b>3</b> | <b>2</b> | <b>1</b> | <b>1</b>       | <b>2</b> | <b>3</b> | <b>4</b> | <b>5</b> | <b>6</b> | <b>7</b> | <b>8</b> |
| Mandible          | <b>8</b>        | <b>7</b>   | <b>6</b> | <b>5</b> | <b>4</b> | <b>3</b> | <b>2</b> | <b>1</b> | <b>1</b>       | <b>2</b> | <b>3</b> | <b>4</b> | <b>5</b> | <b>6</b> | <b>7</b> | <b>8</b> |
| Present           | NP              | P  | P        | P        | P        | P        | P        | P        | P              | P        | P        | P        | P        | P        | P        | NP       |
| Calculus          | -               | Sb<br>Ml   | Sb<br>Ml | Fb<br>Ml | Fbl      | Sl       | Sl       | Sl       | Sl             | Ml       | Sl       | Sbl      | Sl       | Sb<br>Ml | Sbl      | -        |
| DEH               | -               | -  | -        | -        | -        | G        | G        | G        | G              | G        | G        | -        | -        | -        | -        | -        |
| Caries            | -               | -  | Mm       | -        | -        | -        | -        | -        | -              | -        | -        | -        | -        | -        | -        | -        |
| Wear              | -               | 3  | 4        | 3        | 3        | 3        | 3        | 5        | 5              | 4        | 3        | 3        | 3        | 4        | 3        | -        |

**KEY:**

Present - Tooth presence; am - ante-mortem tooth loss; pm - post-mortem tooth loss; p - tooth present; - - jaw not present

Caries - Calculus; F - flecks of calculus; S - slight calculus; M - moderate calculus; H - heavy calculus; a - all surfaces; b - buccal surface; d - distal surface; m - mesial surface; l - lingual surface; o - occlusal surface

DEH - dental enamel hypoplasia; l - lines; g - grooves; p - pits

Caries - caries; s - small lesions; m - moderate lesions; l - large lesions

Wear - dental wear; numbers from 1-8 - slight to severe wear