



**YORK ARCHAEOLOGICAL TRUST**



**THE MEDIEVAL CEMETERY OF ST LEONARD'S  
LEPER HOSPITAL AT MIDLAND ROAD,  
PETERBOROUGH**

By J.M. McComish, G. Millward and A. Boyle

*WEB PUBLICATION*

Report Number YAT 11/2017



# YORK ARCHAEOLOGICAL TRUST



York Archaeological Trust undertakes a wide range of urban and rural archaeological consultancies, surveys, evaluations, assessments and excavations for commercial, academic and charitable clients. We manage projects, provide professional advice and fieldwork to ensure a high quality, cost effective archaeological and heritage service. Our staff have a considerable depth and variety of professional experience and an international reputation for research, development and maximising the public, educational and commercial benefits of archaeology. Based in York, Sheffield, Nottingham and Glasgow the Trust's services are available throughout Britain and beyond.

**York Archaeological Trust, Cuthbert Morrell House, 47 Adware, York YO1 7BX**

Phone: +44 (0)1904 663000 Fax: +44 (0)1904 663024

Email: [archaeology@yorkat.co.uk](mailto:archaeology@yorkat.co.uk) Website: <http://www.yorkarchaeology.co.uk>

## CONTENTS

<b>SUMMARY.....</b>	<b>VI</b>
<b>COPYRIGHT DECLARATION: .....</b>	<b>VI</b>
<b>1 INTRODUCTION .....</b>	<b>7</b>
<b>2 METHODOLOGY.....</b>	<b>7</b>
<b>3 LOCATION, GEOLOGY &amp; TOPOGRAPHY .....</b>	<b>8</b>
<b>4 HISTORICAL BACKGROUND OF ST LEONARD’S HOSPITAL.....</b>	<b>8</b>
<b>5 LEPROSY .....</b>	<b>10</b>
5.1 The spread of leprosy .....	10
5.2 Diagnosis and treatment of the disease in the medieval period.....	12
5.3 Medieval attitudes to leprosy.....	12
5.4 Leper hospitals in England .....	15
5.5 The burial of lepers .....	17
<b>6 A SUMMARY OF THE SEQUENCE OF DEPOSITS AT THE MIDLAND ROAD SITE.....</b>	<b>20</b>
<b>7 THE CEMETERY .....</b>	<b>21</b>
7.1 The date of the cemetery .....	21
7.2 Phases of use within the cemetery.....	21
7.3 Phase 1.....	22
7.4 Phase 2.....	24
7.5 Burial practice .....	25
<b>8 THE HUMAN BONES.....</b>	<b>44</b>
8.1 Introduction .....	44
8.2 Osteological analysis.....	45
8.3 Pathological analysis.....	68
8.4 Dental Health .....	118
<b>9 DISCUSSION AND CONCLUSION .....</b>	<b>123</b>
9.1 The layout of the burial ground in Phases 1 and 2 .....	123
9.2 Burial practices in Phase 1 and 2 .....	126
9.3 The population at Midland Road .....	130
<b>10 FUTURE WORK.....</b>	<b>135</b>
<b>PUBLISHED REFERENCES .....</b>	<b>137</b>
<b>WEB-BASED REFERENCES .....</b>	<b>144</b>

<b>UNPUBLISHED SOURCES.....</b>	<b>146</b>
<b>ACKNOWLEDGEMENTS .....</b>	<b>146</b>
<b>APPENDIX 1 – SKELETON CATALOGUE AND DISARTICULATED DEPOSITS .....</b>	<b>147</b>
Introduction .....	147
Appendix 1a - Skeleton Catalogue .....	147
Appendix 1b - Disarticulated human bone .....	251
<b>APPENDIX 2 – CARBON 14 DATING .....</b>	<b>253</b>
<b>APPENDIX 3 – CONSERVATION OF THE LACE TAGS .....</b>	<b>266</b>
<b>APPENDIX 4 – ANALYSIS OF FIBRES FROM THE LACE TAGS .....</b>	<b>281</b>
<b>FIGURES .....</b>	<b>287</b>

### Figures

Figure 1: Site location.....	287
Figure 2: Skeleton numbers .....	288
Figure 3: Dating evidence.....	289
Figure 4: The Phase 1 burials and burial rows .....	290
Figure 5: The Phase 2 burials and burial rows .....	291
Figure 6: Orientation of burials.....	292
Figure 7: Burial leg positions .....	293
Figure 8: Burial arm positions .....	294
Figure 9: Iron nails and the evidence for coffins and shrouds.....	295
Figure 10: The locations of the males, females and children .....	296
Figure 11: The locations of burials exhibiting leprosy .....	297
Figure 12: The locations of burials exhibiting signs of trauma and injury .....	298

### Plates

Cover: General view of the archaeological excavation at Midland Road, Peterborough	
Plate 1: Skeletons 82-83, with a detail of their overlapping hands. ....	26
Plate 2: Skeleton 40. ....	27
Plate 3: Skeletons 6, 18 and 31. ....	28
Plate 4: Skeletons 43, 75 and 84 .....	28
Plate 5: Skeletons 10, 60 and 63. ....	29
Plate 6: Skeletons 54 and 73. ....	29
Plate 7: Arm Position 1 Skeleton 16 and Position 2 Skeleton 76. ....	31
Plate 8: Arm Position 3 Skeleton 9 and Position 5 Skeleton 60. ....	31
Plate 9: Skeletons 7, 12 and 15 .....	33
Plate 10: Skeletons 16, 17 and 23 .....	33
Plate 11: Skeletons 42, 44 and 45 .....	34
Plate 12: Skeletons 51, 71 and 72 .....	34
Plate 13: Skeletons 76, 78 and 80 .....	35

Plate 14: Skeletons 88, 93 and 94 .....	35
Plate 15: Skeletons 120, 124 and 127 .....	36
Plate 16: Skeletons 132 and 144 .....	36
Plate 17: Skeletons 9, 14 and 69 .....	37
Plate 18: Skeletons 74, 79 and 81 .....	37
Plate 19: Skeletons 97, 104 and 139/140 .....	38
Plate 20: Skeletons 32, 34 and 67 .....	38
Plate 21: Skeleton 137 and 59 .....	39
Plate 22: Extract from the original context card o Skeleton 93 showing the position of the lace tags (labelled as shroud pins) .....	40
Plate 23: Skeleton 74, anterior view of poorly healed fracture of surgical neck of right humerus .....	71
Plate 24: Skeleton 74, anterior view of right scapula .....	71
Plate 25: Skeleton 141, anterior view of poorly healed fracture of left femoral neck .....	72
Plate 26: Skeleton 42, lateral view of TV10-12 .....	73
Plate 27: Skeleton 16, rhino maxillary change .....	87
Plate 28: Skeleton 16, abnormal porosity of the palate .....	87
Plate 29: Skeleton 18, new bone deposition on left fibula shaft .....	88
Plate 30: Skeleton 18, destruction of right proximal foot phalanx 2 .....	88
Plate 31: Skeleton 69, rhino-maxillary changes .....	89
Plate 32: Skeleton 80, new woven bone deposition on left fibula .....	90
Plate 33: Skeleton 84, chronic ulcer on tibia .....	90
Plate 34: Skeleton 43, left proximal foot phalanges, plantar view .....	94
Plate 35: Skeleton 76, blade-like remodelling of the left 5th metatarsal .....	97
Plate 36: Skeleton 136, destruction of distal articulation of right 1st metatarsal .....	97
Plate 37: Skeleton 18, lesions on endocranial surface of occipital .....	117
Plate 38: SEMicrographs of samples 1, 6, 11, 12, 21, 23, 24, 26 at the lowest magnification showing the cylindrical shape of the fragments (Images: Margarita Gleba) .....	283
Plate 39: SEMicrograph of sample 24 showing a cross section (Image: Margarita Gleba) ..	284
Plate 40: SEMicrographs of samples 1, 11, 12, 21, 23, 26 showing the interlaced fibrous internal structure of the fragments (Images: Margarita Gleba) .....	284
Plate 41: SEMicrographs of samples 1, 11, 12, 23, showing globular structures .....	285
Plate 42: SEMicrographs of samples 6, 23, showing smooth surface .....	285
Plate 43: SEMicrographs of sample 11 showing dark discoid structures with multiple perforations (Image: Margarita Gleba) .....	286
Plate 44: Fibre structure of leather .....	286

## Tables

Table 1: Summary of the Carbon 14 dates for the site .....	22
Table 2: Summary of osteological and palaeopathological data .....	57
Table 3: Scoring criteria for Skeletal condition (surface preservation) (after McKinley 2004, 16) .....	58
Table 4: Surface preservation expressed as a percentage .....	59
Table 5: Fragmentation expressed as a percentage .....	59

Table 6: Completeness .....	60
Table 7: Sex distribution of the adults .....	61
Table 8: Combined adult age and sex distribution, Phase 1 .....	62
Table 9: Combined adult age and sex distribution, Phase 2 .....	62
Table 10: Combined adult age and sex distribution, both phases.....	63
Table 11: Stature .....	64
Table 12: Meric index - range and mean, Phase 1 .....	64
Table 13: Meric index - number of femora in each category, Phase 1 .....	65
Table 14: Meric index - range and mean, Phase 2 .....	65
Table 15: Metric index - number of femora in each category, Phase 2.....	65
Table 16: Cnemic index - range and mean, Phase 1 .....	65
Table 17: Cnemic index - number of tibiae in each category, Phase 1 .....	66
Table 18: Cnemic index - range and mean, Phase 2 .....	66
Table 19: Cnemic index - number of tibiae in each category, Phase 2 .....	66
Table 20: Midline cranial non-metric traits (adults) .....	67
Table 21: Paired cranial traits (adults) .....	67
Table 22: Paired post-cranial traits (adults).....	68
Table 23: Prevalence of cribra orbitalia, Phase 1.....	69
Table 24: Prevalence of cribra orbitalia, Phase 2.....	69
Table 25: Prevalence of maxillary sinusitis in adults (sinuses and individuals), Phase 1 .....	75
Table 26: Prevalence of maxillary sinusitis in adults (sinuses and individuals), Phase 2 .....	75
Table 27: Diagnostic criteria for leprosy in Skeletal remains (after Lee and Manchester 2008; Ortner 2008).....	80
Table 28: Summary of the potential evidence for leprosy, Phase 1 .....	86
Table 29: Summary of the potential evidence for leprosy, Phase 2 .....	99
Table 30: Synthesis of the Skeletons diagnosed with leprosy, both phases.....	103
Table 31: Prevalence of degenerative joint disease in the extra-spinal joints (joints affected), Phase 1 .....	106
Table 32: Prevalence of joint disease in the extra-spinal joints (joints affected), Phase 2..	108
Table 33: Prevalence of osteoarthritis in the extra-spinal joints (joints affected), Phase 1	110
Table 34: Prevalence of osteoarthritis in the extra-spinal joints (joints affected), Phase 2	112
Table 35: Prevalence of spondylosis deformans, Phase 1 .....	113
Table 36: Prevalence of spondylosis deformans, Phase 2 .....	113
Table 37: Prevalence of joint disease of the vertebral articulations, Phase 1 .....	114
Table 38: Prevalence of joint disease of the vertebral articulations, Phase 2.....	114
Table 39: Prevalence of osteoarthritis in the spine, Phase 1.....	115
Table 40: Prevalence of osteoarthritis in the spine, Phase 2.....	115
Table 41: Prevalence of Schmorl's nodes, Phase 1 .....	115
Table 42: Prevalence of Schmorl's nodes, Phase 2 .....	116
Table 43: Dental health in the non-adults .....	119
Table 44: Dental calculus (teeth affected) .....	120
Table 45: Dental caries (permanent teeth).....	120
Table 46: Dental abscess (tooth positions).....	120
Table 47: Teeth lost ante-mortem (tooth positions affected).....	121
Table 48: Teeth with dental enamel hypoplasia.....	121

Table 49: Enamel chipping .....	121
---------------------------------	-----

### **Graphs**

Graph 1: Surface preservation .....	58
Graph 2: Fragmentation.....	59
Graph 3: Completeness expressed as a percentage .....	60
Graph 4: Sex distribution of the adults .....	61
Graph 5: Adult male and female age distribution.....	63

### **Abbreviations**

Sf = Small find number

CPR = Crude prevalence rate

TPR = Total prevalence rate

While the cardinal points of the compass are written in full (e.g. north-east), for brevity the various sub-divisions of the compass have been abbreviated to NE, ENE and NbE (north by east).

For ease of reference all graves are referred to by the number of the Skeleton they contained, rather than by the context number of the grave cut. The Skeleton number is in the form Sk 1, Sk 2 etc.

## SUMMARY

This report relates to the excavation of a medieval and post-medieval cemetery at Midland Road, Peterborough. The excavation and the initial post-excavation work were undertaken by Archaeology Services Durham University, resulting in an evaluation report (Dye and Jenkins 2014) and an excavation assessment report (Swann 2015).

The present report was prepared by staff of York Archaeological Trust and it represents a full post-excavation report relating to the cemetery together with a detailed analysis of the Skeletal remains prepared by A. Boyle.

### **COPYRIGHT DECLARATION:**

York Archaeological Trust give permission for the material presented within this report to be used by the archives/repository with which it is deposited, in perpetuity, although York Archaeological Trust retains the right to be identified as the author of all project documentation and reports, as specified in the Copyright, Designs and Patents Act 1988 (chapter IV, section 79). The permission will allow the repository to reproduce material, including for use by third parties, with the copyright owner suitably acknowledged.

### **Disclaimer:**

This document has been prepared for the commissioning body and titled project (or named part thereof) and should not be relied upon or used for any other project without an independent check being carried out as to its suitability and prior written authority of the author being obtained. York Archaeological Trust accepts no responsibility or liability for the consequences of this document being used for a purpose other than that for which it was commissioned.



## 1 INTRODUCTION

by J.M. McComish

This report relates to a medieval and post-medieval cemetery at Midland Road, Peterborough, Cambridgeshire (NGR TL 18399 99053, Figure 1). The cemetery was originally associated with the medieval leper hospital of St Leonard which was founded by 1125. This site is of national importance, as relatively few cemeteries relating to leper hospitals have been excavated.

Initially, seven evaluation trenches were excavated, four of which yielded possible graves. The evaluation led to an archaeological excavation designed to recover all the human remains at the site (Figure 2). Both the evaluation and excavation were undertaken by Archaeological Services, Durham University, with the evaluation and excavation being supervised by N. Thomas and N. Swann respectively. The report for the evaluation was prepared by Dye and Jenkins (2014) while the excavation was reported on by Swann (2015). The present publication report was prepared by staff of York Archaeological Trust and A. Boyle.

## 2 METHODOLOGY

by J.M. McComish

The initial excavations comprised seven evaluation trenches excavated between 7<sup>th</sup>-10<sup>th</sup> July 2014 (Dye and Jenkins 2014, 2). Trenches 1, 2 and 7 were 15m x 2m in size, while Trenches 3, 4 and 5 were 15m x 2m in size, Trench 6 was 15m x 1.5m in size and Trench 8 was 11m x 6m in size, and the trenches ranged from 0.2-1.2m in depth (ibid., 4-5). Features identified as probable graves for inhumation burials were identified in Trenches 1-2 and 6-7, and it was clear from their layout that the possible graves formed part of a larger cemetery. Trenches 3-5 did not contain any features identified as possible graves, indicating that the burials were concentrated in the south-western portion of the site. None of the possible graves were fully excavated during the evaluation, but rather they were covered over and the trenches infilled, in advance of full excavation (ibid., 4).

The main archaeological excavations were undertaken between 4<sup>th</sup> August and 3<sup>rd</sup> October 2014. A trench 20m x 21m in size was excavated, and this was extended on all sides until the limits of the cemetery had been reached. The original site archive and report were recorded in relation to the Archaeological Services Durham University project code PMR14. A total of 144 Skeleton numbers were allocated to human remains during the course of the excavation, though some of these numbers related to charnel deposits rather than interments. The initial post-excavation assessment was completed by 2015.

The artefacts from the site comprised a fossil, 58 residual Mesolithic flints, four fire cracked flints, 50 sherds of pottery ranging from 11<sup>th</sup> to mid-12<sup>th</sup> century in date, a small number of animal bone and shell fragments which were recovered from samples of the grave fills, five fragments of iron nails, 19 copper alloy lace tags of 15<sup>th</sup>-17<sup>th</sup> century date, an undatable copper alloy object interpreted as a possible washer, a small fragment of a copper alloy sheet, a small sliver of glass which was of post-medieval date at the earliest, 20g of industrial

residues and a bone button of 18<sup>th</sup>-19<sup>th</sup> century date. The artefacts are reported on in Swann (2015, 6-11), and the results are not repeated here. The only further work undertaken on the artefacts in 2016 was conservation and consolidation of the lace tags, and the analysis of fibres found inside the lace tags.

The present report was prepared in 2016-7, with J.M. McComish and G. Millward of York Archaeological Trust writing the text relating to the excavated remains, while A. Boyle analysed and reported on the Skeletal remains. The figures were prepared by G. Millward and B. Savine (York Archaeological Trust). The records relating to this work are stored under the York Archaeological Trust Project Code 5870.

### **3 LOCATION, GEOLOGY & TOPOGRAPHY**

by J.M. McComish

The site at Midland Road was located within a polygonal plot of land, 491 square metres in size, which had formerly been used as the GB Oils site. At the time of evaluation the site was bordered by Midland Road to the west, to the north and south by commercial premises and to the north-east by a railway siding (Dye and Jenkins 2014, 2). By the time of the excavation the area to the south of the site had been redeveloped for housing (Swann 2015, 2).

The underlying solid geology of the site is Cornbush Formation Limestone (British Geological Survey website), and no superficial deposits are recorded for the site. The ground is at approximately 12m AOD, sloping very slightly downwards to the north-east.

### **4 HISTORICAL BACKGROUND OF ST LEONARD'S HOSPITAL**

by J.M. McComish

In the interest of brevity, this section refers only to the medieval history of Peterborough with particular reference to the hospital of St Leonard's. Readers wishing for further information on the prehistoric, Roman and modern land use in the area, or information on previous archaeological interventions in the vicinity should consult MacQueen (2012), Dye and Jenkins (2014) and Swann (2015).

During the medieval period the history of Peterborough was heavily influenced by the presence of the important monastery of St Peter at Medeshamstede (now the cathedral), which was founded by Saxulf on land donated by Peada of Mercia (VCH 1906, 83-95). The monastery was destroyed by the Danes in 870, and was restored almost a century later by King Edgar (*ibid.*, 83-95), with the king making generous land donations to the abbey in AD 963 (Garmonsway 1978, 115). This donation probably included the Midland Road site. Abbot Kenulf (992-1005) surrounded the monastic precinct with a wall, which resulted in the name of the abbey changing to Burgh, which later became Goldenburgh, then Peterburgh (VCH 1906, 83-95).

The Domesday book of 1086 listed 52 households in Peterborough and noted that the abbey of St Peter was both lord of the manor and tenant-in-chief in 1086, as it had been in 1066 (Open Domesday website).

The leper hospital of St Leonard, Peterborough, was supported by Peterborough Abbey, and because of this the residents of St Leonard's followed a monastic rule from the outset (Tebbs 1979, 109; Rawcliffe 2006, 131). The first mention of the hospital is in 1125, when there were thirteen lepers and three servants resident (VCH 1906, 162). None of the buildings of this hospital survive, but it is thought to have been located to the west of Westgate, its presence being indicated by the later place names Spital Field, Spital Close, St Leonard's Street and Spital Pond (HER record 01629). The present day Spital Bridge, which is located 220m to the north-west of the present site, also reflects the presence of the hospital (ibid.). A well in the same general area as the hospital was known as St Leonard's Well and this was thought to have medicinal properties (VCH 1906, 162).

The hospital is mentioned again in 1147 when a Northamptonshire landowner Robert de Torpel who was 'infirm and afflicted with leprosy', settled two manors at Cottestock and Glaphorn on Peterborough Abbey in a ceremony in the chapel of St Leonard's Hospital; in return the chapter agreed to support him and four knights for life and to clothe him after death in the Benedictine habit (VCH 1906, 162; Rawcliffe 2006, 131). In 1167 the Court Leet decreed that the leper John Tendale should be removed to a solitary place, this could imply that St Leonard's was full at that time (Tebbs 1979, 110).

William of Woodford, who was abbot of Peterborough from 1295-9, made special provisions for St Leonard's, with a yearly donation of forty ells of cloth to be given at the feast of St Martin, together with a stone of ointment and stone of tallow, while three bacon pigs were to be given one each at Christmas, before Lent and at Easter (VCH 1906, 162). At this time there was an annual payment of a penny on St Peter's Day to the brethren of the hospital (ibid., 162). The monk in charge of the lepers had the right to dine with the abbot of Peterborough's household at Christmas, Easter and on the feasts of St Peter and All Saints (ibid., 162). In 1296 the leper hospital was taxed at £6 but did not pay tithes (ibid., 162).

The tax return of 1535 indicated that eight poor men were living at the hospital, each of whom received 40s a year, and that these men offered daily prayers for the souls of the founders (ibid., 162). Clearly by this stage the function of the hospital had changed to that of a general hospital/almshouse. At the dissolution in 1539 Peterborough Abbey became the cathedral of the city, with the last Abbot John Chambers being made the first bishop, while the prior of the abbey became the dean of the cathedral (Tebbs 1979, 67). It is unclear how the change in status from abbey to cathedral affected the dependant hospital of St Leonard's.

Plague was endemic in England from the time of the Black Death in 1348, and Peterborough saw renewed outbreaks of plague in 1348, 1361, 1399, 1506-7, 1574, 1625 and 1665-67 when 460 people died in the city (ibid., 103). The 1665-7 outbreak was the last recorded provincial outbreak of the disease (Creighton 1894, 34). Most of the victims of the final bout of plague were buried near the Pest House, but some were buried in parish cemeteries or even their own gardens. Although the precise location of the pest house is unclear it was located near Westgate (Tebbs 1979, 103) which may suggest that the former leper hospital had become the pest house by that date. St Leonard's Well is last documented c. 1666 (Pastscape website).

Historic maps of Peterborough such as Robert Creighton's map of 1835 indicate that the area of the former hospital was open land. It remained as such until it was developed for an Oil and Petrol depot in 1926 (Swann 2015, 40).

## 5 LEPROSY

by J.M. McComish

Leprosy has been known since antiquity, and the disease has been associated with fear and stigma from the outset, with sufferers often being cast out from society. Covey (2001, 316) states "Perhaps no other human [the leper], since the periodic outbreaks of plague and the rise of the HIV epidemic, has provoked stronger social responses". The disease of leprosy is caused by infection by the bacteria *Mycobacterium leprae*. Leprosy is also known as Hansen's Disease in honour of G. Armauer Hansen who first identified the causative organism in 1873 (Demaitre 2007, Intro.). The alternative name of Hansen's Disease is often specifically used to remove the stigma associated with the word leprosy.

The World Health Organisation (www.WHO Fact Sheet 101) describes leprosy in the following terms. *M. leprae* multiplies slowly, resulting in a long incubation period for the disease, which is typically 5 years, but can be up to 20 years. Leprosy is transmitted via droplets from the nose and mouth during frequent and close contact (ibid.). There are currently about 180,000 cases of the disease worldwide, mainly in Africa, India and Asia, but the disease can be cured by modern medicine (ibid.). Left untreated leprosy can cause blindness, loss of nerve sensation, local paralysis, Skin damage and the withering of certain parts of the body, resulting in deformed feet and hands (Covey 2001, 315).

It is now known that the Incubation period for leprosy can be shorter, with between 2-4 years before manifest symptoms, and cases as quick as 3 months have been noted (Magilton et al. 2008, 2080). The disease is not very contagious, with only about 10% of people who are exposed to the disease succumbing (Covey 2001, 315). There may also be a genetic factor, with around 5% of the population being susceptible to catching the disease, but even among those who catch the disease some spontaneously recover depending upon the response of the immune system (Demaitre 2007, Intro.). Poor nutrition, ill health and pregnancy may have a worsening effect due to the depression of cell mediated immunity (Magilton et al. 2008, 208).

### 5.1 The spread of leprosy

Leprosy has plagued humanity for a considerable time. The earliest documentary reference to leprosy is an Egyptian papyrus dating to c. 1500 BC, and it has been suggested that the disease is mentioned in the SanSkrit hymns of Atahrva Veda dating to the 1<sup>st</sup> millennium BC, while within the Bible there are around fifty references to the disease (Robbins et al. 2009; Covey 2001, 316). There are, however, problems with all of these texts as it is unclear whether the diseases being described really were leprosy or some other medical condition causing disfigurement. The first definite references to the disease occur in 6<sup>th</sup> century BC texts from South Asia, in 1<sup>st</sup> century works by Celsus and Pliny the Elder, and in a 3<sup>rd</sup> century Chinese text the Shuihudi Qin Jia (Robbins et al. 2009).

A Skeleton from Balathal, India, dating to c. 2000 BC has been identified as leprous (*ibid.*), while a 4th-3rd century BC example is known from a Celtic cemetery at Casalecchio di Reno, Bologna (Mariotti et al. 2005, 311-325). The earliest Skeletal evidence for the disease in Britain is from Roman Cirencester and from a fourth century Romano-British cemetery at Poundbury, Dorchester (Magilton et al. 2008, 9).

Leprosy continued to affect the population of Britain throughout the early medieval period. A 5<sup>th</sup>-6<sup>th</sup> century burial of a leprous male aged around 21-35 years old was found at Great Chesterford, Essex (InSkip et al. 2015), while a possible 6<sup>th</sup> century example is known from Beckford, Gloucestershire (Magilton et al. 2008, 9). Leprosy was present on 7<sup>th</sup> century Skeletons from Eccles, Kent (Manchester 1981, 205-9), Burwell, Cambridgeshire and Edix Hill, Cambridgeshire (Magilton et al. 2008, 9). A 7-8<sup>th</sup> century example is known from Tean on Scilly (*ibid.*, 9). Three further Anglo-Saxon burials with leprosy are known from Cannington in Somerset (*ibid.*, 9), while at Wharram Percy, North Yorkshire, a juvenile dated to AD 960-1000 had leprosy (Roberts 2011, 264). A Saxo-Norman group of burials at Timberhill, Norwich included a possible 35 lepers out of the 180 excavated burials (Magilton et al. 2008, 9).

The first written records of the disease in Britain date to the 10<sup>th</sup> century (Magilton et al. 2008, 9). The spread of leprosy throughout Europe accelerated after this time, but in the case of England it was not until after the Norman Conquest that institutional provision was made for sufferers of the disease (Rawcliffe 2006, 1). By the 12<sup>th</sup> century leprosy was endemic in Europe (Magilton et al. 2008, 10). It has been suggested that leprosy peaked in Europe the 12<sup>th</sup> and 13<sup>th</sup> centuries, largely on the basis of the foundation of leper hospitals (Covey 2001, 317), but other authors state that the disease peaked in the 13-14<sup>th</sup> centuries (Demaitre 2007, Intro.). Leprosy was present throughout the British isles in the later medieval period, as evidenced by a leprous Skeleton at Newark Bay, Orkney dating to the 13<sup>th</sup>-14<sup>th</sup> (Taylor et al. 2000, 1133).

The disease slowly retreated from Europe from the later medieval period onwards. In the case of England there was a decrease in the incidence of the disease from the 14<sup>th</sup> century onwards (Roberts 2011, 264). For example, the leper house of St Mary Magdalene, Ripon, was empty in 1341 (Cullum 1991, 4). It is unclear why the disease retreated, with scholars citing a variety of possible reasons including improved sanitation, acquired immunity, cold weather, and the spread of pulmonary tuberculosis, with the tuberculosis outcompeting leprosy (Covey 2001, 320). It has also been suggested that as lepers had compromised immune systems they would have been especially susceptible to the Black Death (*ibid.*, 320). This can be illustrated by the leper house of St James, Winchester, where all but one of the brothers and sisters died of plague (Magilton et al. 2008, 590).

Just two sites in Britain have produced evidence of leprosy in the period AD 1550-1850: the churchyards of St Augustine the less in Bristol, Avon, and St Marylebone Church in London (Roberts 2011, 265). By the 19<sup>th</sup> century most of Europe was free from leprosy, but there were a few pockets of leprosy left in Scandinavia, Greece, the Iberian Peninsula and the Balkans (Rawcliffe 2006, 1).

## 5.2 Diagnosis and treatment of the disease in the medieval period

Priests initially played a leading role in initiating and conducting examinations of potential lepers, but from the first half of the 14<sup>th</sup> century it was increasingly learned physicians that performed this task (Demaitre 2007, 35). Examiners would look at the Skin, blood, urine, faeces and overall appearance of a person to determine if leprosy was present.

In the period ad 1000–1500 definitions of leprosy varied dramatically and the disease was often a ‘catch-all’ for a wide range of Skin conditions (Roffey 2012, 204). During this period reliable diagnoses and accurate descriptions of the disease were rare, with physicians frequently misdiagnosing the disease and confusing it with other conditions (Covey 2001, 316). Steane (1985, 98) noted that it would be possible to confuse leprosy with impetigo, scrofula, lupus, tuberculosis, erysipelas, St Anthony’s fire and even venereal disease, while Covey (2001, 316) notes that Skin ailments such as fungi, eczema, pellagra, ringworm, and psoriasis could also have borne a resemblance to the changes seen on leprosy Skin. In reality anything that looked like leprosy could be diagnosed as leprosy and any such misdiagnosis had profound consequences for the individual concerned. Cases of misdiagnosis are known from medieval documents (Magilton et al. 2008, 10).

There were three principal medical treatises discussing leprosy available in the medieval period, the first of these was the works of Galen of Pergamum (AD 129-200), though these are somewhat confusing as Galen refers to both elephantia and leprosy interchangeably (Demaitre 2007, 16-17). The second major source was the *Qanun* or Canon of medicine written by Ibn Sina (also known as Avicenna) who lived AD 980-1037, this was translated into Latin by Gerard of Cremona c. 1114-87 (ibid., 20). Finally there was Bernard of Gordon’s *Lilium Medicine* written in 1305 (ibid., 16-17). In the case of Bernard of Gordon half his chapter on leprosy refers to diagnosis and a third to treatment, so it is clear that medicine did not just give up on the afflicted (ibid., 20). Treatments are known to have included herbal remedies, laxatives, purgatives, bathing at specific sites, bloodletting, cautery of flesh, and specific diets (Roberts 2011, 268). The cartularies of leper hospitals rarely if ever mention treatments used on the inmates, being largely concerned with the rules by which they lived (Demaitre 2007, 4). There is evidence of medical care from one burial at the leper hospital of St Mary Magdalen, Winchester, which had an amputated lower left leg (Roffey and Marter 2012) clearly showing that medical care was available to at least some lepers.

## 5.3 Medieval attitudes to leprosy

Christianity does not offer a single explanation as to why humans endure suffering, it can be seen either as a punishment for sin, or as a mark of divine grace offering the chance for personal reflection and redemption. These two contradictory attitudes were present towards lepers throughout the medieval period. It was the character of the individual concerned that often accounted for the manner in which they were treated. Moral and virtuous people with leprosy were praised for their acceptance of God’s will, while lepers regarded as sinners were believed to be suffering from divine retribution.

Taking the more positive view first, namely that leprosy was a divine gift, there are numerous examples from the medieval period of compassionate reactions to the disease.

Christ's love for the despised and leprous outcast was a constant theme in literature throughout the Middle Ages, and comparisons were made between the bodily torment of lepers and those of Christ during his scourging and crucifixion (McComish 2007, 68). To some, lepers endured the torments of purgatory before death, making the disease a privilege rather than a curse (Rawcliffe 2006, 59). Bernard of Clairvaux (d. 1175) argued that disease in general should be embraced as a divine gift (*ibid.*, 55), while St Hugh of Lincoln (d. 1200) declared lepers to be blessed and stated that they would be healed in the after-life (*ibid.*, 59). St Francis of Assisi (d. 1226) converted to a mendicant life on seeing a leper who made him think of Christ, while the French surgeon Guy de Chauliac (d. 1368) stated that the clergy should reassure their patients that leprosy was a mark of divine election not a curse (*ibid.*, 55–7 and 63). The strongly held beliefs that leprosy was a blessing meant that some actually prayed to be infected to bring them closer to God. A monk called Ralph of Marmoutier (d. 1062) prayed to be inflicted with leprosy 'so that his soul might be cleansed of its foul sins' (*ibid.*, 59).

The 11<sup>th</sup>-13<sup>th</sup> centuries saw great acts of mercy towards lepers, Queen Maud (1080-1118) the wife of Henry I was celebrated for her saintly care of lepers, Walter de Lucy a 12<sup>th</sup> century nobleman frequently ministered to them, and St Hugh of Lincoln actually dwelt among them (Steane 1985, 96). Louis IX of France (r. 1226-70) visited leprosaria and personally tended the inmates (Rawcliffe 2006, 55), while Saint Elizabeth of Marburg, who was canonised in 1235, was known to have cared for a woman with leprosy, including bathing her, putting her to bed, cleaning and bandaging her sores, applying salves, cutting her fingernails and loosening the laces of her shoes (Marcombe 2003, 16). Even into the 14<sup>th</sup> century acts of mercy towards lepers were seen as virtuous. For example, in 1362 anyone who visited and relieved the residents of the leper hospital of St Mary Magdalen and St James in Chichester could claim 40 days remission and enjoined penance (Rawcliffe 2006, 133).

In the period up to the 13<sup>th</sup> century the church and rulers often expressed concern for the spiritual and physical care of lepers. A letter from Pope Gregory to the Anglo-Saxon missionary St Boniface advised that lepers should be allowed to partake of the communion but that they could not attend services with people of good health, suggesting that separate services be held (*ibid.*, 256). A belief that lepers could not reasonably be expected to withdraw from society unless they had regular access to the sacraments is expressed in instructions from Louis VI of France (d. 1137) to the clergy of Comiegne (*ibid.*, 256). The Lateran Council of 1179, while noting that lepers were obliged by mosaic law to live apart, also showed charity towards them, stating that it was deplorable that many lepers had been deprived of chapels, clergy and proper burial facilities, and demanding the creation of cemeteries for leper hospitals (*ibid.*, 261 and 357). Pope Alexander III (r. 1159-1181) also exempted leper houses from payment of tithes on agricultural products, so as to place the institutions on a sounder financial footing (*ibid.*, 257).

It is also clear that lepers were not always forced to live apart. There are examples of tolerant acceptance, the most famous being King Baldwin IV of Jerusalem who died of leprosy at the age of 23 in 1185. He contracted the disease as a child, his tutor William of Tyre noted that "each day he grew more ill, the extremities and the face were most affected,

so that the hearts of his faithful men were touched by compassion when they looked at him” (Demaitre 2007, 2). Baldwin was an intelligent and courageous leader, instrumental in the defeat of Saladin at Mont Gisard in 1177 (Marcombe 2003, 13), which no doubt did much to enhance his reputation. There was never any attempt to remove Baldwin from power, despite his illness, indeed he was praised for carrying out his royal duties despite his leprosy. The English Chronicler William of Newburgh (d. c.1198) distinguished between the king’s decaying flesh and his virtuous, well-governed soul (Rawcliffe 2006, 54). Baldwin was clearly not the only leper to remain in office. In 1333 there was a commission of enquiry to see if the leprous abbot of St Albans Richard Wallingford was still fit for office, and his brethren argued strongly that he was; he remained in office until his death 3 years later though he was assisted by a coadjutor who assumed many of his duties during the final stages of the disease (ibid., 254). Priests who developed leprosy were also allowed to continue in office until their appearance gave too much offence to their congregations, at which point an assistant was appointed (ibid, 266). The wealthy could choose to be confined in their own homes rather than entering hospitals (Magilton et al. 2008, 19). Further down the social scale, 21 of the 36 female lepers named in borough leet rolls of Yarmouth between 1369 and 1500 were living at home with their husbands (Rawcliffe 2006, 270), which shows acceptance and tolerance of the disease by close relatives at the very least.

Against this there was the widespread belief that physical illness was the punishment for sin, with the corruption of the soul causing corresponding corruption of the body. For this reason lepers were often portrayed as sinners or heretics whose corrupt behaviour was regarded as a threat to the morals and therefore the health of society as a whole. As a result of this they were often shunned. One example of leprosy being seen as the punishment of sin was the case of Robert FitzPernel Earl of Leicester (d. 1204) whose leprosy was seen as punishment for unjustly obtaining one of Lincoln’s episcopal estates (Magilton et al. 2008, 10). Leprosy was seen in particular as a punishment for sexual sin and was considered to be a sexually transmissible disease (Daniell 1997, 204). It was thought that prostitutes could transmit the disease without contracting it themselves (Magilton et al. 2008, 11).

As the disease spread from the 11th century onwards, so did the associated fear (Cullum 1994, 24). Although Hugh of Lincoln’s (d. 1200) care of lepers was seen by some as virtuous, others were horrified when he kissed the sores of lepers (Magilton et al. 2008, 16). By the late 12<sup>th</sup> century legislation began to appear for the physical separation of lepers. The *Canon De Leprosis* of 1179 declared lepers could not live among the healthy (Steane 1985, 96). Lepers were banned from the streets of London in 1200 (Rawcliffe 2006, 29), while the first recorded use of a rite by which a leper who refused to go into seclusion could be forcibly removed from the community occurred in 1220 (ibid, 29–30). Lepers were banned from the streets of Exeter by 1244, with the ban on lepers in the streets of London being reissued in 1276, suggesting that the original law had not worked (Magilton et al. 2008, 13).

Concern about the danger of physical infection that lepers posed became more apparent in the mid-13<sup>th</sup> century and increased significantly after the Black Death, when fears of transmission through touch and miasma took hold (Rawcliffe 2006, 102 and 269).



The most vindictive act towards lepers occurred in 1321 when King Philip V of France at first condoned and then ordered the burning of lepers in their shelters across the country, on the basis of rumours suggesting that the lepers had conspired with Jews and Moslems to poison the wells and destroy Christianity (Demaitre 2007, 5). Within weeks King Jaume II of Aragon ordered lepers be rounded up then tortured and burned if found guilty of such conspiracy (*ibid.*, 5). Attempts at forcing lepers to withdraw continued. A mandate of Edward III of 1346 required those thought to be leprous to be examined by medical and by lay persons, and if found leprous they could be exiled from the community; though some local by-laws for expulsion pre-dated this (Magilton et al. 2008, 13). In 1371 Charles V of France issued an injunction against the "great number" of leprous beggars on the street of Paris; this clearly had little effect as Charles VI in 1413 noted that there were many lepers who "quite often bother people, and hinder them in passing through and in going to their business" (Demaitre 2007, 143). Legislation seems to have been equally ineffective in London, where in 1372 a leprous baker John Mayn was expelled and threatened with the pillory if he returned (Magilton et al. 2008, 13).

#### 5.4 Leper hospitals in England

At least 320 leper hospitals were established in England between 1066 and the dissolution, meaning that between one quarter and one fifth of all known English medieval hospitals, including almshouses, were originally established for lepers, though they were sometimes housed alongside other patients (Rawcliffe 2006, 106-8). Many hospitals were small, having an average of 10 beds (Magilton et al. 2008, 19). For example, St James and Mary Magdalene Chichester was founded for eight leprous brethren (*ibid.*, 57).

Many leper hospitals were dedicated to saints who were thought to have a logical connection to the disease. The commonest dedication (69 examples) was to St Mary Magdalen (Rawcliffe 2006, 120). Mary Magdalen as seen in the medieval period was a composite of several biblical women including the unnamed woman who was a sinner who anointed Jesus' feet, Mary of Magdala, who witnessed both the crucifixion and resurrection, and Mary of Bethany, sister of Lazarus. Confusion between this Lazarus and the leper in the parable Dives and Lazarus gave rise to the belief that Mary's brother was leprous, hence her connection to the disease. St Leonard is another popular dedication (28 examples) as he was regarded as a patron of lepers, having miraculously appeared to a leper called Rampnaldus and restored him to health (*ibid.*, 124). St Lawrence suffered acutely during his martyrdom, being slowly roasted on a gridiron, this acute physical suffering could be compared to the pain of leprosy, and about a dozen hospitals are dedicated to him (*ibid.*, 125). St Bartholomew having been flayed alive was an obvious patron for all kinds of Skin diseases, and the leper hospital just outside Oxford was dedicated to him (*ibid.*, 124). John the Baptist noted for his long sojourn in the wilderness was the patron of a further six leper hospitals (*ibid.*, 125) his isolation mirroring that of the leper. St Giles the patron saint of beggars, lepers and outcasts, was another appropriate saint.

The founding of hospitals by the aristocracy was sometimes to enable care of a relative, friend or servant. For example, Earl Hugh of Chester, established the hospital at Spon near Coventry to care for one of his household knights, while Brian de Insula (d. 1149) made gifts to the priory at Abergavenny to care for his two leprous sons for life, and Elinald the sheriff

made gifts to Suffolk Priory at Stoke-by-Clare in return for the care of his leprous son (Rawcliffe 2006, 108 and 130-1).

It could be difficult to secure a bed in a leper hospital as certain categories of people would receive preferential treatment, including monks and the relatives or servants of the rich. The hospital of Holy Trinity Arundel founded in 1395 gave priority to the earl's servants, while the leper house at Walsingham was reserved for those of good families (Magilton et al. 2008, 16 and 19). Families could even endow a specific bed in a hospital to ensure they and their heirs would have provision of care should they need it and if not, the family could nominate an alternative candidate (Rawcliffe 2006, 295). Some leper hospitals charged an entry fee, such as the hospital at Lamford, Cornwall (Roffey 2012, 218). It was also possible for the wealthy to buy a place at a hospital whether leprous or not. The leper hospital at Whitby admitted non-lepers soon after its foundation in 1109 and by 1174 ten of the thirteen inmates at St Mary Magdalen's Hospital in Kings Lynn were not leprous (Magilton et al. 2008, 16; Roffey 2012, 217).

Some hospitals, such as Chichester, Harbledown, Southampton and Winchester, were located at some distance from their respective towns (Roffey 2012, 220). Other hospitals were located near healing wells and springs which attracted people with skin diseases (Rawcliffe 2006, 307-9) as at Burton Lazars, Leicestershire and Newark, Nottinghamshire (Roberts 2011, 268). This may also have been the case with St Leonard's Peterborough.

Many leper houses, however, were located on major routes into towns to enable the collection of alms from travellers. Examples of this type include Banbury, Chester, Dunwich, Glasgow, Kings Lynn, Leicester, Newport Pagnell, Oxford, Wallingford, Whitby Wymondham (Rawcliffe 2006, 308 and 311) and York (Evans 1992). In the case of Norwich the five leper hospitals were all located outside a gateway into the city (Rawcliffe 2006, Map 5). Such hospitals were clearly not primarily located with a view of total isolation, but rather with the need to be a visible presence.

Many hospitals had some kind of religious rule from the outset, such as St Leonard's, Peterborough (Tebbs 1979, 109; Rawcliffe 2006, 131), or Maiden Bradley, Wiltshire, where the sisters all had to take the habit as full nuns (Rawcliffe 2006, 264). The late 12th century rule of St Mary Magdalen, Gloucester, stipulated that lepers had to observe the traditional disciplines of patience, obedience and charity. Here, men and women were segregated and any transgressions of the rule were corrected at a general meeting (Roffey 2012, 219). There were other hospitals, however, where there does not seem to have been any form of monastic rule, such as St James, Canterbury (*ibid.*, 264). By the mid-13<sup>th</sup> century, if not before, most of the larger English leper hospitals had adopted monastic rules, often at the behest of patrons (Rawcliffe 2006, 131). Where monastic rules did apply, lepers could therefore be expelled for bad behaviour, as in the case of a leper at Ilford who had smuggled a prostitute into the hospital (*ibid.*, 264).

The inmates dressed as their founders or patrons decreed, often with some kind of hospital uniform. The lepers of St Michael's, Whitby wore the discarded robes of the Cistercians at Rievaulx which were donated annually (*ibid.*, 265).

Once inside inmates were not bereft of care as many foundations included brothers and sisters who dedicated their lives to caring for the residents, but 14<sup>th</sup> century documents from Europe suggest that medical practitioners were largely absent (Demaitre 2007, 5).

As leprosy declined in Europe many leper hospitals were converted to serve either as general hospitals or alms houses. The leprosarium at Sherburn, County Durham, which had been the largest in England held only two lepers by 1434 and was taking in poor men (Magilton et al. 2008, 11). This change was also seen in the Holy Land, where the Order of St Lazarus, which was founded for leprous knights and their servants, was admitting non-lepers by the 13<sup>th</sup> century (ibid., 11). Some leper hospitals fell into ruin, as with the leper houses of St John and St Leonard in Aylesbury which was in ruins by 1348 (ibid., 21) or New Romney, Kent, where it was reported in 1363 that ‘no lepers had come...for a long time and the buildings were quite derelict’ (Roffey 2012, 214). By the reign of Henry VIII leprosy was sufficiently unusual that no one could recall why the Shrewsbury leper house had been founded (Magilton et al. 2008, 21).

## 5.5 The burial of lepers

### 5.5.1 *Leper hospital cemeteries*

Approximately 800 burials in leper hospital cemeteries have been recovered during modern archaeological excavations. Almost half of these burials were recovered from a single excavation (at Chichester). The principal excavations at leper hospital cemeteries are listed below, in order of the date of excavation. It should be noted that not all of the sites listed have been fully published and many of the skeletons have not been examined by a palaeopathologist.

1) Saints Stephen and Thomas Hospital, New Romney Kent, was founded as a leper hospital 1185. It was refounded in 1363 as a hospital for the poor, at a time when the buildings were derelict and there were no lepers. A burial was found in 1935 in a tomb that tapered towards the feet and was made of poorly baked yellow bricks, but this possibly post-dated the closure of the hospital. Excavations in 1959 located further burials but these were not investigated (Magilton et al. 2008, 36-7).

2) St Mary Magdalene’s Hospital, Bidlington, East Sussex is first mentioned in 1296 as a hospital for leprous men, but by 1366 it was re-established as an alms house which survived until 1553 (ibid., 36). Forty-six burials were uncovered in 1959-60 (ibid., 36).

3) St James’ Hospital, Doncaster was founded by 1221 and was suppressed at the reformation. One of four burials excavated in 1961 was leprous (Buckland and Magilton 1989, 134).

4) St Bartholomew’s Hospital, South Acre, Norfolk, was founded c. AD 1100 and is thought to have gone out of use by 1350 possibly as a result of the Black Death (Roberts 2011, 263). Burials were found in 1769, and again in 1967 when twelve burials were uncovered during a road-widening scheme (Wells 1976). Two of the eight skulls seen at South Acre were metopic, which might suggest a genetic relationship, the same being true of further two burials with a detached neutral arch (Wells 1976, 248).

- 5) St Leonard's Hospital, Newark, was founded in 1133-4 for the poor and sick, but one clause in a document mentions lepers. Excavations in 1979 uncovered at least 77 burials (Magilton et al. 2008, 39)
- 6) St Margaret's Hospital, Gloucester, was founded in 1150 and converted to alms houses at a later date. Four burials were uncovered in 1984 (ibid., 40).
- 7) St Mary and St Thomas the Martyr, Ilford, Essex, was founded as a leper house in 1140, but later became an almshouse (Gilchrist and Sloan 2005). Nine poorly dated burials were excavated (ibid.) and were examined by Roberts in 1985 (Archaeology Data Service website).
- 8) St Margaret's Hospital, High Wycombe, Buckinghamshire, was founded by 1229. About 50-60 burials were uncovered in 1883, and a further twelve adult burials were uncovered during road works in 1986 (Farley and Manchester 1989, 84).
- 9) St Giles Brough Bridge, North Yorkshire (also known as St Giles by Brompton Bridge) is first referred to in documents of late 12<sup>th</sup> century date and is last mentioned in 1467, although it probably ceased to function in the 1440s. This hospital housed both the infirm and lepers. Though initially for men, women were admitted from the 13<sup>th</sup> century. Forty-two burials were uncovered during excavations in 1990-1991 (Historic England website; Magilton et al. 2008, 39)
- 10) St James and St Mary Magdalene, Chichester represents by far the largest excavated group of skeletons from a medieval leper hospital; 330 skeletons were excavated between 1986-7 and a further 44 burials were excavated in 1993 (Magilton et al. 2008, 5).
- 11) St Mary Magdalene's Hospital, Brook Street, Colchester, was founded for leprous males in the early 12<sup>th</sup> century. From 1323 sisters are also mentioned, but women were excluded from the hospital in new ordinances laid down in 1423 whereby the hospital was to be for five poor, sick or leprous men (Crossan 2004, 91-2). The hospital was re-founded as almshouses in 1610 (ibid., 93 and 98). Excavations in 1989 uncovered twelve burials relating to the leper hospital and these were sealed by the cemetery of a later parish church (ibid., 111-4).
- 12) St Margaret's Hospital, Spittals Link, Huntingdon, Cambridgeshire was founded in the mid-12<sup>th</sup> century and went out of use in the 14<sup>th</sup> century (Nenk et al. 1994, 194-5). Between 55 and 60 burials were uncovered in service trenches in 1994, but only those burials directly threatened by the ground-works were lifted (ibid., 194-5).
- 13) St Nicholas' Hospital, Lewes, was founded as a leper house in 1264-5. In 1994, excavations at the site recovered 102 burials (Magilton et al. 2008, 37).
- 14) St Mary Magdalene's Hospital, Winchester, dated from the 11<sup>th</sup> to 15<sup>th</sup> centuries (Roffey and Marter 2012). The site was first excavated in 2000 as part of the television programme the 'Time Team', and again from 2008-11 (Roffey 2012, 206). A total of 54 burials were uncovered, of which 38 related to the first phase of use at the site up to the mid-12<sup>th</sup> century, five of which dated from the mid-late 12<sup>th</sup> century to the 14<sup>th</sup> century, and eleven related to the 14<sup>th</sup>-16<sup>th</sup> centuries (Roffey and Marter 2012).

15) St Leonard's Hospital, Hady Hill, Chesterfield. A single burial of a male aged over 50 was uncovered during landscaping (Witkin 2000). The burial was associated with a chalice and paten, indicating that the individual was a priest and he was buried close to a wall which was interpreted as being part of the chapel of the leper hospital (ibid.). The burial dated from the late 11<sup>th</sup> to early 12<sup>th</sup> century (Magilton et al. 2008, 30).

16) St Peter's Hospital, Bury St Edmunds was in use from the early 12<sup>th</sup> century to 1545 during which time it evolved from caring for infirm and leprous priests to caring solely for lepers (Anderson 2003, 1). Twelve burials were found at the site in 2003, with further fragments of bone being discovered in 2008 (ibid., 1).

#### 5.5.2 *Leprous Skeletons in other medieval cemeteries*

Not all lepers were buried in the cemeteries of leper hospitals during the medieval period. There are examples across Britain of lepers buried at monastic sites, in the cemeteries of other medieval hospitals and in parish cemeteries. The presence of lepers such in contexts may have resulted from a number of factors.

It is known from documentary sources that lepers living in small communities without the benefit of religious services could ask for burial in the local churchyard (Rawcliffe 2006, 262). In the case of the leper hospital of St Leonard, Norwich, it has been suggested on the basis of both archaeological and documentary evidence that this hospital lacked its own facilities and had to rely on parochial support, with lepers being buried at the nearby churchyards of both St Margaret in Combusto and All Saints (ibid., 263). Seven leprous skeletons were recovered from archaeological excavations in the churchyard of St Margaret in Combusto (Stirland 2009, 1, 24), while the lepers Henry and Richard Wellys who died in 1448 and 1466 respectively, both asked to be buried at All Saints church (Rawcliffe 2006, 263). It should be noted, however, that the lack of a burial ground at the hospital of St Leonard, Norwich, would have been against canon law.

Examples of lepers in monastic contexts include Norton Priory, Cheshire, where a leprous male aged 20-25, dating to either the early 13<sup>th</sup> or late 14<sup>th</sup> century, was placed in a monolithic stone coffin in the chapter house (Boylston 2008, 151 and 164). Both the coffin and the location of the burial within the priory are clearly indicative of high social status. The cemetery of the Dominican Friary, Guilford, which was in use from 1263-1538, contained a leprous male aged 16-25 (Gilchrist and Sloan 2005). One of the 201 burials excavated at the Carmelite Friary in Aberdeen was a leprous male aged 46 years or older, dating to c.1500-1560 (ibid.). It is unclear in these cases if the individuals concerned were donors who bought the right for burial or whether they were friars who were cared for by the brethren rather than being expelled.

Examples are known of lepers being buried in the grounds of medieval hospitals which were not specifically for lepers. Many non-leper hospitals began to take lepers into their care in the later 13<sup>th</sup> century (Barber and Siburn 2010, 81). For example, two leprous burials were present among the 103 excavated burials in the cemetery of St Nicholas, Lewes, which dated to 1150-1560 (Gilchrist and Sloan 2005), while three lepers were present among the 49 burials excavated in the cemetery of St Leonard's Hospital, London Road, Grantham, which was a hospital for the sick poor (Roberts 2011, 262; Nenck et al. 1992, 251). At Blackfriars

Friary, Ipswich, four of the 250 burials dating from 1263-158 were leprous (Mays 1991, 1 and 54-5). One of these four burials was of a woman aged 50+, who was clearly not a friar, indicating that other factors were involved in the placing of this burial (ibid., 55). There was also evidence of a genetic link between one of the leprous Skeletons and a healthy Skeleton from this site (ibid., 56), suggesting that family ties played a role.

Lepers may have requested burial in churchyards alongside their families. At Dixon Lane and George Street, York, a single leprous female was present among the 118 excavated burials, in a cemetery dating from the early 11<sup>th</sup> to the mid-14<sup>th</sup> century (McComish 2007, 30-31 and 68); there were clearly leper hospitals with cemeteries in the vicinity, indicating that the relatives of the deceased chose to bury their relative in the parish cemetery. This burial was, however, positioned at the very limits of the cemetery, in a marginal position. It is tempting to see this exclusion from the main part of the cemetery in death reflecting prejudices towards the disease and its sufferers in life (ibid., 30-31 and 68). The desire for burial alongside relatives in the parish churchyard may also account for the requests for burial at All Saints, Norwich, by the Wellys' family, noted above. While lepers are clearly present in churchyards this may have been unusual. For example, there are no examples in wills from Chichester of non-lepers seeking burial in a leper hospital (Magilton et al. 2008, 27).

## 6 A SUMMARY OF THE SEQUENCE OF DEPOSITS AT THE MIDLAND ROAD SITE

by J.M. McComish

Naturally occurring Cornbash Formation Limestone (Context 1069) was seen at between 0.3m to 0.5m below the present ground level.

Virtually no subsoil (Context 1068) was preserved at the site due to modern truncation. Cutting into the natural bedrock in evaluation Trench 3 there was a shallow north-south aligned gully (Context 307) which was 0.8m to 1m in width and 0.09m deep. The date of this gully is uncertain as no artefacts were recovered from the backfill.

Also cut into the natural bedrock were the remains of a cemetery from the 12-16<sup>th</sup> centuries, which is described in detail in section 7 below. No original cemetery soils or topsoil survived due to modern truncation.

Features of modern date included a pit (Context 874 and associated backfills 875-6), an area of modern disturbance (Context 923 and associated fill 922), three service pipe trenches (Contexts 930 and 995 and an unnumbered pipe located to the south of 874), an unnumbered brick structure (located in the eastern portion of the cemetery), disturbed ground (Context 823) and a north-east to south-west aligned ditch (Context 800 and associated fills 801-2).

The uppermost deposits at the site were of modern date and comprised brick and concrete rubble (Context 1070) up to 0.5m thick capped by a hard-standing.

## 7 THE CEMETERY

by J.M. McComish and G. Millward

A total of 131 inhumations were recovered at the site (Skeleton numbers 1, 3-10, 12, 14-18, 21, 23-26, 28, 30-40, 42-52, 54-64, 66-116, 118-130 and 132-144). In addition, Skeleton numbers 2, 53, 65, 117 and 131 (originally thought to be an inhumation) were allocated to charnel deposits. Skeleton numbers 13, 19-20, 22, 27 and 29 were not allocated during the excavation. Skeleton number 41 was assigned during the excavation but no bones were recovered relating to that identification number. There was a small cut (Context 905 and associated backfills Contexts 903-4) which may represent the grave cut for an infant, though no bones were present. The precise location of Sk 39 (which was badly disturbed) was unclear from the original site records. In addition to the Skeletons over 5,300 fragments of charnel and disarticulated human bone were present in at least 87 contexts across the site (Swann 2015, 5 and 12). This quantity of charnel was predominantly due to modern truncation as well as the presence of intercutting burials. The preservation of the human bones at the site was exceptionally poor.

### 7.1 The date of the cemetery

The dating evidence for the burials is summarised in Figure 3. Relatively few artefacts were recovered from the cemetery, with pottery dating from the 11<sup>th</sup> to mid-12<sup>th</sup> centuries being present in 24 graves and lace tags dating from the 15-16<sup>th</sup> centuries being present in seven graves. There was a total absence of any 13-14<sup>th</sup> century artefacts, though burials of that date were identified by radio carbon dating.

To clarify the dating of the cemetery, twelve of the burials were subjected to radio carbon 14 dating by SUERC (Table 1). The results of the C14 analysis suggested a date range of 1036-1208 for the earliest burial sampled, to 1470-1690 for the most recent, which concords with the documentary evidence, with the earliest reference to the hospital being 1125 and the most recent to 1535, with the possibility that the site continued in use for burials until 1665 (VCH 1906, 162; Creighton 1894, 34; Tebbs 1979, 103).

### 7.2 Phases of use within the cemetery

The layout of the cemetery is suggestive of two phases of use, with Phase 1 (Figure 4) comprising an orderly pattern of burial rows covering most of the site, which were truncated by the less regularly laid out Phase 2 burials (Figure 5). Only one burial (Sk 39) could not be allocated to a phase as its precise location is unclear from the original site records.

Sample	Skeleton Number	Carbon 14 date (cal AD)
1	37	1380-1530 (89% probability) 1310-1620 (95.4% probability)
2	33	1280-1430 (95.4% probability)
3	21	1150-1300 (93.4% probability) 1050-1300 (95.4% probability)
4	4	1150-1300 (92.1% probability) 1050-1300 (95.4% probability)
5	18	1036-1208 (95.4% probability)
6	85	1280-1420 (95.4% probability)
7	86	1444-1634 (95.4% probability)
8	120	1300-1450 (95.4% probability)
9	93	1470-1690 (82.5% probability) 1470-1810 (95.4% probability)
10	98	1300-1450 (95.4% probability)
11	132	1411-1486 (95.4% probability)
12	139	1442-1633 (95.4% probability)

**Table 1: Summary of the Carbon 14 dates for the site**

### 7.3 Phase 1

Eighty-three Skeletons were allocated to Phase 1. During this phase the cemetery was well-organised, with the burials being arranged in nine slightly irregular rows (Figure 4). From west to east the rows comprised

Row 1 = Sk 108, Sk 138, Sk 46, Sk 50, Sk 66 and Sk 49

Row 2 = Sk 127, Sk 68, Sk 48, Sk 52, Sk 38, Sk 21 and Sk 35

Row 3 = Sk 3, Sk 4 and Sk 106

Row 4 = Sk 136, Sk 134, Sk 133, Sk 5, Sk 94, Sk 88, Sk 87, Sk 74, Sk 57, Sk 55 and Sk 58

Row 5 = Sk 121 and Sk 112

Row 6 = Sk 143, Sk 113, Sk 8, Sk 18, Sk 76, Sk 59, Sk 69, Sk 61, Sk 42, Sk 45, Sk 31 and Sk 30

Row 7 = Sk 129, Sk 25, Sk 26, Sk 125, Sk 141, Sk 142, Sk 128, Sk 9, Sk 10, Sk 75, Sk 60, Sk 62, Sk 72, Sk 70, Sk 63, Sk 51, Sk 32 and Sk 43

Row 8 = Sk 119, Sk 118, Sk 115, Sk 28, Sk 105, Sk 104, Sk 100, Sk 14, Sk 15, Sk 16, Sk 17, Sk 73, Sk 84, Sk 91, Sk 85, Sk 80 and Sk 77

Row 9 = Sk 111, Sk 110, Sk 99, Sk 92 and Sk 95



In addition there were two burials, Sk 64 and Sk 130, which could not be allocated to a row.

The westernmost two burial rows were aligned north-south, Rows 3-6 curved towards the NE at the northern end, and the remaining rows were on an NbE-SbW alignment. There are occasional gaps within the rows, such as between Sk 57 and Sk 74 in Row 4, or Sk 100 and Sk 14 in Row 8, but it is possible that these are the result of the removal of graves by modern truncation.

There was very little intercutting between the Phase 1 burials, which is suggestive of careful layout. The instances of intercutting between the burials were:

- The grave for Sk 5 in Row 4 was truncated by the grave for Sk 106 in Row 3 to the west, but there was no damage to Sk 5.
- The upper right arm of Sk 94 may have been removed by Sk 88, though equally it could have resulted from modern truncation. Both burials were in Row 4.
- The left arm of Sk 87 was removed by Sk 88. Both burials were in Row 4.
- The lower legs of Sk 112 in Row 5 were removed by the grave cut for by Sk 113 in Row 6 to the east.
- All but the Skull and lower legs of Sk 130 (not in a row) were removed by the grave for Sk 129 in Row 7 to the west.
- The upper left torso of Sk 125 was removed by Sk 26. Both burials were in Row 7.

The pattern of the rows, coupled with the evidence for intercutting might imply that Row 4 and 5 together with Sk 130 represent the earliest burials at the site, with the remainder of the rows being laid out from the east of the site to the west, but the evidence is tentative.

The Phase 1 burials were typically laid east-west with the head at the western end, but there were some variations in alignment (Figure 6), ranging from burials aligned between east-west and WbS-EbN, burials being between east-west and EbS-WbN, and burials being aligned between EbS-WbN and WNW-ESE. All the burials were in individual grave cuts.

Charnel was present in the graves for Sk 3, Sk 4, Sk 15, Sk 16, Sk 26, Sk 32, Sk 43, Sk 45, Sk 49, Sk 51, Sk 57 (in this case the charnel was allocated a context number Sk 65), Sk 59, Sk 72, Sk 76, Sk 84, Sk 91, Sk 92, Sk 100, Sk 104, Sk 105, Sk 106, Sk 112, Sk 128, Sk 129 and Sk 142.

Given that these graves are the earliest on the site, it is unclear precisely where on site this charnel originated from; in the case of Sk 35, Sk 26 and Sk 125 the charnel could represent the redeposition of bones disturbed by later Phase 2 graves while for the remaining graves it could simply be the result of modern disturbance.

Nineteen of the Phase 1 graves contained sherds of pottery which ranged in date from the 11<sup>th</sup> to mid-12<sup>th</sup> centuries. Four burials from this phase were submitted for C14 dating, the results being date ranges of 1036-1208 (Sk 18), 1150-1300 (Sks 4 and 21) and 1280-1420 (Sk 85). The overall date for Phase 1 would, therefore, seem to be 11<sup>th</sup> to 13<sup>th</sup> century.

Eleven, or 13.25%, of the burials (Sk 4, Sk 16, Sk 18, Sk 45, Sk 51, Sk 55, Sk 57, Sk 69, Sk 76, Sk 80 and Sk 85) belonging to Phase 1 were assessed as being leprous. A further ten, or 12.05%, of the burials (Sk 9, Sk 42, Sk 43, Sk 68, Sk 84, Sk 91, Sk 104, Sk 118, Sk 112 and Sk 136) were assessed as being probably leprous and another nine, or 10.84%, of the burials (Sk 10, Sk 17,

Sk 21, Sk 32, Sk 35, Sk 38, Sk 60, Sk 73 and Sk 74) were assessed as being possibly leprous. Taken together these possibly, probably and definitely leprous individuals account for 36.14% of the Phase 1 burial population (Figure 11).

#### 7.4 Phase 2

The forty-seven Skeletons allocated to Phase 2 (Figure 5) comprised all the burials containing lace tags (as these had to be of 15<sup>th</sup> century date at the earliest), together with all the burials which clearly disregarded the burials rows of Phase 1 and/or definitely truncated burials of Phase 1, and any burials which had Carbon 14 dates of 14-16<sup>th</sup> century date (Sk 33, Sk 37, Sk 86, Sk 93, Sk 98, Sk 120, Sk 132 and Sk 139).

The layout of the Phase 2 burials was clearly less organised than that of Phase 1. It was possible to suggest eleven burial rows in this phase (numbered Rows 10-20 to avoid confusion with the Phase 1 burials rows), but many of the graves were not in distinct rows. Three of the rows (14, 15 and 17) comprised a pair of burials that seem to have been placed in relation to one another. From west to east the Phase 2 burials were:

Sk 123 - not in a Row

Row 10 = Sk 1 and Sk 124

Row 11 = Sk 40, Sk 36 and Sk 33

Row 12 = Sk 54, Sk 67, Sk 47, Sk 44, Sk 37 and Sk 34

Sk 137, Sk 132, Sk 56 and Sk 23 – not in a row

Row 13 = Sk 135, Sk 6 and Sk 7

Row 14 = Sk 24 and Sk 144

Row 15 = Sk 139 and Sk 140

Row 16 = Sk 12 and Sk 71

Row 17 = Sk 109 and Sk 120

Sk 122, Sk 103, Sk 126, Sk 116, Sk 114 – not in rows

Row 18 = Sk 98, Sk 79, Sk 78, Sk 90, Sk 89 and Sk 86

Row 19 = Sk 107, Sk 93, Sk 102, Sk 97, Sk 82, Sk 83 and Sk 96

Row 20 = Sk 101 and Sk 81

The Phase 2 burials were laid east-west with the head at the western end, but as with Phase 1 there was some variation (Figure 6) with burials being aligned between east-west and WbS-EbN, between WbS-EbN and ENE-WSW, between east-west and EbS-WbN, and between EbS-WbN and WNW-ESE. The range of alignments was slightly greater than that of Phase 1.

Although there are also more spaces devoid of burial within the Phase 2 cemetery it is difficult to know how much of the pattern seen is the result of severe modern truncation. The Phase 2 cemetery layout seems more haphazard than that of Phase 1 with a greater degree of intercutting and a wider range of burial alignments.

Some of the burials within Phase 2 were intercut, with two of the graves in Row 12 truncated burials in Row 11, Sk 93 truncated Sk 98, and Sk 81 truncated the double grave Sk 82/83 which in turn truncated Sk 78.

Many of the Phase 2 graves truncated Phase 1 burials causing disturbance to the earlier burials, the bones of which were often removed and placed in the side of the later grave cut (this was the case for Sk 124, Sk 47, Sk, 34, Sk, 56, Sk 12, Sk 93, Sk 79 and Sk 116 (where the charnel was allocated the number Sk 117)).

There were two multiple occupancy graves in Phase 2, one of which contained Sk 82 and Sk 83, and the other Sk 86, Sk 89 and Sk 90. This marks a distinct change from Phase 1 where there were no multiple occupancy graves.

Five of the Phase 2 graves contained 11-12<sup>th</sup> century pottery, but this could have been residual, while seven contained 15<sup>th</sup>-17<sup>th</sup> century lace tags. Eight burials from this phase were submitted for Carbon 14 dating (Table 1), with the burials concerned ranging from 1280-1430 (Sk 33) at the earliest to 1470-1690 (Sk 93 at the latest). Overall Phase 2, therefore, seems to date from the 13<sup>th</sup> to 17<sup>th</sup> century.

Three, or 3.45%, of the burials (Sk 23, Sk 82 and Sk 97) belonging to Phase 2 were assessed as being leprous. A further eight, or 17.02%, of the burials (Sk 1, Sk 7, Sk 12, Sk 36, Sk 67, Sk 78, Sk 120 and Sk 144) were assessed as being probably leprous and another one, or 2.13%, of the burials (Sk 71) assessed as being possibly leprous. Taken together these possibly, probably and definitely leprous individuals account for 22.6% of the Phase 2 burial population (Figure 11).

## **7.5 Burial practice**

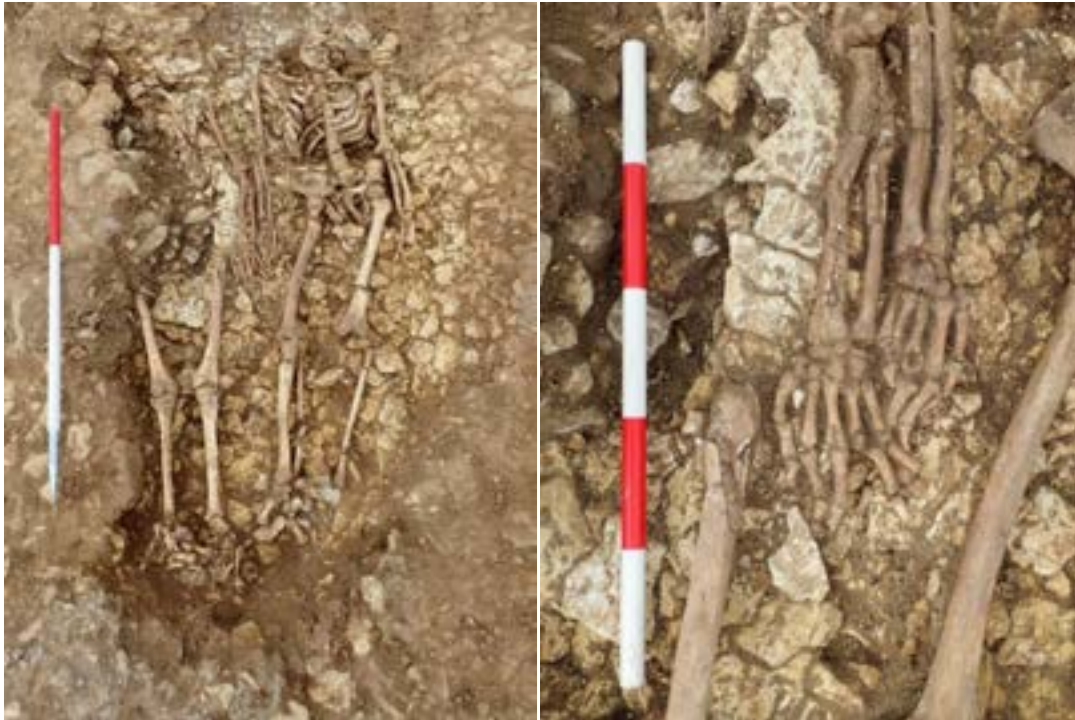### *7.5.1 Grave size and depth*

The various graves from the cemetery at the site were largely rectangular in shape, though some had rounded ends. Two graves cut were slightly wider midway along their length (for Sk 18 in Phase 1 and Sk 54 in Phase 2), but these were not fully anthropomorphic in shape.

The grave cuts ranged from 0.5m to 2.2m in length, 0.3m to 0.95m in width and 0.03m to 0.3m in depth. In general the grave cuts were the smallest size required to accommodate the burial in question, perhaps reflecting the difficulty of excavating graves into the underlying limestone. The only exception was the grave for Sk 36 in Phase 2 which was unusually wide. It should be noted that modern truncation had undoubtedly removed the uppermost portions of the graves, creating a misleading impression of their original depth

### *7.5.2 Multiple occupancy graves*

Two graves were interpreted as being for multiple burials, both of which were in Phase 2. The first of these was for Sk 82-83, which were laid side by side with overlapping hands (Plate 1). Sk 82 was a young adult male who had lepromatous leprosy. Sk 83 was a 26-35 year old adult female who exhibited bone alterations caused by non-specific infection. The comparable ages of the two individuals and the deliberate care taken with this burial appears to indicate that they had some form of relationship, possibly siblings or a married couple, during their lives.



**Plate 1: Skeletons 82-83, with a detail of their overlapping hands.**

The second multiple occupancy grave was for Sk 86, Sk 89 and Sk 90, but this had been severely truncated by modern disturbance making the original burial positions of the three occupants impossible to determine.

#### 7.5.3 *Superimposed burials*

There was a single example on the site where one burial (Sk 12) overlay another (Sk 75). It is unclear if this was pure coincidence, or not.

#### 7.5.4 *Grave markers*

The implication of burial rows within the cemetery is that the graves must have been visible in some way, so as to avoid intercutting. No trace of any grave stones or of post-holes to house wooden markers was seen during the excavation. It is possible, however, that the graves were marked by low mounds. Any such mounds for the Phase 1 burials would have long-gone by the time the Phase 2 burials were interred, hence the degree to which the Phase 2 burials disturbed those of the earlier cemetery. It is impossible to determine if such mounds existed for the Phase 2 burials as the upper portions of all the graves at the site had been severely truncated.

#### 7.5.5 *Burial position*

The burials were typically supine and extended with the arms extended at the side of the body. There were a few burials which differed from the norm. The original assessment report (Swann 2015, 5) stated that one of the burials (Sk 40) was prone, but it is clear from the site photographs (Plate 2) that this was not the case as the sacrum and lumbar vertebrae are clearly supine.

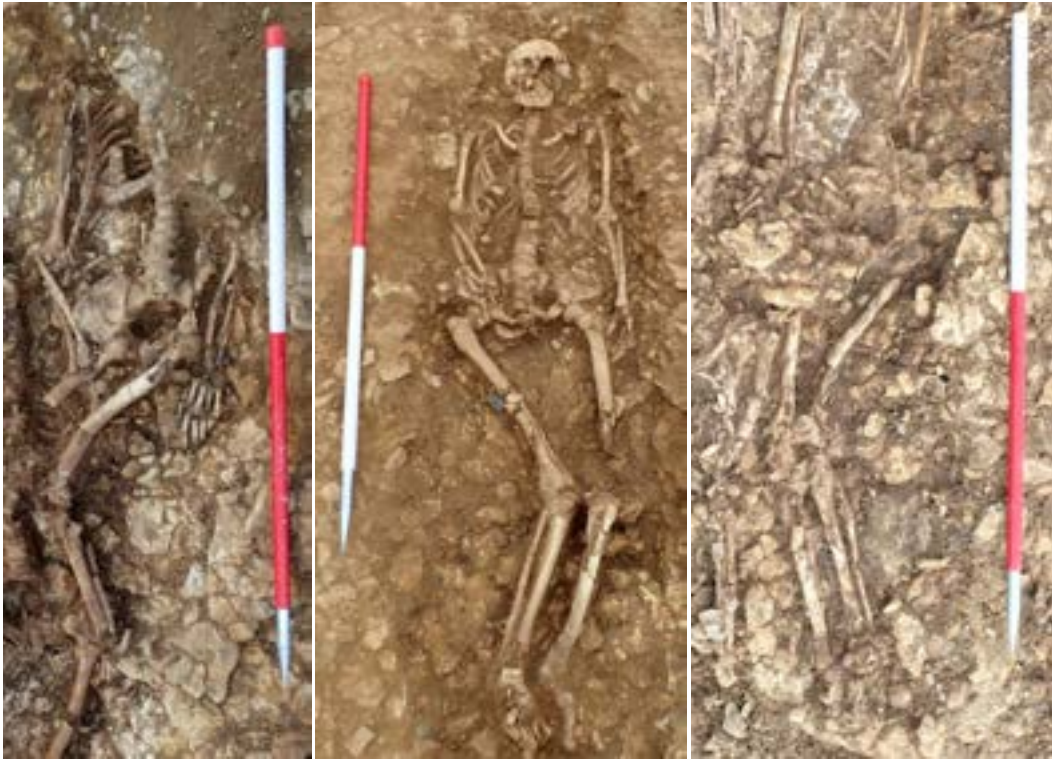

**Plate 2: Skeleton 40.**

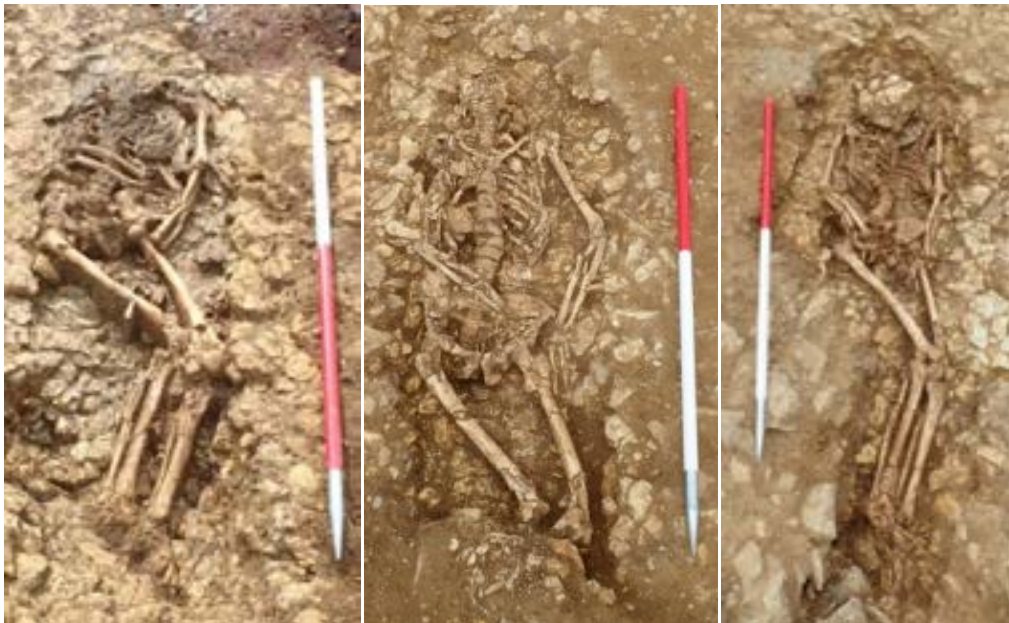Most of the burials at the site had fully extended legs, but there were eleven burials which differed from the norm (Figure 7). Burials Sk 6, Sk 18, Sk 31, Sk 43, Sk 75 and Sk 84 had flexed legs (Plate 3-4). In the case of Sk 6 and Sk 31 the knees were flexed towards the right, while the remaining examples were flexed towards the left. All of Skeletons were within Phase 1 with the exception of Sk 6 which was in Phase 2. These burials were scattered across the site. There were an additional three burials with slightly flexed legs (Sk 10, Sk 60 and Sk 63, Figure 7) all of which were flexed towards the left (Plate 5). These Skeletons were all in burial Row 7 in Phase 1.

Two further burials had unusual leg positions (Figure 7, Plate 6), Sk 54 had the left knee placed above the right knee, while Sk 73 had an extended right leg while the left leg was flexed towards the left.


There does not appear to be any specific pathological reason for the flexed leg burials described above. The pathology of these Skeletons (some of which had conditions which may have caused physical deformation) was not significantly different to that of the rest of the general population, which were buried with extended legs.



**Plate 3: Skeletons 6, 18 and 31.**



**Plate 4: Skeletons 43, 75 and 84**



**Plate 5: Skeletons 10, 60 and 63.**



**Plate 6: Skeletons 54 and 73.**

A total of six different arm positions were seen among the burials (Figure 8, Plates 7-8) which were as follows:

- Position 1 (Plate 7) – both arms fully extended at the side of the body, 48 examples (Sk 3, Sk 7-8, Sk 10, Sk 12, Sk 16-17, Sk 23, Sk 25, Sk 32, Sk 34, Sk 37, Sk 42, Sk 45, Sk 54-57, Sk 63-64, Sk 67, Sk 69, Sk 71-74, Sk 78, Sk 81-83, Sk 86, Sk 88, Sk 92, Sk 96, Sk

100, Sk 112, Sk 116, Sk 118, Sk 120, Sk 124, Sk 126-128, Sk 132-134, Sk 137, Sk 141 and Sk 144)

- Position 2 (Plate 7) – Left arm fully extended at side, right hand on right pelvis, 8 examples (Sk 6, Sk 33, Sk 76, Sk 80, Sk 84, Sk 97, Sk 104 and Sk 139)
- Position 3 (Plate 8) – Right arm fully extended at side, left hand on left pelvis, 8 examples (Sk 9, Sk 18, Sk 44, Sk 51, Sk 59, Sk 62, Sk 79 and Sk 93)
- Position 4 (Plate 4) – Left arm fully extended at side, right hand on left pelvis, 1 example (Sk 75)
- Position 5 (Plate 8) – Left hand on left shoulder, right arm across stomach, 1 example (Sk 60)
- Position 6 (Plate 4) – Left arm flexed, right forearm on rib cage, 1 example (Sk 43)

Twenty-eight of the Skeletons had only one arm surviving, making the original burial position impossible to determine. These Skeletons can be split into four types (Positions 8-11)

- Position 7 – Left hand on left pelvis, right arm missing, 1 example (Sk 94). This could originally have been Position 3 or the right arm could have been a one-off position.
- Position 8 – Left arm fully extended at side, right arm missing, 11 examples (Sk 4, 1 Sk 4, Sk 31, Sk 68, Sk 85, Sk 87, Sk 113, Sk 135, Sk 140 and Sk 142-143). These could originally have been Positions 1, 2 or 4.
- Position 9 – Right arm fully extended at side, left arm missing, 15 examples (Sk 5, 15, Sk 21, Sk 26, Sk 35, Sk 47, Sk 61, Sk 98, Sk 102-103, Sk 105, Sk 107, Sk 110, Sk 122 and Sk 129). These could originally have been Positions 1 or 3.
- Position 10 – Right arm over ribs, left arm missing, 1 example (Sk 101). This could originally have been Position 6 or have been a one-off position with the left arm fully extended and right arm over the ribs.

The remaining burials (Sk 1-2, Sk 24, Sk 28, Sk 30, Sk 36, Sk 38-41, Sk 46, Sk 48-50, Sk 52, Sk 58, Sk 66, Sk 70, Sk 77, Sk 89-91, Sk 95, Sk 99, Sk 106, Sk 108-109, Sk 111, Sk 114-115, Sk 117, Sk 119, Sk 121, Sk 123, Sk 125, Sk 130-131, Sk 136 and Sk 138) were too fragmentary to determine the original burial position.

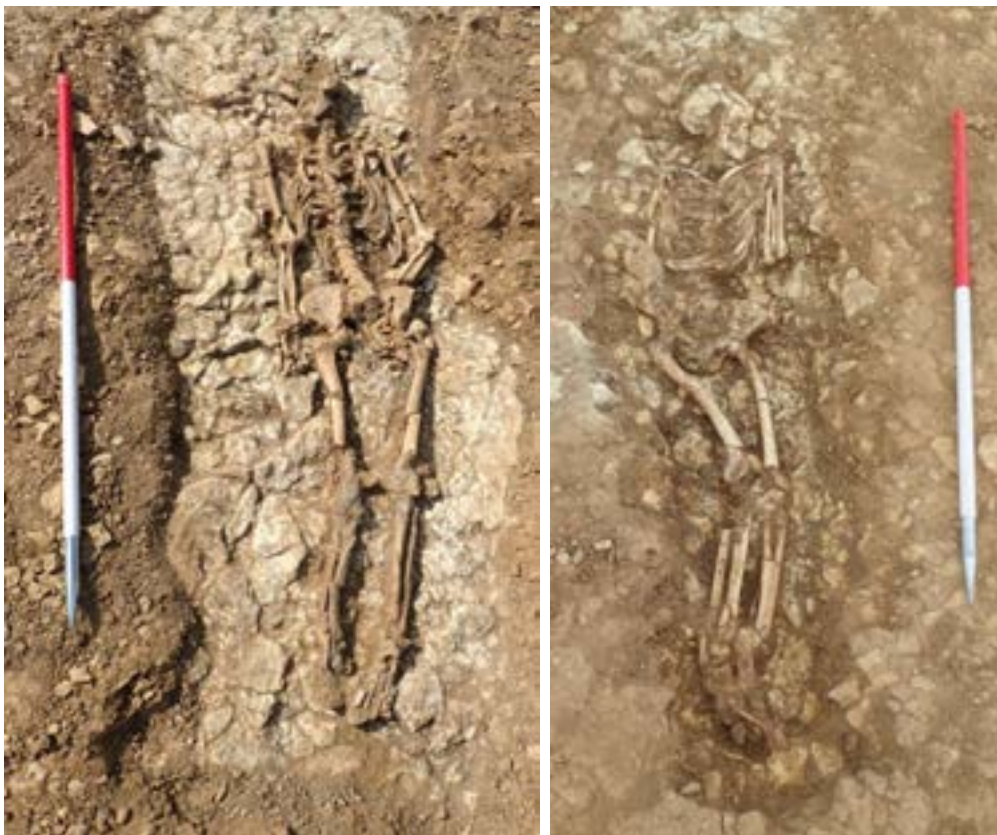The dominant position was clearly for both the arms to be fully extended at the sides (Position 1). Positions 2-4 can be regarded as minor variations of Position 1. There are just three burials which have one or both arms flexed (Positions 5-6 and 10) all of which were in Phase 1. The conformity of arm position suggests a carefully controlled burial rite, during both phases of cemetery use.

There does not appear to be any specific pathological reason for the varied arm positions described above with the exception of Sk 101 (position 10) which had osteomyelitis of the right ulna. This factor may have influenced the decision to bury this individual with their right arm lain over their ribs.





**Plate 7: Arm Position 1 Skeleton 16 and Position 2 Skeleton 76.**



**Plate 8: Arm Position 3 Skeleton 9 and Position 5 Skeleton 60.**

### 7.5.6 *The use of coffins*

As wood was not preserved at Midland Road the presence of coffins is almost impossible to prove.

Five graves (Sk 18, Sk 47, Sk 57, Sk 59 and Sk 121) each contained a small fragment of an iron nail (Figure 9). These fragments occurred randomly within the grave fills and, as there was only a single nail was present in each case, there was therefore no evidence of patterns of nails which could suggest the outline of a coffin. Two of these graves contained burials where the position of the bones suggested that a coffin had not been present (Sk 18 and Sk 59 see below) suggesting that the iron nail fragments in these cases were stray finds.

The position of the Skeletons can be used to suggest that some of the burials were originally coffined, as the bones have a very parallel-sided appearance, as if confined within a box. Twenty-three burials at the site (Sk 7, Sk 12, Sk 15-17, Sk 23, Sk 42, Sk 44-45, Sk 51, Sk 71-72, Sk 76, Sk 78, Sk 80, Sk 88, Sk 93, Sk 94, Sk 120, Sk 124, Sk 127, Sk 132 and Sk 144) were parallel-sided suggestive of interment within a coffin (Plates 9-16).

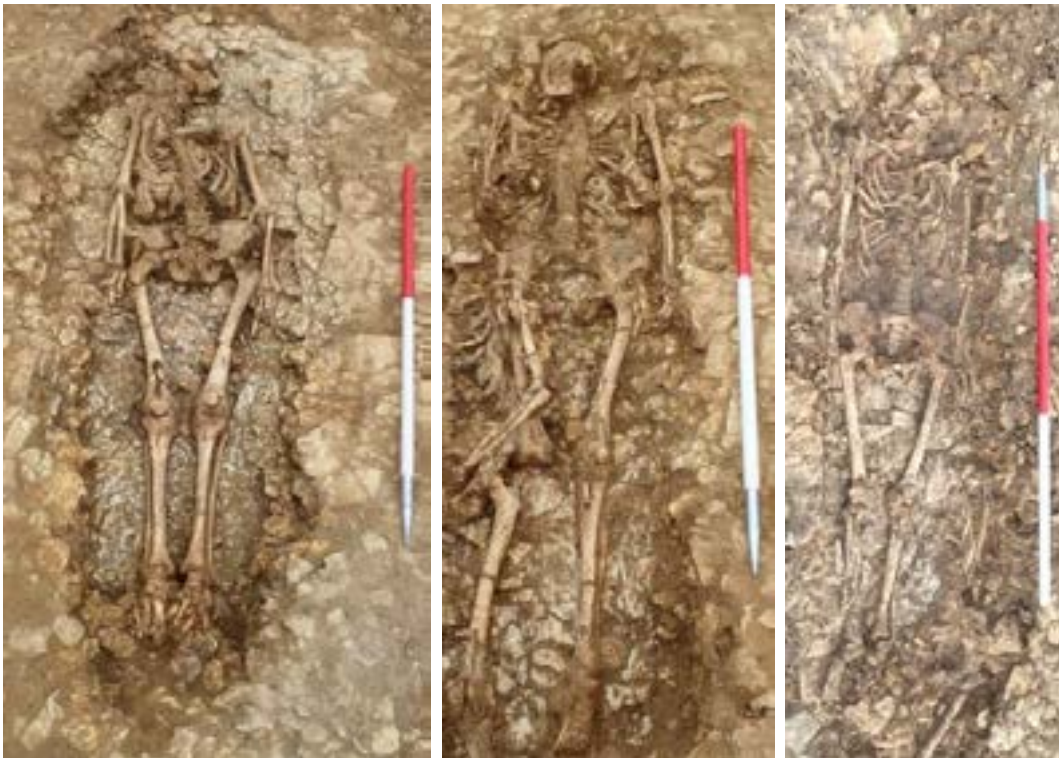The burial position can equally suggest that burial in a coffin was unlikely in 31 burials at Midland Road. This group includes the burials with unusual leg positions listed in section 7.5.4 above (Sk 6, Sk 10, Sk 18, Sk 31, Sk 43, 54, Sk 60, Sk 63, Sk 73, Sk 75 and Sk 84), and the multiple-occupancy burials (Sks 82-83 and Sk 86, Sk 89 and Sk 90) described in section 7.5.2 above. In addition, Sk 9, Sk 14, Sk 69, Sk 74, Sk 79, Sk 81 and Sk 97 (Plates 17-19) were laid in slightly curving positions, suggesting that coffins were not used. Although Sk 104, Sk 139 Sk 140 were partly missing, the position of the spine in each case would also suggest that these burials were not coffined (Plate 19). In the case of Sk 32 and Sk 34 (Plate 20) one or both arms were positioned slightly apart from side of the torso, while Sk 67 and Sk 137 (Plate 20 and 21) had a slightly flexed right arm, all of which might indicate that the Skeleton in question was not buried within a coffin. Sk 59 had hips and a right leg in a slightly twisted position (Plate 21) again suggesting the burial was not coffined.

The remaining Skeletons at the site were too incomplete or badly preserved to suggest from their burial position whether a coffin had originally been present or not.

It was possible to suggest the presence or absence of a coffin on the basis of the burial position for 31 Phase 1 burials, of which 15 were coffined and 16 were not (48.4% and 51.6% respectively), while for Phase 2 the burial position suggests that 10 burials were coffined and 13 were not (43.5% and 56.5% respectively).



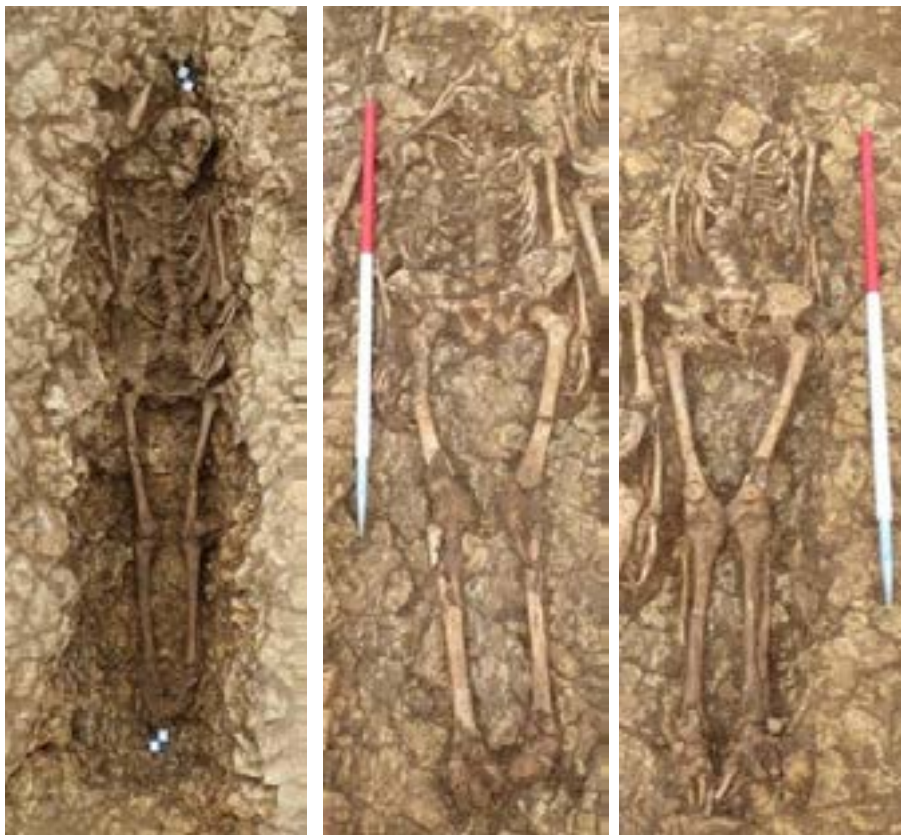**Plate 9: Skeletons 7, 12 and 15**



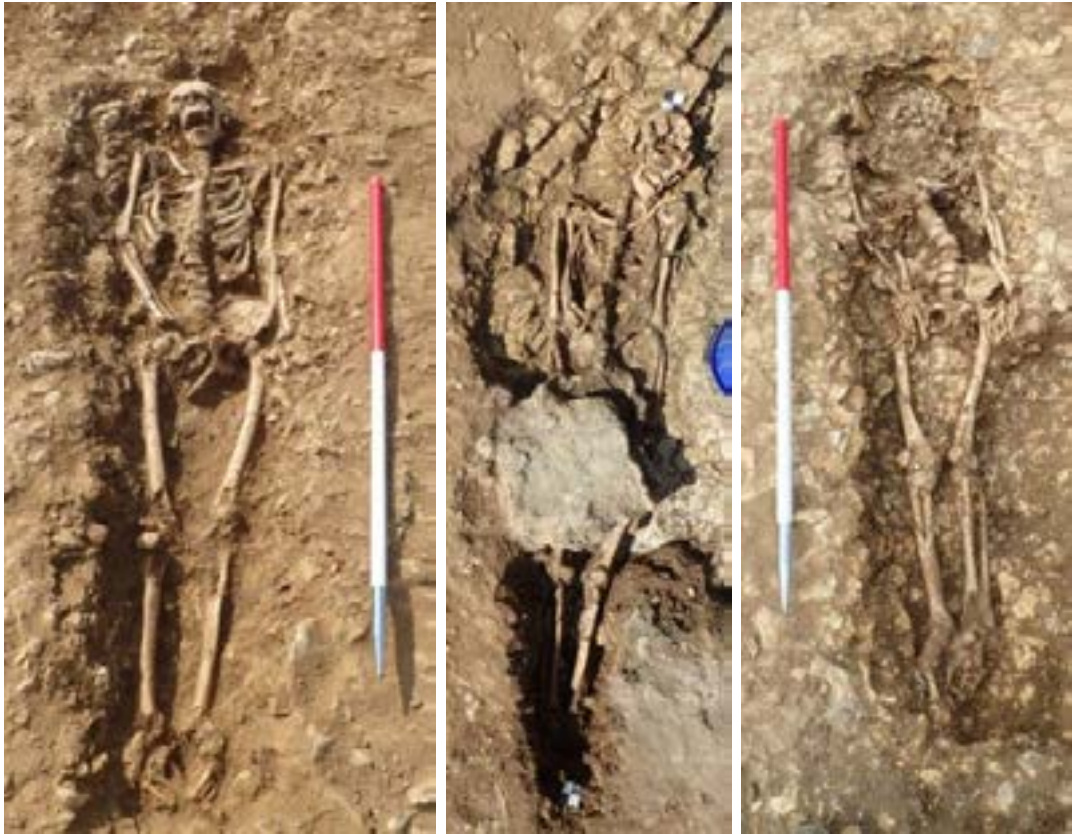**Plate 10: Skeletons 16, 17 and 23**



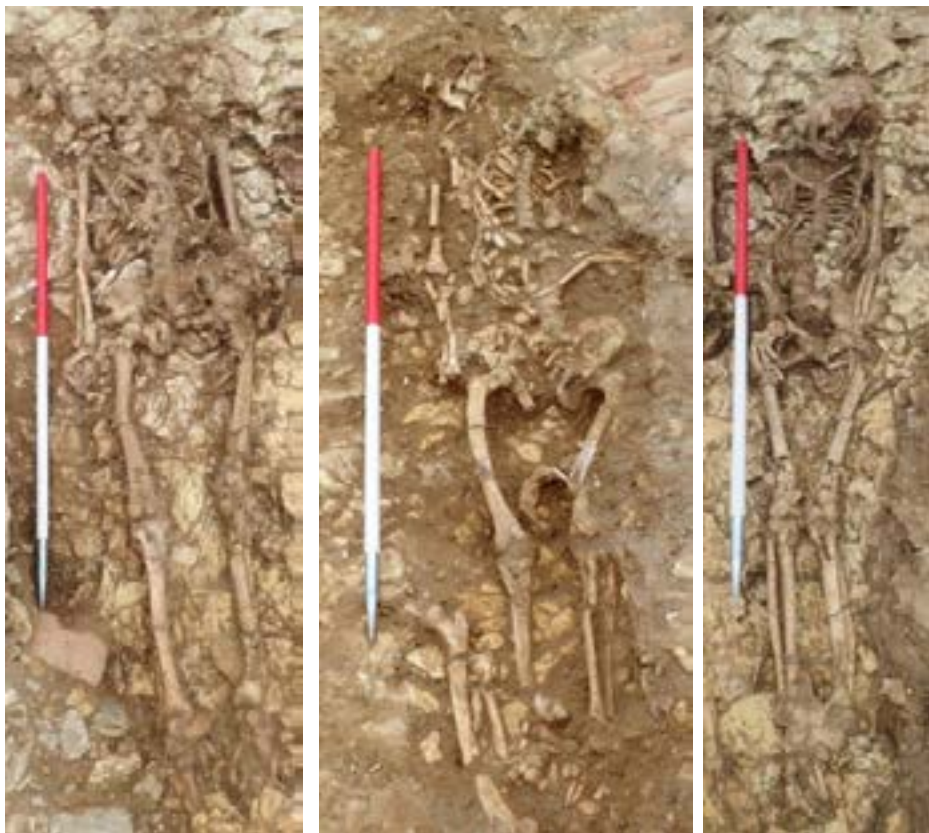**Plate 11: Skeletons 42, 44 and 45**



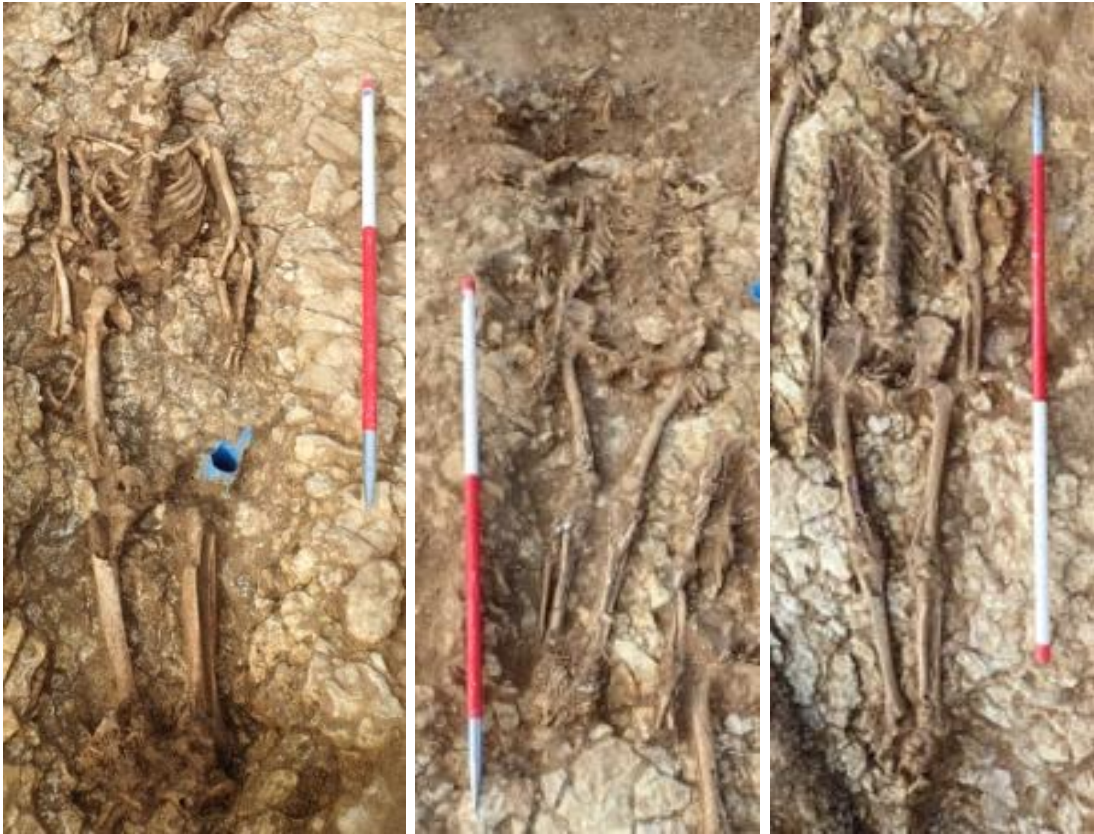**Plate 12: Skeletons 51, 71 and 72**



**Plate 13: Skeletons 76, 78 and 80**



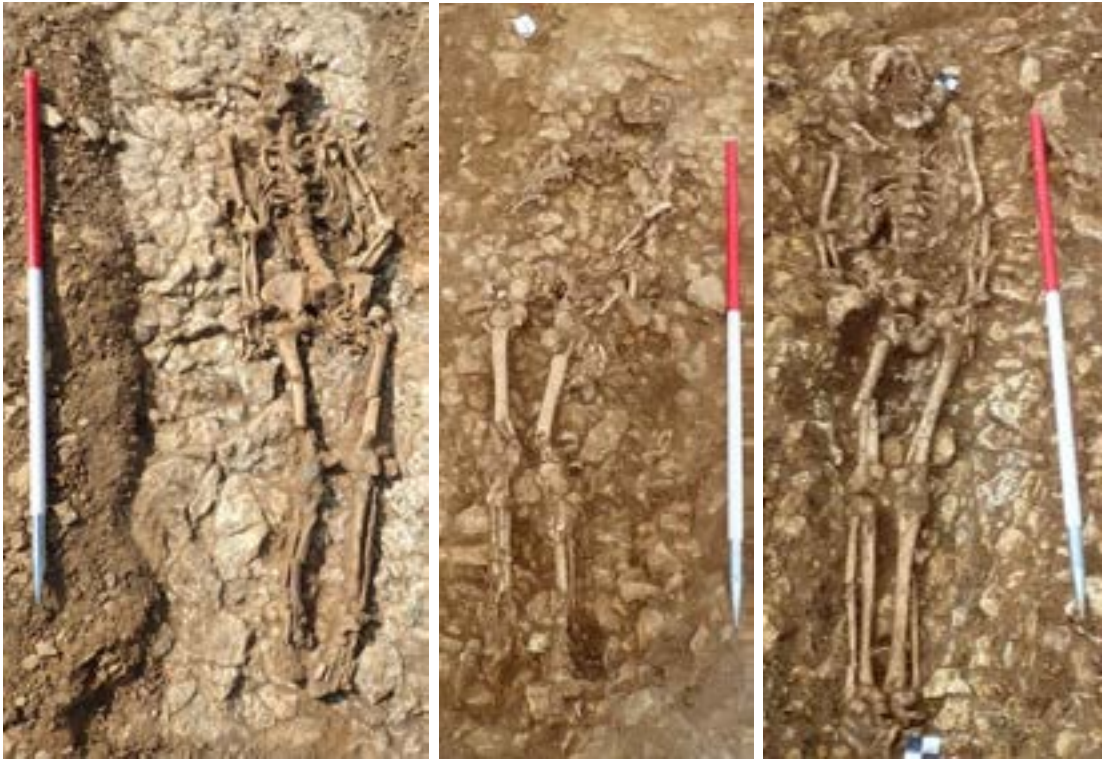**Plate 14: Skeletons 88, 93 and 94**



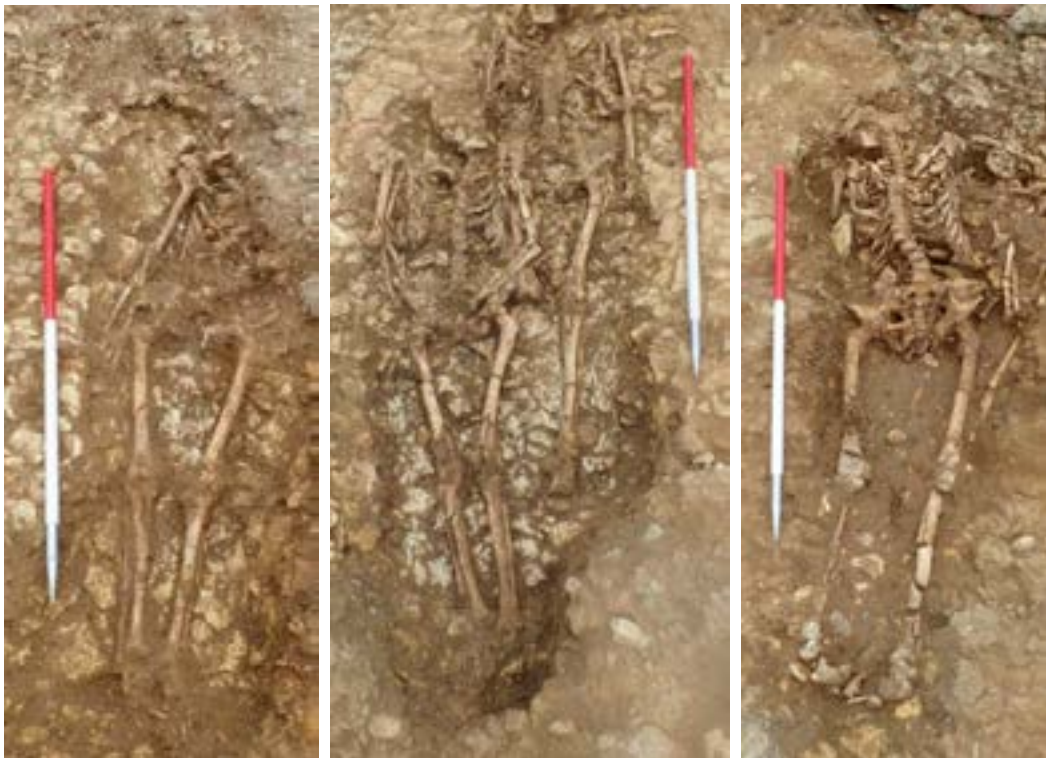**Plate 15: Skeletons 120, 124 and 127**



**Plate 16: Skeletons 132 and 144**



**Plate 17: Skeletons 9, 14 and 69**



**Plate 18: Skeletons 74, 79 and 81**



**Plate 19: Skeletons 97, 104 and 139/140**



**Plate 20: Skeletons 32, 34 and 67**





**Plate 21: Skeleton 137 and 59**

#### 7.5.7 *Evidence for shrouds or clothing*

There is limited evidence to suggest how the burials were clothed prior to interment due to the poor survival of organics at the site.

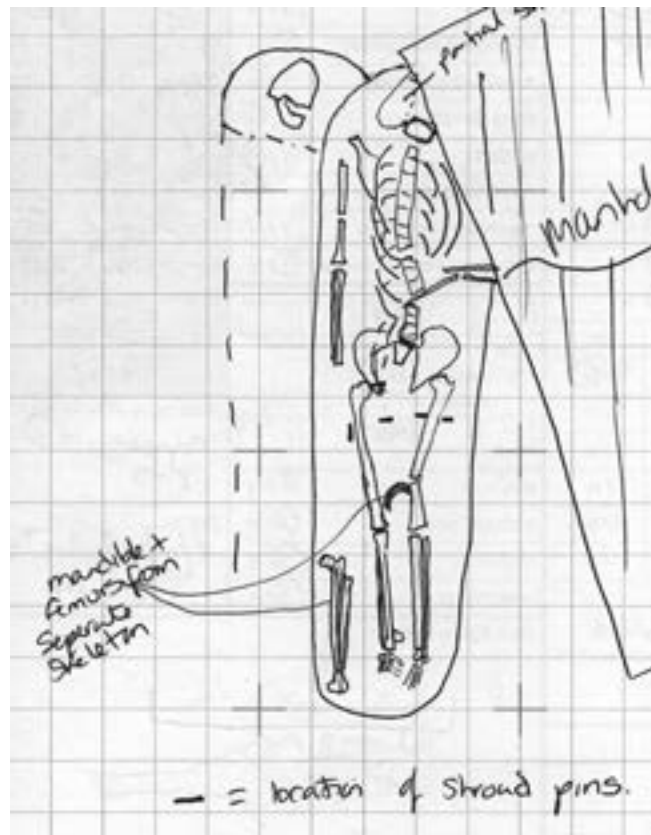
There were seven burials in Phase 2 (Sk 82-3, Sk 87, Sk 93, Sk 101, Sk 132, Sk 139 and Sk 140) with copper alloy lace tags in the grave (Figure 3). These tags may have been for cords to tie a winding sheet or shroud in place.

Sk 93 (Plate 22) was associated with 9 lace tags one of which was located above the sacrum, one above the head of the right femur, and four being in a line across the full width of the body in the area of the upper thigh. The location of the remaining three lace tags in this grave is unclear in the original site records. The lace tag associated with Sk 101 was to the left of the left tibia, while that associated with Sk 139 was located above the left rib cage, and that associated with Sk 140 was to the right of the upper right thigh. In the case of burials Sk 82-3, Sk 87 and Sk 132 the position of the lace tags within the fill was not noted on the original site records.

All of the lace tag fibres that were sent for material analysis were assessed as being leather. This indicates that the copper alloy lace tags were being used to ease the threading, and prevent the fraying, of leather laces. These laces were used for a variety of dress functions from the 15<sup>th</sup> to 17<sup>th</sup> century (Appendix 4).

The copper alloy sheet (Sf 25) was present in the grave fill associated with the Phase 2 burial Sk 132, though its precise position within the grave was not noted at the time of excavation. This may have represented part of a medieval belt fitting or buckle plate, and if so may

indicate that a belt or strap was used to fix a shroud or winding sheet in place, but this could equally represent a stray find.



**Plate 22: Extract from the original context card of Skeleton 93 showing the position of the lace tags (labelled as shroud pins)**

The burial position of Sk 54 (Plate 6) suggests that the burial was bound or tied at the knee prior to burial.

#### 7.5.8 *Burials with associated artefacts*

None of the burials were associated with artefacts. An undatable copper alloy washer (Sf 1) was present in grave fill 842 (associated with Sk 51) but this was presumably an accidental inclusion in the grave.

#### 7.5.9 *The location of male, female and child burials*

There is evidence to suggest that there was an overall bias towards adult males within the burial population with a noticeable increase in that bias during Phase 2. Full details of the sexing and aging analysis form section 8.2

Of the total burial population 109 (83.21%) were adults, 15 (11.45%) were younger adults, while 7 (5.34%) were non-adults (6 were adolescent and 1 was a juvenile). Fifty (40.65%) of the adults and young adults could not be sexed. Of the remainder 53 (43.09%) were male and 20 (16.26%) were female. There does not appear to be any correlation between the sex or age of the individual and the location of their burial within the cemetery (Figure 10).

Twenty-nine (34.94%) of the Phase 1 burials were male (Sk 8, Sk 16, Sk 17, Sk 18, Sk 32, Sk 51, Sk 57, Sk 59, Sk 62, Sk 68, Sk 70, Sk 72, Sk 73, Sk 75, Sk 76, Sk 77, Sk 84, Sk 87, Sk 88, Sk 91, Sk 95, Sk 100, Sk 104, Sk 118, Sk 127, Sk 128, Sk 129, Sk 133 and Sk 134), while 14 (16.87%) were female (Sk 4, Sk 9, Sk 14, Sk 15, Sk 42, Sk 45, Sk 69, Sk 85, Sk 92, Sk 94, Sk 99, Sk 112, Sk 121 and Sk 125) and four (4.82%) were adolescents (Sk 31, Sk 60, Sk 119 and Sk 136). The remaining burials (43.37%) belonging to this phase were unsexed adults. The ratio of males to females, of those that could be sexed, within Phase 1 was in excess of 2:1.

Twenty-four (51.06%) of the Phase 2 burials were male (Sk 7, Sk 34, Sk 37, Sk 67, Sk 71, Sk 78, Sk 79, Sk 81, Sk 82, Sk 86, Sk 89, Sk 90, Sk 93, Sk 96, Sk 97, Sk 101, Sk 103, Sk 116, Sk 120, Sk 135, Sk 137, Sk 139, Sk 140 and Sk 144), while six (12.77%) were female (Sk 23, Sk 24, Sk 44, Sk 56, Sk 83 and Sk 126), two (4.26%) were adolescents (Sk 12 and Sk 98) and one (2.13%) was a young juvenile (Sk 132). The remaining burials (29.78%) belonging to this phase were unsexed adults. The ratio of males to females, of those that could be sexed, within Phase 2 was exactly 4:1.

The vast majority of the disarticulated bone recovered from Midland Road could not be sexed. Of the 3267 fragments, 20 belonged to male individuals and 10 to female individuals. In addition, only 27 fragments and a partially complete Skull were identified as belonging to non-adult individuals. These fragments are discussed further in Appendix 1b.

#### 7.5.10 *The location of burials exhibiting signs of disease, including leprosy*

There are problems with the identification of leprosy in Skeletal material, with the clinical manifestations varying dependent upon the form of leprosy and the resistance of the individual. Full details of the pathological analysis form section 8.3.

Fourteen burials (10.69%) were clearly leprosy, eighteen (13.74%) were probably leprosy, ten (7.63%) were possibly leprosy, forty-four (33.59%) exhibited Skeletal changes caused by non-specific infections and the remaining population of forty-five (34.35%) exhibited no signs of infectious disease (Figure 11).

In total thirty of the burials belonging to Phase 1 exhibited potential signs of leprosy, 36.14% of the Phase 1 population.

In total twelve of the burials belonging to Phase 2 exhibited potential signs of leprosy, 25.54% of the Phase 2 population.

There was no relationship between signs of leprosy and the sex of the individual (with the ratio of leprosy males to females being consistent with the general ratio of males to females in both phases). There was also no relationship between signs of leprosy and the orientation of burials or the presence of coffins.

The leper burials were spread out across the entire cemetery with a greater concentration in the southern two thirds of the exposed area than the northern third of the exposed area. It is not possible, however, to suggest that this was the result of any deliberate strategy due to the generally poor preservation of the human bone, the problems with identifying leprosy and the fact that the full extent of the cemetery was not established.

Rhino-maxillary change was visible in the disarticulated bones recovered from seven contexts, two of which may be associated with articulated Skeletons. Details of these fragments are discussed in Appendix 1b.

In addition to leprosy several other diseases were exhibited within the population at Midland Road. These will be briefly listed here and discussed in more detail in section 8.3.

Exhibiting Skeletal alteration caused by non-specific infection included

- Twenty-four burials (28.92%) of the Phase 1 population (Sk 3, Sk 5, Sk 8, Sk 14, Sk 15, Sk 31, Sk 48, Sk 50, Sk 52, Sk 61, Sk 63, Sk 64, Sk 70, Sk 72, Sk 75, Sk 77, Sk 88, Sk 94, Sk 105, Sk 110, Sk 128, Sk 130, Sk 142 and Sk 143).
- Twenty burials (42.55%) of the Phase 2 population (Sk 24, Sk 34, Sk 37, Sk 40, Sk 44, Sk 47, Sk 56, Sk 79, Sk 81, Sk 83, Sk 101, Sk 102, Sk 103, Sk 109, Sk 122, Sk 123, Sk 126, Sk 132, Sk 135 and Sk 137).

There was no pattern to the burial location of individuals exhibiting signs of non-specific infection.

Exhibiting signs of cribra orbitalia.

- Sk 60 and Sk 85 (Phase 1).
- Sk 57, Sk 78 and Sk 140 (Phase 2).

Exhibiting signs of maxillary sinusitis.

- Sk 18, Sk 45, Sk 69 and Sk 118 (Phase 1).
- Sk 23 and Sk 132 (Phase 2).

Exhibiting signs of respiratory infection.

- Sk 72 (Phase 1) had periosteal lesions on the visceral surfaces of the ribs.

Exhibiting signs of osteomyelitis (independent of leprosy).

- Sk 101 (Phase 2) on their right ulna, right tibiae and right fibula.

Exhibiting signs of periosteal lesions (independent of leprosy).

- Sk 31 and Sk 84 (Phase 1).
- Sk 12, Sk 68, Sk 89 and Sk 98 (Phase 2).

Exhibiting ectocranial and endocranial lesions

- Sk 9, Sk 18, Sk 23, Sk 42 and Sk 68 (Phase 1) also exhibited signs of leprosy.
- Sk 26 and Sk 70 (Phase 1) did not also exhibit signs of leprosy.
- Sk 97 (Phase 2) also exhibited signs of leprosy.
- Sk 93, Sk 96 and Sk 140 (Phase 2) did not also exhibit signs of leprosy.

Due to the low numbers of individuals within the burial population exhibiting signs of other diseases it is not possible to suggest that there is any relationship between an individual's condition and the location of their burial.

### 7.5.11 *The location of burials exhibiting signs of injury and trauma*

There are problems with the identification of injury and trauma in Skeletal material because old and well healed fractures are difficult to identify. There were 22 individuals exhibiting signs of injury and trauma within the population at Midland Road (Figure 12). These will be briefly listed here and discussed in more detail in section 8.3

- Sk 3 (Phase 1) had a possible healed fracture of the midshaft of the right radius.
- Sk 4 (Phase 1) may have had a healed fracture or congenital abnormality of the distal end of their left radius.
- Sk 15 (Phase 1) had a fracture of their right 5<sup>th</sup> metacarpal.
- Sk 16 (Phase 1) had a fracture of their right 5<sup>th</sup> metacarpal.
- Sk 35 (Phase 1) had a well healed fracture on the medial side of the right patella.
- Sk 37 (Phase 2) had a possible healed fracture of their left tibia.
- Sk 42 (Phase 1) had probable compression fractures of their 10<sup>th</sup> and 11<sup>th</sup> thoracic vertebrae.
- Sk 44 (Phase 2) had a possible dislocation of the left proximal ulna.
- Sk 47 (Phase 2) had three rib fractures and three healed rib fractures.
- Sk 48 (Phase 1) had a fracture of their left 5<sup>th</sup> metacarpal.
- Sk 62 (Phase 1) had a fracture of their right proximal 2<sup>nd</sup> hand phalanx.
- Sk 74 (Phase 1) had a poorly healed fracture of the surgical neck of the right humerus, a healed fracture of the right third metacarpal shaft and a probable healed rib fracture.
- Sk 76 (Phase 1) had a possible healed fracture of their right clavicle.
- Sk 82 (Phase 2) had a probable fracture of their 3<sup>rd</sup> sacral body.
- Sk 83 (Phase 2) had a fracture of their right 1<sup>st</sup> proximal foot phalanx.
- Sk 85 (Phase 1) had a possible healed fracture of the right ulna.
- Sk 88 (Phase 1) had five healed rib fractures.
- Sk 89 (Phase 2) had a possible healed fracture of the left clavicle and a possible healed rib fracture.
- Sk 97 (Phase 2) had two healed rib fractures.
- Sk 105 (Phase 1) had a probable compression fracture of their 12<sup>th</sup> thoracic vertebra.
- Sk 127 (Phase 1) had a fracture of their left 2<sup>nd</sup> metacarpal.
- Sk 141 (Phase 1) had a healed fracture of the neck of the left femur.

There is no discernible pattern to the location of the fifteen Phase 1 burials exhibiting signs of injury and trauma within the Midland Road cemetery. The seven Phase 2 burials exhibiting signs of injury and trauma are all located within the southernmost half of the cemetery (Figure 12). Only three of these burials (Sk 62, Sk 89 and Sk 141) had no evidence for infectious disease. In addition, there was no evidence within the burial population for any treatments or surgical practises having taken place.

## 8 THE HUMAN BONES

by Angela Boyle

### 8.1 Introduction

The author was commissioned by York Archaeological Trust (YAT) to carry out the osteological analysis of a human Skeletal assemblage which was excavated in 2014 at the medieval cemetery of St Leonard's leper hospital at Midland Road, Peterborough (NGR TL 18399 99053).

#### 8.1.1 *The cemetery*

The assemblage comprised a total of 133 Skeletons and substantial quantities of disarticulated material. A single Skeleton (Sk 41) could not be located during osteological analysis, while Sk 131 was identified as a disarticulated deposit which contained the remains of multiple individuals, reducing the number of Skeletons analysed to 131. A small feature (905) may have been the grave of an infant, although no bones were recovered.

Overall, the Skeletons were incomplete and severely fragmented but with reasonable preservation of surface details. A small number of Skeletons were more than 81% complete with minimal fragmentation and good preservation of surface detail. Adult males predominated in both phases although a significant number of Skeletons could not be sexed as insufficient diagnostic elements survived. Three Skeletons exhibited contradictory indicators and were classified as indeterminate. There were only seven non-adult Skeletons in the assemblage. There were four adolescents in Phase 1, and two adolescents and a juvenile in Phase 2.

The majority of adults in both phases could only be assigned to the broad adult age category. Most of the adults in Phase 1 that could be more precisely aged were in the prime adult category followed by young adult, older adult and mature adult. In Phase 2, young adults predominated followed by prime adults, then equal numbers of mature and older adults. There is therefore some evidence to suggest that people were dying younger although the numbers are very small.

The incidence of joint disease and osteoarthritis was low in both phases. Limited evidence for trauma including dislocation and spondylolosis was mainly confined to Skeletons from Phase 1. Two probable examples of DISH were identified, one in each phase. A single individual from Phase 1 exhibited evidence of pulmonary infection. Cribra orbitalia was identified in both phases, as was maxillary sinusitis. A clear link between the occurrence of maxillary sinusitis and lepromatous leprosy was identified.

A total of 11 Skeletons from Phase 1 exhibited rhino-maxillary changes consistent with a diagnosis of lepromatous leprosy (CPR 13.25% 11/83; TPR 47.83%, 11/23) compared with a minimum of 3 in Phase 2 (CPR 6.38%, 3/47; TPR 27.27%, 3/11). The diagnosis of a further five Skeletons from Phase 1 and three Skeletons from Phase 2 was problematic and this is discussed in the text. A further four Skeletons in each phase were diagnosed as probable sufferers of leprosy due to the presence of classic features such as claw hand deformity, claw toe deformity, transverse arch collapse, tarsal bars and volar grooves.

Many Skeletons in both phases exhibited non-specific changes which may well have been caused by leprosy, although in the absence of other indicators, it is impossible to prove this.

The analysis was developer-funded and carried out under tight time constraints. Many of the Skeletons were poorly washed which presented difficulties during recording. The archive is to be deposited at the University of Durham where there will be opportunities for the assemblage to fulfil its full potential.

### 8.1.2 *Aims and objectives*

The aims of the osteological analysis were to explore the health and physical attributes of the assemblage and to contextualise the findings by reference to comparative assemblages. The objectives are outlined below:

- to determine the age, sex and stature of the articulated Skeletons
- to undertake metric analysis
- to record the presence of cranial and post-cranial non-metric traits
- to record all evidence for Skeletal and dental pathology
- to provide an inventory of the disarticulated material

### 8.1.3 *Methodology*

All Skeletal material was examined in accordance with national guidelines (Brickley and McKinley 2004; Mays et al. 2004; McKinley 2004). All bones were identified and the part of the bone element that was present was recorded along with surface preservation, completeness and degree of fragmentation for each Skeleton. Information on sex and age was recorded along with Skeletal lesions and dental pathology. Pathological lesions were described by reference to a range of standard texts (e.g. Hillson 1996; Aufderheide and Rodriguez-Martin 1998; Ortner 2003). Metric measurements were taken where possible and a standard range of non-metric traits was recorded. Methods specific to these datasets are described in more detail in the relevant sections below.

## 8.2 **Osteological analysis**

The osteological and palaeopathological data for the articulated Skeletons is summarised by phase in Table 2 below. A detailed Skeletal catalogue forms Appendix 1a. All disarticulated data is located in a table forming part of the digital archive. A summary of this data is presented in Appendix 1b. The data is presented by phase throughout this document with the exception of non-metric traits.

Skeleton No.	Phase	Preservation	Completeness	Fragmentation	Age range	Age category	Sex	Stature (cm)	Dental pathology	Skeletal pathology
3	Phase 1	1	21-40%	Severe	18+ years	adult	?	n/d	one loose tooth, heavy calculus	Extra-spinal JD; non-specific infection; trauma
4	Phase 1	1	0-20%	Severe	18-25 years	young adult	female	n/d	slight periodontal disease, calculus, DEH, dental trauma	Lepromatous leprosy (rhino-maxillary changes); maxillary sinusitis; possible trauma
5	Phase 1	1	41-60%	moderate	45+ years	older adult	?	n/d	calculus, dental trauma, chipped crown, unusual wear pattern	Non-specific infection; extra-spinal JD
8	Phase 1	1	81-100%	moderate	26-35 years	prime adult	male	n/d	moderate periodontal disease, calculus, enamel chipping	SJD; extra-spinal JD; non-specific infection; bony exostosis
9	Phase 1	1	81-100%	slight	26-35 years	prime adult	female	n/d	slight periodontal disease, calculus, caries, DEH, enamel chipping	SJD, extra-spinal JD; extra-spinal OA; ectocranial lesions; osteomyelitis, septic arthritis, probable lepromatous leprosy
10	Phase 1	1	21-40%	extreme	18+ years	adult	?	n/d	calculus	Extra-spinal JD; extra-spinal OA; possible lepromatous leprosy
14	Phase 1	1	21-40%	severe	18+ years	adult	female	n/d	no surviving dentition	SJD; extra-spinal JD; extra-spinal OA; non-specific infection
15	Phase 1	0	61-80%	moderate	18-25 years	young adult	female	n/d	no surviving dentition	Extra-spinal JD; possible trauma; non-specific infection
16	Phase 1	0	81-100%	moderate	45+ years	older adult	male	tibia	AMTL, calculus, abscess	SJD; spinal OA; extra-spinal JD; extra-spinal OA; trauma; lepromatous leprosy (rhino-maxillary changes); septic arthritis



Skeleton No.	Phase	Preservation	Completeness	Fragmentation	Age range	Age category	Sex	Stature (cm)	Dental pathology	Skeletal pathology
17	Phase 1	0	41-60%	moderate	45+ years	older adult	male	n/d	AMTL, calculus, DEH, abscess, periodontal disease	SJD; extra-spinal JD; extra-spinal OA; possible lepromatous leprosy; bony exostoses; septic arthritis
18	Phase 1	0	81-100%	moderate	26-35 years	prime adult	male	n/d	AMTL, calculus, caries, ?root cementosis	SJD; extra-spinal JD; extra-spinal OA; lepromatous leprosy (rhino-maxillary changes); septic arthritis, endocranial lesions
21	Phase 1	2	0-20%	extreme	18+ years	adult	?	n/d	no surviving dentition	Extra-spinal JD; possible lepromatous leprosy; septic arthritis
25	Phase 1	1	41-60%	severe	18-25 years	young adult	?	n/d	calculus	Extra-spinal JD
26	Phase 1	1	0-20%	severe	18+ years	adult	?	n/d	calculus, enamel chipping	Extra-spinal JD; ectocranial lesions
28	Phase 1	1	0-20%	severe	18+ years	adult	?	n/d	no surviving dentition	Extra-spinal OA
30	Phase 1	0	0-20%	severe	18+ years	adult	?	n/d	one loose tooth, flecks of calculus	None
31	Phase 1	0	41-60%	severe	15-16 years	adolescent	n/a	n/a	no surviving dentition	Extra-spinal JD; non-specific infection
32	Phase 1	1	81-100%	severe	36-45 years)	mature adult	male	n/d	periodontal disease, AMTL, calculus, caries,	SJD; extra-spinal JD; extra-spinal OA; possible lepromatous leprosy; septic arthritis
35	Phase 1	1	21-40%	moderate	18+ years	adult	?	n/d	calculus, caries	Extra-spinal JD; extra-spinal OA; trauma; possible lepromatous leprosy; septic arthritis

Skeleton No.	Phase	Preservation	Completeness	Fragmentation	Age range	Age category	Sex	Stature (cm)	Dental pathology	Skeletal pathology
38	Phase 1	1	0-20%	moderate	18+ years	adult	?	n/d	no dentition	Extra-spinal JD; possible lepromatous leprosy; septic arthritis
42	Phase 1	1	81-100%	slight	36-45 years	mature adult	female	n/d	periodontal disease, AMTL, DEH, abscess, enamel chipping	SJD; extra-spinal JD; bony exostosis; ectocranial lesions; ?lepromatous leprosy (possible rhino- maxillary changes)
43	Phase 1	1	61-80%	severe	18+ years	adult	?	n/d	no surviving dentition	Extra-spinal JD; extra- spinal OA; probable lepromatous leprosy, ossified haematoma
45	Phase 1	0	81-100%	moderate	26-35 years	prime adult	female	n/d	calculus, caries, periodontal disease, dental trauma	SJD; extra-spinal JD; extra-spinal OA; lepromatous leprosy (rhino-maxillary changes)
46	Phase 1	1	0-20%	moderate	18+ years	adult	?	n/d	calculus	None
48	Phase 1	2	21-40%	severe	18+ years	adult	?	n/d	no surviving dentition	SJD; Extra-spinal JD; extra-spinal OA; probable trauma; non- specific infection
49	Phase 1	2	0-20%	moderate	18+ years	adult	?	n/d	no surviving dentition	Extra-spinal JD
50	Phase 1	3	0-20%	moderate	18+ years	adult	?	n/d	no surviving dentition	Non-specific infection
51	Phase 1	0	61-80%	moderate	18-25 years	young adult	male	n/d	calculus	Lepromatous leprosy (rhino-maxillary changes), maxillary sinusitis; chronic ulcer
52	Phase 1	1	0-20%	severe	18+ years	adult	?	n/d	no surviving dentition	Non-specific infection
55	Phase 1	1	41-60%	severe	?18+ years	adult	indeterminate	n/d	periodontal disease, AMTL, calculus, caries, enamel chipping	SJD; extra-spinal JD, extra-spinal OA; ?lepromatous leprosy (possible rhino- maxillary changes)

Skeleton No.	Phase	Preservation	Completeness	Fragmentation	Age range	Age category	Sex	Stature (cm)	Dental pathology	Skeletal pathology
57	Phase 1	1	41-60%	severe	18+ years	adult	male	n/d	AMTL, caries, DEH	SJD; extra-spinal JD; extra-spinal OA; trauma, ?lepromatous leprosy (possible rhino-maxillary changes)
58	Phase 1	1	0-20%	severe	18+ years	adult	?	n/d	no surviving dentition	Extra-spinal JD
59	Phase 1	0	81-100%	moderate	18-25 years	young adult	male?	n/d	moderate periodontal disease, calculus, caries	SJD; extra-spinal JD
60	Phase 1	1	61-80%	severe	15-17 years	adolescent	n/a	n/a	calculus	Cribrra orbitalia; possible lepromatous leprosy
61	Phase 1	1	0-20%	moderate	18+ years	adult	?	n/d	no surviving dentition	Extra-spinal JD; non-specific infection
62	Phase 1	0	41-60%	severe	18+ years	adult	male	n/d	1 loose tooth	SJD; extra-spinal JD; spinal OA; extra spinal OA possible trauma
63	Phase 1	0	41-60%	moderate	18+ years	adult	?	n/d	no surviving dentition	SJD; extra-spinal JD; non-specific infection
64	Phase 1	0	0-20%	moderate	18+ years	adult	?	n/d	no surviving dentition	Extra-spinal JD; extra-spinal OA; non-specific infection
66	Phase 1	1	0-20%	severe	?18+ years	adult	?	n/d	no surviving dentition	None
68	Phase 1	1	21-40%	moderate	26-35 years	prime adult	male?	n/d	periodontal disease, AMTL, calculus, caries	SJD; extra-spinal JD; non-specific infection; ?lepromatous leprosy (rhino-maxillary changes), ectocranial lesions
69	Phase 1	0	81-100%	moderate	36-45 years	mature adult	female	n/d	periodontal disease, AMTL, calculus, caries, crowding and rotation	SJD; maxillary sinusitis; leprosy (rhino-maxillary changes)
70	Phase 1	0	41-60%	severe	18+ years	adult	male?	n/d	calculus, chipped enamel, unusual wear pattern	Extra-spinal JD; non-specific infection; endocranial lesions

Skeleton No.	Phase	Preservation	Completeness	Fragmentation	Age range	Age category	Sex	Stature (cm)	Dental pathology	Skeletal pathology
72	Phase 1	0	81-100%	moderate	17-20 years	young adult	male	n/d	periodontal disease, calculus, caries	Extra-spinal JD; bony exostosis; respiratory infection; non-specific infection
73	Phase 1	1	61-80%	severe	18+ years	adult	male	n/d	no surviving dentition	SJD; extra-spinal JD; possible lepromatous leprosy; septic arthritis
74	Phase 1	1	81-100%	moderate	18+ years	adult	?	n/d	AMTL, calculus, caries, abscess, considerable periodontal disease	SJD; spinal OA; extra-spinal JD; extra-spinal OA; trauma; possible lepromatous leprosy; septic arthritis
75	Phase 1	1	21-40%	severe	18+ years	adult	male	n/d	caries	SJD; extra-spinal JD; non-specific infection
76	Phase 1	0	81-100%	moderate	36-45 years	mature adult	male	n/d	slight periodontal disease, calculus, enamel chipping	SJD; extra-spinal OA, extra-spinal OA; lepromatous leprosy (rhino-maxillary changes) possible osteomyelitis
77	Phase 1	1	21-40%	moderate	18+ years	adult	?	n/d	no surviving dentition	Extra-spinal JD; non-specific infection; chronic ulcer
80	Phase 1	0	81-100%	moderate	26-35 years	prime adult	indeterminate	n/d	periodontal disease, calculus, enamel chipping	SJD; extra-spinal JD; lepromatous leprosy (rhino-maxillary changes), osteomyelitis
84	Phase 1	1	81-100%	moderate	26-35 years	prime adult	male	n/d	periodontal disease, AMTL, calculus, caries,	Extra-spinal JD; extra-spinal OA; possible Perthes disease; ?lepromatous leprosy (rhino-maxillary changes); chronic ulcers

Skeleton No.	Phase	Preservation	Completeness	Fragmentation	Age range	Age category	Sex	Stature (cm)	Dental pathology	Skeletal pathology
85	Phase 1	1	21-40%	severe	26-35 years	prime adult	female	n/d	considerable periodontal disease, AMTL, calculus, caries, DEH, abscess, abscess, enamel chipping	SJD; extra-spinal JD; cribra orbitalia; possible trauma; bony exostoses; lepromatous leprosy (rhino-maxillary changes)
87	Phase 1	1	21-40%	severe	45+ years	older adult	male?	n/d	AMTL, calculus, caries, periodontal disease	SJD
88	Phase 1	0	81-100%	moderate	18+ years	adult	male	n/d	Considerable periodontal disease, AMTL, DEH	SJD; extra-spinal JD; extra-spinal OA; bony exostosis, non-specific infection
91	Phase 1	0	0-20%	severe	26-35 years	prime adult	male	n/d	periodontal disease, AMTL, calculus, caries,	SJD; extra-spinal OA; ?lepromatous leprosy (rhino-maxillary changes)
92	Phase 1	0	21-40%	moderate	18+ years	adult	female?	n/d	no surviving dentition	SJD; extra-spinal JD
94	Phase 1	0	61-80%	severe	26-35 years	prime adult	female?	n/d	calculus, caries, periodontal disease, dental trauma	SJD; extra-spinal JD; non-specific infection
95	Phase 1	1	0-20%	severe	26-35 years	prime adult	male	n/d	moderate periodontal disease	SJD
99	Phase 1	0	21-40%	moderate	18+ years	adult	female	n/d	no surviving dentition	SJD
100	Phase 1	2	21-40%	severe	18+ years	adult	male?	n/d	no surviving dentition	SJD; extra-spinal OA
104	Phase 1	0	61-80%	moderate	26-35 years	prime adult	male	n/d	no surviving dentition	SJD; extra-spinal JD; probable lepromatous leprosy; septic arthritis
105	Phase 1	0	0-20%	moderate	18+ years	adult	?	n/d	no surviving dentition	SJD; extra-spinal JD; extra-spinal OA; trauma; non-specific infection
106	Phase 1	0	0-20%	moderate	18+ years	adult	?	n/d	no surviving dentition	Extra-spinal JD

Skeleton No.	Phase	Preservation	Completeness	Fragmentation	Age range	Age category	Sex	Stature (cm)	Dental pathology	Skeletal pathology
108	Phase 1	1	0-20%	severe	18+ years	adult	?	n/d	no surviving dentition	Bony exostosis
110	Phase 1	1	21-40%	moderate	18+ years	adult	?	n/d	no surviving dentition	Extra-spinal JD; non-specific infection; septic arthritis
111	Phase 1	1	0-20%	moderate	18+ years	adult	?	n/d	calculus	Extra-spinal JD
112	Phase 1	1	41-60%	moderate	25-35 years	prime adult	female	n/d	moderate periodontal disease, calculus, dental chipping, 2 microdontic premolars with bent roots	SJD; extra—spinal JD; probable lepromatous leprosy; volar grooves; septic arthritis
113	Phase 1	0	21-40%	severe	18+ years	adult	male?	n/d	no surviving dentition	Extra-spinal JD; extra-spinal OA
115	Phase 1	1	0-20%	moderate	18+ years	adult	?	n/d	no surviving dentition	None
118	Phase 1	1	0-20%	severe	18-25 years	young adult	male?	n/d	AMTL	SJD; maxillary sinusitis; ?lepromatous leprosy (rhino-maxillary changes)
119	Phase 1	1	0-20%	severe	16-18 years	adolescent	?	n/d	no surviving dentition	None
121	Phase 1	1	0-20%	severe	26-35 years	prime adult	female?	n/d	AMTL, considerable periodontal disease, calculus, caries,	SJD; extra-spinal JD; spinal OA
125	Phase 1	0	0-20%	severe	18-25 years	young adult	female	n/d	calculus, caries	SJD
127	Phase 1	2	61-80%	severe	18+ years	adult	male?	n/d	calculus, caries, abscess	SJD, extra-spinal JD; extra-spinal OA; trauma; DISH
128	Phase 1	1	61-80%	extreme	26-35 years	prime adult	male	n/d	calculus, caries, moderate periodontal disease, dental trauma	SJD; extra-spinal JD; extra-spinal OA; non-specific infection
129	Phase 1	1	0-20%	severe	26-35 years	prime adult	male	n/d	no surviving dentition	SJD; extra-spinal JD
130	Phase 1	2	0-20%	severe	18+ years	adult	?	n/d	2 loose teeth, calculus	SJD; non-specific infection

Skeleton No.	Phase	Preservation	Completeness	Fragmentation	Age range	Age category	Sex	Stature (cm)	Dental pathology	Skeletal pathology
133	Phase 1	0	21-40%	severe	18-25 years	young adult	male?	n/d	1 loose tooth	None
134	Phase 1	0	0-20%	severe	18+ years	adult	male	n/d	no surviving dentition	SJD; extra-spinal JD
136	Phase 1	0	21-40%	slight	13-17 years	adolescent	n/a	n/a	no surviving dentition	Probable lepromatous leprosy; osteomyelitis, septic arthritis, chronic ulcer; claw toe deformity
138	Phase 1	0	0-20%	severe	18+ years	adult	?	n/d	no surviving dentition	Extra-spinal JD
141	Phase 1	1	21-40%	moderate	18+ years	adult	?	n/d	No surviving dentition	SJD; extra-spinal JD, extra-spinal OA; trauma
142	Phase 1	1	21-40%	severe	18+ years	adult	?	n/d	no surviving dentition	SJD; extra-spinal JD; non-specific infection
143	Phase 1	1	41-60%	severe	45+ years	older adult	?	n/d	moderate periodontal disease, calculus, unusual wear pattern	SJD; extra-spinal JD; non-specific infection
1	Phase 2	2	0-20%	moderate	18+ years	adult	?	n/d	no surviving dentition	Extra-spinal JD; extra-spinal OA; probable lepromatous leprosy; septic arthritis, possible transverse arch collapse
6	Phase 2	1	41-60%	moderate	18+ years	adult	?	n/d	no surviving dentition	SJD; extra-spinal JD; extra-spinal OA; non-specific infection
7	Phase 2	0	41-60%	severe	18+ years	adult	male	n/d	no surviving dentition	SJD; extra-spinal JD; extra-spinal OA; probable lepromatous leprosy; septic arthritis

Skeleton No.	Phase	Preservation	Completeness	Fragmentation	Age range	Age category	Sex	Stature (cm)	Dental pathology	Skeletal pathology
12	Phase 2	0	61-80%	slight	16-17 years	adolescent	n/a	n/a	no surviving dentition	SJD; probable lepromatous leprosy; septic arthritis; osteomyelitis; chronic ulcer or ossified haematoma; claw toe deformity
23	Phase 2	0	81-100%	moderate	36-45 years	mature adult	female	n/d	periodontal disease, AMTL, calculus, DEH, enamel chipping	SJD; extra-spinal JD; maxillary sinusitis; lepromatous leprosy (rhino-maxillary changes); ectocranial lesions
24	Phase 2	0	81-100%	moderate	36-45 years	mature adult	female	n/d	periodontal disease, AMTL, calculus, DEH, enamel chipping	Extra-spinal JD; non-specific infection
33	Phase 2	1	21-40%	severe	26-35 years	adult	indeterminate	n/d	moderate periodontal disease, AMTL, calculus, caries	SJD; extra-spinal JD
34	Phase 2	1	81-100%	severe	18+ years	adult	male?	n/d	periodontal disease, AMTL, calculus, caries, enamel chipping	SJD; extra-spinal JD; extra-spinal OA; non-specific infection
36	Phase 2	1	21-40%	severe	18+ years	adult	?	n/d	no surviving dentition	Probable lepromatous leprosy; septic arthritis
37	Phase 2	0	61-80%	severe	18+ years	adult	male	n/d	calculus, caries	SJD; extra-spinal JD; extra-spinal OA; non-specific infection, possible trauma
40	Phase 2	0	41-60%	moderate	18+ years	adult	?	n/d	no surviving dentition	SJD; extra-spinal JD; non-specific infection
44	Phase 2	1	61-80%	moderate	18-25 years	young adult	female?	n/d	calculus, caries, enamel chipping	JD; extra-spinal OA; dislocation; non-specific infection
47	Phase 2	1	41-60%	moderate	18+ years	adult	?	n/d	no surviving dentition	SJD; extra-spinal OA; trauma, non-specific infection
54	Phase 2	2	21-40%	extreme	18+ years	adult	?	n/d	no surviving dentition	SJD; extra-spinal JD; spinal OA



Skeleton No.	Phase	Preservation	Completeness	Fragmentation	Age range	Age category	Sex	Stature (cm)	Dental pathology	Skeletal pathology
56	Phase 2	0	41-60%	severe	18+ years	adult	female	n/d	AMTL, calculus, caries, DEH, periodontal disease	SJD; extra-spinal JD, spinal OA; cribra orbitalia; non-specific infection
67	Phase 2	0	81-100%	severe	36-45 years	mature adult	male	n/d	AMTL, calculus	SJD; extra-spinal JD; infection; ?lepromatous leprosy
71	Phase 2	1	81-100%	moderate	18+ years	adult	male	n/d	periodontal disease, calculus	SJD; extra-spinal JD; probable ossified haematoma; possible lepromatous leprosy
78	Phase 2	1	41-60%	severe	45+ years	older adult	male	n/d	periodontal disease, calculus, abscess, unusual wear pattern	SJD; extra-spinal JD; cribra orbitalia; non-specific infection; lepromatous leprosy (rhino-maxillary changes)
79	Phase 2	1	81-100%	moderate	18+ years	adult	male?	n/d	moderate periodontal disease, calculus	SJD; extra-spinal JD; non-specific infection
81	Phase 2	0	81-100%	moderate	26-35 years	prime adult	male	n/d	AMTL, calculus, DEH, periodontal disease	SJD; extra-spinal OA; non-specific infection
82	Phase 2	1	81-100%	slight	18-25 years	young adult	male?	n/d	calculus, DEH, dental trauma	Extra-spinal JD; trauma; lepromatous leprosy (rhino-maxillary changes)
83	Phase 2	0	41-60%	moderate	26-35 years	prime adult	female	n/d	slight periodontal disease, calculus, caries	Non-specific infection; possible trauma
86	Phase 2	0	41-60%	moderate	26-35 years	prime adult	male	n/d	slight periodontal disease, AMTL, calculus, caries, abscess, enamel chipping	SJD; extra-spinal JD; non-specific infection
89	Phase 2	0	21-40%	moderate	26-35 years	prime adult	male	180.714 +/- 4.05 cm	calculus, caries, DEH, periodontal disease	SJD; extra-spinal JD; trauma; non-specific infection
90	Phase 2	1	0-20%	moderate	26-35 years	prime adult	male	n/d	calculus, caries, DEH, retention of deciduous root	SJD; extra-spinal JD

Skeleton No.	Phase	Preservation	Completeness	Fragmentation	Age range	Age category	Sex	Stature (cm)	Dental pathology	Skeletal pathology
93	Phase 2	0	81-100%	moderate	18-25 years	young adult	male	n/d	slight periodontal disease, calculus	Extra-spinal JD; ectocranial lesions
96	Phase 2	1	21-40%	moderate	18-25 years	young adult	male	n/d	considerable periodontal disease, AMTL, calculus, caries, DEH	Extra-spinal JD
97	Phase 2	1	81-100%	moderate	18+ years	adult	male	n/d	considerable periodontal disease, AMTL, calculus, caries, DEH	SJD; extra-spinal JD; spinal OA; extra-spinal OA; trauma; lepromatous leprosy (rhino-maxillary changes); ectocranial lesions; chronic ulcer
98	Phase 2	1	21-40%	moderate	13-17 years	adolescent	n/a	n/a	no surviving dentition	Non-specific infection
101	Phase 2	0	0-20%	severe	18+ years	adult	male?	n/d	no surviving dentition	Extra-spinal JD; osteomyelitis; non-specific infection
102	Phase 2	1	41-60%	moderate	18-25 years	young adult	?	n/d	no surviving dentition	Non-specific infection; trauma
103	Phase 2	0	21-40%	moderate	18+ years	adult	male	n/d	no surviving dentition	Extra-spinal JD; non-specific infection
107	Phase 2	1	0-20%	moderate	18+ years	adult	?	n/d	no surviving dentition	Extra-spinal JD
109	Phase 2	0	0-20%	moderate	18+ years	adult	?	n/d	no surviving dentition	Extra-spinal JD; non-specific infection
114	Phase 2	0	0-20%	moderate	18+ years	adult	?	n/d	no surviving dentition	Extra-spinal JD
116	Phase 2	1	21-40%	moderate	18+ years	adult	male?	n/d	3 loose teeth, calculus, DEH	Extra-spinal JD
120	Phase 2	1	81-100%	slight	45+ years	older adult	male	n/d	AMTL, calculus, caries, abscess, periodontal disease, unusual wear pattern	SJD; extra-spinal JD; spinal OA, ?lepromatous leprosy (possible rhino-maxillary changes)
122	Phase 2	2	21-40%	severe	18+ years	adult	?	n/d	no surviving dentition	Extra-spinal JD; non-specific infection

Skeleton No.	Phase	Preservation	Completeness	Fragmentation	Age range	Age category	Sex	Stature (cm)	Dental pathology	Skeletal pathology
123	Phase 2	1	0-20%	severe	18+ years	adult	?	n/d	no surviving dentition	Non-specific infection; septic arthritis
124	Phase 2	1	41-60%	extreme	18+ years	adult	?	n/d	periodontal disease, calculus	SJD; extra-spinal JD; spinal OA
126	Phase 2	1	41-60%	moderate	45+ years	older adult	female	n/d	no surviving dentition	SJD; extra-spinal JD; non-specific infection
132	Phase 2	0	61-80%	severe	3-5 years	younger juvenile	n/a	n/a	calculus	Non-specific infection; maxillary sinusitis
135	Phase 2	0	21-40%	severe	18+ years	adult	male	n/d	caries	SJD; extra-spinal JD; non-specific infection
137	Phase 2	1	61-80%	moderate	18+ years	adult	male	n/d	no surviving dentition	SJD; extra-spinal JD, extra-spinal OA; non-specific infection; septic arthritis
139	Phase 2	1	41-60%	moderate	18+ years	adult	male	n/d	2 loose teeth, calculus	SJD; extra-spinal JD
140	Phase 2	0	21-40%	moderate	18-20 years	young adult	male	n/d	calculus, DEH, slight periodontal disease	Cribrum orbitale; ectocranial lesions
144	Phase 2	1	61-80%	severe	18+ years	adult	male	n/d	no surviving dentition	SJD; extra-spinal JD; extra-spinal OA; DISH; probable lepromatous leprosy; septic arthritis, claw toe deformity, bony exostosis
39	unphased	1	0-20%	severe	18+ years	adult	?	n/d	no surviving dentition	SJD; extra-spinal JD

**Table 2: Summary of osteological and palaeopathological data**

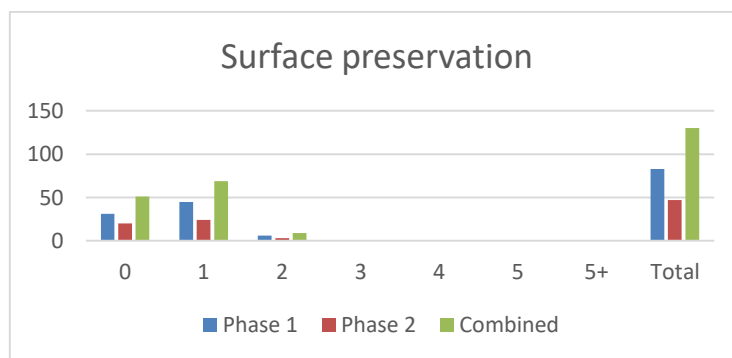
8.2.1 Surface preservation

Surface preservation was recorded by reference to the scoring criteria of McKinley (2004, 16) which are summarised in Table 3.

Score	Scoring criteria
0	Surface morphology clearly visible with fresh appearance to bone and no modification
1	Slight and patchy surface erosion
2	More extensive erosion of surface
3	Most of the bone surface affected by some degree of erosion, general morphology maintained but detail of parts of surface masked by erosive action
4	All of bone surface affected by erosive action; general profile maintained and depth of modification not visible across the whole surface
5	Heavy erosion across whole surface, completely masking normal surface morphology with some modification of profile
5+	As for grade 5 with extensive penetrating erosion resulting in modification of profile (includes near destroyed bone)

**Table 3: Scoring criteria for Skeletal condition (surface preservation) (after McKinley 2004, 16)**

Assessment of preservation considers the severity of erosion/abrasion to bone surfaces but does not consider completeness. Surface preservation can have an impact on both the quality and the quantity of information that can be recovered. The scores for the assemblage are presented in Graph 1 and Table 4 below. Where surface preservation was variable throughout an individual Skeleton, the condition of most of the Skeleton was taken as the preservation grade for the entire Skeleton.



**Graph 1: Surface preservation**

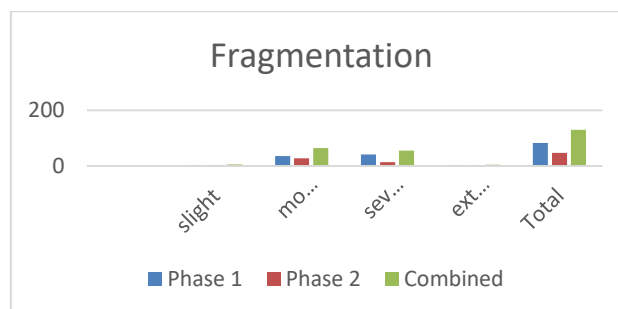
Most Skeletons in both phases were scored as 0 or 1, with a few as 2 or 3. There was little variation between phases. A detailed breakdown appears in Table 4 below. Unphased Sk 39 was categorised as 1.

Degree of preservation	Phase 1	Phase 2	Combined
0	31 (37.35%)	20 (42.55%)	51 (39.23%)
1	45 (54.22%)	24 (51.06%)	69 (53.08%)
2	6 (7.23%)	3 (6.38%)	9 (6.92%)
3	1 (1.2%)	0	1 (1.2%)
4	0	0	0
5	0	0	0
5+	0	0	0
Total	83 (63.85%)	47 (36.15%)	130

**Table 4: Surface preservation expressed as a percentage.**

### 8.2.2 Fragmentation

Five categories were used for scoring the degree of fragmentation of the Skeletons, ranging from minimal (little or no fragmentation) through to extreme, i.e. extensive fragmentation with bones in multiple small fragments (see Graph 2 and Table 5 below). Most of the assemblage across both phases were classified as moderately or severely fragmented. The fact that stature could only be calculated for a total of five adults is a good indicator of the general degree of fragmentation. Unphased Sk 39 was severely fragmented.



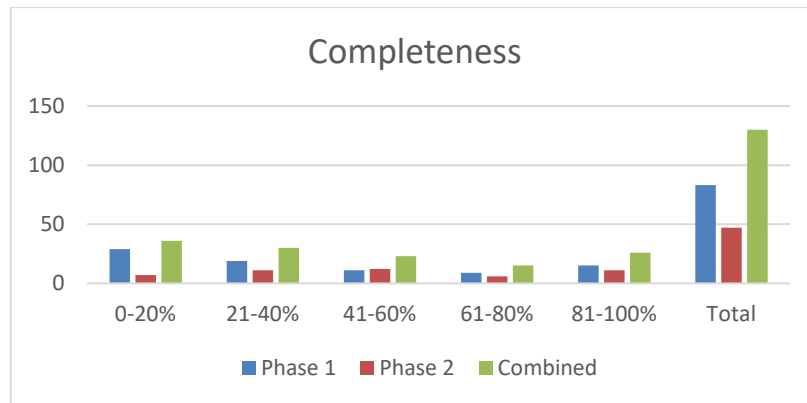
**Graph 2: Fragmentation**

Fragmentation	Phase 1	Phase 2	Combined
minimal	0 (0%)	0 (0%)	0 (0%)
slight	3 (3.61%)	3 (6.38%)	6 (4.62%)
moderate	36 (43.37%)	28 (59.57%)	64 (49.23%)
severe	41 (49.39%)	14 (29.79%)	55 (42.31%)
extreme	3 (3.61%)	2 (4.26%)	5 (3.85%)
Total	83	47	130

**Table 5: Fragmentation expressed as a percentage**

### 8.2.3 Completeness

Completeness of individual Skeletons was expressed as a percentage: 0-20%, 21-40%, 41-60%, 61-80% and 81-100% (see Graph 3 and Table 6 below).



**Graph 3: Completeness expressed as a percentage**

Completeness	Phase 1	Phase 2	Combined
0-20%	29 (34.94%)	7 (14.89%)	36 (27.69%)
21-40%	19 (22.89%)	11 (23.40%)	30 (23.08%)
41-60%	11 (13.25%)	12 (25.53%)	23 (17.69%)
61-80%	9 (10.84%)	6 (12.77%)	15 (11.54%)
81-100%	15 (18.07%)	11 (23.40%)	26 (20%)
Total	83	47	130

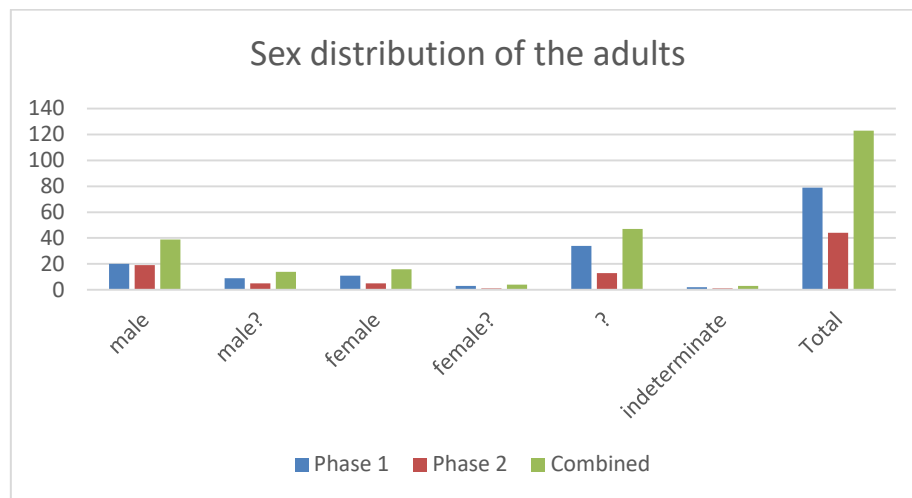
**Table 6: Completeness**

Just over half of the Skeletons in both phases were less than 40% complete while only 26 Skeletons (20%) were 81-100% complete. Sk 39 fell into the least complete category. Completeness of Skeletons has obvious implications for the level of information that can be recovered, particularly when combined with the general level of fragmentation. Reasonable surface preservation, however, enabled the observation of subtle changes such as abnormal porosity.

### 8.2.4 Sex determination

Sex determination was carried out using standard osteological techniques for assessment of the pelvis and the Skull (Buikstra and Ubelaker 1994). Greater weight is assigned to the pelvis as its features are more sexually dimorphic from an earlier age than those of the Skull. The development of features of the Skull is highly dependent upon when puberty occurs and may be influenced by genetics, cultural practices and disease, among other factors (Cox and Mays 2000). An individual exhibiting female Skull characteristics and male pelvic characteristics is not unusual (Walker 1995). Metric measurements were used where possible to supplement assessment of the Skull and pelvis (Bass 1987). Skeletons were

assigned to one of the following categories: male, male?, unsexed, female?, female, and indeterminate. The sex distribution of the adults appears in Graph 4 and Table 7 below.



**Graph 4: Sex distribution of the adults**

Sex	Phase 1	Phase 2	Combined
male	20 (25.32%)	19 (43.18%)	39 (31.71%)
male?	9 (11.39%)	5 (11.36%)	14 (11.38%)
female	11 (13.92%)	5 (11.36%)	16 (13.00%)
female?	3 (3.79%)	1 (2.27%)	4 (3.25%)
?	34 (43.04%)	13 (29.55%)	47 (38.21%)
indeterminate	2 (2.53%)	1 (2.27%)	3 (2.44%)
Total	79	44	123

**Table 7: Sex distribution of the adults**

Males predominated in both phases: there were 29 males or probable males in Phase 1 (36.71%) and 24 in Phase 2 (54.55%) with a combined total of 53 (43.09%); 14 females or probable females were identified in Phase 1 (17.72%) with 6 in Phase 2 (13.64%). This may, however, not be significant when balanced against the number of unsexed individuals in both phases (Phase 1: 34, 43.04%; Phase 2: 13, 29.55%).

#### 8.2.5 Assessment of age

Standard methods for estimating age at death of adult Skeletons refer to degeneration and remodelling of the auricular surface of the ilium (Lovejoy et al. 1985) and the pubic symphysis (Brooks and Suchey 1990), dental attrition (Miles 1962; Brothwell 1981) and rib end morphology (Iskan et al. 1984; Iskan and Loth 1988). In addition, observations relating to late fusing epiphyses are used to age younger adults (Scheuer and Black 2000a and b). In this assemblage most auricular surfaces, pubic symphyses and sternal rib ends had not survived so age estimation was based on dental attrition and/or the final stages of Skeletal fusion.

Age estimation of non-adult Skeletons was based on stages of dental development (Moorrees et al. 1963a, 1963b), dental eruption (Ubelaker 1989), measurements of long bones and other relevant Skeletal elements and epiphyseal fusion (Scheuer and Black 2000a; 2000b; Schaefer et al. 2008).

Non-adult age categories comprised foetus (f: below 38-40 weeks in utero), neonate (N - birth to 1 month), infant (I - 1 to 12 months), younger juvenile (YJ – 1 to 6 years), older juvenile (OJ – 7 to 12 years) and adolescent (A – 13 to 17 years). Adults were assigned to one of the following categories: young adult (YA – 18 to 25 years), prime adult (PA – 26 to 35 years), mature adult (MA – 36 to 45 years), and older adult (OA – 45+ years). A category of adult (A) was assigned to adult Skeletons who could not be more precisely aged than 18 years or older. A category of non-adult was assigned to Skeletons who could not be more precisely aged than less than 18 years (NA).

Age group	Male	%	Female	%	Un-sexed	%	Indeterminate	%	Total	%
YA	5	6.33	3	3.79	1	1.27	0	0	9	11.39
PA	9	11.39	6	7.59	0	0	1	1.27	16	20.25
MA	2	2.53	2	2.53	0	0	0	0	4	5.06
OA	3	3.79	0	0	2	2.53	0	0	5	6.33
A	10	12.66	3	3.79	31	39.24	0	0	44	55.69
A?	0	0	0	0	0	0	1	1.27	1	1.27
Total	29	36.71	14	17.72	34	43.04	2	2.53	79	

**Table 8: Combined adult age and sex distribution, Phase 1**

Key: ya = young adult (18-25 years); pa = prime adult (26-35 years); mature adult (36-45 years); oa = older adult (45+ years); a = adult (18+ years); a? (?18+ years).

Age group	Male	%	Female	%	Un-sexed	%	Indeterminate	%	Total	%
YA	4	9.09	1	2.27	1	2.27	0	0	6	13.64
PA	4	9.09	1	2.27	0	0	0	0	5	11.36
MA	1	4.54	2	2.27	0	0	0	0	3	6.82
OA	2	4.54	1	2.27	0	0	0	0	3	6.82
A	13	29.54	1	2.27	12	27.27	1	2.27	27	61.36
A?	0	0	0	0	0	0	0	0	0	0
Total	24	56.82	6	11.36	13	29.55	1	2.27	44	

**Table 9: Combined adult age and sex distribution, Phase 2**

Key: ya = young adult (18-25 years); pa = prime adult (26-35 years); mature adult (36-45 years); oa = older adult (45+ years); a = adult (18+ years); a? (?18+ years).

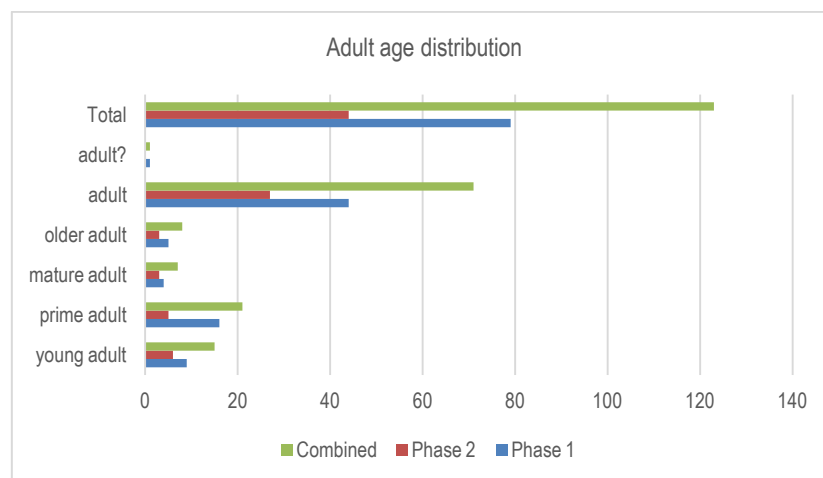


Age group	Male	%	Female	%	Un-sexed	%	Indeterminate	%	Total	%
YA	9	7.32	4	3.25	2	1.63	0	0	15	12.19
PA	13	10.57	7	5.69	0	0	1	0.81	21	17.07
MA	3	3.25	4	2.44	0	0	0	0	7	5.69
OA	5	4.07	1	0.81	2	1.63	0	0	8	6.50
A	23	18.69	4	3.25	43	34.96	1	0.81	71	57.72
A?	0	0	0	0	0	0	1	0.81	1	0.81
Total	53	43.90	20	15.45	47	38.21	3	2.44	123	

**Table 10: Combined adult age and sex distribution, both phases**

Key: ya = young adult (18-25 years); pa = prime adult (26-35 years); mature adult (36-45 years); oa = older adult (45+ years); a = adult (18+ years); a? (?18+ years).

The majority of adults in both phases could only be assigned to the broad adult age category. Most of the adults in Phase 1 that could be more precisely aged were in the prime adult category followed by young adult, older adult and mature adult. In Phase 2, young adults predominated followed by prime adults, then equal numbers of mature and older adults. There is therefore some evidence to suggest that people were dying younger although the number is very small.



**Graph 5: Adult male and female age distribution**

Only seven non-adults were present within the assemblage (5.38%). There was one younger juvenile (2-6 years) and six adolescents (13-17 years). Four adolescents were present in Phase 1 (Sk 31, Sk 60, Sk 119 and Sk 136, CPR 4.82%, 4/83) while one younger juvenile (Sk 132) and two adolescents (Sk 12 and Sk 98) were identified in Phase 2 (CPR 6.38%, 3/47).

## 8.2.6 Metric analysis

### 8.2.6.1 Stature

Stature was calculated using the regression formula developed by reference to adults of known stature (Trotter 1970). Due to the degree of fragmentation and completeness it was only possible to estimate stature for a total of five of the adult Skeletons (Phase 1, Sk 16, Sk 32 and Sk 45; Phase 2, Sk 82 and Sk 89). Very few complete long bones survived. Reconstruction for measurements of long bone length was not attempted as in many cases the breaks were not recent and therefore the edges were eroded. The data is presented in Table 11 below.

	Number			Range	
Sex	(n)	(%)	Mean	Min.	Max.
Male	4	7.41	174.71 (5'7")	167.08 (5'5")	180.71 (5'9")
Female	1	5.26	170.92 (5'6")	170.92	170.92

**Table 11: Stature**

### 8.2.6.2 Platymeric and platycnemic indices

Leg measurements taken from the femora and tibiae were used to calculate the platymeric index (degree of flattening of the femur shaft front to back) and the platycnemic index (degree of medio-lateral flattening of the tibia shaft). Generally speaking, femur and tibia shafts have become rounded (meric and cnemic) over time, possibly due to an increasingly sedentary lifestyle (Wells 1964, 32; Brothwell 1981). However, the relationship between mechanical stress and flattening is far from clear and there could be other causes, such as mineral and vitamin deficiency (Waldron 2007).

The degree of fragmentation and level of completeness meant that few measurements could be taken. The majority of the femora in Phase 1 fell into the platymeric or broad and flat category (27, 62.79%) followed by the eurymeric or rounded range (16, 37.21%). There were no stenomeric femora in Phase 1. The mean meric index was higher for males than females on both the right and left side.

Sex	Right			Left		
	Mean	Range		Mean	Range	
		Min.	Max.		Min.	Max.
Male	81.24 (n=10)	70.74	91.53	83.18 (n=7)	77.11	94.74
Female	75 (n=7)	63.01	87.14	77.98 (n=6)	73.02	91.03
Un-sexed	69.97 (n=7)	68.96	95.86	87.79 (n=6)	79.82	96.93
Indeterminate				72.01 (n=1)	72.01	72.01

**Table 12: Meric index - range and mean, Phase 1**

	Male		Female		Unsexed		Indeterminate		Total	
	Right	Left	Right	Left	Right	Left	Right	Left	Right	Left
Platymeric	6	5	5	5	4	2	0	1	15	12
Eurymeric	4	2	2	1	3	4	0	0	9	7
Stenomic	0	0	0	0	0	0	0	0	0	0

**Table 13: Meric index - number of femora in each category, Phase 1**

Sex	Right			Left		
	Mean	Range		Mean	Range	
		Min.	Max.		Min.	Max.
Male	81.11 (n=11)	69.32	94.65	80.15 (n=10)	68.76	96.37
Female	82.03 (n=1)	82.03	82.03	86.79 (n=2)	79.04	94.53
Un-sexed	81.81 (n=2)	77.79	85.83	79.08 (n=1)	79.08	79.08

**Table 14: Meric index - range and mean, Phase 2**

In Phase 2 the majority of femora also fell into the platymeric (broad and flat) category followed by eurymeric (rounded), with no stenomic (very rounded) examples.

	Male		Female		Unsexed		Total	
	Right	Left	Right	Left	Right	Left	Right	Left
Platymeric	8	8	1	1	0	1	9	10
Eurymeric	3	2	0	1	1	0	4	3
Stenomic	0	0	0	0	0	0	0	0

**Table 15: Metric index - number of femora in each category, Phase 2**

Most tibiae in Phase 1 were mesocnemic (average) while in Phase 2 most were eurycnemic (broad), although the number of bones that could be measured is very small.

Sex	Right			Left		
	Mean	Range		Mean	Range	
		Min.	Max.		Min.	Max.
Male	70.31 (n=6)	64.65	78.68	73.75 (n=7)	63.99	88.5
Female	71.91 (n=3)	62.74	80.74	65.58 (n=2)	61.17	69.99
Un-sexed	66.98 (n=7)	57.22	75.25	66.98 (n=6)	59.32	72.01

**Table 16: Cnemic index - range and mean, Phase 1**

	Male		Female		Unsexed		Total	
	Right	Left	Right	Left	Right	Left	Right	Left
Platycnemic	0	0	1	1	3	1	4	2
Mesocnemic	4	3	0	1	1	4	5	8
Eurycnemic	2	4	2	0	3	1	7	5
Total	6	7	3	2	7	6	14	15

**Table 17: Cnemic index - number of tibiae in each category, Phase 1**

Sex	Right		Left	
	Mean	Range	Mean	Range
		Min. Max.		Min. Max.
Male	69.58 (n=3)	66.79 74.93	69.83 (n=5)	64.74 76.47
Female	74.64 (n=1)	74.64 74.64	74.07 (n=2)	73.32 74.81
Un-sexed	73.13 (n=2)	71.81 74.45	68.74 (n=4)	52.4 75.72

**Table 18: Cnemic index - range and mean, Phase 2**

	Male		Female		Unsexed		Total	
	Right	Left	Right	Left	Right	Left	Right	Left
Platycnemic	0	0	0	0	0	1	0	1
Mesocnemic	2	3	0	0	0	1	2	4
Eurycnemic	1	2	1	2	1	2	3	6
	3	5	1	2	1	4	5	11

**Table 19: Cnemic index - number of tibiae in each category, Phase 2**

### 8.2.6.3 Cranial indices

It was not possible to calculate any cranial indices.

### 8.2.7 Non-metric traits

Non-metric traits occur in a minority of Skeletons and are believed to suggest hereditary affiliation (Saunders 1989). Other factors such as mechanical stress (Kennedy 1989) and environment (Trinkhaus 1978) have also been implicated. A total of 30 cranial and 30 post-cranial traits are routinely recorded (Berry and Berry 1967; Finnegan 1978; Buikstra and Ubelaker 1990).

#### 8.2.7.1 Cranial non-metric traits

It was possible to observe the presence or absence of non-metric traits in 66 of the adult Skeletons. Frequencies are presented in Tables 20 and 21. Due to the incomplete nature of many of the adult Skeletons, the number of individuals for which each trait could be observed was often far fewer than the total number of adult Skeletons present. Most Skulls were highly fragmented, the facial region and the Skull base being most affected. This

impacted on the number of cranial traits that could be recorded. Lambdoid and coronal ossicles were the most common, being observed in most of the adult Skeletons with the relevant bones. Bennett (1965) has suggested that the formation of ossicles in this suture may be related to stresses placed on the growing cranium during foetal life and early infancy.

Midline traits	Trait present	Part present	%
Metopic suture	2	28	7.14%

**Table 20: Midline cranial non-metric traits (adults)**

Paired traits	Right			Left		
	Trait present	Part present	%	Trait present	Part present	%
Lambdoid ossicle	36	38	94.74%	36	38	94.74%
Coronal ossicle	25	28	89.29%	25	28	89.29%
Ossicle at asterion	1	7	14.29%	1	10	10%
Parietal foramen	3	37	8.11%	3	37	8.11%
Mastoid foramen extrasutural	3	28	10.71%	4	34	11.76%
Sutural mastoid foramen	0	29	0%	2	35	5.71%
Double condylar facet	0	35	0%	3	29	10.34%
Maxillary torus	0	17	0%	1	19	5.26%
Mandibular torus	0	45	0%	1	47	2.13%
Zygomatic facial foramen absent	6	31	19.35%	6	34	17.65%
Bridging of supraorbital notch	3	16	18.75%	5	19	26.32%
Accessory supra-orbital foramen	1	15	6.66%	0	16	0%

**Table 21: Paired cranial traits (adults)**

#### 8.2.7.2 Post-cranial non-metric traits

Frequencies for post-cranial traits are presented in Table 22. Due to the incomplete nature of many of the adult Skeletons, the number of individuals for which each trait could be observed was often far fewer than the total number of adult Skeletons present. The most common traits were double anterior calcaneal facets followed by double inferior talar facets, vastus notches and transverse foramen bipartite.

Paired traits	Right			Left		
	Trait present	Part present	%	Trait present	Part present	%
Double atlas facet	5	36	13.88	5	37	13.51
Posterior atlas bridging	0	19	0.00	2	19	10.53
Transverse foramen bipartite	4	32	12.5	6	34	17.65
Accessory acromial facet	1	17	5.88	0	21	0.00
Circumflex sulcus	1	41	2.44	0	42	0.00
Supracondyloid process	0	61	0.00	1	62	1.61
Septal aperture	3	52	5.77	3	44	6.82
Allen's fossa	1	49	2.04	1	39	2.56
Poirier's facet	2	49	4.08	0	40	0.00
Plaque	1	49	2.04	1	39	2.56
Third trochanter	1	30	3.33	1	29	3.45
Vastus notch	1	33	3.03	6	32	18.75
Medial tibia squatting facet	1	43	2.33	0	24	0.00
Lateral tibia squatting facet	0	39	0.00	3	28	10.71
Peroneal tubercle	1	14	7.14	0	17	0.00
Double anterior calcaneal facet	9	37	24.33	9	31	29.03
Absent anterior calcaneal facet	1	39	2.56	1	33	3.03
Double inferior talar facet	5	40	12.5	8	34	23.53
Os trigonum	1	42	2.38	2	37	5.41

**Table 22: Paired post-cranial traits (adults)**

### 8.3 Pathological analysis

All Skeletons were examined macroscopically for evidence of pathological change.

#### 8.3.1 Metabolic disease

An adequate supply of nutrients is required during childhood to support normal growth and development. Several conditions are associated with a lack of specific nutrients. Scurvy is caused by a lack of vitamin C which is found in fresh fruit, vegetables and marine fish. The cause of rickets is a lack of vitamin D which the body produces primarily during exposure to sunlight and also through diet. The diagnosis of these deficiencies is not straightforward as most sufferers would tend to be deficient in more than one nutrient. Furthermore, many of the changes that develop in childhood would have been largely remodelled by the time an individual reached adulthood (Ortner 2003; Lewis 2007).

##### 8.3.1.1 Cribra orbitalia and anaemia

There is disagreement over the classification of cribra orbitalia as a metabolic disease. For example, Walker (2012, 259) considers protic hyperostosis of the ectocranial vault and orbital roofs (cribra orbitalia) as a non-specific indicator of disease and places it within the group of miscellaneous conditions. It has been linked to a number of pathological

conditions, including inflammation, haemorrhage, iron deficiency anaemia, parasitic anaemia, rickets, scurvy and certain genetic and neoplastic diseases (Ortner 2003, 89). Some recent work has suggested that cribra orbitalia can occur as a result of megaloblastic anaemia, where a diet which is deficient in vitamin B12 is caused by gastro-intestinal disease or by maternal depletion (Walker et al. 2009).

Most of the Skulls from this cemetery had suffered post-mortem damage and consequently few orbits could be examined for the presence of cribra orbitalia. The data is presented by phase in Tables 23-24.

	Right orbit			Left orbit			Individuals		
	A	P	%	A	P	%	A	P	%
Males	0	6	0.00	0	3	0.00	0	6	0.00
Females	1	4	25.00	1	5	20.00	1	5	20.00
Unsexed adults	0	0	0.00	0	0	0.00	0	0	0.00
Non-adults	1	1	100.00	0	0	0.00	1	1	100.00
<b>Total</b>	<b>2</b>	<b>11</b>	<b>18.18</b>	<b>1</b>	<b>8</b>	<b>12.50</b>	<b>2</b>	<b>12</b>	<b>16.66</b>

**Table 23: Prevalence of cribra orbitalia, Phase 1**

	Right orbit			Left orbit			Individuals		
	A	P	%	A	P	%	A	P	%
Males	1	6	16.66	1	5	20.00	2	9	22.22
Females	0	1	0.00	2	2	100.00	2	2	100.00
Unsexed adults	1	1	100.00	0	0	0.00	1	1	100.00
Non-adults	0	1	0.00	0	0	0.00	0	1	0.00
<b>Total</b>	<b>2</b>	<b>9</b>	<b>22.22</b>	<b>3</b>	<b>7</b>	<b>42.86</b>	<b>5</b>	<b>13</b>	<b>38.46</b>

**Table 24: Prevalence of cribra orbitalia, Phase 2**

The crude prevalence rate quoted by Roberts and Cox for the medieval period is 10.82% (2003, 235). They further note that hospital sites have a prevalence rate of 25.61% compared to a general rate of 9.33%. The rate recorded for this assemblage varies from 16.66% for Phase 1 to 38.46% for Phase 2, though the sample is a small one.

The well-established complication of chronic eye infection associated with leprosy results in blindness but will also stimulate hypervascularity that will affect the bones of the orbit resulting in increased porosity and possible porous reactive bone formation. Cribra orbitalia

occurred in the leprosy cases from Chichester but it was not common, and where it occurred it was a relatively mild form (Ortner 2008, 200, fig. 14.1). An analysis of frontal grooves, thought to occur as a result of nerve thickening, examined the relationship of frontal grooves and cribra orbitalia (Goode 1993). The chi square test produced a negative correlation, in other words, where cribra orbitalia is present the individual is less likely to suffer from leprosy (Lee and Manchester 2008, 217). A study of modern leprosaria by Jopling and McDougall (1988, 21) led to the suggestion that mild anaemia and raised erythrocyte sedimentation are classic features of lepromatous leprosy. Goode, however, argued (1993) that iron deficiency anaemia may have been a positive response to a high pathogen load in the environment, reflecting those who had successfully fought the leprosy infection or perhaps contracted the less contagious form of leprosy.

At St Leonards, two individuals from Phase 1 (Sk 60 and Sk 85) exhibited evidence of cribra orbitalia. Rhino-maxillary changes affected Sk 85 only while Sk 60 exhibited non-specific infection which affected the lower left arm, the lower legs and the feet. Five individuals from Phase 2 (Sk 23, Sk 34, Sk 56, Sk 78 and Sk 140) had cribra orbitalia. Sk 23 and Sk 78 exhibited rhino-maxillary change while Sk 34 and Sk 56 showed indications of non-specific infection in the lower legs and feet.

### 8.3.2 *Trauma*

Most of the evidence for trauma in archaeological populations is focussed on fractures to bone (Roberts and Manchester 2005, 84-85) with the caveat that old and well healed fractures can be difficult to identify. A total of 17 Skeletons exhibited fractures of one or more bone (CPR 13.08%, 17/130). There were 12 affected individuals in Phase 1 and 5 in Phase 2.

#### 8.3.2.1 *Ante-mortem limb fractures*

Sk 74 (Phase 1), an adult aged upwards of 18 years of indeterminate sex had a very poorly healed fracture of the surgical neck of the right humerus (Plate 23). Some post-mortem damage had affected the humeral head. The humeral head had been displaced both anteriorly and medially. A false joint had formed on the anterior surface of the body of the scapula. Severe eburnation covered the surviving posterior portion of the humeral head. There were severe osteophytes encircling the surviving portion of the humeral head with grooving on the medial side of this surface. The humeral head was flattened and deformed. Severe eburnation was present on the anterior scapula and the glenoid cavity was almost entirely obscured by new bone deposition (Plate 24). The left humerus did not survive.

The TPR at St Leonard's is 2.86% (1/35). The CPR quoted for the humerus in the medieval period is 0.55% (Roberts and Cox 2002, 239, tab. 5.7).

It is unfortunate that the Skeleton is not sufficiently well preserved to determine sex and provide a more precise estimate of age at death as older adults, particularly women, along with non-adults are most commonly affected (Wedel and Galloway 2014, 203). Fractures in the proximal humerus usually result indirectly from falls onto the outstretched hand although direct blows may also cause damage to this region of the bone (ibid., 204). Radiography would be desirable to allow for a clearer interpretation of the precise nature of this fracture.





**Plate 23: Skeleton 74, anterior view of poorly healed fracture of surgical neck of right humerus**



**Plate 24: Skeleton 74, anterior view of right scapula**

Sk 74 (Phase 1), also had a healed fracture of the right third metacarpal shaft, adjacent to the proximal articulation. There was good apposition of the ends although the shaft was thickened and angulated in a palmar direction. A bony exostosis was located on the shaft adjacent to the distal articulation on the palmar surface.

Sk 141 (Phase 1), an adult Skeleton aged upwards of 18 years of uncertain sex, had a healed fracture of the neck of the left femur (Plate 25). There was marked displacement of the neck in a posterior direction, though not distally. There was gross proliferation of irregular new bone on the medial side, which was less severe on the anterior and posterior surfaces. The lateral surface was normal. The lesser trochanter was obscured by new bone and there was also post-mortem damage. The greater trochanter did not survive. New bone extended up to 48.39mm from the shaft in a medial direction. There was a suggestion of a false hip joint which was indicated by a much smoother area on a fragment of the left ilium. It was difficult to be certain because of the extent of post-mortem damage. Very little survived of the left and right pelvis and the right femur was too fragmented for comparison. The left femur

shaft appeared normal. The TPR at St Leonard's is 1.29% (1/77). The CPR quoted for the femur in the medieval period is 0.45% (Roberts and Cox 2002, 239, tab. 5.7).



**Plate 25: Skeleton 141, anterior view of poorly healed fracture of left femoral neck**

Sk 3 (Phase 1), an adult aged upward of 18 years of uncertain sex had a possible healed fracture of the midshaft of the right radius on the basis that it was mal-aligned. The left radius of Sk 4 (Phase 1) appeared mal-aligned at the distal end. This may be a well healed fracture or a congenital abnormality. Sk 85 (Phase 1), a prime adult female aged 26-35 years, had a possible healed fracture of the right ulna suggested by a slight swelling of the shaft on the medial side at the distal end. Sk 37 (Phase 2), an adult male aged upwards of 18 years, had a possible healed fracture of the left tibia. Sk 76 (Phase 1), a mature adult male, had a possible healed fracture of the right clavicle indicated by a slight swelling of the posterior surface at the midshaft. Radiographs would be required to determine if these abnormalities are indeed healed fractures.

Sk 89 (Phase 2), a prime adult male aged 26-35 years, had a possible healed fracture of the acromial end of the left clavicle with possible atrophy of the lateral epiphysis (Wedel and Galloway 2014, 198). The TPR at St Leonard's is 2.38% (1/42). The CPR quoted for the clavicle in the medieval period is 0.56% (Roberts and Cox 2002, 238, tab. 5.7).

Sk 35 (Phase 1), an adult aged upwards of 18 years of uncertain sex had a well healed vertical fracture on the medial side of the right patella. The CPR quoted for the patella in the medieval period is 0.72% (Roberts and Cox 2002, 239, tab. 5.7). Fractures of the patella account for approximately 1% of all fractures and are more common in men although there is no greater susceptibility by side (Wedel and Galloway 2014, 271). Patellar fractures occur either as a result of direct blows or through the tension generated by the quadriceps muscle. Stellate and vertical fractures form over a fifth of all patellar fractures.

#### 8.3.2.2 *Ante-mortem fractures to the vertebrae*

Sk 42 (Phase 1), a mature adult female aged 36-34 years, had probable compression fractures of the tenth and eleventh thoracic vertebrae which resulted in a moderate degree

of kyphosis (Plate 26). Both bodies exhibit anterior wedging. The eleventh thoracic vertebra is more severely affected than the tenth. The anterior bodies measure 14.39 mm and 13.82 mm in thickness. The thickness of an adjacent normal vertebral body is c. 17 mm.



**Plate 26: Skeleton 42, lateral view of TV10-12**

Sk 105 (Phase 1), an adult of uncertain sex aged upwards of 18 years, had a probable compression fracture of the twelfth thoracic vertebra. This caused a marked kyphosis which affected the second through to the twelfth thoracic bodies. The anterior thickness of the affected vertebra was 19.12 mm compared with a posterior body width of 24.57 mm.

In both the examples discussed above X-ray would be required to confirm the presence of a fracture and discount age related change.

Sk 82 (Phase 2), a young probable male adult aged 18-25 years had a probable fracture of the third sacral body which is compressed anteriorly resulting in a marked increase to the normal sacral curvature (Wedel and Galloway 2014, 187). A hairline crack is visible on the left side of the third sacral arch.

The CPR quoted for the vertebrae in the medieval period is 1.03% (Roberts and Cox 2002, 239).

#### 8.3.2.3 *Ante-mortem fractures to the ribs*

A total of five individuals had rib fractures, numbers varying from one to five. Sk 47 (Phase 2), an adult aged upwards of 18 years of uncertain sex had three rib fractures (2 left and 1 right). A left ?3<sup>rd</sup> rib had a healed fracture located at the angle of the bone with good apposition of broken ends and callus surviving. A left ?8<sup>th</sup> rib had a healed neck fracture. The bone is slightly misshapen with callus surviving. A right 3<sup>rd</sup> rib had a healed fracture located at the neck of bone. There was poor apposition of the broken ends. The anterior portion of the rib was displaced in a distal direction and there is callus surviving.

Sk 74 (Phase 1), an adult aged upwards of 18 years has a probable healed ?right eighth rib fracture; callus survives on the caudal surface.

Sk 88 (Phase 1), an adult male aged upwards of 18 years had five healed right rib fractures, located at the midshaft with callus surviving on the visceral surfaces.

Sk 89 (Phase 2), a prime adult male aged 26-35 years, had a possible healed fracture of the angle of the left 6<sup>th</sup> rib, with new bone deposition on the caudal surface.

Sk 97 (Phase 2), an adult male aged upwards of 18 years had two 2 healed rib fractures, probably from the left side, located at the midshaft. There was good apposition of the ends though there was considerable survival of callus on the caudal surfaces.

The CPR quoted for the ribs in the medieval period is 3.57% (Roberts and Cox 2002, 239, tab. 5.7). The CPR at St Leonard's is 2.41% (2/83) for Phase 1 and 6.38% (3/47) for Phase 2.

#### 8.3.2.4 *Ante-mortem fractures to the bones of the hands and feet*

Sk 15 (Phase 1) and 16 (Phase 1) both had fractures of the right fifth metacarpal. Sk 48 (Phase 1) had a fracture of the left 5<sup>th</sup> metacarpal. Sk 127 (Phase 1) had a fracture of the left second metacarpal. Sk 62 (Phase 1) had a fracture of the right proximal second hand phalanx. Sk 83 (Phase 2) had a fracture of the right first proximal foot phalanx.

#### 8.3.2.5 *Dislocation*

Sk 44 (Phase 2), a young probable female adult aged 18-25 years had a possible dislocation of the left proximal ulna (Aufderheide and Rodriguez-Martin 1998, 25, fig. 3.7; Walker 2012, 124). Post-mortem loss of the coronoid process had occurred and there was also some damage to the proximal edge of the olecranon. The radial notch had been completely remodelled and there was new bone deposition on the lateral side of the trochlear notch. The entire olecranon was much reduced in thickness and there was subchondral pitting in the trochlear notch. Other possible diagnoses include an olecranon fracture. The left humerus and left proximal ulna did not survive. The TPR at St Leonard's is 1.49% (1/67). The CPR quoted for medieval Britain (Roberts and Cox 2002, 238, tab. 5.6) which relates to the elbow rather than an individual bone is 0.10%.

#### 8.3.2.6 *Spondylolysis*

The fifth lumbar vertebra of Sk 134 (Phase 1), an adult male aged upwards of 18 years, exhibited unilateral separation of the pars interarticularis (left side). This is referred to as spondylolysis and is relatively common in archaeological assemblages (Walker 2012, 116). Between 2.3 and 10% of individuals in modern populations have the condition, which is more common in males than females and is usually asymptomatic (Resnick 2002, 3003). Clinical evidence reveals that spondylolysis is the result of a fatigue fracture where stress or repeated trauma, rather than a single traumatic event leads to the break (Merbs 1983, 39; Waldron 1991, 64). Unilateral lesions occur in approximately one-fifth of cases of spondylolysis, although this may sometimes be due to unilateral healing of bilateral lesions (Resnick 2002, 3004). Studies have shown that most spondylolysis is initially unilateral; it can then heal or progress to bilateral separation (Walker 2012, 117). It is possible that the unilateral form puts abnormal strain on the other side, leading to bilateral separation (Merbs 2002, 156, 171).

### 8.3.3 Infectious disease

Infections to which the body has developed at least sufficient immunity to prolong its co-existence as a chronic infection are the most likely to generate obvious Skeletal lesions (Aufderheide and Rodriguez-Martin 1998, 118). The initial bony response to infection is the production of disorganised, woven bone which during the healing process is remodelled and transformed into lamellar bone. Therefore, woven bone is indicative of an infection that was active at the time of death, whereas the presence of lamellar bone indicates that an infection has healed or is in the process of healing. In case where both are present, it is likely that an infection is longstanding or recurring. Much of the evidence for infection observed in archaeological assemblages is non-specific, in other words it is not possible to diagnose a specific condition. This is discussed further in Section 8.3.4 below.

#### 8.3.3.1 Maxillary sinusitis

Maxillary sinusitis is one of the most common non-specific infections in past and modern populations. Dental abscesses, poor ventilation, air pollution and allergies have all been linked to the condition, which, unless treated can persist for years; Skeletal changes can start to manifest after only a few weeks (Lewis et al. 1994, 498). Sinuses were not systematically investigated. Only those that were broken or readily visible were investigated. It is highly likely that this impacted on the prevalence rate. The data is presented by phase in Tables 25-26.

	Right maxilla			Left maxilla			Individuals		
	A	P	%	A	P	%	A	P	%
Sex									
Males	1	7	14.28	1	7	14.28	2	9	22.22
Females	2	4	50.00	1	4	25.00	2	6	33.33
Non-adult	0	0	0.00	0	1	0.00	0	1	0.00
Indeterminate	0	1	0.00	0	1	0.00	0	1	0.00
Total	3	12	25.00	2	13	15.38	4	17	23.53

**Table 25: Prevalence of maxillary sinusitis in adults (sinuses and individuals), Phase 1**

Key: A = number of sinuses/individuals with maxillary sinusitis; P = number of sinuses/individuals possible to observe.

	Right maxilla			Left maxilla			Individuals		
	A	P	%	A	P	%	A	P	%
Sex									
Males	0	5	0.00	0	5	0.00	0	7	0.00
Females	1	1	100.00	0	0	0.00	1	1	100.00
Non-adult	0	0	0.00	1	1	100.00	1	1	100.00
Total	1	6	16.66	1	6	16.66	2	9	22.22

**Table 26: Prevalence of maxillary sinusitis in adults (sinuses and individuals), Phase 2**

Key: A = number of sinuses/individuals with maxillary sinusitis; P = number of sinuses/individuals possible to observe.

The CPR quoted by Roberts and Cox (2002, 233, tab. 5.3) for the medieval period is 13.3%. This is lower than the CPR for St Leonard's which is 23.53% for Phase 1 and 22.22% for Phase 2. At Chichester 58% of those with sinuses present were affected (Lee and Boylston 2008, 225). The right side was more frequently affected and in just over 50% the involvement was bilateral. Inflammation of the nasal mucosa is a feature of lepromatous leprosy. This may spread to the mucosa of the paranasal sinuses, resulting in ulceration that in turn predisposes the sinus to secondary pyogenic bacterial attack and sinusitis (op. cit).

A total of four individuals (Sk 18, Sk 45, Sk 69 and Sk 118) in Phase 1 had maxillary sinusitis and all exhibited evidence of rhino-maxillary change. There were two affected individuals in Phase 2 (Sk 23 and Sk 132). Sk 23 exhibited rhino-maxillary change while Sk 132, a younger juvenile had abnormal palatal porosity. Very little else of the maxillary area or nasal aperture survived. None of these individuals had suffered from dental abscesses. A close association between lepromatous leprosy and maxillary sinusitis was highlighted by Barton (1979). In the Chichester sample 43 crania had evidence for rhino-maxillary change and maxillary sinusitis (63% of those with nasal antra present and facies leprosa). This is below the level anticipated by Barton but much higher than the 13.3% quoted for the period (Roberts and Cox 2002). A detailed study of maxillary sinusitis at Chichester (Boocock et al. 1995a and 1995b) found that 54.9% of the adults had evidence for the condition and that there was no significant difference in prevalence rates between those with leprosy and those with no skeletal evidence for the disease (Lee and Boylston 2008, 225).

#### 8.3.3.2 *Respiratory infections*

Lung infections can lead to deposits of new bone on the visceral surfaces of the ribs (Roberts and Manchester 2005) and in a high percentage of individuals these lesions have been associated with tuberculosis (Santos and Roberts 2001; Mays et al. 2002; Matos and Santos 2006; Santos and Roberts 2006).

A single individual exhibited periosteal lesions on the visceral surfaces of the ribs. Sk 72 (Phase 1), a young adult male, had periosteal lesions on the visceral surfaces of at least three right ribs and one left rib. All areas of the rib were affected and the lesions extended from the costal to the sternal end. A total of 14 fragments were affected and the deposits comprised thin, grey woven new bone which would have been active at the time of death. The form, location and bilateral nature of these lesions may be a chronic pulmonary infection. There is insufficient evidence to suggest a diagnosis of pulmonary tuberculosis (Matos and Santos 2006, 193; Santos and Roberts 2006, 44, 47). Nineteen adults at Chichester had visceral rib lesions (Lee and Boylston, 2008, 222) which in six individuals were associated with other skeletal indicators of tuberculosis.

#### 8.3.3.3 *Osteomyelitis*

As well as specific infections such as treponematoses, tuberculosis and leprosy, there are a great many infectious diseases that lead to generalised or non-specific bone changes where the particular micro-organism cannot be identified (Walker 2012, 32). These non-specific infections are often categorised by the tissue affected: periostitis (periosteum or the fibrous sheath that covers the bone), osteitis (the cortical bone) and osteomyelitis (medullary cavity) (Roberts 2000, 146). Roberts and Manchester (2005) consider that the subdivision of

non-specific infection into these categories is misleading, since they probably result from the same infective process. Brickley et al. (2006), however, suggest that this terminology is a useful way of describing the severity of the infection.

Infection may arise as a result of pathogens spreading from an adjacent lesion via the blood stream (for example, as seen in trauma, chronic Skin ulceration, paranasal sinusitis, middle ear cavity infection, a dental abscess and visceral rib surface inflammation), or as a result of direct implantation into bone (for example as seen in puncture and penetrating injuries).

A single Skeleton exhibited evidence of probable osteomyelitis, but did not display any of the classic indicators used in the diagnosis of leprosy (all other examples are discussed in section 8.3.4 below). Osteomyelitis affected the right ulna, tibiae and right fibula of Sk 101. There was marked thickening of all three bone shafts and involvement of the medullary cavity. Radiography would be required to confirm this diagnosis.

Cases of osteomyelitis which were potentially linked to lepromatous leprosy are discussed in section 8.3.4 below. The CPR quoted for osteomyelitis in the medieval period is 0.78% (Roberts and Cox 2000, 240, tab. 5.8).

#### 8.3.3.4 *Periosteal reactions*

Periosteal new bone forms the protective layer of periosteum which encases the bones. Lesions can occur in a range of conditions including infection, trauma, scurvy, venous stasis, secondary hypertrophic osteoarthropathy and neoplastic disease (Resnick 2002, 4884; Ortner 2003, 88). Arguably it is a reflection of living conditions and whatever its cause it affected many people (Roberts and Cox 2000, 235). Grauer (1993) identified acquired anaemia, parasite infestations and endemic treponematoses as possible causal agents and noted that periosteal reactions were more common in those living longest. The CPR quoted for the medieval period is 14.08% (Roberts and Cox 2002, 235, tab. 5.5).

Often the lesions are not diagnostic and in such cases it is recommended that they should be described as 'periosteal lesions' (Walker 2012, 34). Grey, disorganised woven bone is an initial response and it is later converted into more organised and dense lamellar bone.

In this section, only those examples which had no link to a possible diagnosis of leprosy are discussed. Hence, periosteal lesions which affect the forearms, hands, lower legs and feet are considered in Section 8.3.4 below.

##### *Phase 1*

Sk 31, an adolescent aged 15-16 years had a small periosteal lesion on the left femur, immediately proximal to the lesser trochanter. It comprised woven grey bone which was active at the time of death. Sk 84, a prime adult male aged 26-35 years, had a small area of woven new bone on a fragment of the left ilium, on the medial surface above the acetabulum. It would have been active at the time of death.

##### *Phase 2*

Sk 12, an adolescent aged 16-17 years, exhibited a swelling of the shaft of the left femur on the lateral surface which was demarcated by woven bone. This may have been a chronic ulcer or an ossified haematoma. Sk 68, a prime adult male aged 26-35 years, had a small periosteal lesion on the medial surface of the left ilium, adjacent to the sciatic notch. It

would have been active at the time of death. Sk 89, a prime adult male aged 26-35 years, had a healed periosteal lesion on the left clavicle, located at the medial side of the conoid tubercle. Sk 98, an adolescent aged 13-17 years had a small periosteal lesion located on the anterior surface of the blade of the right scapula, adjacent to the glenoid cavity.

#### 8.3.4 *Leprosy*

Leprosy is a chronic bacterial infection primarily affecting the peripheral nervous system with secondary involvement of the soft tissue and bone caused by the organism *Mycobacterium leprae*. The infection is transmitted by infectious droplets. It has a long incubation period and only a very small percentage of those infected go on to develop the clinical form of the disease, even though it is thought to be extremely infective. The paucibacillary (or tuberculoid) form and the multibacillary (or lepromatous) form represent the two extremes of the leprosy spectrum. There are many intermediate expressions of the disease. The form of the disease is entirely dependent on the immune response of the affected individual. There is high resistance in paucibacillary leprosy, which diminishes through borderline to the lowest resistance form, multibacillary leprosy. It has been suggested (Lee and Manchester 2008) that individuals at St James and St Mary Magdalen, Chichester who exhibited volar grooving of the proximal hand phalanges and tarsal bridging in the absence of any other indicators of leprosy, may have been suffering from paucibacillary or tuberculoid leprosy, although this form is generally believed to be very difficult to diagnose in archaeological material. This is because skeletal lesions would have been minimal or non-existent (Lee and Manchester 2008, 208). Borderline leprosy is immunologically unstable and it is therefore possible for an individual to downgrade to lepromatous leprosy if his or her health becomes compromised.

##### 8.3.4.1 *Clinical features of leprosy*

Leprosy is still a huge problem in the developing world today with the World Health Organisation estimating that there were 1.8 million cases worldwide in 1995 (McDougall 1996). In countries where leprosy is still rife, it tends to affect one in 100 people (Rawcliffe 2006) so the disease is not highly infectious. Young people are particularly vulnerable to contracting the disease between the ages of 10 and 20 but the bony changes take from 5 – 7 years to develop (Boylston 2012, 1).

The word 'leprosy' comes from the Greek 'lepros'. The disease predominantly affects the skin and nerves. It is the only such condition which causes nerve damage in the sufferer and this is what makes the physical manifestations so unpleasant (Malaviya 2010). Like other chronic granulomatous infections such as tuberculosis, it is the response of the patient's immune system which is the cause of tissue damage as much as the disease itself. This is particularly true of tuberculoid leprosy, which is the type seen in those with the most powerful immune reaction. This causes milder skin lesions with fewer bacteria than other forms of leprosy but very rapid onset of peripheral nerve damage (Malaviya 2010) due to the cell-mediated response.

In the early stages of lepromatous leprosy, the nerves are not involved and the skin lesions are not likely to be noticed. However, this is the stage at which the individual is at his most infectious (Lee and Manchester 2008, 209). Early symptoms include nasal congestion and



swelling of the legs (oedema). Ultimately, lepromatous leprosy, seen in those who have a poor immune response, produces severe changes to the Skin and mucous membranes which are full of bacilli. The characteristic facial features are wrinkling and thickening of the Skin (known as leonine facies), disappearance of facial hair and eyebrows and paralysis of the lower eyelid termed lagophthalmos (Shah and Shah 2010). As the disease progresses the nasal spine and cartilage are affected, leading to a sunken nose. Bacteria in the swollen mucous membranes cause nasal congestion and an unpleasant discharge (Malaviya 2010).

The nerves of the post-cranial Skeleton become thickened and replaced by fibrous tissue and gradually both sensory, and then motor functions are affected. It is the unopposed action of normal muscles that leads to instability in the joints. Damage to the sensory nerve leads to a condition termed 'glove and stocking' anaesthesia when the peripheral nerves of the forearm or lower leg are affected (Boylston 2012). The nerve damage is always bilateral and symmetrical although one side may become involved earlier than the other (Lee and Manchester 2008, 209). The resulting lack of sensation results in repeated injury to the hands and feet with chronic plantar ulceration a common feature (ibid. fig. 15.1b). Leprosy also affects the lymph nodes, eyes, liver, spleen, pharynx, larynx, trachea and testes.

#### 8.3.4.2 *Skeletal indicators of leprosy*

The ability to diagnose leprosy in archaeological populations ranges from problematic to highly likely (Ortner 2008, 206). Diagnosis becomes problematic as a distinction has to be made between lesions that occur in direct response to *m. leprae* and those that occur as secondary infections from exposure to pathogens through Skin ulcers (Andersen et al. 1994), often resulting in non-specific changes to the hands, lower legs and feet. Diagnosis is further complicated by taphonomic factors such as surface preservation, fragmentation and completeness. Nonetheless, the overall pattern of multifocal leprosy is quite distinctive.

The diagnostic criteria employed in the present analysis are based on those defined for the remains from St James and St Mary Magdalene, Chichester (Lee and Manchester 2008; Ortner 2008) which are presented in Table 27 below. These diagnostic criteria were recently employed in the identification of leprosy among the assemblage from St Mary Magdalen, Winchester (Roffey and Tucker 2012, 173). The major sites for Skeletal involvement in leprosy include the bones of the face, the hands, the lower legs and the feet.

Leprous osteomyelitis can occur due to the spread of *mycobacterium leprae* to the medullary cavities, principally of the bones of the hands and feet (Manchester 2008, 182). Septic arthritis occurs where the synovium and joint cavity are exposed to bacteria through haematogenous spread, extension from adjacent tissues or direct invasion from an injury (Ortner 2003, 222). Chronic septic arthritis may eventually result in destruction and ankylosis (Walker 2012, 87).

Lesions of the Skull	Nasal lesions	Destructive remodelling of the nasal aperture. Destruction of the anterior nasal spine. Abnormal porosity of the nasal floor. Destruction of the turbinates and nasal septum.
	Maxilla	Abnormal porosity of the alveolar process. Destructive remodelling of the anterior alveolar process.
	Palate	Abnormal porosity. Lytic defects.
Abnormalities of the teeth		Odontodysplasia – failure of root development in children with leprosy
Bones of the hands		Destructive remodelling (concentric atrophy) of the metacarpals and phalanges. Flexion contracture resulting in volar grooving.
Bones of the lower leg		Periostitis caused by secondary infection of the feet
Bones of the feet		Destructive remodelling (concentric atrophy) of the metatarsals and phalanges. Blade-like remodelling of the metatarsals and phalanges. Dorsal exostoses of the tarsal bones, particularly the navicular. Secondary infection following trauma. Septic arthritis [Osteomyelitis]

**Table 27: Diagnostic criteria for leprosy in Skeletal remains (after Lee and Manchester 2008; Ortner 2008)**

*Rhino-maxillary syndrome*

Rhino-maxillary syndrome is characterised by remodelling and thickening/rounding of the nasal aperture with abnormal porosity of the palate, reduction or elimination of the anterior nasal spine and symmetrical resorption of the anterior maxillary sockets. In severe cases this can result in the loss of the anterior dentition. These distinctive changes were first recorded by Moller-Christiansen (1953; 1961; 1974; 1978) as *facies leprosa*. Combined with inflammatory changes to the oral and nasal surfaces of the palatine process of the maxilla, the turbinates and the nasal aperture, these are important diagnostic criteria in the diagnosis of leprosy in the Skeleton (Lee and Manchester 2008; Ortner 2008). Andersen et al. (1994) stated that rhino-maxillary remodelling is only seen in lepromatous leprosy and is diagnostic for this condition. Some elements of this syndrome have also been recorded in sufferers of treponemal disease (e.g. Cook 1994) and tuberculosis of the soft tissue and facial Skin (Ortner and Putschar 1981).

In most cases of destructive remodelling around the nasal aperture, the margins are smooth compact bone which indicates a very chronic stage of lepromatous leprosy (Ortner 2008, 201), however, the appearance of this process in the early stages of nasal involvement is more problematic. Possible early stage examples at Chichester included porosity of the maxillary bone at the aperture margin along with pitting and porosity of the inner surface of

the nasal passage (op. cit. fig. 14.3b). Early-stage leprosy in the form of abnormal porosity of the rhinomaxillary region and manual and pedal digits is included in this analysis.

#### *Changes to the forearms*

Jopling (1984) considered periostitis to be rare in the bones of the forearm in leprosy. Five Skeletons at Chichester had leprosy infection of the hand in conjunction with periostitis of the forearms (Lee and Manchester 2008, 212). At least one example was recorded at Winchester (Roffey and Tucker 2012, 175). This Skeleton also had severe changes to the rhino-maxillary area, the hands, lower legs and feet.

#### *Changes to the hands*

The most distinctive changes to the bones of the hands occur as a consequence of several disease processes which include acro-osteolysis, a loss of peripheral bone substance through absorption, concentric diaphyseal remodelling of the shafts as well as destruction of the distal end of the bones (Anderson et al. 1994; Lee and Manchester 2008). Other changes are caused by a septic arthritis of the joints, as well as osteomyelitis and periostitis. Involvement of the motor nerves leads to flexion contracture of the digits and claw hand deformity and may result in volar grooving near the tips of the phalanges (palmar surfaces) or destruction of the phalanges of the hand (Anderson and Manchester 1987).

Motor nerve damage results in claw hand deformity because of unopposed spasticity of the flexor muscles (Lee and Manchester 2008, 213, fig. 15.6). The clawing of the fingers prevents damage to the palm, leaving the prominent parts, in particular, the joints, vulnerable to pyogenic sepsis and dorsal ulceration as the individual attempts to use the insensitive hand (Andersen and Manchester 1987). In the anaesthetised hands the individual cannot assess the friction force required to hold objects and therefore uses the maximum force all the time, with turning, shearing and striking forces no longer regulated by warning pain (Parry 1984). Secondary bacterial infection may give rise to sub-periosteal change, osteomyelitis and eventual septic arthritis (Lee and Manchester 2008, 213).

Volar grooves are visible as shallow depressions to the volar surface of the distal end of the proximal phalanges, close to the distal articular surface (Lee and Manchester 2008, 213-214). They are the consequence of sustained hyperextension of the metacarpo-phalangeal joint and hyperflexion, or even subluxation, at the interphalangeal joint. They are a sequel to ulnar nerve paralysis resulting in the claw hand deformity, even occurring in individuals with no other leprosy changes to the hand (Andersen and Manchester 1987). In severe cases the median nerve is also affected and this can lead to a 'swan-neck' deformity of the fingers (Malaviya 2010). This can cause depressions near the tips of the phalanges on their palmar surfaces or varying degrees of destruction of the phalanges. Changes rarely proceed beyond the metacarpo-phalangeal joint so it is the digits that are mainly affected (Andersen et al. 1994), by contrast any of the joints in the feet may be affected. It has been suggested (ibid.) that other conditions may result in volar grooves, for example, Dupuytren's contracture.

#### *Changes to the lower legs*

Sensory nerve damage predisposes the sufferer to trauma followed by secondary ulceration and non-specific infections which affect the lower limbs. Periostitis of the lower limbs is a very common feature of archaeological populations and can have multiple causes, including

trauma and treponemal disease (Roberts 2000, 153). Ortner suggested that a diagnosis of leprosy could be proposed when the periosteal reaction is focussed primarily on the distal ends of the bones rather than on the midshaft and proximal ends, reflecting the pathogenic stimulus in the foot (Ortner, 2008, 204). If the major focus of the reactive bone is in the midshaft or proximal end of the bone, diagnostic options other than leprosy are more likely. Manchester (2008) states that smooth, undulating layers of new bone on adjacent surfaces of the tibia and fibula are characteristic of leprosy when observed to be symmetrical on both legs. The bacteria causing the inflammation are normally staphylococci which have gained entry as a result of injury to the feet and the infection spreads up the lower leg along the interosseous membrane, as far as the knee joint (Boylston 2012, 7).

This is perhaps the most problematic of the diagnostic criteria. Ortner argued that ‘when bone forming abnormalities occur on the distal tibia and fibula, but are the only abnormality, a diagnosis of leprosy may be plausible in some cases but not in others and there is likely to be disagreement between observers.’ (Ortner, 2008, 200). Where possible the location (medial, lateral, anterior, posterior), extent (distal third, distal half) and bilateral or unilateral nature of any inflammatory response in the lower limbs have been recorded in the catalogue (see Appendix 1a). This is unclear in some cases due to the high level of fragmentation (there is limited potential for long bone reconstruction).

Chronic ulcer is another example of secondary infection that may be associated with neurological degeneration and diminished vascular function associated with leprosy (Ortner 2008, 205, fig. 14.11). The tibia is a particularly common site. The bony response to an overlying ulcer includes an area of reactive (abnormal) bone formation which has a well-defined border with the adjacent normal bone. The lesion may also appear porous which is indicative of the pathology being active at the time of death.

#### *Changes to the feet*

Two major abnormalities of the foot are directly associated with neuro-vascular disorders which are linked to leprosy: destructive remodelling of the metatarsals and phalanges (concentric, blade-like or knife-edge remodelling, sucked candy appearance or narrowing at the distal end); and degeneration of one or both arches of the foot, with collapse of the foot and reactive remodelling of the tarsal bones (Andersen and Manchester 1988; Ortner 2008, 205, figs 14.12 and 14.13). Destructive remodelling of the metatarsals and phalanges tends to be concentric and most severe in the distal ends and diaphysis of the metatarsals and phalanges. Severity varies from a barely identifiable abnormal reduction of diaphyseal diameters to cases where the phalanges may be entirely missing and the metatarsal bones greatly reduced in size with very little of the proximal metaphysis surviving.

Damage to the joints of the toes may result from both loss of sensation in the feet and bacteria circulating in the bloodstream and causing granulomas to form close to the joints (Malaviya 2010). The trabecular bone is thinned causing it to become fragile and osteoporotic. Ulceration of the soles may lead to septic arthritis in the joints, particularly those between the metatarsals and phalanges. However, it can also cause damage to, or ankylosis of, the tarsal bones and spread of the infection to the bones of the lower leg (Andersen et al. 1994). Infection in the joints of the metatarsals and phalanges or septic

arthritis leads to healing of the bones in strange positions and also 'knife-edge' remodelling with resorption of the bone of the metatarsal shafts externally and narrowing of the medulla on X-ray.

Mechanical alteration to the architecture of the foot, due to sensory and motor nerve damage, can lead to drop foot. The normal arch of the foot may become flattened, leading to changes in the ligaments - flexion contractures – causing navicular squeezing and tarsal disintegration, depending on severity (Kulkarni and Mehta 1983). Motor neuropathy leads to paralysis of certain muscle groups, and may also result in longitudinal and transverse arch collapse as well as claw toe deformity. As long as the integrity of the foot is maintained septic changes will affect the main pressure points of the feet which include the calcaneus, and the first and fifth metatarso-phalangeal joints. Collapse of the transverse arch of the foot is visible in the destruction of the 2<sup>nd</sup>, 3<sup>rd</sup> and 4<sup>th</sup> metatarso-phalangeal joints or navicular squeezing

Tarsal bars have been identified as an early indication of abnormal mechanical stress on the intertarsal joints (Andersen and Manchester 1988) and are hypertrophic lesions on the dorsal surfaces of the tarsal bones. They are caused by chronic ligamentous strain which results in the development of exostoses or flanges of bone at the sites of ligamentous attachment (Lee and Manchester 2008, 217). They may develop in the absence of tarsal disintegration (Kulkarni and Mehta 1983).

At Chichester, it was observed that some Skeletons exhibited evidence of unilateral involvement or severe involvement of the foot but no rhino-maxillary involvement and it was argued that these manifestations reflect a more effective immune response relative to those that occur in severe lepromatous leprosy (Ortner 2008, 207). It was further noted at Chichester that the feet were more often and more severely affected by leprosy than the hands (Ortner, op. cit.). This also appears to be the case at St Leonard's (see below).

#### 8.3.4.3 *Skeletal evidence for leprosy at St Leonard's*

Confident diagnosis of leprosy has been greatly hindered by the low completeness and high fragmentation of the Skeletal assemblage from St Leonard's (see Sections 8.2.1 to 8.2.3 above). In particular, the facial area of many Skulls was greatly damaged, impacting upon the survival of the rhino-maxillary area. The potential evidence for leprosy based on the presence of one or more of the diagnostic criteria discussed above is summarised by phase in Tables 28-29 below.

##### *Phase 1 - Rhinomaxillary syndrome*

In Phase 1, a total of 16 Skeletons (Sk 4, Sk 16, Sk 18, Sk 42, Sk 45, Sk 51, Sk 55, Sk 57, Sk 68, Sk 69, Sk 76, Sk 80, Sk 84, Sk 85, Sk 91 and Sk 118) exhibited some features of rhino-maxillary syndrome. The CPR for Phase 1 is 19.27% (16/83) while the TPR is 69.57% (16/23). Eight males, five females, two adults of indeterminate sex and one adult of uncertain sex were affected. Most individuals fell into the young adult (18-25 years) or prime adult category (26-35 years) and a single Skeleton was an older adult (45+ years).

With the exception of Skeletons Sk 4, Sk 55, Sk 57, Sk 68 and Sk 91 all these Skeletons manifested other diagnostic criteria. In the case of Sk 91, no other relevant Skeletal elements survived.

Sk. No.	Phase	Age	Sex	RMS	Forearms	Hands	Feet	Lower legs	Comments
3	1	adult (18+ yrs)	?	-	No	no	-	Yes, distal half	Little of hands surviving
4	1	young adult (18-25 yrs)	F	yes	No	-	-	-	Cal AD 1150-1300 (92.1% probability)
5	1	older adult (45+ yrs)	?	-	No	-	no	Yes, location unclear	Little of forearms survives
8	1	prime adult (26-35 yrs)	M	-	No	No	yes	Yes, distal 1/2	
9	1	prime adult (26-35 yrs)	F	-	No	no	yes	Yes, distal 2/3	No anterior maxilla
10	1	adult (18+ yrs)	?	-	No	yes	yes	Yes, distal 1/3	
14	1	adult (18+ yrs)	F	-	No	no	no	Yes, distal 2/3	
15	1	young adult (18-25 yrs)	F	-	No	no	yes	Yes, distal 2/3	
16	1	older adult (45+ yrs)	M	yes	No	no	yes	No	
17	1	older adult (45+ yrs)	M	-	No	yes	yes	Yes, location unclear	
18	1	prime adult (26-35 yrs)	M	yes	Yes	yes	yes	yes	Cal AD 1030-1208 (95.4% probability)
21	1	adult (18+ yrs)	?	-	No	no	yes	Yes, distal 2/3	Cal AD 1150-1300 (93.4% probability)
25	1	Young adult (18-25 years)	?	-	No	no	-	-	
26	1	Adult (18+ years)	?	-	No	-	-	-	
28	1	Adult (18+ years)	?	-	-	-	-	no	
30	1	Adult (18+ years)	?	-	No	-	-	-	
31	1	adolescent (13-17 yrs)	n/a	-	Yes	no	no	Yes, distal 1/2	
32	1	mature adult (36-45 years)	M	-	No	no	yes	Yes, distal 1/3	
35	1	adult (18+ yrs)	?	-	No	no	yes	Yes, distal 1/3	
38	1	adult (18+ yrs)	?	-	-	-	yes	no	
42	1	mature adult (36-45 years)	F	Yes?	No	no	yes	Yes, distal 2/3	
43	1	adult (18+ yrs)	?	-	No	no	yes	Yes, distal 2/3	
45	1	prime adult (26-35 yrs)	F	yes	Yes	no	no	Yes, distal 2/3	little of feet surviving
46	1	Adult (18+ years)	?	-	-	-	-	-	
48	1	adult (18+ yrs)	?	-	No	no	no	Yes, location unclear	little of hands/feet surviving
49	1	Adult (18+ years)	?	-	-	-	no	no	
50	1	adult (18+ yrs)	?	-	No	no	no	Yes, distal 1/2	
51	1	young adult (18-25 yrs)	M	yes	No	no	no	Yes, entire shaft	
52	1	adult (18+ yrs)	?	-	-	-	no	Yes, distal 2/3	little of feet surviving

Sk. No.	Phase	Age	Sex	RMS	Forearms	Hands	Feet	Lower legs	Comments
55	1	adult (18+ yrs)	I	yes	No	no	no	No	little of hands, feet, lower legs surviving
57	1	adult (18+ yrs)	M	yes?	No	no	no	No	
58	1	Adult (18+ years)	?	-	No	-	-	-	
59	1	Young adult (18-25 years)	M?	-	No	no	-	no	
60	1	adolescent (13-17 yrs)	n/a	no	Yes	no	yes	Yes, midshaft	little of hands/feet surviving
61	1	adult (18+ yrs)	?	-	No	-	no feet	Yes, distal 1/2	
62	1	Adult (18+ years)	M	-	No	no	-	No	
63	1	adult (18+ yrs)	?	-	Yes	yes	yes	Yes, distal 2/3	
64	1	adult (18+ yrs)	?	-	No	no	yes	Yes, distal 1/3	
66	1	?adult (18+ years)	?	-	-	-	-		
68	1	Prime adult (26-35 years)	?	yes	No	no	-	-	Little of hands surviving
69	2	mature adult (36-45 years)	F	yes	No	no	yes	Yes, distal 1/2	little of hands surviving
70	1	adult (18+ yrs)	M?	no	No	no	no feet	Yes, distal 2/3	
72	1	young adult (18-25 yrs)	M	no	No	no	yes	Yes	
73	1	adult (18+ yrs)	M	-	No	no	yes	Yes, distal 2/3	
74	1	adult (18+ yrs)	I	-	No	no	yes	Yes, distal 2/3	
75	1	Adult (18+ years)	M	-	Yes	no	-	-	Little of hands survived
76	1	mature adult (36-45 years)	M	yes?	No	yes	yes	Yes, distal 2/3	
77	1	adult (18+ yrs)	?	-	-	no	no	Yes, distal 2/3	little of hands surviving
80	1	prime adult (26-35 yrs)	I	yes	No	no	yes	Yes, distal 1/3	
84	1	prime adult (26-35 yrs)	M	yes?	No	no	no	Yes	
85	1	prime adult (26-35 yrs)	F	yes	No	no	yes	Yes, distal 1/3	little of hands/feet surviving; cal AD 1280-1420 (95.5% probability)
87	1	Older adult (45+ years)	M?	no	-	no	-	-	Little of hands surviving
88	1	adult (18+ yrs)	M	no	No	no	yes	Yes	
91	1	prime adult (26-35 yrs)	M	yes	-	-	-	-	left and right maxilla may not be a pair
92	1	Adult (18+ years)	F?	no	No	no	-	-	Little of hands surviving
94	1	prime adult (26-35 yrs)	F?	-	No	no	no	Yes, distal 2/3	little of feet surviving
95	1	Prime adult (26-35 years)	M	-	-	-	-	-	
99	1	Adult (18+ years)	F	-	-	-	no	No	

Sk. No.	Phase	Age	Sex	RMS	Forearms	Hands	Feet	Lower legs	Comments
100	1	Adult (18+ years)	M?	-	No	no	-	-	Little of hands surviving
104	1	prime adult (26-35 yrs)	M	-	Yes	yes	yes	Yes, distal 2/3	
105	1	Adult (18+ years)	?	-	Yes	no	-	-	
106	1	Adult (18+ years)	?	-	-	no	no	no	
108	1	Adult (18+ years)	?	-	-	-	-	no	
110	1	adult (18+ yrs)	?	-	No	no	yes	No	
111	1	Adult (18+ years)	?	-	-	-	-	-	
112	1	prime adult (26-35 yrs)	F	-	No	yes	-	-	
113	1	Adult (18+ years)	M?	-	No	no	no	no	
115	1	Adult (18+ years)	?	-	-	no	no	no	
118	1	young adult (18-25 yrs)	M?	yes	No	no	-	-	Very little of forearms surviving
119	1	Adolescent (16-18 years)	n/a	-	-	-	-	-	
121	1	Prime adult (26-35 years)	F?	no	-	-	-	-	
125	1	Young adult (18-25 years)	F	-	No	no	-	-	
127	1	Adult (18+ years)	M?	-	No	no	no	no	
128	1	prime adult (26-35 yrs)	M	-	No	-	no	Yes, distal 1/2	
129	1	Prime adult (26-35 years)	M	-	No	no	-	-	Little of hands surviving
130	1	Adult (18+ years)	?	-	-	-	-	Yes	
133	1	Young adult (18-25 years)	M?	-	No	no	-	-	
134	1	Adult (18+ years)	M	-	No	no	-	-	
136	1	adolescent (13-17 yrs)	n/a	-	-	-	yes	Yes, distal 1/3	
138	1	Adult (18+ years)	?	-	-	-	no	No	
141	1	Adult (18+ years)	?	-	No	no	no	no	Little of hands and feet surviving
142	1	adult (18+ yrs)	?	-	No	-	-	Yes, location unclear	
143	1	older adult (45+ yrs)	?	-	-	no	no	Yes, distal 1/2	little of forearms/hands /feet surviving

**Table 28: Summary of the potential evidence for leprosy, Phase 1**

Key: - = bone not present; I = indeterminate; RMS = rhino-maxillary syndrome

Sk 4, a young adult female, exhibited abnormal porosity on the palate, abnormal porosity and new bone deposition on the left nasal floor with extensive remodelling on the left side of the nasal aperture. The right side did not survive. There was a suggestion of a possible concave profile although insufficient survived to be certain. No other pathological changes to the Skeleton were observed.



Sk 16, an older adult male, exhibited considerable resorption of the maxillary alveolar process which was more severe on the left side (see Plates 27 and 28 below). Lytic lesions and new bone deposition were present on the palate. There was also destruction of the anterior nasal spine with resorption and remodelling of the surviving portion of the nasal aperture. There was a suggestion of a concave facial profile though insufficient survived to be certain. This Skeleton also exhibited localised gross destruction of the head of the right first metatarsal which was most severe on the plantar surface. A very similar example was seen at St James and St Mary Magdalene, Chichester (Ortner 2008, 205, fig. 14.13). The head of the left first distal foot phalanx had also been destroyed by probable septic arthritis although the changes were partly obscured by post-mortem damage. A further fragment of unidentified possible foot phalanx also exhibited gross destruction and remodelling, again probable as a result of septic arthritis.



**Plate 27: Skeleton 16, rhino maxillary change**



**Plate 28: Skeleton 16, abnormal porosity of the palate**

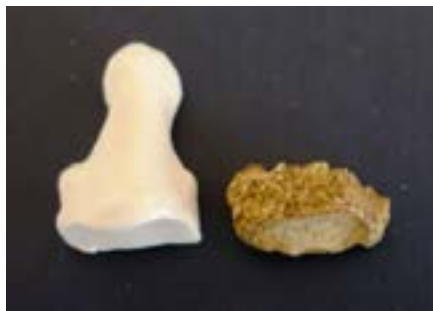Sk 18, a prime adult male, exhibited abnormal porosity on the nasal floor and remodelling of the nasal aperture which appeared more severe on the left side although the right had suffered post-mortem damage. There was also destruction of the anterior nasal spine and marked destruction of the alveolar bone in the region of the incisors and canines. There was a suggestion of a concave facial profile, though insufficient survived to be certain. Characteristic changes to the right forearm, the hands, lower legs and feet make this a convincing example of lepromatous leprosy (see Plate 29 below). Three periosteal lesions were present on the right ulna and many of the bones of the hands had woven bone

deposits. The distal half of the left and right tibiae shafts exhibited thick deposits of woven bone which was creamy white in colour and located on the lateral side of the anterior crest. The left and right fibulae exhibited thick and florid deposits of woven bone.



**Plate 29: Skeleton 18, new bone deposition on left fibula shaft**

The right fifth metatarsal exhibited severe blade-like remodelling with marked periosteal new bone deposition on the lateral and medial sides of the shaft. The plantar and dorsal surfaces were less severely affected. The right first distal foot phalanx was mostly destroyed possible as a consequence of septic arthritis (see Plate 30 below) while the left fifth intermediate and distal foot phalanges were fused, possibly indicative of claw toe deformity. The latter may be indicative of claw toe deformity (see Appendix 1a for full details of pathological changes).



**Plate 30: Skeleton 18, destruction of right proximal foot phalanx 2**

Sk 42, a mature adult female, exhibited changes to the left side of the nasal aperture which appeared smoother than the right. The anterior maxillary sockets were normal although there was post-mortem damage. The tibiae and fibulae had diffuse deposits of woven, grey, periosteal new bone, affecting all surfaces and extending over the distal 2/3 of the shafts. Evidence of a probable chronic ulcer was seen on the left tibia. The right third intermediate foot phalanx had abnormal porosity on the plantar surface. While the rhino-maxillary changes are inconclusive, the distribution of other lesions makes this a probable case of lepromatous leprosy.

Sk 45, a prime adult female, exhibited resorption of the anterior maxillary sockets, abnormal palatal porosity, new bone deposition and abnormal porosity on the left and right nasal floor. There was remodelling of the anterior nasal spine. The surviving portion of the left and right nasal aperture was smooth and remodelled with a suggestion of a concave facial

profile. Periosteal lesions were present on the right radius and ulna, fibulae and tibiae. No pathological changes were observed on the feet.

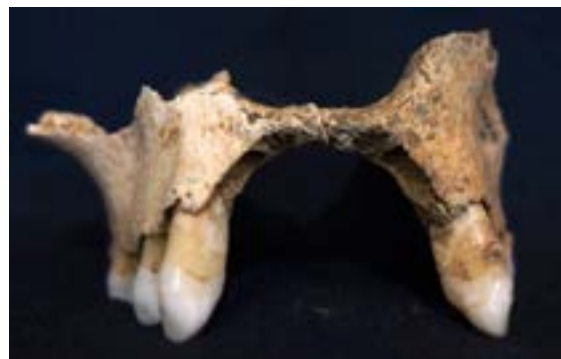Sk 51, a young adult male, exhibited abnormal porosity of the palate with remodelling of the surviving portion of the nasal aperture. There was also post-mortem damage. Periosteal lesions were present on the tibiae and a possible chronic ulcer was identified on the left fibula. No pathological changes were observed on the feet.

Sk 55, an adult of indeterminate sex, exhibited abnormal porosity of the nasal floor (left and right) with resorption of the anterior sockets and remodelling of the surviving portion of the nasal aperture. No other pathological changes were observed on the Skeleton.

Sk 57, an adult male, exhibited resorption of the anterior maxillary sockets and remodelling of the nasal aperture. Only a small portion of the right side survived. No other pathological changes were observed on this Skeleton.

Sk 68, a prime adult of indeterminate sex, exhibited abnormal palatal porosity and resorption of the anterior sockets. The nasal region did not survive, nor did the lower legs or hands. No pathological changes to the forearms or feet were observed.

Sk 69, a mature adult female aged 36-45 years, exhibited ante-mortem loss of the maxillary incisors with extreme destructive remodelling of the anterior alveolar process (see Plate 31 below). There was also some resorption of the sockets for the maxillary canines and the right first premolar along with destruction of the anterior nasal spine. The surviving portion of the left side of the nasal aperture was smooth and remodelled and there was abnormal porosity of the palate and the nasal floor. Insufficient survives to be certain but there is a definite suggestion of a concave facial profile. This is the best example in the assemblage. Striated lamellar bone was present on the distal half of the tibiae and there were periosteal lesions on the plantar surface of a probable left second metatarsal.



**Plate 31: Skeleton 69, rhino-maxillary changes**

Sk 76, a mature adult male, exhibited abnormal porosity on the palate with mild new bone deposition along the midline. While the evidence for rhino-maxillary change was not convincing many other pathological changes were observed. Changes to the bones of the hand comprised abnormal porosity and new bone deposition with ankylosis of hand phalanges, possible osteomyelitis and septic arthritis which had resulted in the destruction

of many of the joints. Fusion of intermediate and distal phalanges of the hand was suggestive of claw hand deformity. Periosteal lesions were present on the bones of the lower legs and changes to the feet included the destruction of distal articulations with blade-like remodelling of the metatarsal shafts. Tarsal exostoses were also present. Destruction of the metatarso-phalangeal joints in the feet was suggestive of septic arthritis and transverse arch collapse.

Sk 80, a prime adult of indeterminate sex, exhibited abnormal porosity and new bone deposition on the right side of the nasal floor with remodelling of the nasal aperture. There was no resorption of the anterior sockets on the left side. The right did not survive. There was clear evidence of osteomyelitis which affected the right tibia and the left fibula. In the case of the fibula the entire shaft was affected though it was much more severe on the lateral side. On the distal half of the bone there was a profusion of woven bone which measured up to 10.15 mm in thickness (see Plate 32). Abnormal porosity was present on the shafts of the right third, fourth and fifth metatarsals.



**Plate 32: Skeleton 80, new woven bone deposition on left fibula**

Sk 84, a prime adult male, exhibited resorption of the anterior alveolar bone in the region of the right maxillary incisors and right canine with abnormal porosity of the palate. Evidence of active periostitis and four possible chronic ulcers were observed on the tibiae (see Plate 33 below).



**Plate 33: Skeleton 84, chronic ulcer on tibia**

Sk 85, a prime adult female, exhibited remodelling of the nasal aperture and destruction of the anterior nasal spine. There was woven bone on the floor of the nasal aperture and

marked resorption of the anterior sockets with a possible concave facial profile. Periosteal lesions were observed on the lower legs and feet.

Sk 91, a prime adult male, exhibited abnormal porosity and new bone deposition on the right side of the nasal floor. The right side of the nasal aperture did not survive, nor did the anterior nasal spine. The forearms, hands, lower legs and feet of this Skeleton did not survive. This may be an example of early rhino-maxillary change.

Sk 118, a young adult male, exhibited abnormal porosity on the left side of the palate with probable remodelling of the surviving portion of the nasal aperture. There was abnormal porosity of the left nasal floor and severe resorption of the alveolar process around the socket for the maxillary left first incisor. No other pathological changes were observed on this Skeleton, although the lower legs and feet did not survive.

#### *Phase 1 - Changes to the forearms*

A total of eight Skeletons in Phase 1 exhibited pathological changes to the forearms (Sk 18, Sk 31, Sk 45, Sk 60, Sk 63, Sk 75, Sk 104 and Sk 105). Only those examples not considered elsewhere appear in this section.

Sk 31, an adolescent aged 13-17 years, had active periosteal lesions on the left radius, left femur and lower legs. The maxilla did not survive. These changes have been diagnosed as non-specific.

Sk 60, an adolescent aged 15-17 years, had active periosteal lesions on the left radius and ulna, tibiae, fibulae and metatarsals. Three probable chronic ulcers were evidenced by well demarcated areas of irregular woven bone associated with slight swelling on the lateral and medial side of the left tibia. The rhino-maxillary area survived but no pathological changes were observed. The lesions have been diagnosed as possibly indicative of lepromatous leprosy.

Sk 63, an adult of uncertain sex, had active periosteal lesions on the left ulna, metacarpals and phalanges of the hand, the lower legs and metatarsals. The rhino-maxillary area did not survive. These lesions have been diagnosed as non-specific.

Sk 75, an adult male, exhibited periosteal lesions on the ulnae. There were no pathological changes to the hands. The rhino-maxillary area, lower legs and feet did not survive. These changes have been diagnosed as non-specific.

Sk 104, a prime adult male, had active periosteal lesions on the left ulna, the metacarpals and a proximal phalanx. Both active and healed lesions were present on the tibiae and fibulae. Septic arthritis is suggested by the destructive remodelling of the metatarso-phalangeal joints and transverse arch collapse. Both navicular bones had dorsal exostoses. This Skeleton has been diagnosed as a probable case of lepromatous leprosy.

Sk 105, an adult of uncertain sex, had a periosteal lesion on the right radius which appeared to be healed. No pathological changes to the hands were observed. The rhino-maxillary area, lower legs and feet did not survive. These changes have been diagnosed as non-specific.

The CPR at St Leonard's is 9.64% (8/83) while the TPR is 12.69% (8/63).

*Phase 1 - Changes to the hands*

Only seven Skeletons in Phase 1 exhibited changes to the hands (Sk 10, Sk 17-18, Sk 63, Sk 76, Sk 104 and Sk 112) which for the most part were much less severe than those observed on the feet. Only those examples not considered elsewhere appear in this section.

Abnormal porosity was present on the dorsal shafts of the left 5<sup>th</sup> metacarpal and right 4<sup>th</sup> proximal hand phalanx of Sk 10, an adult of uncertain sex. Periosteal lesions were observed on the lower legs and abnormal porosity was observed on the metatarsals. There was also a dorsal exostosis on the left navicular. There was no surviving maxilla. These lesions have been diagnosed as possibly indicative of lepromatous leprosy.

The left second and third metacarpals of Sk 17 had woven bone deposits on the dorsal shafts close to the distal articulations. There was no surviving maxilla. Both active and healed periosteal lesions were observed on the lower legs and the feet suggesting a long-standing or recurring condition. These lesions have been diagnosed as possibly indicative of lepromatous leprosy.

Sk 112 presented new bone deposition on the bones of the right hand as well as volar grooves and destruction of at least two distal articulations of phalanges. Abnormal porosity was also observed on the surviving portion of the palate. This was the only example of volar grooves in the assemblage. This individual also exhibited destruction of two distal articulations and abnormal porosity of the palate was noted. The latter may be suggestive of early-stage rhino-maxillary change. These lesions have been diagnosed as probably indicative of lepromatous leprosy.

Five Skeletons at Chichester had leprous infection of the hand in conjunction with periostitis of the forearm (Lee and Manchester 2008, 212). Jopling (1984) considered periostitis to be rare in the bones of the lower arm. The CPR at St Leonard's is 8.43% (7/83) while the TPR is 11.86% (7/59).

*Phase 1 - Changes to the legs*

The sequence of events that leads to deposition of sub-periosteal bone on the lower legs is unclear and a number of arguments have been advanced (Jopling 1984). In archaeological populations, because the disease process is fixed at the time of death it is not possible to determine whether the foot or facial changes occurred first, or whether tuberculoid leprosy downgraded to lepromatous (Lee and Manchester 2008, 215).

At Chichester, the most significant changes appeared as a smooth profuse undulating layer of new bone applied to the cortical surface and the deposits are described as having an indolent appearance resembling molten lead (Lee and Manchester 2008, 214, fig. 16.12). The changes are bilateral and are most marked on adjacent surfaces of the tibiae and fibulae along the attachment of the interosseous membrane.

Pathological changes to the lower legs were exhibited by 42 individuals (Sk 3, Sk 5, Sk 8-10, Sk 14-15, Sk 17-18, Sk 21, Sk 31-32, Sk 35, Sk 42-43, Sk 45, Sk 48, Sk 50-52, Sk 60-61, Sk 63-64, Sk 69-70, Sk 72-74, Sk 76-77, Sk 80, Sk 82, Sk 84-85, Sk 88, Sk 94, Sk 104, Sk 128, Sk 136 and Sk 142-143). Only those examples not considered elsewhere appear in this section. The CPR at St Leonard's is 50.60% (42/83) while the TPR is 71.19% (42/59).

Sk 8, a prime adult male, exhibited lamellar lesions of the right distal tibia shaft, either side of the anterior crest and on all surfaces of the shaft of the left first metatarsal. These lesions have been classified as non-specific.

Sk 9, a prime adult female, exhibited woven bone on all surfaces of the tibiae and the fibulae, affecting at least the distal two thirds of the shafts. Deposits were also noted on all surfaces of the left first metatarsal. The shaft of the left second or third is thickened with visible involvement of the medullary cavity and woven bone deposition. Probable destruction of the distal articulation was also likely although there was post-mortem damage. The left fourth metatarsal was similarly affected. There was also a lytic defect (possible cloaca) on the lateral side of the shaft immediately distal to the proximal articulation.

Woven bone was present on all shafts of the left fifth metatarsal which had post-mortem damage to the distal articulation. The left first proximal foot phalanx exhibited destruction of the proximal and distal articulations and the shaft was thickened with woven bone on the dorsal surface. The left second proximal foot phalanx also exhibited destruction of the proximal and distal articulations with thickening of the shaft and woven bone on the plantar surface. Destruction of the metatarso-phalangeal joints is suggestive of septic arthritis and transverse arch collapse. These changes have been diagnosed as evidence of probable lepromatous leprosy.

Sk 15, a young adult female, had both healed and active lesions on the distal two thirds of the tibiae and the fibulae. Woven bone and abnormal porosity was present on the dorsal surfaces of the right and left fourth metatarsals. The changes have been categorised as non-specific.

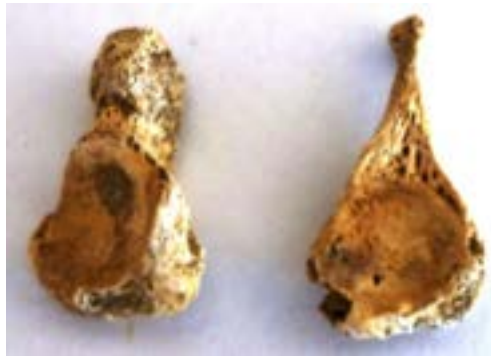Sk 21, an unsexed adult, exhibited woven bone on the distal half of the tibia and the distal two thirds of the fibulae. Woven bone was also observed on the shafts of the right and left fifth, and left second and fourth metatarsals. The distal articulations of two unidentified foot phalanges are suggestive of possible septic arthritis. These changes have been diagnosed as possible lepromatous leprosy.

Sk 32, a mature adult male, exhibited changes to the feet only. Abnormal porosity and woven bone deposits were observed on the shafts of the metatarsals and the phalanges. Destruction of the distal articulations of the first and second right foot phalanges and the left distal third foot phalanx is suggestive of septic arthritis. Healed lamellar bone was present on the anterior and medial surfaces of the distal third of the tibiae. No pathology was observed on the fibulae. This Skeleton was diagnosed as possibly having lepromatous leprosy.

Sk 35, an unsexed adult, exhibited woven bone on the distal third of the left tibia. The deposits on the right tibia are lamellar. Lamellar bone was present on the proximal third of the shaft of the right fibula, and the distal third of the left fibula. Woven bone was present on the distal third of the right fibula. Woven bone was also observed on the entire shaft of the right first metatarsal. The distal articulation of the right proximal foot phalanx was expanded with abnormal porosity on the dorsal and plantar surfaces. The distal articulation

of the left first proximal foot phalanx had suffered destructive remodelling, probably as a result of septic arthritis. This has been diagnosed as a possible case of lepromatous leprosy.

Sk 43, an unsexed adult, exhibited creamy-white woven bone on the medial, anterior and lateral surfaces of the tibiae. It was most severe on the lateral surface and the distal two thirds were affected. The lateral and medial surfaces of the distal two thirds of the fibulae were also affected. A possible tarsal bar was observed on the dorsal surface of the right cuboid. There was no surviving navicular and the other tarsals were unaffected. There was advanced destruction of the right first, second and third metatarsals with only the proximal articulation and a small part of the shafts surviving. This is described as pencilling or sucked candy (see Ortner 2008, fig. 14.12). The left second, fourth and fifth metatarsals exhibited blade-like remodelling. Pencilling of the shafts of two left proximal foot phalanges was observed and destructive remodelling of the distal articulations had occurred, probably caused by septic arthritis. Cupping of the proximal articulations was also observed (see Plate 34 below).



**Plate 34: Skeleton 43, left proximal foot phalanges, plantar view**

The destruction of the metatarso-phalangeal joints is suggestive of transverse arch collapse. Proliferation of woven bone and abnormal porosity was present on the posterior surface of the left calcaneus. This Skeleton has been diagnosed as a probable case of lepromatous leprosy. The destruction of the metatarso-phalangeal joints is suggestive of transverse arch collapse. Proliferation of woven bone and abnormal porosity was present on the posterior surface of the left calcaneus. This Skeleton has been diagnosed as a probable case of lepromatous leprosy.

Sk 64, an unsexed adult, exhibited woven bone on the lateral surface of the right tibia at the distal end; nothing was observed on the left tibia which was highly fragmented. Woven bone was also observed on the fibulae and was more severe on the left side. Lamellar bone was present on the lateral side of the left fifth metatarsal shaft. These changes have been characterised as non-specific.

Sk 70, a probable male adult, exhibited woven bone on the medial and lateral surfaces of the tibiae which was more severe on the lateral and affected the distal two thirds of the shaft. The medial and anterior surfaces of the fibulae were affected and the deposits extended



across the distal two thirds of the shafts, becoming more diffuse towards the midshaft. These lesions have been categorised as non-specific.

Sk 72, a young adult male, exhibited woven bone on the medial, lateral and anterior surfaces of the left tibia which extended as far as the tibial tuberosity. The distal half of the left tibia was also affected but less severely. Woven bone was also observed on the plantar surface of the left third metatarsal while lamellar bone was present on the plantar surface of the left fourth metatarsal. These lesions have been categorised as non-specific.

Sk 73, an adult male, exhibited lamellar bone on the distal two thirds of the shafts in addition to thick and florid deposits of woven bone which were largely confined to the distal third of the tibiae. The distal two thirds of the left fibula also had thick and florid deposits of woven bone; the right fibula did not survive. Woven bone was present on the plantar surface of the left fifth metatarsal. Possible destructive remodelling of the distal articulation of the right first proximal foot phalanx was partly obscured by post-mortem damage. Destructive remodelling at the distal end of the right first distal foot phalanx was observed. Both are suggestive of septic arthritis. This Skeleton has been diagnosed as a possible case of lepromatous leprosy.

Sk 74, an adult of indeterminate sex, exhibited woven bone on the medial and lateral surfaces of the distal third of the fibulae. A probable chronic ulcer was observed on the posterior surface of the left fibula in the proximal third. An area of reactive bone combined with swelling had a well demarcated border. Lamellar bone was observed on the tibiae. Destructive remodelling of the distal end of the right first distal phalanx is suggestive of possible septic arthritis. A tarsal bar was identified on the left navicular bone. This Skeleton has been diagnosed as a possible case of lepromatous leprosy.

Sk 88, an adult male, exhibited lamellar bone on the medial side of the tibiae, running the length of the shaft and more severe on the right bone. Diffuse patches of woven bone were present on the lateral surface of the right fibula, affecting the proximal third. Woven bone was also present on the lateral surfaces of the calcanei. These changes have been diagnosed as non-specific.

Sk 130, an unsexed adult, exhibited diffuse woven bone on two conjoining fragments of the left fibula, on the medial and anterior surfaces. The right fibula was similarly affected. These changes have been diagnosed as non-specific.

Sk 136, an adolescent, exhibited woven bone on the lateral side of the medial third of the shaft, anterior to the interosseous crest; lamellar bone extended along the full length of the medial surface. A probable chronic ulcer was observed on the medial surface of the right tibia at the distal end; lamellar bone extended along the full length of the medial surface. A second probable chronic ulcer was observed on the lateral side of the right fibula. Destructive remodelling of the distal articulation of the right 1<sup>st</sup> metatarsal was observed along with thickening of the shaft may be evidence of osteomyelitis. Destruction of the distal end of the right first distal phalanx is suggestive of possible septic arthritis. Fusion of the left fifth intermediate and distal foot phalanges is probable evidence of claw toe deformity. This Skeleton has been diagnosed as a possible case of lepromatous leprosy.

A total of 13 Skeletons exhibited pathological changes to the legs only (Sk 3, Sk 5, Sk 14, Sk 48, Sk 50, Sk 52, Sk 61, Sk 77, Sk 94, Sk 128, Sk 130 and Sk 142-143). There is insufficient evidence in these examples to suggest a diagnosis of leprosy. All have been categorised as non-specific infection.

*Phase 1 - Changes to the feet*

Changes to the feet in leprosy are secondary and result from the loss of sensation in the foot leading to painless superficial trauma, ulceration and secondary bacterial invasion, pyogenic osteomyelitis and septic arthritis (Lee and Manchester 2008, 215).

A total of 27 Skeletons exhibited pathological changes to the feet (Sk 8-10, Sk 15-18, Sk 21, Sk 32, Sk 35, Sk 38, Sk 42, Sk 60, Sk 63-64, Sk 69, Sk 72-74, Sk 76, Sk 80, Sk 82, Sk 85, Sk 88, Sk 104, Sk 110 and Sk 136). In most cases Skeletons also exhibited changes to the lower limbs and/or hands. The CPR at St Leonard's is 32.53% (27/83) while the CPR is 54% (27/50). There is a good correlation with Skeletons exhibiting rhino-maxillary changes.

Sk 38, an unsexed adult, exhibited destructive remodelling of the distal articulation of the left second foot phalanx, suggestive of septic arthritis. Abnormal porosity was observed on the dorsal surfaces of the surviving metatarsal shafts. Woven bone was observed on the anterior and lateral surfaces of the distal shaft of the left tibia. Woven bone on the distal two thirds of the left fibula shaft was thicker and more severe. The anterior, medial and posterior surfaces were affected. The deposits become more diffuse on the proximal third of the shaft. The right tibia and fibula were less severely affected. This Skeleton has been diagnosed as a possible case of lepromatous leprosy.

Sk 64, an unsexed adult, exhibited woven bone deposition on the lateral surface of the right tibia at the distal end. No lesions were observed on the left tibia which was highly fragmented. Woven bone was also observed on the shafts of the fibulae being more severe on the left bone. Lamellar bone was observed on the shaft of the left fifth metatarsal. These lesions have been diagnosed as non-specific.

Sk 110, an unsexed adult, exhibited destructive remodelling of the distal articulation of the left third proximal foot phalanx, suggestive of septic arthritis. These changes have been diagnosed as non-specific.

Blade-like/knife-like remodelling (see Plate 35 below) of the metatarsal shafts was observed in 3 Skeletons (Sk 18, Sk 43 and Sk 76) while destruction of the distal articulations of metatarsals (see Plate 36 below) was observed in the feet of 14 Skeletons (Sk 9, Sk 16-17, Sk 21, Sk 32, Sk 35, Sk 38, Sk 43, Sk 73-74, Sk 76, Sk 104, Sk 110 and Sk 136). This is probably as a consequence of septic arthritis. Septic arthritis may lead to ankylosis of the interphalangeal joints and give rise to claw toe deformity.

Tarsal exostoses, possibly tarsal bars were observed in the feet of 6 Skeletons (Sk 10, Sk 43, Sk 74, Sk 76, Sk 104 and Sk 127).



**Plate 35: Skeleton 76, blade-like remodelling of the left 5th metatarsal**



**Plate 36: Skeleton 136, destruction of distal articulation of right 1st metatarsal**

*Phase 2 - Rhino-maxillary change*

A total of three Skeletons in Phase 2 exhibited evidence of rhino-maxillary change (Sk 23, Sk 82 and Sk 97). A further three were diagnosed as probable cases (Sk 67, Sk 78 and Sk 120). Five were males and one was female. There was a fairly even distribution of ages with one adult, one young adult, two mature adults and two older adults. The CPR for definite cases in Phase 2 at St Leonard's is 6.39% (3/47) with a TPR of 27.28% (3/11).

Sk 23, a mature adult female, exhibited considerable destructive remodelling of the anterior alveolar process, abnormal porosity of the palate, abnormal porosity and new bone deposition on the floor of the nasal aperture, and remodelling of the walls of the nasal aperture which were smooth. The facial profile was possibly concave but insufficient survived to be certain. Periosteal lesions on the lower legs were also observed. This Skeleton was diagnosed as a definite case of lepromatous leprosy.

Sk. No.	Phase	Age	Sex	RMS	Forearms	Hands	Feet	Lower legs	Comments
1	2	adult (18+ yrs)	?	-	-	-	yes	Yes, distal 1/3	
6	2	Adult (18+ years)	?	-	No	no	no	no	
7	2	adult (18+ yrs)	M	-	No	no	yes	Yes, ?midshaft	
12	2	adolescent (13-17 yrs)	n/a	-	No	no	yes	No	
23	2	mature adult (36-45 years)	F	yes	No	no	no	Yes, distal 2/3	
24	2	adult (18+ yrs)	?	-	-	no	no	Yes, distal 2/3	little of hands/feet surviving
33	2	Prime adult (26-35 years)	I	-	No	-	-	-	
34	2	adult (18+ yrs)	M?	-	No	no	yes	Yes, distal 1/2	Little of forearms surviving
36	2	adult (18+ yrs)	?	-	No	no	yes	No	lower legs highly fragmented
37	2	adult (18+ yrs)	M	-	No	no	no	Yes, distal 1/3	Cal AD 1380-1530 (89% probability)
40	2	adult (18+ yrs)	?	-	No	no	yes	Yes, distal 2/3	
44	2	young adult (18-25 yrs)	F?	-	No	no	yes	Yes, distal 2/3	
47	2	adult (18+ yrs)	?	-	No	no	no	Yes, distal 1/2	
54	2	adult (18+ yrs)	F	-	No	-	no	Yes, location unclear	
56	2	Adult (18+ years)	F	-	No	-	no	no	
67	2	mature adult (36-45 years)	M	yes?	No	no	yes	Yes, ?distal 2/3	little of hands surviving
71	2	adult (18+ yrs)	M	-	No	yes	no	Yes, distal 1/2	little of feet surviving
78	2	older adult (45+ yrs)	M	yes	No	no	-	Yes, distal 1/3	little of hands surviving
79	2	adult (18+ yrs)	M?	-	Yes	no	no	Yes, distal 1/3	little of feet surviving
81	2	prime adult (26-35 yrs)	M	-	No	no	no	Yes, location unclear	little of hands/feet surviving
82	2	Young adult (18-25 years)	M?	Yes?	No	no	yes	Yes	
83	2	prime adult (26-35 yrs)	F	no	No	no	no	Yes, midshaft	lace tag associated
86	2	Prime adult (26-35 years)	M	no	No	no	-	-	
89	2	prime adult (26-35 yrs)	M	no	-	-	-	-	
90	2	Prime adult (26-35 years)	M	Yes?	-	-	-	-	
93	2	Young adult (18-25 years)	M	-	No	no	no	no	
96	2	Young adult (18-25 years)	M	no	No	no	-	-	
97	2	adult (18+ yrs)	M	yes	No	no	no	Yes, distal 1/3	

Sk. No.	Phase	Age	Sex	RMS	Forearms	Hands	Feet	Lower legs	Comments
98	2	Adolescent (13-17 years)	n/a	-	No	no	-	-	
101	2	adult (18+ yrs)	M?	-	No	-	-	Yes, distal 2/3	lace tag associated
102	2	young adult (18-25 yrs)	?	-	No	no	yes	no	Little of forearms surviving
103	2	adult (18+ yrs)	M	-	No	no	yes	no	
107	2	Adult (18+ years)	?	-	No	no	-	-	
109	2	adult (18+ yrs)	?	-	-	-	yes	no	
114	2	Adult (18+ years)	?	-	-	-	no	No	
116	2	Adult (18+ years)	M?	-	No	no	no	no	
120	2	older adult (45+ yrs)	M	yes?	No	no	no	no	Cal AD 1300-1450 (95.4% probability)
122	2	adult (18+ yrs)	?	-	No	No	-	Yes, midshaft	little of hands surviving
123	2	adult (18+ yrs)	?	-	-	-	yes	-	
124	2	Adult (18+ years)	?	-	No	no	no	no	
126	2	older adult (45+ yrs)	F	-	Yes	no	-	Yes, midshaft	
132	2	Young juvenile (2-6 years)	n/a	-	No	-	-	Yes, distal 2/3	Lace tag associated; cal AD 1411-1486 (95.4% probability)
135	2	Adult (18+ years)	M	-	Yes	no	-	-	
137	2	adult (18+ yrs)	M	-	No	no	yes	no	
139	2	Adult (18+ years)	M	-	No	no	-	-	
140	2	Young adult (18-20 years)	M	-	-	-	-	-	
144	2	adult (18+ yrs)	M	-	No	no	yes	no	

**Table 29: Summary of the potential evidence for leprosy, Phase 2**

Key: - = bone not present; I = indeterminate; RMS = rhinomaxillary syndrome

Sk 82, a young adult male, exhibited advanced resorption of the anterior sockets and abnormal porosity of the palate. Little of the nasal aperture survived although the margins appeared normal. Periosteal lesions were present on the tibiae and fibulae. The joints of the right intermediate and distal 5<sup>th</sup> foot phalanges were fused together suggesting claw toe deformity. There was also probable remodelling and abnormal porosity which was partly obscured by post-mortem damage.

Sk 97, an adult male, exhibited abnormal porosity of the palate, resorption of the anterior sockets of the maxilla with associated abnormal porosity of the alveolar bone. There was no remodelling of the anterior nasal spine or the very small surviving portion of the nasal

aperture. Active periosteal lesions were present on the tibiae and there were three probable chronic ulcers which were demarcated by periosteal new bone and swelling of the shaft.

Sk 67, a mature adult male, is very tentatively included here. Two small fragments of the left and right maxilla had abnormal porosity affecting the palatal area. The nasal area did not survive. Periosteal lesions were seen on the lower legs and there were two small dorsal exostoses on the right navicular bone. This Skeleton was diagnosed as a probable case of lepromatous leprosy.

Sk 78, an older adult male, exhibited resorption of the anterior sockets and abnormal porosity of the palate. The nasal floor was normal. The nasal aperture and anterior nasal spine did not survive. Active periosteal lesions were observed on the lower legs.

Sk 120, an older adult male, exhibited abnormal porosity of the palate. Very little of the nasal aperture survived although there may have been some remodelling on the left side. The bone in the region of the anterior maxillary dentition was much resorbed. No changes to the nasal floor were observed.

*Phase 2 - Changes to the forearms*

Sk 79, an adult male, had healed periosteal lesions on the right distal ulna. Woven bone was observed on the tibiae and fibulae. This would have been active at the time of death. The rhino-maxillary area did not survive.

Sk 126, an older adult female, had a small healed periosteal lesion on the midshaft of the right radius. A combination of healed and unhealed lesions was present on probable midshaft fragments of the tibiae. The rhino-maxillary area did not survive.

Sk 135, an adult male, had a small healed periosteal lesion on the midshaft of the right radius. The rhino-maxillary area, lower legs and feet did not survive.

In the absence of classic indicators of leprosy these lesions are deemed to be non-specific.

*Phase 2 - Changes to the hands*

Sk 71, an adult male, exhibited woven bone on the palmar surfaces of all the surviving phalanges of the hands. There was also woven bone on the distal half of the left tibia which was most severe on the lateral and anterior surfaces. Some deposits were white and indolent in appearance, others were grey and more active in appearance. They became more diffuse towards the midshaft of the bones. The right tibia was highly fragmented but appeared much less severely affected. Both fibulae were similarly affected. Woven bone, white in colour, was also seen on the left calcaneus. The TPR for changes to the hands in Phase 2 was 2.86% (1/35). This Skeleton has been diagnosed as a possible case of lepromatous leprosy.

*Phase 2 - Changes to the lower legs*

A total of 22 Skeletons exhibited changes to the lower legs (see Table 28 above). In 11 examples no other Skeletal changes were present Sk 24, Sk 37, Sk 47, Sk 54, Sk 79, Sk 81, Sk 83, Sk 101, Sk 122, Sk 126 and Sk 132). The TPR for Phase 2 is 61.11% (22/36). When Skeletons with changes to the lower legs only are excluded this falls to 30.56% (11/36).

Changes to the lower legs only are not considered sufficient to suggest a diagnosis of leprosy.

Sk 1, an unsexed adult, had active periosteal lesions on the distal third of the left fibula. Deposits were also present on the shafts of the left first, second and fifth metatarsals. Probable septic arthritis was evidenced by partial destructive remodelling of the distal articulations of the fourth and fifth metatarsals, and the proximal articulation of the left third proximal foot phalanx. The destruction at the fourth and fifth metatarso-phalangeal joints is suggestive of transverse arch collapse. This Skeleton has been diagnosed as a probable case of lepromatous leprosy.

Sk 7, an adult male, exhibited woven bone deposition on the lateral side of the right tibia, the medial surface of the right fibula and the right first proximal foot phalanx. Probable septic arthritis was indicated by destruction of the distal articulations of the right first and second distal foot phalanges. This Skeleton has been diagnosed as probable case of lepromatous leprosy.

Sk 34, a probable adult male, exhibited healed periosteal lesions on the medial and lateral surfaces of tibiae at the midshaft. Healed lesions were also present on the distal third of the left fibula. Woven bone was also present on the right second, third and fifth metatarsals. These changes have been diagnosed as non-specific.

Sk 44, a probable young adult female, had a combination of healed and active lesions which were most severe on the distal third of the tibiae. Diffuse active lesions affected the distal two thirds of the right fibula. Active lesions were also present on the right second and third metatarsals. These were up to 5mm thick on the right second metatarsal. Active deposits were also present on the right proximal second and third foot phalanges. The left third proximal foot phalanx had abnormal porosity on the dorsal surface. These changes have been diagnosed as non-specific.

#### *Phase 2 - Changes to the feet*

A total of 14 Skeletons (Sk 1, Sk 7, Sk 12, Sk 34, Sk 36, Sk 44, Sk 67, Sk 82, Sk 102-103, Sk 108, Sk 123, Sk 137 and Sk 144) in Phase 2 exhibited pathological changes to the feet (CPR 29.79%, 14/47; TPR 43.75%, 14/32).

Sk 12, an adolescent aged 13-17 years, exhibited changes to the feet which included the deposition of woven bone, probable osteomyelitis and the destruction of the head of the left first distal foot phalanx, suggestive of septic arthritis. The right 5<sup>th</sup> intermediate foot phalanx was fused to the distal probably resulting in claw toe deformity. This Skeleton has been diagnosed as a probable case of lepromatous leprosy.

Sk 36, an unsexed adult, had woven bone and abnormal porosity on the plantar surface of the shaft of the right first metatarsal. Woven bone and abnormal porosity was also observed on the shafts of the right and left first proximal foot phalanges. Destructive remodelling of both distal articulations is suggestive of septic arthritis. The shaft of a probable left fifth metatarsal exhibited blade-like remodelling. This Skeleton has been diagnosed as a probable case of lepromatous leprosy.

Sk 102, an unsexed young adult, had woven bone on the lateral surfaces of the calcanei. These changes have been diagnosed as non-specific.

Sk 103, an adult male, exhibited woven bone on the shafts of the left first, third and fourth metatarsals. These changes have been diagnosed as non-specific.

Sk 109, an unsexed adult, exhibited woven bone on the shafts of the left third, left and right fourth metatarsals. These changes have been diagnosed as non-specific.

Sk 123, an unsexed adult, exhibited destructive remodelling of the distal articulation of the left second distal foot phalanx, suggestive of septic arthritis. Woven bone was observed on the shaft of the left first proximal foot phalanx, along with abnormal porosity. These changes have been diagnosed as non-specific.

Sk 137, an adult male, exhibited woven bone on the shafts of the left and right first metatarsals along with abnormal porosity. Destructive remodelling of the distal articulation of the left fourth proximal foot phalanx was observed, suggestive of septic arthritis.

Sk 144, an adult male, exhibited destructive remodelling of the first and second metatarso-phalangeal joints. Concentric remodelling of the shaft of the right first proximal foot phalanx and the right first distal foot phalanx was observed along with destructive remodelling of the distal articulation of the right second intermediate foot phalanx. Destructive remodelling is suggestive of septic arthritis. Claw toe deformity is suggested by the fusion of the fourth intermediate and distal foot phalanges. A possible tarsal bar was present on the right talus.

The TPR for changes to the feet at St Leonard's is 14/32.

#### 8.3.4.4 *Summary of the evidence*

The pathological changes described in the preceding section have been used to assign individual Skeletons to one of four categories as follows: Skeletons have been assigned to categories depending on the evidence available as follows:

- Skeleton has lepromatous leprosy – rhino-maxillary changes are present
- Skeleton is likely to have lepromatous leprosy – characteristic changes to hands and/or feet are present. These include claw hand, volar grooves, claw toe, transverse arch collapse, septic arthritis and osteomyelitis, although other conditions cannot be ruled out. It is stated where post-mortem damage hinders diagnosis.
- Skeleton may have leprosy – periosteal lesions involving the forearms and or lower legs. Other conditions cannot be ruled out.
- Non-specific infection – no classic changes or patterns of change that could be linked to leprosy.

In Phase 1 the Skeletons definitely diagnosed as cases of lepromatous leprosy comprised six males, three females, one unsexed adult and one indeterminate adult. All age categories were represented: there were four prime adults, two young adults, two mature adults, one older adult and two adults aged upwards of 18 years.

Lepromatous Skeletons in Phase 2 comprised one young adult male, one adult male aged upwards of 18 years and one mature adult female.



Of the four non-adults in Phase 1, one was diagnosed as a probable sufferer of lepromatous leprosy (136) and one as possible (60). A single probable non-adult in Phase 2 was identified (12).

The results are synthesised by phase in Table 30 below.

	Lepromatous leprosy (LL)	Probable LL	Possible LL	Non-specific infection
Phase 1	N = 11 (Skeletons 4, 16, 18, 45, 51, 55, 57, 69, 76, 80, 85)	N = 10 (Skeletons 9, 42, 43, 68, 84, 91, 104, 118, 112, 136)	N = 9 (Skeletons 10, 17, 21, 32, 35, 38, 60, 73, 74)	N = 24 (3, 5, 8, 14, 15, 3148, 50, 52, 61, 63, 64, 70, 72, 75, 77, 88, 94, 105, 110, 128, 130, 142, 143)
Phase 2	N = 3 (Skeletons 23, 82, 97)	N = 8 (Skeletons 1, 7, 12, 36, 67, 78, 120, 144)	N = 1 (71)	N = 20 (24, 34, 37, 40, 44, 47, 56, 79, 81, 83, 101, 102, 103, 109, 122, 123, 126, 132, 135, 137)
Total	14	18	10	44

**Table 30: Synthesis of the Skeletons diagnosed with leprosy, both phases**

### 8.3.5 Joint disease

Prevalence rates for joint disease were sub-divided by phase and by sex but not into age categories as the numbers in each category would have been too small to be meaningful.

#### 8.3.5.1 Extra-spinal joint disease

A total of 78 out of the 79 adult Skeletons from Phase 1 had one or more joints that could be scored. The CPR was 82% (64/78). Although the total prevalence of joint disease was low at 12.03%, all joints were affected to some degree. The rate of joint disease observed in males was almost double that of females, but this may not be significant given the high proportion of unsexed individuals in the group.

All 44 adults from Phase 2 had one or more joints that could be scored. The CPR was (39/44). The total prevalence was slightly higher in Phase 2, at 14.48%. Males were much more affected than females in this phase, at 18.25% and 4.76%. The jaw was the only joint that was unaffected. The data is presented in Tables 31-32.

#### 8.3.5.2 Extra-spinal osteoarthritis

Extra-spinal osteoarthritis was diagnosed by the presence of eburnation or at least two of either porosity, osteophytes and/or bony contour change (Rogers and Waldron 1995). The data is presented by phase in Tables 33-34.

A total of 10 adults in Phase 1 suffered from osteoarthritis. Although the total prevalence of this was very low at 1.92%, all joints with the exception of the jaw were affected. Male and female rates were almost equal at 1.85% and 1.37%.

A total of seven adults in Phase 2 suffered from osteoarthritis. Again, the total prevalence was very low at 1.48%, although fewer joints were affected. Males were affected more than females, at 1.75% and 0.26%.

#### 8.3.5.3 Spinal joint disease

Preservation of vertebrae in this assemblage was generally poor. A total of 56 Skeletons in Phase 1 had one or more vertebral bodies surviving, with 35 in Phase 2. Only 8 Skeletons in Phase 1, and 6 Skeletons in Phase 2 had all surviving vertebral bodies (6 cervical, 12 thoracic,

5 lumbar, 1 sacral). The total number of vertebral bodies observed in Phase 1 was 742, with 508 in Phase 2.

Spondylosis deformans is diagnosed by the presence of marginal osteophytosis and/or increased porosity of on the surfaces of the vertebral bodies (Rogers and Waldron 1995). The condition is caused by degeneration of the intervertebral disc and is associated with increasing age.

The results are presented by phase in Tables 35-36. The total prevalence rates in both phases were almost equal.

A total of 56 individuals in Phase 1 had one or more vertebral bodies that could be scored. Of that number, 41 exhibited some degree of spondylolosis deformans. The thoracic vertebrae were the most commonly affected overall. More males than females were affected although the proportion of unsexed adults was high

A total of 35 individuals in Phase 2 had one or more vertebral bodies that could be scored. Of that number 25 exhibited some degree of spondylolosis deformans. In this phase thoracic and lumbar vertebrae were affected in almost equal proportions and affected males outnumbered affected females by almost two to one.

		Male			Female			Unsexed			Indeterminate			Total		
Joint	Bone	With DJD	N	%	With DJD	N	%	With DJD	N	%	With DJD	N	%	With DJD	N	%
Jaw	TMJ	3	17	17.65	0	12	0.00	0	4	0.00	0	2	0.00	3	35	8.57
	Mandible	4	17	23.53	0	12	0.00	0	4	0.00	0	2	0.00	4	35	11.43
Manubrio-clavicular	Manubrium	0	4	0.00	1	6	16.66	0	0	0.00	0	1	0.00	1	11	9.09
	Medial clavicle	8	27	29.63	0	13	0.00	4	7	57.14	1	4	25.00	13	51	25.49
Shoulder	Lateral clavicle	4	25	16	0	8	0.00	3	7	42.86	0	1	0.00	7	41	17.07
	Glenoid	13	29	44.83	1	13	7.69	3	6	50.00	1	1	100.00	18	49	40.82
	Proximal humerus	1	23	4.35	0	8	0.00	0	3	0.00	0	1	0.00	1	35	2.86
Elbow	Distal humerus	4	26	15.38	3	9	33.33	1	7	14.29	0	2	0.00	8	44	18.18
	Proximal radius	0	18	0.00	3	13	23.08	5	9	55.55	0	1	0.00	8	41	19.51
	Proximal ulna	12	33	36.36	7	15	46.66	10	15	66.66	4	4	100.00	33	67	49.25
Wrist	Distal radius	10	29	34.48	1	10	10.00	4	6	66.66	2	2	100.00	17	47	36.17
	Distal ulna	5	21	23.81	1	10	10.00	3	8	37.50	1	3	33.33	10	42	23.81
	Scaphoid	8	30	26.66	0	9	0.00	3	17	17.65	1	2	50.00	12	57	21.05
	Lunate	8	31	25.80	0	8	0.00	2	17	11.76	0	2	0.00	10	57	17.54
Hand		34	269	12.64	4	91	4.39	12	49	24.49	2	18	11.11	52	524	9.93
Fingers		43	676	6.36	0	308	0.00	9	371	2.43	0	45	0.00	52	1396	3.72
Hip	Acetabulum	7	28	48	2	8	25.00	6	10	60.00	0	4	0.00	15	47	31.91
	Proximal femur	4	38	10.53	7	18	38.89	7	18	38.89	0	3	0.00	18	76	23.68
Knee	Distal femur	0	25	0.00	0	11	0.00	0	13	0.00	0	2	0.00	0	51	0.00
	Patella	3	23	13.04	1	9	11.11	4	8	50.00	2	2	100.00	10	42	23.81

Joint	Bone	Male			Female			Unsexed			Indeterminate			Total		
		With DJD	N	%	With DJD	N	%	With DJD	N	%	With DJD	N	%	With DJD	N	%
	Proximal tibia	3	19	15.79	2	9	22.22	1	6	16.66	0	1	0.00	6	35	17.14
	Proximal fibula	4	7	57.14	0	3	0.00	0	1	0.00	0	0	0.00	4	11	36.36
Ankle	Distal tibia	2	10.53	16.66	2	10	20.00	2	19	10.53	0	2	0.00	8	49	16.33
	Distal fibula	3	19	15.79	2	8	25.00	2	10	20.00	0	1	0.00	7	38	18.42
	Talus	8	24	33.33	1	8	12.50	8	24	33.33	1	2	50.00	18	58	31.03
Foot		46	189	24.34	8	53	15.09	37	168	22.02	0	27	0.00	94	437	21.51
Toes		27	230	11.74	1	50	2.00	11	163	6.75	0	17	0.00	41	460	8.91
<b>Total</b>		<b>264</b>	<b>1892</b>	<b>13.95</b>	<b>46</b>	<b>732</b>	<b>6.28</b>	<b>138</b>	<b>1072</b>	<b>12.87</b>	<b>15</b>	<b>152</b>	<b>9.87</b>	<b>463</b>	<b>3848</b>	<b>12.03</b>

**Table 31: Prevalence of degenerative joint disease in the extra-spinal joints (joints affected), Phase 1**

Key: TMJ = temporo-mandibular joint; P = proximal; D = distal; M = medial; Hand = proximal metacarpals, triquetral, pisiform; hamate, trapezium, capitate, trapezoid; Fingers = distal metacarpals and phalanges; Foot = calcaneus, cuboid, navicular, medial, lateral and intermediate cuneiforms and proximal metatarsals; Toes = distal metatarsals and phalanges.

Joint	Bone	Male			Female			Unsexed			Indeterminate			Total		
		With DJD	N	%	With DJD	N	%	With DJD	N	%	With DJD	N	%	With DJD	N	%
Jaw	TMJ	0	14	0.00	0	4	0.00	0	0	0.00	0	0	0.00	0	18	0
	Mandible	0	15	0.00	0	4	0.00	0	0	0.00	0	0	0.00	0	19	0
Manubrio-clavicular	Manubrium	2	6	33.33	0	0	0.00	0	0	0.00	2	2	100.00	4	8	50
	Medial clavicle	10	23	43.48	1	7	14.29	0	1	0.00	2	2	100.00	13	33	39.39
Shoulder	Lateral clavicle	6	16	37.5	2	2	100	1	1	100.00	0	2	0.00	9	21	42.86
	Glenoid	8	22	36.36	0	3	0.00	0	0	0.00	0	2	0.00	8	27	29.63
	Proximal humerus	1	19	5.26	0	3	0.00	0	0	0.00	0	1	0.00	1	23	4.35
Elbow	Distal humerus	7	27	25.93	0	5	0.00	1	5	20.00	0	2	0.00	8	39	20.51
	Proximal radius	5	21	23.81	0	4	0.00	0	3	0.00	0	2	0.00	5	30	16.67
	Proximal ulna	17	35	48.57	3	7	42.86	3	5	60.00	0	2	0.00	23	49	46.94
Wrist	Distal radius	13	27	48.15	3	4	75.00	0	2	0.00	0	0	0.00	16	33	48.48
	Distal ulna	4	19	21.05	0	2	0.00	1	2	50.00	0	0	0.00	5	23	21.74
	Scaphoid	8	27	29.63	0	5	0.00	1	3	33.33	0	0	0.00	9	35	25.71
	Lunate	9	22	40.91	0	4	0.00	1	3	33.33	0	0	0.00	10	29	34.48
Hand		40	216	18.52	2	47	4.26	3	43	6.98	0	0	0.00	45	306	14.71
Fingers		29	540	5.37	0	130	0.00	3	129	2.33	0	0	0.00	32	799	4.01
Hip	Acetabulum	13	24	54.17	0	5	0.00	2	2	100.00	0	0	0.00	15	31	48.39
	Proximal femur	22	35	62.86	2	8	25.00	3	5	60.00	0	0	0.00	27	48	56.25
Knee	Distal femur	6	21	28.57	0	5	0.00	0	2	0.00	0	0	0.00	6	28	21.43
	Patella	7	18	38.88	0	6	0.00	4	9	44.44	0	0	0.00	11	33	33.33

Joint	Bone	Male			Female			Unsexed			Indeterminate			Total		
		With DJD	N	%	With DJD	N	%	With DJD	N	%	With DJD	N	%	With DJD	N	%
	Proximal tibia	7	17	41.17	0	2	0.00	0	3	0.00	0	0	0.00	7	22	31.82
	Proximal fibula	1	5	20.00	0	1	0.00	0	2	0.00	0	0	0.00	1	8	12.50
Ankle	Distal tibia	8	21	38.09	3	6	50.00	1	8	12.5	0	0	0.00	12	35	34.29
	Distal fibula	8	18	44.44	0	2	0.00	0	11	0.00	0	0	0.00	8	31	25.81
	Talus	12	26	46.15	0	5	0.00	2	12	16.66	0	0	0.00	14	43	32.56
Foot		25	165	15.15	2	49	4.08	5	87	5.75	0	0	0.00	32	301	10.63
Toes		13	141	9.22	0	58	0.00	8	91	8.79	0	0	0.00	21	290	7.24
<b>Total</b>		<b>281</b>	<b>1540</b>	<b>18.25</b>	<b>18</b>	<b>378</b>	<b>4.76</b>	<b>39</b>	<b>429</b>	<b>9.09</b>	<b>4</b>	<b>15</b>	<b>26.66</b>	<b>342</b>	<b>2362</b>	<b>14.48</b>

**Table 32: Prevalence of joint disease in the extra-spinal joints (joints affected), Phase 2**

Key: TMJ = temporo-mandibular joint; P = proximal; D = distal; M = medial; Hand = proximal metacarpals, triquetral, pisiform; hamate, trapezium, capitate, trapezoid; Fingers = distal metacarpals and phalanges; Foot = calcaneus, cuboid, navicular, medial, lateral and intermediate cuneiforms and proximal metatarsals; Toes = distal metatarsals and phalanges.

Joint	Bone	Male			Female			Unsexed			Indeterminate			Total		
		With OA	N	%	With OA	N	%	With OA	N	%	With OA	N	%	With OA	N	%
Jaw	TMJ	0	17	0.00	0	12	0.00	0	4	0.00	0	2	0.00	0	35	0.00
	Mandible	0	17	0.00	0	12	0.00	0	4	0.00	0	2	0.00	0	35	0.00
Manubrio-clavicular	Manubrium	0	4	0.00	1	6	0.00	0	0	0.00	1	1	100.00	2	11	27.27
	Medial clavicle	1	27	0.00	1	13	0.00	0	7	0.00	0	4	0.00	2	51	3.92
Shoulder	Lateral clavicle	4	25	8.00	0	8	0.00	4	7	28.57	0	1	0.00	8	41	19.51
	Glenoid	1	29	3.45	0	13	0.00	4	6	50.00	0	1	0.00	5	49	10.20
	Proximal humerus	0	23	0.00	0	8	0.00	1	3	33.33	0	1	0.00	1	35	2.86
Elbow	Distal humerus	0	26	0.00	0	9	0.00	0	7	0.00	0	2	0.00	0	44	0.00
	Proximal radius	0	18	0.00	0	13	0.00	1	9	0.00	0	1	0.00	1	41	2.44
	Proximal ulna	0	33	0.00	0	15	0.00	1	15	0.00	0	4	0.00	1	67	1.49
Wrist	Distal radius	0	29	0.00	0	10	0.00	0	6	0.00	0	2	0.00	0	47	0.00
	Distal ulna	0	21	0.00	0	10	0.00	0	8	0.00	0	3	0.00	0	42	0.00
	Scaphoid	1	30	3.33	0	9	0.00	1	17	0.00	0	2	0.00	2	57	3.51
	Lunate	0	31	0.00	0	8	0.00	0	17	0.00	0	2	0.00	0	57	0.00
Hand		2	269	0.00	0	91	0.00	1	149	0.00	0	18	0.00	3	524	0.57
Fingers		3	676	0.44	2	308	0.65	0	371	0.00	0	45	0.00	5	1396	0.36
Hip	Acetabulum	6	25	12	0	8	0.00	2	10	0.00	0	4	0.00	8	47	17.02
	Proximal femur	10	38	7.89	6	18	0.00	8	18	5.55	0	3	0.00	24	76	31.58
Knee	Distal femur	0	25	0.00	0	11	0.00	1	13	0.00	0	2	0.00	1	51	1.96
	Patella	0	23	0.00	0	9	0.00	0	8	0.00	0	2	0.00	0	42	0.00

Joint	Bone	Male			Female			Unsexed			Indeterminate			Total		
		With OA	N	%	With OA	N	%	With OA	N	%	With OA	N	%	With OA	N	%
	Proximal tibia	1	19	0.00	0	9	0.00	0	6	0.00	0	1	0.00	1	35	2.86
	Proximal fibula	0	7	0.00	0	3	0.00	0	1	0.00	0	0	0.00	0	11	0.00
Ankle	Distal tibia	0	18	0.00	0	10	0.00	2	19	5.26	0	2	0.00	2	49	4.08
	Distal fibula	0	19	0.00	0	8	0.00	0	10	0.00	0	1	0.00	0	38	0.00
	Talus	0	24	0.00	0	8	0.00	1	24	4.16	0	2	0.00	1	58	1.72
Foot		2	189	0.00	0	53	0.00	1	168	0.59	0	27	0.00	2	437	0.46
Toes		3	230	1.30	0	50	0.00	2	163	1.23	0	17	0.00	5	460	1.09
<b>Total</b>		<b>35</b>	<b>1892</b>	<b>1.85</b>	<b>10</b>	<b>732</b>	<b>1.37</b>	<b>28</b>	<b>1072</b>	<b>2.61</b>	<b>1</b>	<b>152</b>	<b>0.66</b>	<b>74</b>	<b>3848</b>	<b>1.92</b>

**Table 33: Prevalence of osteoarthritis in the extra-spinal joints (joints affected), Phase 1**

Key: TMJ = temporo-mandibular joint; P = proximal; D = distal; M = medial; Hand = proximal metacarpals, triquetral, pisiform; hamate, trapezium, capitate, trapezoid; Fingers = distal metacarpals and phalanges; Foot = calcaneus, cuboid, navicular, medial, XXX



Joint	Bone	Male			Female			Unsexed			Indeterminate			Total		
		With OA	N	%	With OA	N	%	With OA	N	%	With OA	N	%	With OA	N	%
Jaw	TMJ	0	14	0.00	0	4	0.00	0	0	0.00	0	0	0.00	0	18	0.00
	Mandible	0	15	0.00	0	4	0.00	0	0	0.00	0	0	0.00	0	19	0.00
Manubrio-clavicular	Manubrium	0	6	0.00	0	0	0.00	0	0	0.00	0	2	0.00	0	8	0.00
	Medial clavicle	0	23	0.00	0	7	0.00	0	1	0.0	0	2	0.00	0	33	0.00
Shoulder	Lateral clavicle	0	16	0.00	0	2	0.00	1	1	100.00	0	2	0.00	1	21	4.76
	Glenoid	0	22	0.00	0	3	0.00	0	0	0.00	0	2	0.00	0	27	0.00
	Proximal humerus	0	19	0.00	0	3	0.00	0	0	0.00	0	1	0.00	0	23	0.00
Elbow	Distal humerus	0	27	0.00	0	5	0.00	0	5	0.00	0	2	0.00	0	39	0.00
	Proximal radius	0	21	0.00	0	4	0.00	0	3	0.00	0	2	0.00	0	30	0.00
	Proximal ulna	0	35	0.00	0	7	0.00	0	5	0.00	0	2	0.00	0	49	0.00
Wrist	Distal radius	3	27	11.11	0	4	0.00	0	2	0.00	0	0	0.00	3	33	9.09
	Distal ulna	2	19	10.53	0	2	0.00	1	2	50.00	0	0	0.00	3	23	13.04
	Scaphoid	0	27	0.00	0	5	0.00	0	3	0.00	0	0	0.00	0	35	0.00
	Lunate	2	22	9.09	0	4	0.00	0	3	0.00	0	0	0.00	2	29	6.89
Hand		3	216	1.39	0	47	0.00	0	43	0.00	0	0	0.00	3	306	0.98
Fingers		2	540	0.37	0	130	0.00	0	129	0.00	0	0	0.00	2	799	0.25
Hip	Acetabulum	5	24	20.83	0	5	0.00	1	2	50.00	0	0	0.00	6	31	19.35
	Proximal femur	3	35	8.57	0	8	0.00	0	5	0.00	0	0	0.00	3	48	6.25
Knee	Distal femur	1	21	4.76	0	5	0.00	0	2	0.00	0	0	0.00	1	28	3.57
	Patella	1	18	5.55	0	6	0.00	0	9	0.00	0	0	0.00	1	33	3.03
	Proximal tibia	1	17	5.88	0	2	0.00	0	3	0.00	0	0	0.00	1	22	4.55

Joint	Bone	Male			Female			Unsexed			Indeterminate			Total		
		With OA	N	%	With OA	N	%	With OA	N	%	With OA	N	%	With OA	N	%
	Proximal fibula	1	5	20.00	0	1	0.00	0	2	0.00	0	0	0.00	1	8	12.50
Ankle	Distal tibia	0	21	0.00	0	6	0.00	0	8	0.00	0	0	0.00	0	35	0.00
	Distal fibula	0	18	0.00	0	2	0.00	0	11	0.00	0	0	0.00	0	31	0.00
	Talus	1	26	3.85	0	5	0.00	0	12	0.00	0	0	0.00	1	43	2.33
Foot		1	165	0.61	0	49	0.00	2	87	2.29	0	0	0.00	3	301	0.99
Toes		1	141	0.71	0	58	0.00	0	91	0.00	0	0	0.00	1	290	0.34
<b>Total</b>		<b>27</b>	<b>1540</b>	<b>1.75</b>	<b>1</b>	<b>378</b>	<b>0.26</b>	<b>7</b>	<b>429</b>	<b>1.63</b>	<b>0</b>	<b>15</b>	<b>0.00</b>	<b>35</b>	<b>2362</b>	<b>1.48</b>

**Table 34: Prevalence of osteoarthritis in the extra-spinal joints (joints affected), Phase 2**

Key: TMJ = temporo-mandibular joint; P = proximal; D = distal; M = medial; Hand = proximal metacarpals, triquetral, pisiform; hamate, trapezium, capitate, trapezoid; Fingers = distal metacarpals and phalanges; Foot = calcaneus, cuboid, navicular, medial, lateral and intermediate cuneiforms and proximal metatarsals; Toes = distal metatarsals and phalanges.

Sex	CV			TV			LV			S			Total		
	A	P	%	A	P	%	A	P	%	A	P	%	A	P	%
M	38	106	35.85	63	184	34.24	27	75	36	5	10	50	133	375	35.47
F	10	58	17.24	25	85	29.41	9	35	25.71	1	6	16.67	45	184	24.46
U	8	35	22.86	33	73	45.21	4	24	16.67	1	7	14.29	46	139	33.09
I	2	12	16.67	0	21	0	0	10	0	0	2	0	2	45	4.44
<b>Total</b>	<b>58</b>	<b>211</b>	<b>27.49</b>	<b>121</b>	<b>363</b>	<b>33.33</b>	<b>40</b>	<b>144</b>	<b>27.78</b>	<b>7</b>	<b>25</b>	<b>29.17</b>	<b>226</b>	<b>742</b>	<b>30.46</b>

**Table 35: Prevalence of spondylolosis deformans, Phase 1**

Key: CV = cervical vertebrae; TV = thoracic vertebrae; LV = lumbar vertebrae; S = sacral; A – affected; P = present; P = present; M = male; F = female; U = unsexed; I = indeterminate.

Sex	CV			TV			LV			S			Total		
	A	P	%	A	P	%	A	P	%	A	P	%	A	P	%
M	25	90	27.78	68	180	37.78	27	76	35.83	5	14	35.71	125	360	34.72
F	6	27	22.22	7	42	16.67	0	12	0	1	4	25	14	85	16.47
U	0	1	0	7	24	29.17	8	10	80	1	3	0	16	38	42.11
I.	1	4	25	7	11	63.64	0	5	0	0	1	0	8	21	38.10
<b>Total</b>	<b>33</b>	<b>124</b>	<b>26.61</b>	<b>89</b>	<b>259</b>	<b>34.36</b>	<b>35</b>	<b>103</b>	<b>33.98</b>	<b>7</b>	<b>22</b>	<b>31.82</b>	<b>164</b>	<b>508</b>	<b>32.28</b>

**Table 36: Prevalence of spondylolosis deformans, Phase 2**

Key: CV = cervical vertebrae; TV = thoracic vertebrae; LV = lumbar vertebrae; S = sacral; A – affected; P = present; P = present; M = male; F = female; U = unsexed; I = indeterminate.

The data on joint disease of the vertebral articulations is presented in Table 37-38 below. The overall rates in both phases were very similar. A total of 58 individuals in Phase 2 had one or more vertebral facets that could be scored. Of that number 31 exhibited some joint disease of the vertebral articulations. More males than females were affected in Phase 1. The sacral facets were most commonly affected followed by the lumbar, with the thoracic and cervical being almost equally affected.

A total of 33 individuals in Phase 2 had one or more vertebral facets that could be scored. Of that number 20 exhibited some joint disease of the vertebral articulations. Females were very rarely affected in this phase. Otherwise the trends are very similar in both phases.

Sex	CV			TV			LV			S			Total		
	A	P	%	A	P	%	A	P	%	A	P	%	A	P	%
M	31	269	11.52	22	292	7.53	20	133	15.04	7	20	35	80	714	11.20
F	7	146	4.79	8	157	5.10	11	76	14.47	2	8	25.00	28	387	7.24
U	4	103	3.88	13	101	12.87	6	53	11.32	2	11	18.18	25	268	9.33
I	6	42	14.29	0	26	0	0	25	0	0	2	0	6	95	6.32
<b>Total</b>	<b>48</b>	<b>560</b>	<b>8.57</b>	<b>43</b>	<b>576</b>	<b>7.47</b>	<b>37</b>	<b>287</b>	<b>12.89</b>	<b>11</b>	<b>39</b>	<b>28.21</b>	<b>139</b>	<b>1462</b>	<b>9.51</b>

**Table 37: Prevalence of joint disease of the vertebral articulations, Phase 1**

Key: CV = cervical vertebrae; TV = thoracic vertebrae; LV = lumbar vertebrae; S = sacral; A – affected; P = present; P = present; M = male; F = female; U = unsexed; I = indeterminate.

Sex	CV			TV			LV			SV			Total		
	A	P	%	A	P	%	A	P	%	A	P	%	A	P	%
M	23	272	8.46	32	411	7.79	40	207	19.32	9	24	37.50	104	914	11.38
F	1	73	1.37	0	55	0	0	21	0	1	5	20	2	154	1.30
U	3	21	14.29	3	58	5.17	6	18	33.33	2	3	66.67	14	100	14
I	0	12	0	0	12	0	0	15	0	1	2	50	1	41	2.44
<b>Total</b>	<b>27</b>	<b>382</b>	<b>7.07</b>	<b>35</b>	<b>543</b>	<b>6.45</b>	<b>46</b>	<b>261</b>	<b>17.62</b>	<b>13</b>	<b>34</b>	<b>38.24</b>	<b>121</b>	<b>1220</b>	<b>9.92</b>

**Table 38: Prevalence of joint disease of the vertebral articulations, Phase 2**

Key: CV = cervical vertebrae; TV = thoracic vertebrae; LV = lumbar vertebrae; S = sacral; A – affected; P = present; P = present; M = male; F = female; U = unsexed; I = indeterminate.

#### 8.3.5.4 Spinal osteoarthritis

The data on spinal osteoarthritis is presented in Table 39-40. The rates were broadly similar and very low in both phases. Thoracic vertebral facets were unaffected in both phases. A total of 58 individuals in Phase 1 had one or more vertebral facets that could be scored. Of that number 4 exhibited some joint disease of the vertebral articulations. More males than females were affected.

A total of 33 individuals in Phase 2 had one or more vertebral facets that could be scored. Of that number 6 exhibited some joint disease of the vertebral articulations. Slightly more females were affected than males.

Sex	CV			TV			LV			SV			Total		
	A	P	%	A	N	%	A	P	%	A	P	%	A	P	%
M	10	269	3.72	0	292	0	3	133	2.26	0	20	0	13	714	1.82
F	1	146	0.68	0	157	0	0	76	0	0	8	0	1	387	0.26
U	0	103	0	0	101	0	3	53	5.66	0	13	0	3	270	1.11
I	0	34	0	0	24	0	0	16	0	0	1	0	0	75	0
<b>Total</b>	<b>11</b>	<b>552</b>	<b>1.99</b>	<b>0</b>	<b>574</b>	<b>0</b>	<b>6</b>	<b>278</b>	<b>2.16</b>	<b>0</b>	<b>38</b>	<b>0</b>	<b>17</b>	<b>1442</b>	<b>1.18</b>

**Table 39: Prevalence of osteoarthritis in the spine, Phase 1**

Key: CV = cervical vertebrae; TV = thoracic vertebrae; LV = lumbar vertebrae; S = sacral; A – affected; P = present; P = present; M = male; F = female; U = unsexed; I = indeterminate.

Sex	CV			TV			LV			SV			Total		
	A	P	%	A	P	%	A	P	%	A	P	%	A	P	%
M	2	272	0.74	0	411	0	0	197	0	1	24	4.17	3	904	0.33
F	1	73	1.37	0	55	0	0	21	0	0	5	0	1	154	0.65
U	3	21	14.29	0	58	0	4	28	14.29	0	3	0	7	110	6.36
I	0	12	0	0	12	0	0	15	0	0	2	0	0	41	0
<b>Total</b>	<b>6</b>	<b>378</b>	<b>1.59</b>	<b>0</b>	<b>536</b>	<b>0</b>	<b>4</b>	<b>261</b>	<b>1.53</b>	<b>1</b>	<b>34</b>	<b>2.94</b>	<b>11</b>	<b>1209</b>	<b>0.91</b>

**Table 40: Prevalence of osteoarthritis in the spine, Phase 2**

Key: CV = cervical vertebrae; TV = thoracic vertebrae; LV = lumbar vertebrae; S = sacral; A – affected; P = present; P = present; M = male; F = female; U = unsexed; I = indeterminate.

8.3.5.5 *Schmorl's nodes*

Schmorl's nodes appear as indentations in the upper and lower surfaces of the vertebral bodies caused by the pressure of herniated vertebral discs (Aufderheide and Rodriguez-Martin 1998, 97). The data is presented in Tables 41-42 below. The rates in both phases were broadly similar. More males than females were affected in both phases. The thoracic vertebrae were most commonly affected followed by the lumbar in both phases.

Sex	CV			TV			LV			S			Total		
	A	P	%	A	P	%	A	P	%	A	P	%	A	P	%
M	3	106	2.83	44	184	23.91	11	90	12.22	0	15	0	58	395	14.68
F	0	53	0	9	85	10.59	7	35	20	0	6	0	16	179	8.94
U	0	34	0	17	73	23.29	6	24	25	1	7	14.29	24	138	17.39
I	0	12	0	2	21	9.52	0	10	0	0	2	0	2	45	4.44
<b>Total</b>	<b>3</b>	<b>205</b>	<b>1.46</b>	<b>72</b>	<b>363</b>	<b>19.83</b>	<b>24</b>	<b>159</b>	<b>15.09</b>	<b>1</b>	<b>30</b>	<b>3.33</b>	<b>100</b>	<b>757</b>	<b>13.21</b>

**Table 41: Prevalence of Schmorl's nodes, Phase 1**

Key: CV = cervical vertebrae; TV = thoracic vertebrae; LV = lumbar vertebrae; S = sacral; A – affected; P = present; P = present; M = male; F = female; U = unsexed; I = indeterminate.

Sex	CV			TV			LV			S			Total		
	A	P	%	A	P	%	A	P	%	A	P	%	A	P	%
M	0	76	0	50	182	27.47	18	77	23.38	0	14	0	68	349	19.48
F	0	27	0	7	47	14.89	2	12	16.67	0	4	0.00	9	90	10
U	0	5	0	2	19	10.53	0	10	0.00	0	3	0.00	2	37	5.41
I	0	4	0	1	11	9.09	0	5	0	0	1	0	1	21	4.76
<b>Total</b>	<b>0</b>	<b>114</b>	<b>0</b>	<b>60</b>	<b>261</b>	<b>22.99</b>	<b>20</b>	<b>104</b>	<b>19.23</b>	<b>0</b>	<b>22</b>	<b>0.00</b>	<b>80</b>	<b>501</b>	<b>15.97</b>

**Table 42: Prevalence of Schmorl's nodes, Phase 2**

Key: CV = cervical vertebrae; TV = thoracic vertebrae; LV = lumbar vertebrae; S = sacral; A – affected; P = present; M = male; F = female; U = unsexed; I = indeterminate.

A total of 56 individuals in Phase 1 had one or more vertebral bodies that could be scored. Of that number, 30 exhibited Schmorl's nodes.

A total of 35 individuals in Phase 2 had one or more vertebral bodies that could be scored. Of that number 15 exhibited Schmorl's nodes.

#### 8.3.5.6 *Perthes disease*

Sk 84, a prime adult male from Phase 1, exhibited changes to the left femur head which had an expanded mushroom-like appearance although there was no shortening of the femoral neck. There was marked flattening of the femur shaft in the anterior-posterior plane. The right femur was normal. A diagnosis of Perthes disease is a possibility. The condition involves disruption of the blood supply to the femoral head epiphysis, often as a result of trauma. It occurs mainly in young boys between the ages of five and ten years and is often bilateral, though not exclusively so (Lee and Boylston 2008, 257). A child suffering from this condition would have walked with a characteristic limp. In this case both the left acetabulum and the left femur displayed moderate joint disease in the form of osteophtyes and porosity.

#### 8.3.5.7 *Diffuse Idiopathic Skeletal Hyperostosis (DISH)*

DISH is characterised by bony proliferation due to ossification of ligaments on the anterior aspect of the vertebral bodies, leading to eventual ankylosis. Extra bone is also produced at the sites of tendon and ligament insertion in both spinal and extraspinal locations. It is rarely found in individuals under the age of 50 years and there is a bias in favour of males – in the region of 70% (Resnick and Niwayama 1988). The facet joints of the vertebrae are unaffected and the spine never becomes completely rigid (Forestier and Lagier 1971). DISH is only identified conclusively on the Skeleton when four or more consecutive vertebrae are fused (Rogers and Waldron 1995)

Sk 127 (Phase 1), an adult male, exhibited characteristic changes which affected the fourth through to the twelfth thoracic vertebrae. There were large flowing osteophtyes running down the right side of the affected vertebrae, while the intervertebral joint spaces were maintained. There were no surviving apophyseal joints. The first to fifth lumbar vertebrae had severe osteophtyes resulting in fusion of the bodies on both the right and left side, although at this location the joint spaces were not maintained. The changes to the lumbar vertebrae are seen in other types of spondyloarthropathy such as ankylosing spondylitis

(Rogers and Waldron 1995). An X-ray would be desirable. There was also marked enthesal change affecting the femora, the tibiae, the fibulae, the left patella, the iliac crest, the left and right acetabulum. The sacro-iliac joints and ischial tuberosities did not survive.

Sk 144 (Phase 2), an adult male, exhibited fusion of the bodies of the fifth through to the ninth thoracic vertebrae on the anterior right side. The disc spaces were preserved. There was no fusion of the apophyseal joints of the fifth through to the seventh thoracic vertebrae, however, the inferior facets of the eighth thoracic vertebra were fused to the superior facets of the ninth thoracic vertebra. Bony proliferation continued on the anterior right side down to the level of the eleventh thoracic vertebrae. This Skeleton was diagnosed with probable lepromatous leprosy as changes to the feet included septic arthritis and claw toe deformity.

The CPR quoted for DISH in the medieval period (Roberts and Cox 2002, 246, tab. 5.9) is 3.3%. The CPR at St Leonard's is 1.27% for Phase 1 and 2.27% for Phase 2.

At Chichester, three Skeletons were diagnosed with the condition while a further eight were thought to be suffering from early DISH (Boylston 2008, 250). All were male and in the mature age range. The majority of vertebrae affected were the middle to the lower thoracic.

### 8.3.6 *Miscellaneous*

#### 8.3.6.1 *Ectocranial and endocranial lesions - Phase 1*

Sk 9, a prime adult female, exhibited an area of increased porosity and irregular new bone deposition immediately proximal to the nuchal crest on the ectocranial surface. This Skeleton also exhibited pathological changes which are possible indicators of leprosy.

Sk 18, a prime adult male, exhibited endocranial lesions on the occipital bone. There was increased porosity and vascularity, associated with a deposit of woven bone which extended over the occipital sulcus to the cruciform eminence and over the right transverse sulcus, but not the left (see Plate 37 below). This Skeleton was diagnosed with lepromatous leprosy.



**Plate 37: Skeleton 18, lesions on endocranial surface of occipital**

Sk 23, a mature adult female, exhibited abnormal porosity of the ectocranial surface of the frontals and parietals. This Skeleton was diagnosed with lepromatous leprosy.

Sk 26, an unsexed adult aged upwards of 18 years, exhibited slightly abnormal porosity on the ectocranial surface of the posterior portion of the left and right parietals.

Sk 42, a mature adult female aged 36-45 years, exhibited abnormal porosity and irregular new bone deposition on the left and right supra-orbital ridges immediately above the orbits. The changes extended across the glabella. Similar changes were seen on the anterior surface of the left and right zygomatic bones. This Skeleton was diagnosed with probable lepromatous leprosy.

Sk 68, a prime adult male, exhibited abnormal porosity on the ectocranial surfaces of the occipital and the parietals, and the anterior surface of the left zygomatic bone with a focus around the foramen. This Skeleton was diagnosed with probable lepromatous leprosy.

Sk 70, an adult male aged upwards of 18 years, exhibited abnormal porosity and woven bone deposition on the endocranial surface of the left temporal, confined to squamous portion, immediately posterior to the petrous pyramid.

#### 8.3.6.2 *Ectocranial and endocranial lesions - Phase 2*

Sk 93, a young adult male, exhibited abnormal porosity and woven bone deposition on the ectocranial surface of the occipital, overlying the nuchal crest.

Sk 96, a young adult male, exhibited abnormal porosity on the anterior surface of the right zygomatic.

Sk 97, an adult male aged upwards of 18 years, exhibited abnormal porosity on the ectocranial surfaces of the parietals, the frontal bone and the right zygomatics. Woven bone deposits were present on the glabella and above the right supra-orbital ridge. The right was damaged. This Skeleton was diagnosed with lepromatous leprosy.

Sk 140, a young adult male, exhibited abnormal porosity and woven bone deposition on the body of the sphenoid, the lateral surface of the left mandible, below the condyle and the right mandible, on the medial surface. Inflammation in these areas is seen in cases of scurvy (Ortner and Erikson 1997).

## 8.4 **Dental Health**

A total of 48 adults from Phase 1 and 27 from Phase 2 had teeth and/or jaws surviving. The prevalence rates have been sub-divided by phase and then by sex but not by age category as the numbers were too small to provide a meaningful sample.

Two non-adult Skeletons had surviving dentition: an adolescent from Phase 1 (60) and a younger juvenile from Phase 2 (132). All teeth were examined macroscopically for evidence of pathological changes. Dental pathology observed in the non-adult dentition was limited to calculus. The prevalence rates for non-adults appear in Table 43 below.



	Calculus	Caries	Abscess	DEH	AMTL
Phase 1	1/23	0/23	0/21	0/23	0/28
Phase 2	4/17	0/17	0/6	0/17	0/17
Total	5/40	0/40	0/27	0/40	0/45

**Table 43: Dental health in the non-adults**

#### 8.4.1 *Calculus*

Plaque which is not removed effectively from the teeth can mineralise and form calculus on the tooth crowns or roots where they are exposed. Calculus is a common feature of archaeological populations of all periods although poor preservation and cleaning after excavation can have an impact on its survival.

The prevalence of dental calculus by phase is presented in Table 44 below. Slightly more females than males had calculus in both phases although this may not be significant given the proportion of unsexed adults in both phases. The total number of teeth with calculus in both phases was broadly similar at 59.25% for Phase 1 and 61.37% for Phase 2.

The CPR quoted for the medieval period is 53.99% with a range of 37.96% to 71.18% (Roberts and Cox 2002, 261-2, tab. 5.18). For this period the high calculus rate is more likely to reflect a lack of effective oral hygiene than diets high in protein (ibid.).

#### 8.4.2 *Dental caries*

Dental caries are cavities that result from the demineralisation of teeth when they are attacked by acids that develop when bacteria ferment food sugars, especially sucrose.

The prevalence of dental caries is presented by phase in Table 45 below. The rate was higher for females in both phases. A slight decrease in the occurrence of caries was seen in Phase 2.

Roberts and Cox quote an overall prevalence rate per individual of 53% suggesting that almost half of individuals in the samples examined had one or more carious teeth. The rate of caries per tooth position examined is 5.6%, an increase from the early medieval rate of 4.2% but they caution that both sets of statistics hide an enormous range of variation (2002, 258-259, tab. 5.15). This compares well with the rate in both phases at St Leonard's.

#### 8.4.3 *Dental abscesses*

Dental abscesses occur when bacteria enter the pulp cavity of a tooth causing inflammation and a build-up of pus at the apex of the root. This culminates in the formation of a hole in the surrounding bone which allows the pus to drain out and relieve the pressure. Causes include dental caries, extreme wear, periodontal disease and trauma.

The prevalence of dental abscesses is presented by phase in Table 46 below. The rate was slightly higher for females than males in both phases. The total number of teeth affected in both phases was almost identical.

The mean rate per individual quoted by Roberts and Cox (2002, 259-260, tab. 5.16) is 26% and that per tooth is 3%.

	Male teeth			Female teeth			Unsexed teeth			Indet.			Total teeth		
	Calculus	Total	%	Calculus	Total	%	Calculus	Total	%	Calculus	Total	%	Calculus	Total	%
Phase 1	188	310	60.65	146	223	65.47	33	54	61.11	29	60	48.33	397	670	59.25
Phase 2	156	271	57.56	49	71	69.01	3	6	50.00	16	17	94.12	224	365	61.37
Total	344	581	59.21	195	294	66.33	36	60	60.00	45	77	58.44	621	1035	60.00

**Table 44: Dental calculus (teeth affected)**

	Male teeth			Female teeth			Unsexed teeth			Indet.			Total teeth		
	Caries	Total	%	Caries	Total	%	Caries	Total	%	Caries	Total	%	Caries	Total	%
Phase 1	36	310	11.61	31	223	13.90	3	54	5.55	9	60	15.00	79	670	11.79
Phase 2	23	271	8.49	8	71	11.27	0	6	0.00	3	17	17.65	34	365	9.32
Total	59	581	10.15	39	294	13.27	3	60	5.00	12	77	15.58	113	1035	10.92

**Table 45: Dental caries (permanent teeth)**

	Male teeth			Female teeth			Unsexed teeth			Indet.			Total teeth		
Phase	Abscess	Total	%	Abscess	Total	%	Abscess	Total	%	Abscess	Total	%	Abscess	Total	%
Phase 1	7	282	2.48	5	152	3.29	1	26	3.85	0	41	0.00	13	522	2.29
Phase 2	5	224	2.23	2	71	2.82	0	8	0	0	12	0.00	7	281	2.49
Total	12	506	2.37	7	223	3.14	1	34	2.94	0	53	0.00	20	803	2.49

**Table 46: Dental abscess (tooth positions)**

	Male teeth			Female teeth			Unsexed teeth			Indet.			Total teeth		
	AMTL	Total	%	AMTL	Total	%	AMTL	Total	%	AMTL	Total	%	AMTL	Total	%
Phase 1	64	404	15.84	12	247	4.86	7	63	11.11	1	63	1.59	84	805	10.44
Phase 2	30	317	9.46	7	78	8.97	1	11	9.09	1	18	5.55	39	424	9.19
Total	94	717	13.11	19	325	5.85	8	74	10.81	2	81	2.47	123	1229	10.01

**Table 47: Teeth lost ante-mortem (tooth positions affected)**

	Male teeth			Female teeth			Unsexed teeth			Indet.			Total teeth		
	DEH	Total	%	DEH	Total	%	DEH	Total	%	DEH	Total	%	DEH	Total	%
Phase 1	1	310	0.32	13	223	5.83	0	54	0.00	0	60	0.00	14	670	2.09
Phase 2	30	271	11.07	8	71	11.27	0	6	0.00	0	17	0.00	38	365	8.77
Total	31	581	5.34	21	294	7.14	0	60	0.00	0	77	0.00	52	1035	5.02

**Table 48: Teeth with dental enamel hypoplasia**

	Male teeth			Female teeth			Unsexed teeth			Indet.			Total teeth		
	Enamel chipping	Total	%	Enamel chipping	Total	%	Enamel chipping	Total	%	Enamel chipping	Total	%	Enamel chipping	Total	%
Phase 1	12	310	3.87	18	223	8.07	2	54	3.70%	1	60	1.67	33	647	5.10
Phase 2	5	255	1.96	4	71	5.63	0	6	0	0	17	0	9	349	2.58
	17	565	3.00	22	294	7.48	2	60	3.33	1	77	1.29	42	996	4.22

**Table 49: Enamel chipping**

#### 8.4.4 *Ante-mortem tooth loss*

Causes of AMTL include dental caries, pulp exposure due to heavy wear or periodontal disease. The data is presented by phase in Table 47 above. Many more males than females were affected in Phase 1, whereas in Phase 2 the rates were very similar. The total overall rates were very similar: 10.44% in Phase 1 and 9.19% in Phase 2.

#### 8.4.5 *Dental enamel hypoplasia*

Dental enamel hypoplasia (DEH) is the presence of lines, grooves or pits on the surface of the tooth crown. They occur when crown formation is interrupted during periods of illness or malnutrition. The data is presented by phase in Table 48 above. Many more females than males were affected in Phase 1 while in Phase 2 the rates were almost identical. There is a marked increase between phases: 2.09% in Phase 1 and 8.77 in Phase 2.

#### 8.4.6 *Dental trauma*

##### 8.4.6.1 *Enamel chips*

The incidence of enamel chips was recorded for all dentition and the data appears in Table 49. The rate was higher in Phase 1 than in Phase 2. Females were more commonly affected than males in both phases.

#### 8.4.7 *Periodontal disease*

It was possible to observe the incidence of periodontal disease for 29 adults in Phase 1 and 16 in Phase 2. A total of 27 adults in Phase 1 and 16 adults in Phase 2 exhibited some degree of periodontal disease.

#### 8.4.8 *Dental anomalies*

##### 8.4.8.1 *Crowding and rotation*

Sk 69 (Phase 1), a mature adult female, exhibited crowding and rotation of the mandibular incisors. Sk 91 (Phase 1), a prime adult male, exhibited slight rotation of the left mandibular canine.

Sk 89 (Phase 2), a prime adult male, exhibited crowding of the right mandibular incisors and rotation of the right mandibular canine. Sk 93 (Phase 2), a young adult male, exhibited crowding of the mandibular incisors and rotation of the left mandibular canine.

##### 8.4.8.2 *Retention of deciduous teeth*

Sk 90 (Phase 2), a prime adult male, had retained part of a deciduous root which was located between the left maxillary first and second premolars.

#### 8.4.9 *Unusual wear patterns*

Sk 5 (Phase 1), an older adult of uncertain sex, exhibited marked wear sloping downwards from buccal to lingual on a single surviving maxillary third molar. Sk 70 (Phase 1), an adult aged upwards of 18 years, exhibited unusual sloping wear from mesial to lingual on the maxillary left first premolar. Most of the crown is destroyed. Sk 143 (Phase 1), an older adult of uncertain sex exhibited advanced wear sloping down from buccal to lingual. Sk 78 (Phase 2), an older adult male, exhibited extreme maxillary molar wear sloping down from buccal to lingual.

## 9 DISCUSSION AND CONCLUSION

by J.M. McComish and G. Millward

### 9.1 The layout of the burial ground in Phases 1 and 2

The burial ground at Midland Road, Peterborough, clearly had two separate phases of use. The first, Phase 1, was of 11<sup>th</sup>-13<sup>th</sup> century date and clearly related to the medieval leper hospital of St Leonard, as eleven of the burials were definitely leprous with a further nineteen exhibiting signs that may have been leprous.

There was no artefactual evidence from the site dating from the later 12<sup>th</sup> to late 14<sup>th</sup> century date, despite the fact that it is known from documentary sources that the hospital was in use at this stage (section 4 above). The C<sup>14</sup> dates for the site do however clearly show that burials took place throughout the late 12<sup>th</sup>-14<sup>th</sup> centuries (Phase 2) and that this second phase of use continued into the 15-16<sup>th</sup> centuries, by which time the documentary evidence indicates that the hospital was for the poor rather than lepers. It is interesting, then, that leprous burials were still taking place during the later phase, albeit at a reduced ratio within the population. Only three of the Phase 2 burials were definitely leprous with a further nine exhibiting signs that may have been leprous.

As the hospital buildings lay beyond the limits of excavation it is impossible to know whether other areas, such as the hospital chapel, contained higher status burials. It is also impossible to determine whether other plots of land were used for burials at differing times. This was certainly the case at other leper hospitals. At St Mary Magdalen's Hospital, Winchester, the original cemetery was decommissioned in the mid-late 12<sup>th</sup> century, and a new cemetery was initiated in a different area of the site (Roffey and Marter 2012). The (non-leper) hospital of St Mary's Spitalfields, London, also had three separate areas of burials one relating to the first priory up to 1235, one for the period 1235-80 and one for 1280-1320 (Magilton et al. 2008, 37). A similar arrangement at Midland Road might explain the absence of existence of 13-14<sup>th</sup> century artefacts at the site.

There was no trace of mortuary structures at Midland Road, such as those seen at the hospital of St James and Mary Magdalen, Chichester (*ibid.*, 65-6) being present.

#### 9.1.1 Cemetery boundaries

Medieval cemeteries were often surrounded by ditches, such as those seen at Dixon Lane, York (McComish 2007, 56), or at Chichester (Magilton et al. 2008, 77-81). The only possible evidence for a possible boundary ditch at Midland Road was cut 306, in Trench 3, but this was somewhat to the east of the burials, and may be unrelated.

#### 9.1.2 Burial rows

In many medieval cemeteries, particularly parish churches that were in use for prolonged periods of time, the degree of intercutting is such that it is difficult to determine how the cemetery was laid out. For shorter lived or smaller cemeteries it is sometimes possible to determine clear rows of burials. At St Mary Magdalen's Hospital, Colchester, three of the five burials associated with the first phase of the leper house were in a north-south aligned row (Crossan 2004, Figure 7, 111), while at Chichester the north-eastern and south-

westernmost portions of the cemetery were in organised rows, with the central portion of the site having a less clear pattern (Magilton et al. 2008, Figure 7.8).

It is clear that in Phase 1 at Midland Road the cemetery was carefully laid out in a series of rows, with relatively little evidence of intercutting. The rows were laid out in such a way that there was relatively little wasted space within the cemetery. The Phase 2 burials were also clearly in rows, but these were placed in a less organised pattern than those of Phase 1.

### 9.1.3 *Orientation*

In most medieval cemeteries burials were laid east-west with the head at the western end of the grave. This was, according to the 13<sup>th</sup> century liturgist Durandus, Bishop of Mende, so that the dead were pointing in the right direction to stand up and face Christ on the day of Judgement (BinSki 1996, 56). Medieval leper cemeteries with east-west aligned graves are known. For example, at St Margaret, High Wycombe, Buckinghamshire, the twelve graves uncovered were in east-west aligned graves (Farley and Manchester 1989, 82). It should be noted that within any given medieval cemetery are usually subtle variations in alignments, with not all the burials being truly east-west. An example of such variation is known from the leper hospital of Mary Magdalene's Bidlington, East Sussex, the bodies were all buried with heads to west but some at western end of the site approached a SW-NE alignment (Magilton et al. 2008, 36 and 40). It has also been noted that groups of contemporaneous burials conform to a common alignment (ibid., 115).

There are however, examples where burials were placed in other orientations, often in relation to nearby boundaries, or buildings, particularly churches. The burials in the parish cemetery of St Benet's Swinegate, York, ranged from NNE-SSW, to NE-SW, to ENE-WSW, (McComish 2015, 20) with some burials being aligned to upstanding portions of Roman masonry. At the parish cemetery of St Stephen's church, York the boundary ditch of the cemetery exerted a strong influence on the layout of the graves at the site, with the exception of the most recent graves which were on a noticeably different alignment and may have been interred after the ditch had gone out of use (McComish 2007, 61).

The orientations seen at Midland Row conform to the general pattern from medieval cemeteries. The Skeletons were for the most part east-west with the head at the western end of the grave, but there were subtle variations in alignment (see Figure 7). The range of orientations seen was slightly greater in Phase 2 than in Phase 1. It is clear that in Phase 2 at least, some of the burials were laid in pairs with shared alignments, such as those in Rows 14, 15 and 17, and possibly also Sk 132 and Sk 137.

### 9.1.4 *The placement of lepers and non lepers within the cemetery*

It is not always easy to determine the presence of leprosy in the archaeological record (Magilton et al. 2008, 208). Many Skeletons may not show any changes of leprosy even if the person had been suffering from the infection, making identification of the disease problematic (Roberts 2011, 265).

It is clear that seemingly healthy individuals were buried within the cemeteries of leper hospitals and this may have resulted from a variety of circumstances. It is known that from documentary sources that people could use the cemetery of a leper hospital in lieu of a parish church if none was available, as was the case with St Leonard's, Northampton

(Rawcliffe 2006, 262). It could also be that the priest who ministered to the lepers, together with any nurses or servants of the hospital might choose to be buried there (*ibid.*, 262). The seemingly healthy Skeletons may also represent people who were mis-diagnosed with the condition, and suffered from some other disease which left no Skeletal trace. It is also possible that people might choose to be buried alongside relatives. The loss of income from burials to leper hospitals was clearly of concern to churches. For example, in 1153 the clergy of Tournai secured a ruling that only the *conversi* of hospital who acted as nurses and servants could be buried in the cemetery (*ibid.*, 262).

The ratio of lepers to non-lepers within the cemeteries of leper hospitals varies. For example, at St Margaret's, High Wycombe, Buckinghamshire, three of the twelve burials uncovered did not show signs of leprosy (Farley and Manchester 1989, 84), at St Bartholomew's, South Acre, Norfolk, five of the twelve burials showed no signs of leprosy (Wells 1976, 242-6), while only two of the five burials associated with the first phase of buildings at St Mary Magdalen's Hospital, Colchester, showed possible signs of leprosy (Crossan 2004, 117). At St Mary and St Thomas the Martyr, Ilford, Essex, only two of the nine Skeletons examined showed signs of leprosy (Gilchrist and Sloan 2005). At St Mary Magdalen's Hospital, Winchester, seven of the 43 burials excavated showed no sign of leprosy (Roffey and Marter 2012). Six of the seven burials examined from Mary Magdalene's Bidlington, East Sussex, were leprosy (Magilton et al. 2008, 36). St Nicholas Lewes contained only two lepers among the 102 burials excavated, but the early cemetery could have been elsewhere (*ibid.*, 37). Only one of the burials at St Leonard's, Newark, showed signs of leprosy (*ibid.*, 39). At St James and St Mary Magdalene, Chichester, out of 374 burials 75 have leprosy, 14 have lesions suggesting they probably had the disease, and 37 have non-specific infections that might have developed into obvious leprosy change (*ibid.*, 209).

At Midland Road, out of 131 burials 14 have leprosy, 18 have lesions suggesting that they probably have the disease, and 10 have non-specific infections that might have developed into obvious leprosy change. In total 36.14% of the Phase 1 burials were exhibited some signs of leprosy and 25.53% of the Phase 2 burials exhibited some signs of leprosy.

The ratio of burials exhibiting signs of leprosy in at Midland Road is directly comparable to the ratio of burials exhibiting signs of leprosy change at St James and St Mary Magdalene, Chichester (*ibid.*, 209). Most of the other cemeteries described above had higher rates of leprosy within their much smaller sample sizes. Only St Mary Magdalene, Winchester and St Nicholas Lewes had large enough burial populations for meaningful comparison. St Mary Magdalene, Winchester had a much higher ratio of burials (83.72%) exhibiting signs of leprosy change (Roffey and Marter 2012) perhaps indicating that the leper hospital there was much more specialised and exclusive than the one at Midland Road. In contrast only two of the hundred and two (1.96%) burials at St. Nicholas Lewes exhibited signs of leprosy change (Magilton et al. 2008, 37). The main problem with comparing these burial populations is that few of the cemeteries described above have been fully excavated and very few of the Skeletal assemblages have been fully analysed.

The organisation of the investigated part of the cemetery at Midland Road suggests that there was no spatial patterning with regard to pathology. St Nicholas Lewes had no spatial

patterning with regard to pathology (Magilton et al. 2008, 37), this was also true of St James and St Mary Magdalene, Chichester (ibid., 113).

Too few leper cemeteries have been investigated to determine if there was segregation between staff and inmates (Magilton et al. 2008, 27).

#### 9.1.5 *The placement of males, females and children within the cemetery*

The sex of the burials at any given leper hospital would to a large extent be determined by who was admitted, as some leper hospitals were for a single sex. St James the Less in London, apparently catered for leprous women (Roffey 2102, 218), while St Mary Magdalen's Hospital, Colchester, was initially for men (Crossan 2004, 117). In the latter case the cemetery seemed to confirm this with four males and one Skeleton of indeterminate sex being present in the earliest phase of the cemetery (ibid., 117). Even within such institutions there may have been a mixture of the sexes, a male priest would be needed to minister to female lepers, and the servants of any given hospital could also have been of both sexes.

Where a hospital was in use for both sexes there is no evidence for separation of males and females within cemeteries. Interspersed males and females were present at St Margaret, High Wycombe, Buckinghamshire, (Farley and Manchester 1989, 84), at St Nicholas, Lewes (Magilton et al. 2008, 37), or in the later stages of St James and St Mary Magdalene, Chichester, once women had been admitted to the hospital (ibid., 112).

There was no discernible separation of males and females within the cemetery at Midland Road in either of the phases of burial. There were, however, many more males buried within this cemetery than females with an increase in the ratio of males to females during the later phase of burial. This seems to indicate that although the hospital at Midland Road was never exclusively occupied by males, females were always in the minority. This pattern appears to mirror the evidence from St James and St Mary Magdalene, Chichester, which demonstrated an increase in the ratio of female burials (up to normal population levels) during the later phases of the cemetery use (ibid., 145).

Children are occasionally found in medieval leper hospital cemeteries, such as a child's Skull in an early context at St Mary Magdalen's Hospital, Brook Street, Colchester (Crossan 2004, 114). Whether this represents the burial of parishioners in the cemetery is unclear.

Only one child and six adolescents were identified within the burials at Midland Road. Three of the adolescents were buried in close proximity to each other in the centre of the cemetery. There was no separation, however, of the adolescents and child from the general adult population. All of them exhibited signs of pathology which may indicate that they were residents of the hospital prior to their deaths rather than being occasional burials of local parishioners.

## 9.2 **Burial practices in Phase 1 and 2**

The burials at Midland Road, Peterborough, were clearly buried in the same way as, and with the same respect and care as the non-lepers buried in cemetery, and indeed with burials in typical medieval parish cemeteries.



### 9.2.1 *Grave size, shape and depth*

In the majority of cases there is discernible difference in terms of the size, shape and depth of the grave cuts in the Phase 1 and Phase 2 burials at Midland Road. In general the graves were narrow, shallow and sub-rectangular, with only three examples present, Sk 16 (Phase 1) and Sk 54 and Sk 36 (Phase 2) where the cut was larger than required. A similar correlation between grave size and burial size was seen at the leper hospital of St James and St Mary Magdalene, Chichester (Magilton et al. 2008, 114).

There were no anthropomorphic graves cuts (those with an inbuilt head niche) at Midland Road, such as the examples seen at St Mary Magdalen, Winchester (Roffey 2012, 221).

Magilton et al. (2008, 420) noted that graves were dug in the presence of the funeral cortege, and that consequently graves would tend towards being shallow. At St Mary Magdalen's Hospital Bidlington, East Sussex, the graves were on average 0.75m deep though two graves were 0.6m deeper (Magilton et al. 2008, 36), while at South Acre, Norfolk, the graves were 0.9-1.2m deep (*ibid.*, 38). The graves at Midland Road, Peterborough were notably shallower, ranging from just 0.03m to 0.3m in depth. The shallowness of the graves at this site clearly results from severe modern truncation, which had removed the upper portions of all of the graves.

### 9.2.2 *Multiple occupancy graves*

Multiple occupancy graves, though rare, are known at other leper hospitals. At Mary Magdalene's Bidlington, East Sussex, a young adult male and young adult female were buried together, while at St Leonard's Newark there was a single example of one grave on top of another (Magilton et al. 2008, 36 and 39).

At the Midland Road site there were two multiple occupancy graves, both of which were in Phase 2. It is possible that the presence of such graves represents a chronological change in burial practice. Clearly the people interred must have died at the same time, which may suggest that the people died as the result of local epidemics, and that it was simply more economical to excavate one large grave rather than individual graves.

### 9.2.3 *The use of grave markers*

Magilton et al. (2008, 28) noted that outside burials rarely seem to have had markers and churchyard gravestones were not common prior to the 18<sup>th</sup> century. While there was no conclusive evidence for grave markers at the Midland Road site, the rarity of intercutting in Phase 1 suggests that the burials in this phase must have been marked in some way. A similar pattern was seen in northern cemetery of Mary Magdalen, Winchester, where few of the burials in the northern cemetery at the site intercut, suggesting that each grave had been marked (Roffey 2012, 221-2). The most obvious suggestion is that the graves were marked by low mounds.

### 9.2.4 *Burial positions*

Burial positions on medieval cemeteries are usually supine and extended, but at many sites there are often variations in terms of arm positions, and the presence of occasional burials with flexed legs. For example, the (non-leper) cemetery of St Andrew's Priory, York, had nine burial positions (Stroud and Kemp 1993, 145), while at the leper hospital of St James and St

Mary Magdalene, Chichester, most burials had the arms on the body, but 16% had the arms fully extended at the side (Magilton et al. 2008, 117 and 130).

The burials at Midland Road were all supine and extended though a small number had flexed legs. The presence of small numbers of burials with flexed legs has been noted elsewhere. For example, one of the twelve burials at St Margaret's, High Wycombe, Buckinghamshire, was flexed at the knees and lay on its left side (Farley and Manchester 1989, 82).

In terms of arm positions, it was clearly the norm at Midland Road during both Phase 1 and 2 for both arms to be fully extended at the sides, and most of the other burial positions seen represented minor variations of this position. Only three burials had arm positions which were significantly different (p26 above), two of which were in Phase 1 (Sk 43 and Sk 60), and one in Phase 2 (Sk 101). There is no evidence that burial position related to the sex or age of the person, and it was clearly not linked to the location of the burials within the cemetery. In this regard the cemetery is similar to that of St James and St Mary Magdalene Chichester, where there was no convincing evidence that burial position at was linked to sex, age or location within the cemetery (Magilton et al. 2008, 57).

#### 9.2.5 *The use of coffins*

It might be argued that the use of a coffin could have been greater in the case of a hospital in an attempt to contain disease. During the Black Death some continental cities insisted on burial in a coffin to prevent the escape of miasmas (Magilton et al. 2008, 31). Despite this there was clearly some variation in the medieval period as to whether bodies were interred with or without coffins, with examples of both types of burial being known in leper cemeteries. At St Mary Magdalen's Hospital, Colchester, the five burials associated with the earliest stages of the leper hospital were not in coffins (Crossan 2004, 111). In contrast, seven of the later burials at St Mary Magdalen's Hospital, Colchester, dating from the mid-13<sup>th</sup> century to 1610 were in rectangular grave cuts with evidence for coffins in the form of nails and soil stains left by decomposed timbers (ibid., 114), though these burials were located within the church or church porch and may therefore represent higher status individuals.

It is often only iron coffin nails that survive to indicate the position and layout of a coffin. Particularly good examples of this were seen at the medieval Jewish cemetery of Jewbury in York, for example Sk 2425 where nails were visible at the base, in the corners and from the lid of the coffin (Lilley et al. 1994, Figure 106a). At St James and St Mary Magdalene leper hospital, Chichester, there were 64 cases where there were sufficient nails to suggest the pattern of the coffin, and these patterns were used to suggest that there were both rectangular shaped and anthropomorphic coffins (Magilton et al. 2008, 121).

It should be noted, however, that a lack of nails does not necessarily mean coffins were absent, as coffins could be held together with wooden pegs rather than iron nails, such as those seen at St Benet's Swinegate, York (McComish 2015, 44-5) or at Barton-on Humber (Rodwell and Rodwell 1982: 301; Panter 1994, 26-31).

In the case of Midland Road, Peterborough, there was no convincing evidence of nailed coffins, but the burial positions of 23 of the Skeletons may suggest a coffin was present (7.5.6 above). Against this a comparison of burial positions to the presence of nails at St

James and St Mary Magdalene, Chichester, showed that the position of the Skeleton was of no help in determining whether the Skeleton was likely to have been in a coffin or not (Magilton et al. 2008, 118-9)

It should be noted that a burial in a coffin could not be squeezed into a grave that is too small, unlike a shrouded burial.

#### 9.2.6 *Dressing the dead for burial*

Due to the poor survival of organic remains on most archaeological sites it is often unclear how the dead were dressed for burial. Some information can be gleaned from illustrations, and depictions on tombs. The Bayeux Tapestry shows the funeral of Edward the Confessor with the king's body tightly bound in a winding sheet that shows the contours of the body (Magilton et al. 2008, 30). The mid-15<sup>th</sup> century Connolly Book of Hours shows a tightly bound body wrapped in such a way that the outline of the head is clearly visible (John Burns Library). Tightly binding a body in this way would have made handling the body during burial easier, especially if no coffin was intended.

A different type of shroud, is also known from memorial brasses of 15-16<sup>th</sup> century date, such as at Aylsham church in Norfolk, which depict a Skeleton within a bag like shroud, while a tomb dating to 1473 at Fenny Bentley in Derbyshire, shows two adults in bag like shrouds which are knotted above the head and feet and tied around the lower legs (McComish 2015 28-9). These were presumably sewn shut lengthways.

None of the burials at Midland Road, Peterborough, had any organic remains present indicative of shrouds, but the burial position of a few burials might indicate the type of shroud used. The leg position of Sk 54 suggested that the Skeleton had been bound at the knees, perhaps indicating a winding sheet. In contrast the arm positions of Sk 32, Sk 43, Sk 67 and Sk 137 may suggest a looser bag-like shroud.

Binding cords are suggested by the presence of lace tags in seven of the graves at Midland Road. Similar objects are known at other cemeteries, such as St James and St Mary Magdalene, Chichester (Magilton et al. 2008, 57) or at Whithorn, Scotland c. 1350-1450 (Nicholson and Hill 1997, 35). The lace tags from Midland Road were for leather, indicating that narrow leather cords were used. It is impossible to know, however, whether such cords were used to tie a winding sheet or shroud in place.

There were no examples of shroud pins at Midland Road. Finds of this type are known from other cemeteries such as the parish church cemeteries such as St Helen-on-the-walls, York (Dawes and Magilton 1980, 14).

Part of a buckle was present in a single burial at Midland Road (Sk 132) which may indicated that a strap was used to tie the shroud/winding sheet in place. It could equally represent clothing. Parallels are known at other sites such as St James and St Mary Magdalene, Chichester where six buckles were found three in graves (Magilton et al. 2008, 129) or the non-leper cemetery of St Mary Horsefair, York, where a single example was found (Magilton et al. 2008, 39).

It has been suggested that narrow graves are an indicator of shrouded rather than coffined burials (Hadley 2001, 65). Against this, many of the wooden coffins seen at the Swinegate

excavations in York, were exceptionally narrow, suggesting that narrowness of the grave cannot in itself be taken as an indicator of a shrouded as opposed to a confined burial.

#### 9.2.7 *Stones within the graves*

The deliberate placing of stones within a grave is known across Britain during the Anglo-Saxon period and continuing up to at least the 12<sup>th</sup> century. Such stones are often placed to either side of the Skull, or beneath the head, being referred to as 'ear-muffs' and 'pillow stones' respectively. Examples are known from leper hospitals in England, such as at Mary Magdalene's Bidlington, East Sussex, where five burials had stones around or below Skull (Magilton et al. 2008, 36), or St Nicholas', Lewes, where seven burials had ear muffs which the excavators dated to the 12/13<sup>th</sup> (ibid., 37). A different placing of stones was seen at St Leonard's Newark, where one burial had thin stones over the chest (ibid., 39).

There was no evidence at Midland Road for any deliberately placed stones within the graves.

#### 9.2.8 *Indicators of high status burial*

It is known that even among lepers there was a social hierarchy; at Salle-aux-Puelles, Rouen, Normandy the lepers eating in the hall passed their scraps on to lepers waiting outside (Roffey 2012, 218).

There are occasionally burials in leper cemeteries which are suggestive of higher status individuals. For example, at St James and St Mary Magdalene, Chichester, one non-leprous male was buried in a stone lined tomb (Magilton et al. 2008, 86-8), while at St Mary Magdalen, Winchester, one burials was presumably of a pilgrim as it contained a scallop shell (Roffey 2012, 206). At St Leonard's Newark there was a burial of a priest with pewter chalice and paten which was placed in a stone lined grave (Magilton et al. 2008, 39), and at Hady Hill, Chesterfield a priest with a chalice and paten was buried close to a wall which was interpreted as being part of the chapel of the leper hospital (Witkin 2000).

None of the graves at Midland Road showed any obvious signs of being high status. It should be noted, however, that none of the hospital buildings, including the chapel, were excavated at the site, and it is perfectly possible that higher status burials could have been located elsewhere.

#### 9.2.8 *Disturbed bones and charnel*

Many of the graves at the Midland Road site contained the bones of earlier burials, usually laid to one side of the grave cut. There were no examples of specific charnel pits for multiple individuals such as that seen at St James and St Mary Magdalene, Chichester, where there was a purpose excavated charnel pit housing the remains of eight individuals (Magilton et al. 2008, 89)

### 9.3 **The population at Midland Road**

by A. Boyle

#### 9.3.1 *The condition of the assemblage*

Overall, the Skeletons were incomplete and severely fragmented but with reasonable preservation of surface details. Many of the Skeletons were poorly washed. This was perhaps in part due to the fragile condition of some elements, in particular vertebrae. A

small quantity of material which displayed pathological lesions was washed by the author. A small number of Skeletons were more than 81% complete with minimal fragmentation and good preservation of surface detail.

### 9.3.2 *Age and sex composition*

Adult males predominated in both phases although a significant number of Skeletons could not be sexed as insufficient diagnostic elements survived. Three Skeletons exhibited contradictory indicators and were classified as indeterminate. There were only seven non-adult Skeletons in the assemblage. There were four adolescents in Phase 1, and two adolescents and a juvenile in Phase 2.

The majority of adults in both phases could only be assigned to the broad adult age category. Most of the adults in Phase 1 that could be more precisely aged were in the prime adult category followed by young adult, older adult and mature adult. In Phase 2, young adults predominated followed by prime adults, then by equal numbers of mature and older adults. There is, therefore, some evidence to suggest that people were dying younger although the numbers are very small.

### 9.3.3 *The health of the population*

The incidence of joint disease and osteoarthritis was low in both phases. Limited evidence for trauma including fractures, dislocation and spondylolosis was mainly confined to Skeletons from Phase 1. Two probable examples of DISH were identified, one in each phase. A single individual from Phase 1 exhibited evidence of pulmonary infection. Cribra orbitalia was identified in both phases, as was maxillary sinusitis. A clear link between the occurrence of maxillary sinusitis and lepromatous leprosy was identified.

Many Skeletons in both phases exhibited non-specific changes which may well have been caused by leprosy, although in the absence of other indicators, it is impossible to prove this.

Rates of calculus were normal for the period, though slightly more females than males were affected. This was also the case for caries and dental abscesses. Conversely, more males than females overall had suffered ante-mortem tooth loss. The variation between the sexes was much more marked in Phase 1. Dental enamel hypoplasia had a marked increase in Phase 2. In Phase 1, may more females than males were affected, while in Phase 2 the rates were virtually identical.

### 9.3.4 *Skeletal evidence for leprosy at St Leonard's*

Leprosy is difficult to contract and approximately 90% of those infected do not go on to develop the disease; of those who contract leprosy today, most die of tuberculosis (Roberts and Cox 2000, 267). More than 80% of people diagnosed with leprosy in a modern context die before any Skeletal changes take place (Steinbock 1976, 6) and this has probably always been the case. A total of 11 Skeletons from Phase 1 exhibited definite rhino-maxillary changes (CPR 13.25% 11/83; TPR 47.83%, 11/23) compared with a minimum of 3 in Phase 2 (CPR 6.38%, 3/47; TPR 27.27%, 3/11). The diagnosis of a further 10 Skeletons from Phase 1 and 8 from Phase 2 was less clear cut and they have been categorised as probable examples of lepromatous leprosy due to the presence of possible rhino-maxillary changes and/or other classic features including claw hand deformity, claw toe deformity and volar grooves.

As noted above, young people are particularly vulnerable to contracting the disease between the ages of 10 and 20 but the bony changes take from 5 – 7 years to develop (Boylston 2012, 1). Of the four non-adults in Phase 1, one was diagnosed as a probable sufferer of lepromatous leprosy (136) and one as possible (60). A single non-adult Skeleton (12) in Phase 2 was probably suffering from lepromatous leprosy.

In Phase 1 the Skeletons identified as definite cases of lepromatous leprosy comprised six males, three females, one unsexed adult and one indeterminate adult. All age categories were represented: there were four prime adults, two young adults, two mature adults, one older adult and two adults aged upwards of 18 years. Lepromatous Skeletons in Phase 2 comprised one young adult male, one adult male aged upwards of 18 years and one mature adult female. At Chichester, 37 (9.64%) Skeletons had definite rhino-maxillary syndrome (RMS) with a further 20 having changes that are considered to be early RMS (Lee and Magilton 2008, 266).

Modern clinical data suggests that patients with leprosy die on average 25 years earlier than the population from which they come (Miller 1994; Nunzi and Massone 2012; Roffey and Tucker 2012, 174). As noted above, there is some limited evidence to suggest that people were dying younger at St Leonard's although the number are very small. There is a slight predominance of young and prime adults among the adult Skeletons who were identified as definite cases of lepromatous leprosy.

#### 9.3.5 *The hospital of St Leonard's in context*

There is evidence of leprosy in Britain prior to the medieval period (see McComish section 5 above) but it appears to have become a social problem in the middle of the 11<sup>th</sup> century (Orme and Webster 1995). It did, however, have a very limited temporal span in England and Wales, and only reached endemic proportions between the 12<sup>th</sup> and 14<sup>th</sup> centuries (Clay 1909). The population of England, which doubled during the medieval period (Dyer 1989), was reduced by 35-50% in the middle of the 14<sup>th</sup> century by the Black Death (Miller and Hatcher 1978) and this disease may have been partly responsible for the decline of leprosy in the 14<sup>th</sup> century (see Roberts 2011, 264). Lepers were susceptible to plague because their immune systems were compromised. Outbreaks of plague in Peterborough were documented in 1348, 1361, 1399, 1506-7, 1574, 1625, and 1665-7 (Tebbs 1979, 67). There is historical evidence to suggest that after the mid-14<sup>th</sup> century life expectancy increased (Dyer 1989, 182) due, in part to a dramatic decrease in the population caused by the Black Death.

A link has also been suggested between the decline of leprosy and the climate in Britain (Duncan 1994). The rise and fall of leprosy coincides respectively with what is known as the 'medieval warm epoch' of AD 1150-1300 and the 'climatic worsening' of AD 1300-1500 (Roberts and Cox 2002, 228). It is known that the survival of the bacillus outside the body is reduced with lower temperatures and that precipitation levels also play a part. Duncan's work suggests that climatic changes may have been a factor in the spread and decline of leprosy but that human responses to such change acted synergistically with climate to that effect (op. cit).

It was a fundamental belief of the Christian church that God used sickness as a means of stigmatising or punishing the wicked (Roberts and Cox 2000, 249). Infectious disease was

ascribed to airborne vapours which were absorbed through the open pores of the body thus the breath of leprosy sufferers was believed to be a risk to the healthy (Rawcliffe 1995). Contemporary sources make it clear that a leper was stigmatised and a complex object of pity, revulsion and ostracism. Admission to a leprosy hospital involved a symbolic funeral acting as a rite of separation. Lepers were disinherited, wore distinctive clothing and had to carry a clapper to warn others that they were in the vicinity. Conversely, benefactors provided for their wellbeing. Roberts and Cox (2000, 268) suggest that the term leper represented a concept or concepts of particular relevance to the medieval psyche rather than a clear-cut case of an individual with a particular disease process. The use of trained physicians to diagnose leprosy did not occur until the 15<sup>th</sup> century (*ibid.*, 269). Prior to this, diagnoses relied on a variety of tests such as observing the speed at which grains of salt dissolved in the blood, pricking the hands and feet with a needle, examination of urine, and observing facial characteristics through a flame (*ibid.*). Leprosy was applied to a wide range of skin conditions (Roffey 2012, 204) and there is evidence for misdiagnosis in medieval documents (Magilton 2008, 10). Treatment involved herbal remedies including the use of fumitory, scabious and nettle, bloodletting, dietary regimes including dried scorpion heads and soil from an ant hill (Roberts and Cox 2000, 270).

More than 300 leper hospitals were documented in medieval England, most of which were founded before the 14<sup>th</sup> century (Knowles and Hadcock 1971; Satchell 1998; Magilton 2008; Roffey and Tucker 2012, 170). The traditional view that these were specialised institutions for the provision and the exclusion of leprosy sufferers is in part contradicted by the archaeological evidence which suggests that these cemetery populations were broader and that the range of diseases was wider (*ibid.*). This is borne out by the evidence from St Leonard's where just under half of the skeletons in Phase 1, and just over one quarter of the skeletons in Phase 2 were afflicted with leprosy. At St James and St Mary Magdalene, Chichester the prevalence rate was 19.5% (see below) while at St Mary Magdalene, Winchester a prevalence rate of 86.8% was recorded (Roffey and Tucker 2012, 170).

The chief building period for such hospitals was before the middle of the thirteenth century (Clay 1909). During the 14<sup>th</sup> century, schemes of taxation still referred to lepers and measures were taken for their expulsion from towns. Like other hospitals, leprosaria were situated outside the city walls, which made it easier for sufferers from the disease to respect the interdiction they were under not to enter the urban precinct. The elderly and the unwell also sought admission to leprosaria which after the 14th century often became almshouses or hospitals for the poor (Satchell 1998).

The largest excavation of a cemetery associated with a leprosy hospital is St James and St Mary Magdalene, Chichester, where 384 skeletons in 374 graves were excavated (Lee and Magilton 2008, 151). Seventy-five of these (19.5%) showed osteological evidence of the disease (Lee and Magilton 2008, 265) although recent work on this assemblage hints at the possibility of more examples (Storm *pers. comm.*; quoted in Boylston 2012, 2). The male to female ratio was abnormal with 190 male or probable male burials (49.8%), 81 female or probable female burials (20.8%) and 113 of undetermined sex (29.4%). At St Leonard's a similar trend was observed in both phases. The combined total were 53 males or probable males (43.09%), 20 females or probable females (16.26%), 47 unsexed adults (38.21%) and 3

indeterminate adults (2.44%). At Chichester over 83% of all burials with leprosy were male compared with 13.3% of women; the predominance of male lepers over female one is explained by the original foundation being for men only (Lee and Magilton op. cit.).

Children at Chichester made up 27% of the total sample (104 Skeletons), however, only two (1.58%) of these came from the earlier part of the cemetery used by the leprosarium and their presence raises questions as to whether or not they were recognised by the community as suffering from the disease (Lewis 2008, 174). This figure is lower than St Leonard's where seven non-adults were identified (5.38%). Children were admitted to leprosaria with their sick parents to prevent them from becoming orphaned and destitute and during the medieval period they were considered to be particularly vulnerable to leprosy as demonstrated by 15<sup>th</sup> century edicts which prohibited leprosy sufferers from touching children (Mercier 1915; Lewis 2008, 175). At Chichester, the most common infectious disease among the children was tuberculosis and it was suggested that the slowly debilitating nature of leprosy probably means that even if the children had the skin lesions of leprosy, skeletal lesions did not have time to develop before they died. There was only one young child at St Leonard's (132) and periosteal lesions were present on the lower legs. Abnormal porosity of the palate and maxillary sinusitis were also observed. There were no complete long bones so it was not possible to compare skeletal growth with dental development. At Chichester, the growth profiles of the children showed them to be shorter than other later medieval children from lay cemeteries and the leprosy sample from Naestved in Denmark, so they were clearly disadvantaged (Lewis 2008, 187). All the other non-adults at St Leonard's were adolescents and two of them (12, 136) had pathological lesions probably indicative of leprosy. In neither case did the maxilla survive. At Winchester, three adolescents had relatively advanced leprosy changes to the rhinomaxillary region, hands and feet, as well as associated infections of the distal lower limbs, which suggests that they contracted the disease at a young age (Roffey and Tucker 2012, 174).

In addition to the nearly 20% of skeletons at Chichester who presented some lesions associated with leprosy, a further 3-13% had non-specific changes whose distribution suggested early leprosy change (Lee and Magilton 2008, 269). At St Leonard's 12% (10/83) of skeletons exhibited lesions probably caused by leprosy while in Phase 2 this figure was 17% in Phase 2 (see Table 29 above for breakdown).

The site at Chichester could clearly be divided into two areas: the earlier was the burial ground which served the leper hospital and contained mainly males with 43% demonstrating some change resulting from leprosy; the later almshouse phase had a more normal population structure with men, women and children present and only 20% of adult burials showed lesions linked to leprosy (Lee and Magilton 2008, 269). This spatial arrangement contrasts markedly with St Leonard's where the second phase of burials (thought to be linked to the function of the hospital as an almshouse) were placed directly on top of the first phase of burials (linked to the function of the hospital as a leprosaria).

The decline in leprosy is well demonstrated at Chichester where sufferers decline in numbers and only a handful of skulls exhibited definite rhino-maxillary syndrome (ibid.). There was a significant increase in tuberculosis although it was argued that this reflected a



change in the admissions policy rather than any connection between the two diseases. There is also evidence of a decline in the incidence of leprosy at St Leonard's with only 3 examples of definite rhino-maxillary change in Phase 2, compared with 11 examples in Phase 1.

The very high prevalence rate at St Mary Magdalen, Chichester has already been referred to above. This cemetery, to the north of the medieval chapel, represents a discrete burial area, separate from the main, more recent cemetery to the south (Roffey and Tucker 2012, 170). This is a much larger percentage than has previously been recorded in other British cemeteries, with 75 of 384 burials (19.5%) from the cemetery of the St James and St Mary Magdalene leper hospital, Chichester, recorded as showing definite evidence for leprosy (Lee and Manchester 2008, 265). A very similar percentage (19.4%, 35 of 180 burials) was recorded among the burials from the Saxo-Norman cemetery at St John Timberhill, Norwich (Shepherd Popescu 2009). The percentage of individuals with Skeletal evidence for leprosy at the medieval leper hospital site of Naestved, Denmark, was very similar to that seen in the Winchester sample (Møller-Christensen 1978). It has been proposed that the relatively low rates of leprosy seen at Chichester and Norwich was the result of the medieval practice of ascribing a number of different diseases, usually of the Skin, to leprosy and isolating these individuals in institutions alongside those with clinical leprosy, as well as the transformation of leper hospitals into more general institutions during the later medieval period (Magilton 2008). It is argued that the institution of St Mary Magdalen, Winchester, seems to have been much more exclusively for those with leprosy (Roffey and Tucker 2012, 174). It is further noted that the evidence from the buildings and cemetery suggests an institutional setting where members of the community were afforded a certain level of care, as well as dignity and respect, which runs contrary to traditional perception of lepers and their social circumstances with the hospital serving as a dedicated, perhaps pioneering, model for the care of lepers (*ibid.*, 178).

### 9.3.6 *Conclusions*

The excavations at St Leonard's are a significant addition to the relatively few modern investigations of cemeteries associated with leper hospitals. The Skeletal evidence suggests that in its first phase the hospital and its cemetery were perhaps not intended exclusively for lepers but rather for individuals who were diseased and infirm because of other afflictions. This compares well with the evidence from Chichester (Magilton et al. 2008) but is in marked contrast to Winchester (Roffey and Tucker 2012). There is also evidence here of the country-wide decline in leprosy beyond the 14<sup>th</sup> century.

## 10 **FUTURE WORK**

by A. Boyle

The analysis was developer-funded and carried out under tight time constraints. Many of the Skeletons were poorly washed which presented difficulties during recording. Radiography is desirable to provide further information on aspects such as the incidence of osteomyelitis in the assemblage, and to determine if possible vertebral fractures have been correctly

identified or are in fact age-related. There are considerable quantities of disarticulated material with some scope for re-association with individual Skeletons.

At Chichester the authors commented on the inability conclusively to differentiate high resistance leprosy (tuberculoid leprosy) from low-resistance leprosy (lepromatous leprosy) in the absence of rhino-maxillary change (Lee and Magilton 2008, 269). They did note that there may be some indication from the presence or absence of symmetrical lesions in the upper and lower limbs. There is some scope for the reconstruction of the bones of the lower legs to further examine the distribution of non-specific lesions, although this will in part be hampered by the fact that many of the post-mortem breaks are not recent and therefore many edges are abraded.

A recent example of a Skeleton of 5<sup>th</sup>-6<sup>th</sup> century date from Great Chesterford combined osteological, biochemical and geochemical analysis (InSkip et al. 2015). The Skeleton showed osteological evidence of lepromatous leprosy and this was confirmed by lipid biomarker analysis and ancient DNA (aDNA) analysis, which provided evidence for both multi-copy and single copy loci from the *Mycobacterium leprae* genome. Strontium and oxygen isotope analysis suggested an origin outside of Britain.

The archive is to be deposited at the University of Durham where there will be opportunities for the assemblage to fulfil its obvious multi-disciplinary research potential.

## PUBLISHED REFERENCES

- Andersen, J. G. and Manchester, K., 1987. 'Grooving of the proximal phalanx in leprosy: a palaeopathological and radiological study', *Journal of Archaeological Science* **14**, 77-82
- Andersen, J. G. and Manchester, K., 1988. 'Dorsal tarsal exostoses in leprosy: a palaeopathological and radiological study', *Journal of Archaeological Science* **15**, 51-6
- Andersen, J. G., Manchester, K. and Roberts, C., 1994. 'Septic bone changes in leprosy: a clinical, radiological and palaeopathological review', *International Journal of Osteoarchaeology* **4**, 21-30
- Anderson, S., 1998. *Leprosy in a medieval churchyard in Norwich. Current and Recent Research in Osteoarchaeology*. Proceedings of the 3<sup>rd</sup> meeting of the Osteoarchaeology Research Group Oxford (Oxford).
- Aufderheide, A. C. and Rodríguez-Martín, C., 1998. *The Cambridge Encyclopaedia of Human Paleopathology* (Cambridge)
- Barber, L. and Siburn, L., 2010. 'The medieval hospital of St Nicholas, Lewes, East Sussex, excavations 1994'. *Sussex Archaeological Collections* **148**, 79-109
- Barton, R. P. E., 1979. 'Radiological changes of the paranasal sinuses in leprosy', *Journal of Laryngology and Otology* **93**, 597-600
- Bass, W. M., 1987. *Human Osteology: A Laboratory and Field Manual*, 3<sup>rd</sup> Edition (Missouri)
- Bennett, K. A., 1965. 'The aetiology and genetics of wormian bones', *American Journal of Physical Anthropology* **23**, 255-260
- Berry, A. C. and Berry, R. J., 1967. 'Epigenetic variation in the human cranium', *Journal of Anatomy* **101**, 361-379
- BinSki, P., 1996. *Medieval Death Ritual and Representation* (British Museum Press)
- Boocock, P., Roberts, C. and Manchester, K., 1995a. 'Maxillary sinusitis in medieval Chichester, England', *American Journal of Physical Anthropology* **98**, 483-95
- Boocock, P., Roberts, C. and Manchester, K., 1995b. 'Prevalence of maxillary sinusitis in leprous individuals from a medieval leprosy hospital', *International Journal of Leprosy* **63**, 265-8
- Boylston, A., 2008. 'The Human Bone', in F. Brown and C. Howard-Davis, *Norton priory: Monastery to Museum Excavations 1970-87* (Oxford), 149-182
- Boylston, A. and Lee, F., 2008. 'Joint disease', in A. Boylston, F. Lees and J. Magilton (eds.), *Lepers Outside the Gate: Excavations at the Cemetery of the Hospital of St James and St Mary Magdalene, Chichester, 1986-1987 and 1993*, Chichester Excavations Volume **10**, CBA Research Report **158** (York), 239-251
- Brickley, M. and McKinley, J. I., 2004. 'Guidelines to the standards for recording of human remains', Institute of Field Archaeologists Paper No. **7** (Reading)

- Brickley, M., Berry, H. and Wester., G., 2006. 'The people: physical anthropology', in J. Adams, M. Brickley, S. Buteaux and R. Cherrington (eds.), *St Martin's uncovered: investigations in the churchyard of St Martin's-in-the-Bull-Ring, Birmingham* (Oxford), 90-151
- Brooks, S.T. and Suchey, J. M., 1990. 'Skeletal age determination based on the os pubis: a comparison of the Ascádi-NemeSkéri and Suchey-Brooks methods', *Human Evolution* **5**, 227-238
- Brothwell, D. R., 1958. 'Evidence of Leprosy in British Archaeological Material', *Medical History* **11**, 287-91
- Brothwell, D. R., 1981. *Digging up Bones, 3rd Edition* (London and Oxford)
- Buckland, P. C. and Magilton, J. R., 1989. *The Archaeology of Doncaster 2. The Medieval and Later Town*. British Archaeological Reports, British Series **202 (ii)** (Oxford)
- Buikstra, J. E. and Ubelaker, D. H., 1994. *Standards for Data Collection from Human Skeletal Remains* (Fayetteville)
- Clay, R. M., 1909. *The mediaeval hospitals of England* (London)
- Cook, D. C., 1994. 'Dental evidence for congenital syphilis (and its absence) before and after the conquest of the New World', in J. Berato, J.P. Brun, O. Dutour and G. Palfi (eds.), *L'Origine de la syphilis en Europe: avant ou après 1493?* (Paris), 169–175.
- Covey, H. C., 2001. 'People with leprosy (Hansen's disease) during the Middle Ages'. *The Social Science Journal* **38**, 315-321
- Cox, M., 2000. 'Ageing adults from the Skeleton', in S. Mays and M.Cox (eds.) *Human Osteology in Archaeology and Forensic Science* (London), 61-82
- Creighton, C., 1894. (reprinted 1965). *A History of epidemics in Britain, Volume 2* (Cambridge).
- Crossan, C., 2004. 'Excavations at St Mary Magdalen's Hospital, Brook Street, Colchester', *Essex Archaeology and History*, **34**, 91-154
- Cullum, P. H., 1991. 'Cremetts and Corrodies: Care of the Poor and Sick at St Leonard's Hospital, York in the Middle Ages', *Borthwick Paper* **79**
- Cullum, P. H., 1994. 'Leper-houses and leprosy during the Middle Ages', *Interim* **19/2**, 24–31
- Daniell, C., 1997. *Death and Burial in Medieval England 1066–1500* (London)
- Demaitre, L., 2007. *Leprosy in Premodern Medicine A Malady of the Whole Body* (Baltimore)
- Duncan, K., 1994. 'Climate and the decline of leprosy in Britain', *Proceedings of the Royal College of Physicians Edinburgh* **24**, 114-20
- Dyer, C., 1989. *Standards of Living in the Later Middle Ages: Social Change in England c. 1200-1520* (Cambridge)
- Farley, M. and Manchester, K., 1989. 'The Cemetery of the Leper Hospital of St Margaret, High Wycombe, Buckinghamshire', *Medieval Archaeology*, **22**, 82-9

- Finnegan, M., 1978. 'Non-metric variation of the infra-cranial Skeleton', *Journal of Anatomy* **125**, 23-37
- Forestier, J. and Lagier, R., 1971. 'Ankylosing hyperostosis of the spine', *Clinical Orthopaedics* **74**, 65-83
- Garmonsway, G. N., 1978. *The Anglo-Saxon Chronicle* (London)
- Grauer, A. L., 1993. 'Patterns of anaemia and infection from medieval York, England', *American Journal of Physical Anthropology* **91**, 203-13
- Hadley, D. M., 2001. *Death in Medieval England* (Stroud)
- Hillson, S., 1996. *Dental Anthropology* (Cambridge)
- İşcan, M. Y., Loth, S. R. and Wright, R. K., 1984. 'Age estimation from the rib phase analysis: white males', *Journal of Forensic Sciences* **29**, 1094-1104
- İşcan, M. Y. and Loth, S. R., 1986. 'Determination of age from the sternal rib in white females: a test of the phase method', *Journal of Forensic Sciences* **31**, 990-999
- Jopling, W. H., 1984. *Handbook of leprosy, 3<sup>rd</sup> edition* (London)
- Jopling, W. H. and McDougall, A. C., 1988. *Handbook of leprosy, 4<sup>th</sup> edition*, (London)
- Kennedy, K. A. R., 1989. 'Skeletal markers of occupational stress', in M.Y. İşcan and K.A.R. Kennedy (eds.), *Reconstruction of Life from the Skeleton* (New York), 129-160
- Knowles, D. and Hadcock, R. N., 1971. *Medieval Religious Houses: England and Wales, 2nd edition* (London)
- Kulkarniu, V. N. and Mehta., J. M., 1983. 'Tarsal disintegration (TD) in leprosy', *Leprosy in India* **55**, 338-69
- Lee, F. and Magilton, J., 2008. 'Physical Anthropology', in A. Boylston, F. Lee and J. Magilton (eds.), *Lepers Outside the Gate: Excavations at the Cemetery of the Hospital of St James and St Mary Magdalene, Chichester, 1986–1987 and 1993*, Chichester Excavations Volume **10**, CBA Research Report **158** (York), 150-156
- Lee, F. and Manchester, K., 2008. 'Leprosy: a review of the evidence in the Chichester sample', in A. Boylston, F. Lee and J. Magilton (eds.), *Lepers Outside the Gate: Excavations at the Cemetery of the Hospital of St James and St Mary Magdalene, Chichester, 1986–1987 and 1993*, Chichester Excavations Volume **10**, CBA Research Report **158** (York), 208–217
- Lee, F. and Boylston, A., 2008. 'Infection: tuberculosis and other infectious diseases', in A. Boylston, F. Lee and J. Magilton (eds.), *Lepers Outside the Gate: Excavations at the Cemetery of the Hospital of St James and St Mary Magdalene, Chichester, 1986–1987 and 1993*, Chichester Excavations Volume **10**, CBA Research Report **158** (York), 218-228
- Lee, F. and Magilton, J., 2008. 'Discussion', in A. Boylston, F. Lee and J. Magilton (eds.), *Lepers Outside the Gate: Excavations at the Cemetery of the Hospital of St James and St Mary Magdalene, Chichester, 1986–1987 and 1993*, Chichester Excavations Volume **10**, CBA Research Report **158** (York), 263-269

Lewis, M. E., 2007. *The Bioarchaeology of Children: Perspectives from Biological and Forensic Anthropology* (Cambridge)

Lewis, M., 2008. 'The children', in A. Boylston, F. Lee and J. Magilton (eds.), *Lepers Outside the Gate: Excavations at the Cemetery of the Hospital of St James and St Mary Magdalene, Chichester, 1986–1987 and 1993*, Chichester Excavations Volume **10**, CBA Research Report **158** (York), 174-187

Lovejoy, C. O., Meindl, R. S., Pryzbeck, T. R. and Mensforth, R., 1985. 'Chronological metamorphosis of the auricular surface of the ilium: a new method for the determination of Skeletal age at death', *American Journal of Physical Anthropology* **68**, 15-28

Lilley, J. M., Stroud, G, Brothwell, D. R. and Williamson, M. H., 1994. *The Jewish burial ground at Jewbury*. The Archaeology of York, The Medieval Cemeteries, **12/3**

Magilton, J., 2008. 'Leprosy, lepers and their hospitals', in A. Boylston, F. Lee and J. Magilton (eds.), *Lepers Outside the Gate: Excavations at the Cemetery of the Hospital of St James and St Mary Magdalene, Chichester, 1986–1987 and 1993*, Chichester Excavations Volume **10**, CBA Research Report **158** (York), 9-26

Magilton, J., Lee, F. and Boylston, A. (eds.), 2008. *Lepers outside the gate Excavations at the cemetery of the Hospital of St James and St Mary Magdalene, Chichester 1856-7 and 1993*. Chichester Excavations **10**. CBA Research report **158**. Council for British Archaeology (York)

Manchester, K., 1981. 'A leprous Skeleton of the 7<sup>th</sup> century from Eccles Kent, and the present evidence of leprosy in early Britain', *Journal of Archaeological Science* **8 Issue 2**, 205-209

Malaviya, G. N., 2010. 'Deformity/disability prevention, Indian Association of Leprologists', in B. Kumar and H. Kumar Kar (eds.) *Textbook of Leprosy* (New Delhi), 447-67

Manchester, K., 2008. 'Appendix 10. Bone changes in leprosy: pathogenesis and palaeopathology', in A. Boylston, F. Lee and J. Magilton (eds.), *Lepers Outside the Gate: Excavations at the Cemetery of the Hospital of St James and St Mary Magdalene, Chichester, 1986–1987 and 1993*, Chichester Excavations Volume **10**, CBA Research Report **158** (York), 182-186

Marcombe, D., 2003. *Leper Knights The Order of St Lazarus of Jerusalem in England, 1150-1544* (Woodbridge)

Margeson, S., 1993. Norwich Households: The Medieval and Post-Medieval Finds from Norwich Survey Excavations 1971-1978. *East Anglian Archaeology Report* No. 58.

Mariotti, V., Dutour, O., Belcastro, M. G., Facchini, F. and Brasili, P., 2005. 'Probable early presence of leprosy in Europe in a Celtic Skeleton of the 4th-3rd century BC', *International Journal of Osteoarchaeology* **15**, 311–325.

Matos, V. And Santos, A. L., 2006. 'On the trail of pulmonary tuberculosis based on rib lesions: results from the human identified Skeletal collection from the Museu Bocage (Lisbon, Portugal)', *American Journal of Physical Anthropology* **130**, 190-200

- Mays, S. A., 1991. *The Medieval Burials from the Blackfriars friary, School Street, Ipswich, Suffolk (Excavated 1983-85)*, Ancient Monuments Laboratory Report 16/91 (Parts I & II)
- Mays, S., Brickley, M., and Dodwell, N., 2004. *Human bones from archaeological sites – Guidelines for producing assessment documents and analytical reports*, English Heritage
- Mays, S. and Cox, M., 2000. 'Sex determination in Skeletal remains', in S. Mays and M. Cox (eds.), *Human Osteology in Archaeology and Forensic Science* (London), 117-130
- Merbs, C. F., 1983. 'Patterns of activity induced pathology in a Canadian Inuit population', *Archaeological Survey of Canada Paper 119*, (Ottawa)
- Merbs, C. F., 2002. 'Asymmetrical spondylolysis', *American Journal of Physical Anthropology 119*, 156-74
- Mercier, E., 1915. *Leper houses and medieval hospitals* (London)
- McDougall, A. C., 1996. 'The clinical examination of peripheral nerves in leprosy', *Indian Journal of Leprosy 68 (4)*, 378-80
- McKinley, J. I., 2004. 'Compiling a Skeletal inventory: disarticulated and co-mingled remains', in M. Brickley and J. I. McKinley (eds.), *Guidelines to the Standards for Recording Human Remains*, IFA Paper No. 7 (Southampton and Reading), 14-17
- Michel, A., 2014. Skin deep: an outline of the structure of different Skins and how it influences behaviour in use. A practitioners' guide, in S. Harris and A. J. Veldmeijer (eds.), *Why Leather? The material and cultural dimensions of leather*, 23-40.
- Miles, A. E. W., 1962. 'Assessment of the ages of a population of Anglo-Saxons from their dentitions', *Proceedings of the Royal Society of Medicine 55*, 881-886
- Miller, R. A., 1994. 'Leprosy (Hansen's disease)', in B. Isselbacher, K. Fauci and M. Wilson (eds.), *Harrison's Principles of Internal Medicine* (New York), 718-722
- Miller, E. and Hatcher, J., 1978. *Medieval England – Rural Society and Economic Change 1086-1348* (London)
- Møller-Christensen, V., 1953. *Ten Lepers from Naestved in Denmark*, Danish Science Press Medical Monograph 2 (Copenhagen)
- Møller-Christensen, V., 1961. *Bone Changes in Leprosy* (Copenhagen)
- Møller-Christensen, V., 1974. 'Changes in the anterior nasal spine and the alveolar process of the maxillae in leprosy: a clinical examination', *International Journal of Leprosy 42*, 431-435
- Møller-Christensen, V., 1978. *Leprosy Changes of the Skull* (Odense)
- Moorrees, C. F. A., Fanning, E. A. and Hunt, E. E., 1963a. 'Formation and resorption of three deciduous teeth in children', *American Journal of Physical Anthropology 21*, 205-213
- Moorrees, C. F. A., Fanning, E. A. and Hunt, E. E., 1963b. 'Age variation of formation stages for ten permanent teeth', *Journal of Dental Research 42*, 1490-1502
- Nenk, B., Margeson, S. and Hurley, W., 1992. 'Medieval Britain and Ireland 1991', *Medieval Archaeology 36*, 251

- Nenk, B., Margeson, S. and Hurley, W., 1994. 'Medieval Britain and Ireland 1993', *Medieval Archaeology* **38**, 1954-5
- Nicholson, A. and Hill, P., 1997. 'The Non-Ferrous Metals', in P. Hill (ed.) *Whithorn and St Ninian The Excavation of a Monastic Town 1984-91* (Stroud)
- Nunzi, E. and Massone, C. (eds.), 2012. *Leprosy: A Practical Guide* (London and New York)
- Orme, N. and Webster, M., 1995. *The English hospital 1070-1570* (New Haven, Yale University Press)
- Ortner, D. J., 2003. *Identification of Pathological Conditions in Human Skeletal Remains* (Amsterdam)
- Ortner, D., J. 2008. 'Skeletal manifestations of leprosy', in A. Boylston, F. Lee and J. Magilton (eds.), *Lepers Outside the Gate: Excavations at the Cemetery of the Hospital of St James and St Mary Magdalene, Chichester, 1986-1987 and 1993*, Chichester Excavations Volume **10**, CBA Research Report **158** (York), 198-207
- Ortner, D. J. and Erickson, M., 1997. 'Bone changes in the human skull probably resulting from scurvy in infancy and childhood', *International Journal of Osteoarchaeology* **7**, 212-220
- Ortner, D. J. and Putschar, W. G. J., 1981. *Identification of Pathological Conditions in Human Skeletal Remains* (Washington)
- Panter, I., 1994. 'Well Travelled Coffins', *Interim* **19/3**, 26-33
- Parry, E. H., 1984. *Principals of medicine in Africa* (Oxford)
- Rawcliffe, C., 1995. *Medicine and society in later medieval England* (Stroud)
- Rawcliffe, C., 2006. *Leprosy in Medieval England* (Woodbridge)
- Resnick, D., 2002. *Diagnosis of Bone and Joint Disorders*, 4th Edition (Philadelphia)
- Resnick, D. and Niwayama, G., 1988. *Diagnoses of bone and joint disorders*, 2<sup>nd</sup> edition (Philadelphia)
- Roberts, C., 2000. 'Infectious disease in biocultural perspective: past, present and future work in Britain', in S. Mays and M. Cox (eds.), *Human Osteology in Archaeology and Forensic Science* (London), 145-162
- Roberts, C., 2011. 'The Bio Archaeology of Leprosy and Tuberculosis A Comparative Study of Perceptions, Stigma, Diagnosis and treatment', in A. C. Agarwal and B. A. Glencross (eds.), *Social Bioarchaeology*, Blackwell Studies in Global Archaeology. (Chichester)
- Roberts, C. A. and Cox, M., 2003. *Health and Disease in Britain. From prehistory to the present day* (Stroud)
- Roberts, C. A. and Manchester, K., 2005. *The Archaeology of Disease*, 3<sup>rd</sup> edition (Stroud)
- Rodwell, W. and Rodwell, K., 1982. 'St Peter's Church, Barton-upon-Humber: Excavation and Structural Study 1978-81', *Antiquaries Journal* **LXII part 2**, 283-315
- Roffey, S., 2012. 'Medieval leper hospitals in England: an archaeological perspective', *Medieval Archaeology* **56**, 203-234



- Roffey, S. and Tucker, K., 2012. 'A contextual study of the medieval hospital and cemetery of St Mary Magdalen, Winchester, England', *International Journal of Palaeopathology* **2**, 170-180
- Rogers, J. and Waldron, T., 1995. *A field guide to joint disease in archaeology* (Chichester)
- Rogers, J., 2000. 'The palaeopathology of joint disease', in S. Mays and M. Cox (eds.), *Human Osteology in Archaeology and Forensic Science* (London), 163-185
- Santos, A. L. and Roberts, C. A., 2001. 'A picture of tuberculosis in young Portuguese people in the early 20<sup>th</sup> century: a multidisciplinary study of the Skeletal and historical evidence', *American Journal of Physical Anthropology* **115**, 38-49
- Santos, A. L. and Roberts, C. A., 2006. 'Anatomy of a serial killer: differential diagnosis of tuberculosis based on rib lesions of adult individuals from the Coimbra Identified Skeletal Collection, Portugal', *American Journal of Physical Anthropology* **130**, 38-49
- Saunders, S. R., 1989. 'Non-metric variation', in M. Y. İşcan and K. A. R. Kennedy (eds.), *Reconstruction of Life from the Skeleton* (New York), 95-108
- Schaefer, M., Black, S. and Scheuer, L., 2008. *Juvenile Osteology: A Laboratory and Field Manual*
- Scheuer, L. and Black, S., 2000a. 'Development and ageing of the juvenile Skeleton', in S. Mays and M. Cox (eds.), *Human Osteology in Archaeology and Forensic Science* (London), 9-22
- Scheuer, L. and Black, S., 2000b.. *Developmental Juvenile Osteology* (San Diego)
- Shah, A. and Shah, N. 2010. 'Deformities of face, hands and feet and their management', in H. Kumar Kar and B. Kumar (eds.), *Indian Association of Leprologists' Textbook of Leprosy* (New Delhi), 424-446
- Shepherd Popescu, E., 2009. 'Norwich Castle: Excavations and Historical Survey 1987–98. Part I: Anglo-Saxon to c. 1345', *East Anglian Archaeology* **132**
- Steane, J., 1985. *The Archaeology of England and Wales* (London and New York)
- Steinbock, R. T., 1976. *Palaeopathological diagnosis interpretation* (Springfield, Illinois)
- Stewart, T. D., 1979. *Essentials of Forensic Anthropology* (Springfield, Illinois)
- Stirland, A., 2009. *Criminal and Paupers the graveyard of St Margaret Fyebiggate in Combusto, Norwich, 1987*, *East Anglian Archaeology* 129.
- Stroud, G. and Kemp, R. L., 1993. *Cemeteries of St Andrew, Fishergate*. The Archaeology of York, The Medieval Cemeteries, **12/2**
- Stuart-Macadam, P., 1992. 'Anaemia in past populations', in P. Stuart-Macadam and S. Kent (eds.), *Diet, Demography and Disease: Changing Perspectives of Anaemia* (New York), 151-170
- Taylor, G. M., Widdison, S., Brown, I. N. and Young, D., 2000. 'A medieval case of leprosy from 13-14<sup>th</sup> century Orkney', *Journal of Archaeological Science* **27**, 1133-1138

- Tebbs, H. F., 1979. *Peterborough* (New York)
- Trinkhaus, E., 1978. 'Bilateral asymmetry of human Skeletal non-metric traits', *American Journal of Physical Anthropology* **49**, 315-318
- Trotter, M., 1970. 'Estimation of stature from intact long limb bones', in T. D. Stewart (ed.), *Personal Identification in Mass Disasters* (Washington DC), 71-83
- Ubelaker, D. H., 1989. *Human Skeletal Remains; Excavation, Analysis, Interpretation* (Washington)
- Victoria County History (VCH), Serjeantson, R. M., Ryland W. and Adkins, D., (eds.) 1906. *A History of the County of Northampton: Volume 2*. (London).
- Walker, D., 2012. *Disease in London, 1<sup>st</sup>-19<sup>th</sup> centuries. An illustrated guide to diagnosis*, MOLA Monograph **56**, Museum of London Archaeology, London
- Walker, P. L., 1995. 'Problems of preservation and sexism in sexing: some lessons from historical collections for palaeodemographers', in A. Herring and S. R Saunders (eds.), *Grave Reflections: Portraying the Past through Cemetery Studies* (Toronto), 31-47
- Walker, P. L., Bathurst, P. R., Richman, R., Gjerdrum, T. and Andrushko, V. A., 2009. 'The causes of porotic hyperostosis and cribra orbitalia: a reappraisal of the iron-deficiency-anaemia hypothesis', *American Journal of Physical Anthropology* **139**, 109-125
- Waldron, T., 1991. 'Variations in the rates of spondylolysis in early populations', *International Journal of Osteoarchaeology* **1**, 63-5
- Wedel, V. L. and Galloway, A., 2014. *Broken bones. Anthropological Analysis of blunt force trauma*, 2<sup>nd</sup> edition (Springfield, Illinois)
- Wells, C., 1976, 'A Leper Cemetery at South Acre, Norfolk', *Medieval Archaeology* **11**, 242-248

## WEB-BASED REFERENCES

Boylston, A, 2012 Charnel deposits from St Bartlemas' Chapel excavation, Oxford 2011. Discussion of the palaeopathology and its implications. Available online at <http://www.archeox.net/investigations/human-bone-archeox-excavations-bartlemas-chaple-autumn-2011.html>

British Geological Survey website. Available online at <http://mapapps.bgs.ac.uk/geologyofbritain/home.html>

Gilchrist, R. and Sloan, B. 2005. *Medieval monastic cemeteries in Britain 1050-1600: a digital resource and database of excavated samples*. Available online at [http://archaeologydataservice.ac.uk/archives/view/cemeteries\\_ahrb\\_2005/](http://archaeologydataservice.ac.uk/archives/view/cemeteries_ahrb_2005/)

Historic England. Available online at

<https://historicengland.org.uk/listing/the-list/list-entry/1021210>.

InSkip, S. A., Taylor, G. M. , Zakrzewski, S. R., Mays, S. A., Pike, A. W. G., and Llewellyn, G., 2015. *Osteological, Biomolecular and Geochemical Examination of an Early Anglo-Saxon Case of Lepromatous Leprosy*. Available online at

<http://journals.plos.org/plosone/article?id=10.1371/journal.pone.0124282>

John Burns Library (for the Connolly Book of Hours). Available online at

<https://johnburnslibrary.wordpress.com/2013/04/22/connollybookofhours/>

McComish, J. M., 2007. *Roman, Anglian and Anglo-Scandinavian Activity and a Medieval Cemetery on land at the Junction of Dixon Lane and George Street, York*, York Archaeological Trust report AYW9. Available online at

<http://www.yorkarchaeology.co.uk/wp-content/uploads/2015/05/AYW9-Dixon-Lane-and-George-Street1.pdf>

McComish, J. M., 2015. *Archaeological Investigations at 12-18 Swinegate 14 Little Stonegate and 18 Back Swinegate*, York Archaeological Trust report 2015/44. Available online at

<http://www.yorkarchaeology.co.uk/wp-content/uploads/2015/08/Swinegate-Final-text-with-Figures.pdf>

Pastscape. Available online at

[http://www.pastscape.org/hob.aspx?hob\\_id=364024](http://www.pastscape.org/hob.aspx?hob_id=364024)

Peterborough HER. Available online at

<http://her.peterborough.gov.uk/forms/Homepage.aspx>

Open Domesday. Available online at

<http://opendomesday.org/place/TL1998/peterborough/>

Robbins, G., Tripathy, V. M., Misra, V. N., Mohanty, R.K., Shinde, V. S. and Gray, K. M., 2009 *Ancient Skeletal Evidence for Leprosy in India (2000 B.C.)*. Available online at

<http://journals.plos.org/plosone/article?id=10.1371/journal.pone.0005669>

Roffey, S. and Marter, P., 2012. *Excavations at the Hospital of St Mary Magdalen, Winchester, 2008-2012: A Summary Report*. Available online at <http://www.winchester.ac.uk/academicdepartments/archaeology/Research/MHARP/Documents/MHARP2012Report.pdf>

Witkin, A., 2000. *Excavation and Analysis of a Skeleton from Hady Hill, Chesterfield, Derbyshire*. Available online at <https://cswb.bournemouth.ac.uk/aip/online/E/east%20midlands/EDERBS.pdf>

## UNPUBLISHED SOURCES

Dye, J. and Jenkins, C., 2015. *Former GB Oils Site, Midland Road, Peterborough, Cambridgeshire, archaeological evaluation*. Archaeological Services, Durham University, Report 3520

Evans, D., 1992. *130-148 Lawrence Street, York: A Report on an Archaeological Evaluation* YAT Evaluation Report 1992/10

Goode, J. L., 1993. *A consideration of the effects of nerve thickening on the Skeleton in individuals suffering from leprosy*, Unpublished BSc dissertation, University of Bradford

MacQueen, J., 2012. *Midland Road, Peterborough, Heritage Assessment*. URS

Satchell, M. 1998. *The Emergence of Leper-houses in Medieval England, 1100-1250*. PhD thesis, Oxford University

Swann, N., 2015. *Midland Road, Peterborough, Cambridgeshire, archaeological excavation*. Archaeological Services, Durham University, Report 3726

## ACKNOWLEDGEMENTS

Ben Savine and Gary Millward are thanked for preparing the figures.

Angela Boyle would like to extend sincere thanks to Dr Louise Loe of Oxford Archaeology who commented on selected sections of the text and the catalogue of Skeletons. The author also acknowledges the assistance of Dr Linda Fibiger of Edinburgh University. Any errors or omissions, however, are the responsibility of the author.

## APPENDIX 1 – SKELETON CATALOGUE AND DISARTICULATED DEPOSITS

by A. Boyle

### Introduction

The total number of Skeletons in the catalogue is 131. One Skeleton (Sk 41) could not be located during analysis. The maxilla of Sk 51 could not be located. The data presented on the missing maxilla was collected by Ruth Whyte rather than the author. Deposit 131 which was identified as a Skeleton during excavation is in fact a disarticulated deposit. A summary of all disarticulated deposits forms Appendix 1b. A full table of all disarticulated material exists in the archive.

### Appendix 1a - Skeleton Catalogue

Key to the catalogue

#### *Preservation*

Surface preservation was recorded with reference to the scoring criteria of McKinley (2004, 16).

#### *Fragmentation*

Five categories were used for scoring the degree of fragmentation of the Skeletons, ranging from minimal (little or no fragmentation) through to extreme (extensive fragmentation with bones in multiple small fragments).

#### *Completeness*

Completeness of individual Skeletons was expressed as a percentage: 0-20%, 21-40%, 41-60%, 61-80% and 81-100%.

#### *Sex*

Skeletons were assigned to one of the following categories: male, male?, unsexed, female?, female, and indeterminate.

#### *Age at death*

Non-adult age categories comprised foetus (f: below 38-40 weeks in utero), neonate (N - birth to 1 month), infant (I - 1 to 12 months), younger juvenile (YJ - 1 to 6 years), older juvenile (OJ - 7 to 12 years) and adolescent (A - 13 to 17 years). Adults were assigned to one of the following categories: young adult (YA - 18 to 25 years), prime adult (PA - 26 to 35 years), mature adult (MA - 36 to 45 years), and older adult (OA - 45+ years). A category of adult (A) was assigned to adult Skeletons who could not be more precisely aged than 18 years or older. A category of non-adult was assigned to Skeletons who could not be more precisely aged than less than 18 years (NA).

#### *Skeletal pathology*

Pathological changes have been assigned to one of the following categories:

- Congenital
- Metabolic
- Joint disease
- Trauma

- Infectious
- Miscellaneous

### *The classification of leprosy*

Skeletons have been assigned to categories depending on the evidence available as follows:

- Skeleton has lepromatous leprosy – rhino-maxillary changes are present
- Skeleton is likely to have lepromatous leprosy – characteristic changes to hands and/or feet are present. These include claw hand, volar grooves, claw toe, transverse arch collapse, septic arthritis and osteomyelitis, although other conditions cannot be ruled out.
- Skeleton may have leprosy – periosteal lesions involving the forearms and or lower legs. Other conditions cannot be ruled out.
- Non-specific infection – no classic changes or patterns of change that could be linked to leprosy.

It is stated where post-mortem damage hinders diagnoses.

The following abbreviations have been used in the catalogue:

- JD = joint disease
- SJD = spinal joint disease
- OA = osteoarthritis

### *Dentition*

#### *Presence/absence*

P = tooth present

AM = ante-mortem tooth loss

PM = post-mortem tooth loss

UE = tooth present but unerupted

E = erupting

R = root only

B = broken

CON = congenital absence

#### *Calculus (after Brothwell 1981)*

F = flecks

S = slight

M = moderate calculus

H = heavy calculus

A = all surfaces

B = buccal

D = distal

M = mesial

L = lingual

O = occlusal

*Caries (After Brothwell 1981)*

S = small

M = moderate

L = large

A = all surfaces

B = buccal

D = distal

M = mesial

L = lingual

O = occlusal

*DEH – dental enamel hypoplasia*

L = lines

G = grooves

P = pits

*Wear (after Smith 1984, in Buikstra and Ubelaker 1994)*

Graded from 1-8: slight to severe.

Skeleton Number	1 (Phase 2)
Preservation	2
Completeness	0-20%
Fragmentation	Moderate
Age	Adult (18+ years)
Sex	?
Stature	n/d
Non-metric traits	Double anterior calcaneal facet (left).
Pathology	<p><u>Extra-spinal joint disease</u>: left foot (navicular); left toe (1<sup>st</sup> tarso-metatarsal joint)</p> <p><u>Extra-spinal OA</u>: left foot (intermediate cuneiform).</p> <p><u>Non-specific infection</u>: left fibula shaft has woven bone on distal third, lateral surface; woven bone on plantar surface of shaft of left 1<sup>st</sup> metatarsal, distal third; woven bone on plantar and dorsal surfaces of shaft of left 2<sup>nd</sup> metatarsal, proximal third; woven bone on plantar and dorsal surfaces of shaft of left 5<sup>th</sup> metatarsal, proximal half, partial destruction of distal articulation; partial destruction of distal articulation of left 4<sup>th</sup> metatarsal; partial destruction of proximal articulation of left 3<sup>rd</sup> proximal foot phalanx. Destruction of articulations suggestive of <u>septic arthritis and transverse arch collapse</u>.</p> <p><u>Tarsal bar</u>: Bony exostosis on left navicular. <u>Probable lepromatous leprosy</u>.</p>
Dental health	No surviving dentition.
Comments	No maxilla, forearms, hands, right lower leg or right foot, very little of left lower leg survives.

Skeleton Number	3 (Phase 1)
Preservation	1
Completeness	21-40%
Fragmentation	Severe
Age	Adult (18+ years)
Sex	?
Stature	n/d
Non-metric traits	Parietal foramen (bilateral).
Pathology	<p><u>Extra-spinal joint disease</u>: right hip (small lytic lesion).</p> <p><u>Non-specific infection</u>: area of striated lamellar bone on medial surface of distal left fibula shaft, lower legs very fragmented.</p> <p><u>Trauma</u>: midshaft of right radius exhibits abnormal angulation, possible healed fracture.</p>
Dental health	One loose tooth, uncertainly identified as incisor or canine, wear grade 6, heavy calculus deposits on buccal, lingual, mesial and distal surfaces. AML (0/1), calculus (1/1), caries (0/1), DEH (0/1), abscess (0/0), tooth positions (0/1).
Comments	No maxilla or feet surviving, very little of hands. Severely fragmented vertebrae not identified.



Skeleton Number	4 (Phase 1)																
Preservation	1																
Completeness	0-20%																
Fragmentation	Severe																
Age	Young adult (18-25 years)																
Sex	Female																
Stature	n/d																
Non-metric traits	Ossicle in lambdoid (bilateral), metopic suture, ossicle in coronal (bilateral), bridging of supraorbital notch (right).																
Pathology	<p><u>Lepromatous leprosy</u>: rhino-maxillary changes, only left side survives, abnormal porosity on palate, abnormal porosity and new bone deposition on left nasal floor, extensive remodelling of left side of nasal aperture, linear lytic defect near junction with nasal floor, probable concave facial profile.</p> <p><u>Maxillary sinusitis</u>: globules of new bone in left sinus, right does not survive.</p> <p>?<u>Trauma</u>: left radius, possible healed fracture, bone appears unusually malaligned at distal end.</p>																
Dental health	Slight mandibular and maxillary periodontal disease. AMTL (0/26), calculus (25/26), caries (0/26), DEH (6/26), enamel chipping (1/26), abscess (0/17), tooth positions (0/17). Presence of occlusal calculus on maxillary dentition indicates lack of occlusion with mandibular.																
Right dentition									Left dentition								
Present	-	-	-	-	-	P	-	P	P	P	P	P	P	P	P	P	P
Calculus	-	-	-	-	-	sbm	-	Fa	-	Sa	fa	mmd	sbmb	mo	sbm	sol	
DEH	-	-	-	-	-	-	-	-	3L	-	1L	-	-	-	-	-	
Caries	-	-	-	-	-	-	-	-	-	-	-	-	-	-	-	-	
Wear	-	-	-	-	-	2	-	2	2	2	2	2	2	3	2	2	
Maxilla	8	7	6	5	4	3	2	1	1	2	3	4	5	6	7	8	
Mandible	8	7	6	5	4	3	2	1	1	2	3	4	5	6	7	8	
Present	P	P	P	P	P	P	P	P	P	P	P	P	P	P	P	P	P
Calculus	ml	sbm	smb	Mb	sl	sbm	sa	mbm	slm	Sb	sbl	sbml	sbml	sbml	sbml	sdl	
DEH	-	-	-	-	3L	1L	-	-	-	-	2L	2L	-	-	-	-	
Caries	-	-	-	-	-	-	-	-	-	-	-	-	-	-	-	-	
Wear	3	3	4	3	4	2	2	2	2	2	2	2	2	4	3	3	
Comments	No hands, feet or lower legs. Radiocarbon dated. Sample 4, 1150-1300 cal AD (92.1% probability), 1050-1300 cal AD (95.4% probability).																

Skeleton Number		5 (Phase 1)															
Preservation		1															
Completeness		41-60%															
Fragmentation		Moderate															
Age		Older adult (45+ years)															
Sex		?															
Stature		n/d															
Non-metric traits		None															
Pathology		<p><u>Extra-spinal OA</u>: left and right sacro-iliac (moderate porosity and marginal osteophytes).</p> <p><u>Non-specific infection</u>: periosteal lesions on left and right tibiae and fibulae; confined to anterior and medial surfaces of shafts, remodelling.</p>															
Dental health		One loose tooth. AMTL (0/1), calculus (1/1), caries (0/1), DEH (0/1), abscess (0/0), tooth positions (0/1). Enamel chipped on buccal and lingual sides. Marked wear sloping downwards from buccal to lingual.															
Right dentition										Left dentition							
Present	P	-	-	-	-	-	-	-	-	-	-	-	-	-	-	-	-
Calculus	ms	-	-	-	-	-	-	-	-	-	-	-	-	-	-	-	-
DEH	-	-	-	-	-	-	-	-	-	-	-	-	-	-	-	-	-
Caries	-	-	-	-	-	-	-	-	-	-	-	-	-	-	-	-	-
Wear	8	-	-	-	-	-	-	-	-	-	-	-	-	-	-	-	-
Maxilla	8	7	6	5	4	3	2	1	1	2	3	4	5	6	7	8	
Mandible	8	7	6	5	4	3	2	1	1	2	3	4	5	6	7	8	
Present	-	-	-	-	-	-	-	-	-	-	-	-	-	-	-	-	-
Calculus	-	-	-	-	-	-	-	-	-	-	-	-	-	-	-	-	-
DEH	-	-	-	-	-	-	-	-	-	-	-	-	-	-	-	-	-
Caries	-	-	-	-	-	-	-	-	-	-	-	-	-	-	-	-	-
Wear	-	-	-	-	-	-	-	-	-	-	-	-	-	-	-	-	-
Comments		No pathological changes to feet which are well preserved. No maxilla or hands surviving. Little of forearms survives.															

Skeleton Number	6 (Phase 2)
Preservation	1
Completeness	41-60%
Fragmentation	Moderate
Age	Adult (18+ years)
Sex	?
Stature	n/d
Non-metric traits	Vastus notch (bilateral)
Pathology	<p><u>Spinal joint disease</u>: 4 thoracic, 5 lumbar, 1 sacral (osteophytes, porosity); dense new bone deposition on inferior body of LV5 and superior body of S1.</p> <p><u>Extra-spinal joint disease</u>: left elbow, left wrist, left and right hip, left and right knee; right sacral ala has moderate osteophytes; dense, irregular new bone deposition across most of articulation; right auricular surface is similarly affected; c 30% of left sacral ala survives and is similarly affected; left auricular surface does not survive.</p> <p><u>Extra-spinal OA</u>: right wrist, right sacro-iliac</p> <p><u>Non-specific infection</u>: possible periostitis on anterior half of right sacral ala.</p>
Dental health	No surviving dentition
Comments	No maxilla, little of feet surviving.

Skeleton Number	7 (Phase 2)
Preservation	0
Completeness	41-60%
Fragmentation	Severe
Age	Adult (18+ years)
Sex	Male
Stature	n/d
Non-metric traits	None
Pathology	<p><u>Spinal joint disease</u>: 5 cervical, 2 thoracic (osteophytes, porosity and Schmorl's nodes); superior and inferior body surfaces of TV12 have dense new bone deposits.</p> <p><u>Extra-spinal joint disease</u>: left shoulder, right elbow, left and right wrists, left and right fingers, left and right hip, right knee, left and right ankle, left foot, left and right toes.</p> <p><u>Extra-spinal OA</u>: right finger, left hip.</p> <p><u>Non-specific infection</u>: woven bone on lateral side of right tibia and medial surface of right fibula; right 1<sup>st</sup> proximal foot phalanx has woven bone on dorsal surface of shaft, adjacent to proximal articulation; right 1<sup>st</sup> distal foot phalanx, destruction of distal articulation, porosity on lateral side of shaft, blade-like remodelling affects distal 3<sup>rd</sup> of shaft on lateral side; right 2<sup>nd</sup> distal foot phalanx, limited destruction of distal articulation, abnormal porosity on shaft; 3<sup>rd</sup> left intermediate foot phalanx, new bone deposition on dorsal surface of shaft, lateral side, adjacent to distal articulation. Destruction of articulations is suggestive of <u>septic arthritis</u>. <u>Probable lepromatous leprosy</u>.</p>
Dental health	No surviving dentition.
Comments	Highly fragmented vertebrae with iron concretion. Maxilla does not survive.

Skeleton Number	8 (Phase 1)															
Preservation	1															
Completeness	81-100%															
Fragmentation	Moderate															
Age	Prime adult (26-35 years)															
Sex	Male															
Stature	n/d															
Non-metric traits	Ossicle in lambdoid (bilateral), ossicle in coronal (bilateral), double atlas facet (bilateral), double anterior calcaneal facet (bilateral).															
Pathology	<p><u>Spinal joint disease</u>: 1 cervical facet (mild osteophytes); 7 thoracic bodies (mild osteophytes and porosity, mild to moderate Schmorl's nodes); 1 sacral facet (mild osteophytes)</p> <p><u>Extra-spinal joint disease</u>: right TMJ (lytic defect); medial clavicle (mild porosity); distal radius (mild marginal osteophytes), proximal ulna (mild marginal osteophytes) auricular surface (mild marginal osteophytes), proximal fibula (mild marginal osteophytes), talus (mild marginal osteophytes), 1<sup>st</sup> metacarpo-phalangeal joint (mild osteophytes), 2<sup>nd</sup> carpo-metacarpal joint (mild osteophytes and porosity).</p> <p><u>Extra-spinal OA</u>: right manubrio-clavicular joint</p> <p><u>Non-specific infection</u>: striated lamellar bone on right distal tibia shaft, either side of anterior crest; left 1<sup>st</sup> metatarsal, all surfaces of shaft.</p> <p><u>Miscellaneous</u>: bony exostosis on lateral side of shaft of left 1<sup>st</sup> metatarsal at midpoint.</p>															
Dental health	Moderate mandibular periodontal disease. AMTL (0/4), calculus (3/4), caries (0/4), DEH (0/4), abscess (0/4), tooth positions present (4/4), enamel chipping (1/4). Crown of left mandibular 1 <sup>st</sup> molar is chipped at buccal/mesial corner.															
Right dentition								Left dentition								
Present	-	-	-	-	-	-	-	-	-	-	-	-	-	-	-	-
Calculus	-	-	-	-	-	-	-	-	-	-	-	-	-	-	-	-
DEH	-	-	-	-	-	-	-	-	-	-	-	-	-	-	-	-
Caries	-	-	-	-	-	-	-	-	-	-	-	-	-	-	-	-
Wear	-	-	-	-	-	-	-	-	-	-	-	-	-	-	-	-
Maxilla	8	7	6	5	4	3	2	1	1	2	3	4	5	6	7	8
Mandible	8	7	6	5	4	3	2	1	1	2	3	4	5	6	7	8
Present	-	-	-	-	-	-	-	-	-	-	-	-	R	P	P	P
Calculus	-	-	-	-	-	-	-	-	-	-	-	-	-	sl	sbl	sbl
DEH	-	-	-	-	-	-	-	-	-	-	-	-	-	-	-	-
Caries	-	-	-	-	-	-	-	-	-	-	-	-	-	-	-	-
Wear	-	-	-	-	-	-	-	-	-	-	-	-	-	5	3	3
Comments	No maxilla.															

Skeleton Number	9 (Phase 1)															
Preservation	1															
Completeness	81-100%															
Fragmentation	Slight															
Age	Prime adult (26-35 years)															
Sex	Female															
Stature	n/d															
Non-metric traits	Ossicle in lambdoid (bilateral).															
Pathology	<p><u>Spinal joint disease</u>: 2 cervical facets, 4 thoracic bodies, 4 lumbar bodies (mild osteophytes and porosity, mild to moderate Schmorl's nodes); new bone deposition on inferior surface of body of CV7; circular lytic defect on inferior surface of body of LV3.</p> <p><u>Extra-spinal joint disease</u>: left proximal radius (mild marginal osteophytes), left distal radius (mild cyst), left capitate (mild cyst), right hamate (mild marginal osteophytes), right triquetral (moderate cyst), left auricular surface (mild marginal osteophytes), left cuboid (mild porosity), left 4<sup>th</sup> proximal hand phalanx (mild porosity).</p> <p><u>Extra-spinal OA</u>: right manubrium, left 4<sup>th</sup> proximal hand phalanx (mild eburnation), left 5<sup>th</sup> intermediate hand phalanx (mild eburnation), left and right proximal femur (mild central osteophytes and porosity).</p> <p><u>Non-specific infection</u>: woven bone on all surfaces of left tibia, extends to level of nutrient foramen, both epiphyses are missing; only medial and lateral surfaces of right tibia are affected, less severe; all surfaces of fibulae shafts, at least distal 2/3 affected, most severe on posterior surface of left fibula; only small portion of shaft of left 1<sup>st</sup> metatarsal survives, woven bone deposition on all surfaces, most severe on plantar;</p> <p><u>Osteomyelitis</u>: shaft of left 2<sup>nd</sup> or 3<sup>rd</sup> metatarsal is thickened with visible involvement of medullary cavity, probable destruction of distal articulation, also post-mortem damage, woven bone on all surfaces, most severe on dorsal; shaft of left 4<sup>th</sup> metatarsal is thickened with visible involvement of medullary cavity, probable destruction of distal articulation, woven bone on all surfaces, most severe on dorsal, lytic defect on lateral side of shaft immediately distal to proximal articulation; woven bone on all surfaces of shaft of left 5<sup>th</sup> metatarsal, shaft is normal, post-mortem damage to distal articulation; left 1<sup>st</sup> proximal foot phalanx, destruction of proximal and distal articulations, shaft is thickened with woven bone on dorsal surface; left 2<sup>nd</sup> proximal foot phalanx, destruction of proximal and distal articulations, woven bone on ?plantar surface, shaft thickened. Destruction of metatarso-phalangeal joints is suggestive of <u>septic arthritis</u> and <u>transverse arch collapse</u>. Probable lepromatous leprosy.</p> <p><u>Miscellaneous</u>: area of increased porosity and irregular new bone deposition immediately proximal to nuchal crest, ectocranial surface.</p>															
Dental health	Slight maxillary and mandibular periodontal disease. AMTL (0/20), calculus (9/19), caries (3/19), DEH (1/19), abscess (0/16), enamel chipping (3/19), tooth positions present (16/20).															
Right dentition								Left dentition								
Present	P	P	P	P	P	P	P	-	-	-	-	-	-	-	-	-
Calculus	-	Fb	-	-	-	sb	-	-	-	-	-	-	-	-	-	-
DEH	-	-	-	-	-	-	-	-	-	-	-	-	-	-	-	-
Caries	-	-	la	-	-	-	-	-	-	-	-	-	-	-	-	-
Wear	3	4	-	3	3	3	3	-	-	-	-	-	-	-	-	-
Maxilla	8	7	6	5	4	3	2	1	1	2	3	4	5	6	7	8
Mandible	8	7	6	5	4	3	2	1	1	2	3	4	5	6	7	8
Present	P	P	P	P	P	P	P	P	P	P	PM	-	-	P	P	P
Calculus	-	-	sl	Mb	-	sb	sb	sb	sb	-	-	-	-	-	-	sl
DEH	-	-	-	1 L	-	-	-	-	-	-	-	-	-	-	-	-
Caries	-	Ppb	ppd	-	-	-	-	-	-	-	-	-	-	-	-	-
Wear	3	4	4	3	4	3	3	3	3	3	-	-	-	6	4	3
Comments	No anterior maxilla.															

Skeleton Number	10 (Phase 1)															
Preservation	1															
Completeness	21-40%															
Fragmentation	Extreme															
Age	Adult (18+ years)															
Sex	?															
Stature	n/d															
Non-metric traits	None															
Pathology	<p><u>Extra-spinal joint disease</u>: right ulna</p> <p><u>Extra-spinal OA</u>: left and right hip, right knee</p> <p><u>Non-specific infection</u>: periostitis on distal half of right fibula is diffuse and grey in colour, medial surface is affected, active; medial and anterior surfaces of left fibula affected, distal third; tibiae have striated lamellar bone either side of the anterior crest, more marked on medial side, distal half affected; left 5<sup>th</sup> metacarpal and right 4<sup>th</sup> proximal hand phalanx have increased porosity on dorsal shafts; <u>tarsal bar</u> on dorsal rim of left navicular at articulation for intermediate cuneiform. <u>Possible lepromatous leprosy</u>.</p>															
Dental health	AMTL (0/2), calculus (2/2), caries (0/2), DEH (0/2), abscess (0/0), tooth positions (0/2).															
Right dentition								Left dentition								
Present	P	-	-	-	-	-	P	-	-	-	-	-	-	-	-	-
Calculus	sbl	-	-	-	-	-	fd	-	-	-	-	-	-	-	-	-
DEH	-	-	-	-	-	-	-	-	-	-	-	-	-	-	-	-
Caries	-	-	-	-	-	-	-	-	-	-	-	-	-	-	-	-
Wear	5	-	-	-	-	-	6	-	-	-	-	-	-	-	-	-
Maxilla	8	7	6	5	4	3	2	1	1	2	3	4	5	6	7	8
Mandible	8	7	6	5	4	3	2	1	1	2	3	4	5	6	7	8
Present	-	-	-	-	-	-	-	-	-	-	-	-	-	-	-	-
Calculus	-	-	-	-	-	-	-	-	-	-	-	-	-	-	-	-
DEH	-	-	-	-	-	-	-	-	-	-	-	-	-	-	-	-
Caries	-	-	-	-	-	-	-	-	-	-	-	-	-	-	-	-
Wear	-	-	-	-	-	-	-	-	-	-	-	-	-	-	-	-
Comments	Feet are highly fragmented and dirt encrusted. Highly fragmented ribs and vertebrae. No maxilla.															

Skeleton Number	12 (Phase 2)
Preservation	0
Completeness	61-80%
Fragmentation	Slight
Age	Adolescent (16-17 years)
Sex	n/a
Stature	n/a
Non-metric traits	Double anterior calcaneal facet (bilateral), double inferior talar facet (left).
Pathology	<p><u>Spinal joint disease</u>: TV12-12 have moderate Schmorl's nodes on surfaces of superior and inferior surfaces.</p> <p><u>Non-specific infection</u>: swelling of shaft of left femur on lateral surface which is demarcated by woven bone, possible chronic ulcer, differential diagnosis is ossified haematoma.</p> <p><u>Osteomyelitis</u>: left 1<sup>st</sup> metatarsal shaft is thickened, woven bone deposition on dorsal and plantar surfaces, full length of shaft is affected; left 2<sup>nd</sup> metatarsal shaft is thickened, woven bone deposition on dorsal surface, only distal half of bone survives, medullary cavity is involved; left 4<sup>th</sup> metatarsal shaft is thickened, woven bone deposition on dorsal and plantar surfaces, only proximal half of bone survives, medullary cavity is entirely filled with new bone; left 1<sup>st</sup> proximal foot phalanx has thickened shaft; destruction of head of left 1<sup>st</sup> distal foot phalanx; irregular lytic defect on proximal articulation of 1<sup>st</sup> right metatarsal; right 5<sup>th</sup> intermediate foot phalanx is fused to distal, possible claw toe deformity. Destruction of articulation is suggestive of <u>septic arthritis</u>. Probable lepromatous leprosy.</p>
Dental health	No surviving dentition.
Comments	No maxilla. No pathological changes to lower legs or hands.

Skeleton Number	14 (Phase 1)
Preservation	1
Completeness	21-40%
Fragmentation	Severe
Age	Adult (18+ years)
Sex	Female
Stature	n/d
Non-metric traits	None
Pathology	<p><u>Spinal joint disease</u>: 3 thoracic facets (mild porosity)</p> <p><u>Extra-spinal joint disease</u>: right hand, left hip</p> <p><u>Extra-spinal OA</u>: right hip</p> <p><u>Non-specific infection</u>: fragment of distal left tibia has striated lamellar bone on medial surface, small area of active periostitis on lateral surface near distal end; left fibula has woven bone on anterior and lateral surfaces, overlying interosseous crest, lighter in colour, distal 2/3 of shaft affected; small area of more active periostitis on lateral surface towards proximal end of shaft; right tibia has striated lamellar bone and woven bone on shaft fragments, not possible to determine precise location; right fibula has woven bone deposition on anterior and lateral surfaces, overlying interosseous crest, lighter in colour, distal 2/3 of shaft affected.</p>
Dental health	No surviving dentition
Comments	No maxilla, lower legs and feet are highly fragmented.

Skeleton Number	15 (Phase 1)
Preservation	0
Completeness	61-80%
Fragmentation	Moderate
Age	Young adult (18-25 years)
Sex	Female
Stature	n/d
Non-metric traits	Lateral tibial squatting facet (left).
Pathology	<p><u>Extra-spinal joint disease</u>: left ankle, left foot.</p> <p><u>Trauma</u>: possible healed fracture of distal shaft of right 5<sup>th</sup> metacarpal, slight swelling on lateral side, bone angulated in palmar direction.</p> <p><u>Non-specific infection</u>: woven bone deposition and striated lamellar bone on distal 2/3 of right and left tibia shaft, posterior surface adjacent to distal articulation is affected, deposits on lateral surface cover distal half of shaft while those on medial surface cover distal 2/3 of shaft; deposits also present on lateral, anterior and medial surfaces of left and right fibulae; changes always more severe on distal third of shaft; right and left 4<sup>th</sup> metatarsals have small areas of increased porosity and new bone deposition on dorsal surfaces.</p>
Dental health	No surviving dentition
Comments	No maxilla



Skeleton Number	16 (Phase 1)															
Preservation	0															
Completeness	81-100%															
Fragmentation	Medium															
Age	Older adult (45+ years)															
Sex	Male															
Stature	176.396 +/- 3.29															
Non-metric traits	Ossicle in lambdoid (bilateral), mastoid foramen extrasutural (left), Poirier's facet (right), double anterior calcaneal facet (left), double inferior talar facet (left)															
Pathology	<p><u>Spinal joint disease</u>: 6 cervical bodies (osteophytes and porosity)</p> <p><u>Spinal OA</u>: 4 cervical facets (eburnation, osteophytes and porosity)</p> <p><u>Extra-spinal joint disease</u>: right scapula, right distal humerus, right and left distal radius, left proximal and distal ulna, left lunate, left and right scaphoid, left acetabulum, left distal tibia, left and right 1<sup>st</sup> metacarpals (proximal and distal), left distal fibula, left and right calcaneus, right talus, left and right navicular, medial and lateral cuneiforms, right 2<sup>nd</sup> and 3<sup>rd</sup> metacarpals, right and left 1<sup>st</sup> metatarsals, left 1<sup>st</sup> proximal phalanx, left 1<sup>st</sup> distal phalanx.</p> <p><u>Extra-spinal OA</u>: left medial clavicle, 2<sup>nd</sup> and 3<sup>rd</sup> right metacarpals, 3<sup>rd</sup> right proximal hand phalanx, left and right proximal femur, left talus, left 1<sup>st</sup> metatarsal and 1<sup>st</sup> proximal phalanx</p> <p><u>Trauma</u>: healed fracture of right 5<sup>th</sup> metacarpal, thickening of shaft which is angulated in palmer direction, callus surviving. Bony exostoses on left distal tibia and fibula, ligament trauma.</p> <p><u>Lepromatous leprosy</u>: considerable resorption of maxillary alveolar process, more severe on left side; erosive lesions either side of the palatine process and new bone deposition, destruction of anterior nasal spine, concave facial profile likely, resorption and remodelling of nasal aperture, no changes to nasal floor, also post-mortem damage; <u>septic arthritis</u>: gross destruction of head of right 1<sup>st</sup> metatarsal, more severe on plantar surface; destruction of head of left 1<sup>st</sup> distal foot phalanx, partly obscured by post-mortem damage; fragment of unidentified possible foot phalanx exhibits gross destruction and remodelling.</p>															
Dental health	AMTL (15/19), calculus (1/4), caries (0/4), DEH (0/4), abscess (1/4), tooth positions (4/19). Externally draining abscess associated with mandibular left 2 <sup>nd</sup> molar, sharp-walled and semi-circular, max. diameter 9.44 mm.															
Right dentition								Left dentition								
Present	-	-	-	-	X	X	X	X	X	X	X	X	X	X	-	-
Calculus	-	-	-	-	-	-	-	-	-	-	-	-	-	-	-	-
DEH	-	-	-	-	-	-	-	-	-	-	-	-	-	-	-	-
Caries	-	-	-	-	-	-	-	-	-	-	-	-	-	-	-	-
Wear	-	-	-	-	-	-	-	-	-	-	-	-	-	-	-	-
Maxilla	8	7	6	5	4	3	2	1	1	2	3	4	5	6	7	8
Mandible	8	7	6	5	4	3	2	1	1	2	3	4	5	6	7	8
Present	-	-	-	-	P	P	-	P	P	-	-	X	X	X	X	X
Calculus	-	-	-	-	-	bm	-	-	-	-	-	-	-	-	-	-
DEH	-	-	-	-	-	-	-	-	-	-	-	-	-	-	-	-
Caries	-	-	-	-	-	-	-	-	-	-	-	-	-	-	-	-
Wear	-	-	-	-	6	5	-	5	5	-	-	-	-	-	-	-
Comments	Thoracic vertebrae are highly fragmented. No pathological changes to hands or lower legs.															

Skeleton Number	17 (Phase 1)															
Preservation	0															
Completeness	41-60%															
Fragmentation	Moderate															
Age	Older adult (45+ years)															
Sex	Male															
Stature	n/d															
Non-metric traits	Ossicle in lambdoid (left and right), ossicle in coronal (left and right).															
Pathology	<p><u>Spinal joint disease</u>: 6 cervical bodies, 5 thoracic bodies, 5 lumbar bodies (mild-severe osteophytes, porosity, Schmorl's nodes)</p> <p><u>Extra spinal joint disease</u>: right clavicle, left wrist, right acetabulum, left ankle (calcaneus), left hand (thumb).</p> <p><u>Extra-spinal OA</u>: left scapula, left acetabulum, left femur</p> <p><u>Non-specific infection</u>: highly fragmented left fibula shaft exhibits striated lamellar bone and woven bone deposition, location on shaft unclear; medial surface of left tibia shaft exhibits striated lamellar bone and woven bone deposition on distal 2/3 of shaft; left 4<sup>th</sup> metatarsal shaft has woven bone on dorsal surface, light in colour, proximal shaft, also some destruction on lateral side of proximal articulation, plantar surface, possible <u>septic arthritis</u>; articulating portion of left 4<sup>th</sup> metatarsal similarly affected; left proximal 2<sup>nd</sup> foot phalanx has small area of light coloured woven bone located on lateral surface close to distal articulation; left 2<sup>nd</sup> and 3<sup>rd</sup> metacarpals have woven bone deposition on dorsal shafts close to distal articulations. <u>Possible lepromatous leprosy</u>.</p> <p><u>Miscellaneous</u>: left ulna has 2 small bony exostoses located on lateral surface immediately below articulation for radius; left distal 3<sup>rd</sup> hand phalanx has small bony exostoses on lateral side of shaft, bone has unusually elongated appearance.</p>															
Dental health	Moderate mandibular periodontal disease, considerable maxillary periodontal disease. AMTL (4/26), calculus (4/22), caries (0/22), DEH (1/22), abscess (4/17), tooth positions (17/26). Maxillary wear slopes down markedly from buccal to lingual, most of crowns worn away; mandibular wear on right side slopes down from lingual to buccal though much less severely. Mandibular right 3 <sup>rd</sup> molar is chipped on distal side. Two internally draining abscesses: maxillary left 1 <sup>st</sup> premolar and maxillary left 1 <sup>st</sup> molar. Three externally draining abscesses: maxillary left 1 <sup>st</sup> premolar and maxillary left 1 <sup>st</sup> and 3 <sup>rd</sup> molars, maxillary right 2 <sup>nd</sup> molar, likely to represent 4 abscesses in total.															
Right dentition									Left dentition							
Present	-	-	P	-	P	-	P	-	-	-	P	P	P	P	P	AM
Calculus	-	-	-	-	-	-	-	-	-	-	-	-	-	-	-	-
DEH	-	-	-	-	-	-	-	-	-	-	-	-	-	-	-	-
Caries	-	-	-	-	-	-	-	-	-	-	-	-	-	-	-	-
Wear	-	-	8	-	8	-	7	-	-	-	5	5	7	7	7	6
Maxilla	8	7	6	5	4	3	2	1	1	2	3	4	5	6	7	8
Mandible	8	7	6	5	4	3	2	1	1	2	3	4	5	6	7	8
Present	P	P	P	P	P	P	P	P	AM	AM	P	P	P	P	P	P
Calculus	-	-	-	-	-	hb	sb	mbm	-	-	fb	-	-	-	-	-
DEH	-	-	-	-	-	-	-	-	-	-	l	-	-	-	-	-
Caries	-	-	-	-	-	-	-	-	-	-	-	-	-	-	-	-
Wear	7	7	7	6	5	5	5	5	-	-	5	5	7	7	7	6
Comments	No lower left leg, anterior maxilla does not survive.															

Skeleton Number	18 (Phase 1)															
Preservation	0															
Completeness	81-100%															
Fragmentation	Severe															
Age	Prime adult (26-35 years)															
Sex	Male															
Stature	n/d															
Non-metric traits	Ossicle in lambdoid (bilateral), ossicle in coronal (bilateral)															
Pathology	<p><u>Spinal joint disease</u>: 7 thoracic bodies, 2 lumbar bodies, 1 sacral body (mild-moderate osteophytes, porosity, Schmorl's nodes); new bone deposition on thoracic bodies, possible intervertebral disc disease.</p> <p><u>Extra-spinal joint disease</u>: right scapula, right toe.</p> <p><u>Extra-spinal OA</u>: medial clavicles</p> <p><u>Lepromatous leprosy</u>: rhino-maxillary syndrome, abnormal porosity on floor of nasal aperture and remodelling of nasal aperture, more severe on left side, right has suffered post-mortem damage, destruction of anterior nasal spine, marked destruction of alveolar bone in region of incisors and canines, more severe on left side, possible concave facial profile, insufficient survives to be certain; 3 patches of woven bone on right ulna, 2 on lateral side at proximal end, 1 on latero-anterior surface at distal end; right 1<sup>st</sup>, 3<sup>rd</sup>, 4<sup>th</sup> and 5<sup>th</sup> metacarpals have woven bone on palmar surfaces at proximal ends; right 2<sup>nd</sup> metacarpal has woven bone on dorsal and palmer surfaces at distal end, more severe on dorsal, light in colour; right 2<sup>nd</sup> proximal and intermediate hand phalanges have woven bone on palmar and dorsal surfaces; also dorsal surface of left 3<sup>rd</sup> metacarpal and dorsal surface of 2<sup>nd</sup> proximal hand phalanx; left and right tibiae shafts exhibit thick deposits of woven bone which is creamy white in colour, distal half, lateral side of anterior crest; left and right fibulae exhibit thick and florid deposits of woven bone, right fibula is mostly complete with conjoining fragments, missing proximal end, entire shaft is affected, deposits are located either side of interosseous crest, much more severe on distal half, deposits light in colour; left fibula is similarly affected, deposits on anterior surface are creamy-white in colour; shafts of right and left 1<sup>st</sup> and right 2<sup>nd</sup> metatarsals exhibit increased porosity and woven bone on dorsal surfaces, surviving portions of right 3<sup>rd</sup> and 4<sup>th</sup>, left 5<sup>th</sup> metatarsals have striated lamellar bone on plantar surfaces; right 5<sup>th</sup> metatarsal exhibits severe blade-like remodelling with marked woven bone deposition on lateral and medial sides of shaft, plantar and dorsal surfaces are less severely affected; right 1<sup>st</sup> distal foot phalanx is mostly destroyed; destruction of articulation is suggestive of <u>septic arthritis</u>; left 5<sup>th</sup> intermediate and distal foot phalanges are fused, possible <u>claw toe deformity</u>.</p> <p><u>Miscellaneous</u>: endocranial lesions on occipital bone; increased porosity and vascularity, new woven bone, grey in colour, extends over occipital sulcus to cruciform eminence and over right transverse sulcus but not left.</p>															
Dental health	Moderate periodontal disease, AMTL (1/31), calculus (15/30), caries (6/30), DEH (0/30), abscess (0/27), tooth positions (27/31). Mandibular 2 <sup>nd</sup> left molar is chipped on mesial side. Maxillary 2 <sup>nd</sup> right incisor has calculus below cemento-enamel junction indicating that root was exposed in life. Maxillary 3 <sup>rd</sup> molar roots exhibit cementosis.															
Right dentition									Left dentition							
Present	P	P	P	P	P	P	P	P	P	AM	P	P	P	P	P	P
Calculus	-	Mb	-	hb	hb	mbd	sa	-	-	-	-	-	-	-	-	-
DEH	-	-	-	-	-	-	-	-	-	-	-	-	-	-	-	-
Caries	lbdo	Mm	la	-	-	-	-	-	-	-	-	-	-	-	sm	-
Wear	-	4	-	6	5	3	4	4	4	-	2	5	6	6	5	1
Maxilla	8	7	6	5	4	3	2	1	1	2	3	4	5	6	7	8
Mandible	8	7	6	5	4	3	2	1	1	2	3	4	5	6	7	8
Present	CON	P	P	P	P	P	P	P	P	P	P	P	P	P	P	CON
Calculus	-	Sbdl	sl	sbl	sa	sl	sd	sbl	mbl	-	mb	sl	-	-	-	-
DEH	-	-	-	-	-	-	-	-	-	-	-	-	-	-	-	-
Caries	-	Ld	-	-	-	-	-	-	-	-	-	-	-	la	-	-
Wear	-	5	7	5	4	2	3	4	4	3	2	4	4	-	5	-
Comments	All surviving vertebrae are highly fragmented. Animal bone present. Radiocarbon dated. Sample 5, 1036-1208 cal AD (95.4% probability).															

Skeleton Number	21 (Phase 1)
Preservation	2
Completeness	0-20%
Fragmentation	Extreme
Age	Adult (18+ years)
Sex	?
Stature	n/d
Non-metric traits	None
Pathology	<p><u>Extra-spinal joint disease</u>: left auricular surface (mild marginal osteophytes), left 3<sup>rd</sup> intermediate phalanx, distal articulation (mild porosity).</p> <p><u>Non-specific infection</u>: left and right tibiae shafts have periosteal/woven new bone deposition, active, distal half, medial and lateral surfaces; distal 2/3 of left and right fibulae similarly affected, deposits are thicker on right fibula; right 5<sup>th</sup> metatarsal shaft has woven bone deposition on plantar and dorsal surfaces, proximal third; plantar surface of unidentified metatarsal shaft similarly affected; plantar and dorsal surfaces of probable left 5<sup>th</sup> metatarsal, bony exostosis on lateral side; woven bone on dorsal surfaces of left 2<sup>nd</sup> and 4<sup>th</sup> metatarsals; two unidentified foot phalanges exhibit destruction at distal ends, possible <u>septic arthritis</u>. <u>Possible lepromatous leprosy</u>.</p>
Dental health	No surviving dentition.
Comments	No maxilla. Preservation of hands and feet is extremely poor. Lower legs are highly fragmented. Radiocarbon dated. Sample 3, 1150-1300 cal AD (93.4% probability), 1050-1300 cal AD (95.4% probability).

Skeleton Number	23 (Phase 2)																
Preservation	0																
Completeness	81-100%																
Fragmentation	Moderate																
Age	Mature adult (36-45 years)																
Sex	Female																
Stature	n/d																
Non-metric traits	Ossicle in lambdoid (bilateral), ossicle in coronal (bilateral), bridging of supra-orbital notch (left), double inferior talar facet (left).																
Pathology	<p><u>Spinal joint disease</u>: 1 cervical facet, 10 thoracic bodies, 2 lumbar bodies (mild-moderate osteophytes, porosity and Schmorl's nodes).</p> <p><u>Extra-spinal joint disease</u>: left and right 1<sup>st</sup> ribs, sternal ends (small bony projections), left and right lateral clavicles, right distal radius, right proximal ulna, left capitate and trapezium, left and right distal tibiae, right cuboid, right 3<sup>rd</sup> metatarsal (mild-moderate osteophytes, porosity, lytic lesion).</p> <p><u>Maxillary sinusitis</u>: small globules of new bone in right maxillary sinus, left does not survive.</p> <p><u>Lepromatous leprosy</u>: rhino-maxillary syndrome, considerable destructive remodelling of anterior alveolar process, abnormal porosity of palate, abnormal porosity and new bone deposition on floor of nasal aperture, remodelling of walls of nasal aperture which are smooth, facial profile is concave; left tibia has striated lamellar bone on lateral and medial surfaces which extends from distal end to level of nutrient foramen, also seen on right tibia which is highly fragmented; left fibula shaft, lateral surface, distal 1/3, striated lamellar bone, small area of woven new bone at proximal limit of deposit, also seen on right fibula which is highly fragmented. Woven bone active at time of death, lamellar bone healed.</p> <p><u>Miscellaneous</u>: abnormal porosity of ectocranial surfaces of frontal and parietals.</p>																
Dental health	Moderate maxillary periodontal disease, considerable mandibular periodontal disease. AMTL (2/27), calculus (14/25), caries (2/25), DEH (1/25), abscess (0/25), tooth positions (25/27), enamel chipping (2/25).																
Right dentition									Left dentition								
Present	CON	P	P	P	P	P	P	AM	-	P	P	P	P	P	P	CON	
Calculus	-	Sdl	-	-	-	-	-	-	-	sb	-	-	-	sl	sbml	-	
DEH	-	-	-	-	-	-	-	-	-	-	-	-	-	-	-	-	
Caries	-CON	-	-	-	-	sl	sm	-	-	-	-	-	-	-	-	-	
Wear	-	2	5	3	6	4	3	-	-	3	4	6	6	8	4	-	
Maxilla	8	7	6	5	4	3	2	1	1	2	3	4	5	6	7	8	
Mandible	8	7	6	5	4	3	2	1	1	2	3	4	5	6	7	8	
Present	CON	P	AM	P	P	P	P	P	P	P	P	P	P	P	P	CON	
Calculus	-	-	-	sb	sb	hb	sbd	Hmmb	hb	hbsl	ml	sl	-	sb	-	-	
DEH	-	-	-	-	-	-	-	-	-	-	-	-	-	-	-	-	
Caries	-	-	-	-	-	-	-	-	-	-	-	-	-	-	-	-	
Wear	-	8	-	6	5	4	3	3	3	3	4	5	6	8	7	-	
Comments	Animal bone in grave fill																

Skeleton Number	24 (Phase 2)
Preservation	1
Completeness	21-40%
Fragmentation	Severe
Age	Adult (18+ years)
Sex	?
Stature	n/d
Non-metric traits	None
Pathology	<u>Extra-spinal OA</u> : left acetabulum (mild osteophytes and porosity).  <u>Non-specific infection</u> : left tibia has woven new bone on medial and lateral surfaces, affects distal 2/3 of shaft, light in colour; right tibia highly fragmented though appears similarly affected; right fibula shaft is very severely affected with deposits up to 10.76 mm on medial surface, less severe on lateral surface, distal 2/3 of shaft affected; left fibula highly fragmented though appears to be similarly affected, woven bone is active at time of death.
Dental health	No surviving dentition.
Comments	No maxilla or forearms. Some highly fragmented tarsal fragments not identified, no obvious pathology.

Skeleton Number	25 (Phase 1)															
Preservation	1															
Completeness	41-60%															
Fragmentation	Severe															
Age	Young adult (18-25 years)															
Sex	?															
Stature	n/d															
Non-metric traits	None															
Pathology	<u>Extra-spinal joint disease</u> : left capitate, right hamate, left lunate, left pisiform, left trapezium, right trapezoid, left triquetral.															
Dental health	AMTL (0/4), calculus (1/4), caries (0/4), DEH (0/4), abscess (0/0), tooth positions (0/4), enamel chipping (0/4).															
Right dentition									Left dentition							
Present	-	-	-	-	-	-	-	-	-	-	-	-	-	-	-	-
Calculus	-	-	-	-	-	-	-	-	-	-	-	-	-	-	-	-
DEH	-	-	-	-	-	-	-	-	-	-	-	-	-	-	-	-
Caries	-	-	-	-	-	-	-	-	-	-	-	-	-	-	-	-
Wear	-	-	-	-	-	-	-	-	-	-	-	-	-	-	-	-
Maxilla	8	7	6	5	4	3	2	1	1	2	3	4	5	6	7	8
Mandible	8	7	6	5	4	3	2	1	1	2	3	4	5	6	7	8
Present	-	P	P	-	-	-	-	-	-	-	-	-	-	P	P	-
Calculus	-	-	Sb	-	-	-	-	-	-	-	-	-	-	-	-	-
DEH	-	-	-	-	-	-	-	-	-	-	-	-	-	-	-	-
Caries	-	-	-	-	-	-	-	-	-	-	-	-	-	-	-	-
Wear	-	3	4	-	-	-	-	-	-	-	-	-	-	4	3	-
Comments	No maxilla, lower legs or feet															

Skeleton Number	26 (Phase 1)																
Preservation	1																
Completeness	0-20%																
Fragmentation	Severe																
Age	Adult (18+ years)																
Sex	?																
Stature	n/d																
Non-metric traits	Ossicle in lambdoid (bilateral).																
Pathology	<p><u>Extra-spinal joint disease</u>: left and right medial and lateral clavicle, right distal humerus and proximal radius.</p> <p><u>Extra-spinal OA</u>: left lateral clavicle.</p> <p><u>Miscellaneous</u>: slightly increased porosity on ectocranial surface of left and right parietals, located in posterior portion.</p>																
Dental health	AMTL (0/3), calculus (2/3), caries (0/3), DEH (0/3), abscess (0/0), tooth positions (0/3), enamel chipping (1/3). Crown of mandibular right 1 <sup>st</sup> molar is chipped on its lingual side.																
Right dentition									Left dentition								
Present	-	-	-	-	-	-	-	-	P	-	-	-	-	-	-	-	-
Calculus	-	-	-	-	-	-	-	-	FI	-	-	-	-	-	-	-	-
DEH	-	-	-	-	-	-	-	-	-	-	-	-	-	-	-	-	-
Caries	-	-	-	-	-	-	-	-	-	-	-	-	-	-	-	-	-
Wear	-	-	-	-	-	-	-	-	5	-	-	-	-	-	-	-	-
Maxilla	8	7	6	5	4	3	2	1	1	2	3	4	5	6	7	8	
Mandible	8	7	6	5	4	3	2	1	1	2	3	4	5	6	7	8	
Present	-	P	P	-	-	-	-	-	-	-	-	-	-	-	-	-	
Calculus	-	slb	-	-	-	-	-	-	-	-	-	-	-	-	-	-	
DEH	-	-	-	-	-	-	-	-	-	-	-	-	-	-	-	-	
Caries	-	-	-	-	-	-	-	-	-	-	-	-	-	-	-	-	
Wear	-	-	-	-	-	-	-	-	-	-	-	-	-	-	-	-	
Comments	No maxilla, hands, lower legs or feet																

Skeleton Number	28 (Phase 1)															
Preservation	1															
Completeness	0-20%															
Fragmentation	Severe															
Age	Adult (18+ years)															
Sex	?															
Stature	n/d															
Non-metric traits	None															
Pathology	<u>Extra-spinal joint disease</u> : right acetabulum, right proximal tibia, left distal fibula.															
Dental health	No surviving dentition.															
Comments	No maxilla, forearms, hands or feet.															

Skeleton Number	30 (Phase 1)															
Preservation	0															
Completeness	0-20%															
Fragmentation	Severe															
Age	Adult (18+ years)															
Sex	?															
Stature	n/d															
Non-metric traits	None															
Pathology	None															
Dental health	AMTL (0/1), calculus (1/1), caries (0/1), DEH (0/1), abscess (0/0), tooth positions (0/1).															
Right dentition								Left dentition								
Present	-	-	-	-	-	P	-	-	-	-	-	-	-	-	-	-
Calculus	-	-	-	-	-	fbmd	-	-	-	-	-	-	-	-	-	-
DEH	-	-	-	-	-	-	-	-	-	-	-	-	-	-	-	-
Caries	-	-	-	-	-	-	-	-	-	-	-	-	-	-	-	-
Wear	-	-	-	-	-	2	-	-	-	-	-	-	-	-	-	-
Maxilla	8	7	6	5	4	3	2	1	1	2	3	4	5	6	7	8
Mandible	8	7	6	5	4	3	2	1	1	2	3	4	5	6	7	8
Present	-	-	-	-	-	-	-	-	-	-	-	-	-	-	-	-
Calculus	-	-	-	-	-	-	-	-	-	-	-	-	-	-	-	-
DEH	-	-	-	-	-	-	-	-	-	-	-	-	-	-	-	-
Caries	-	-	-	-	-	-	-	-	-	-	-	-	-	-	-	-
Wear	-	-	-	-	-	-	-	-	-	-	-	-	-	-	-	-
Comments	No maxilla, hands, lower legs or feet															

Skeleton Number	31 (Phase 1)															
Preservation	0															
Completeness	41-60%															
Fragmentation	Severe															
Age	Adolescent (15-16 years)															
Sex	n/a															
Stature	n/a															
Non-metric traits	None															
Pathology	<p>?Congenital symphalagism: left intermediate 5<sup>th</sup> foot phalanx is fused to distal.</p> <p>Non-specific infection: left distal radius, anterior, lateral, posterior surfaces, woven and disorganised new bone deposit, grey in colour, active in appearance; left femur has small area of periostitis proximal to lesser trochanter, grey in colour, active in appearance; left tibia has striated lamellar bone on anterior surface of distal shaft; right tibia has small area of new bone deposition, lateral side of midshaft, active in appearance; left fibula, medial surface, localised area of woven bone deposition, active.</p>															
Dental health	No surviving dentition															
Comments	No maxilla															



Skeleton Number	32 (Phase 1)															
Preservation	1															
Completeness	81-100%															
Fragmentation	Severe															
Age	Mature adult (36-45 years)															
Sex	Male															
Stature	174.632 +/- 3.37															
Non-metric traits	Absent zygomatic foramen (left), double anterior calcaneal facet (bilateral), double inferior talar facet (left), os trigonum (right). TV1 has transverse foramen on left side.															
Pathology	<p><u>Spinal joint disease</u>: 1 cervical body and 1 facet, 7 thoracic bodies and 1 facet, 1 lumbar body, 2 sacral facets (mild-moderate osteophytes and porosity, moderate-severe Schmorl's nodes).</p> <p><u>Extra-spinal joint disease</u>: left clavicle, left scapula, left 1<sup>st</sup> rib, left humerus, radii and ulnae, left and right capitate, hamate, lunate, scaphoid, trapezium, triquetral, left pisiform, hands, left acetabulum, left proximal femur, patellae, tibiae, fibulae, calcanei, tali, cuboids, naviculars, all cuneiforms, toes (mild osteophytes).</p> <p><u>Extra-spinal OA</u>: right proximal femur, left cuboid</p> <p><u>Non-specific infection</u>: 1<sup>st</sup> metatarsal shafts have increased porosity and woven bone on plantar and dorsal surfaces; right 2<sup>nd</sup>-5<sup>th</sup> metatarsal shafts have woven bone, active; increased porosity on dorsal and plantar surfaces of right proximal foot phalanges 3, 4, 5, right intermediate 2 and 3, left proximal phalanges 1-5, ; some destruction of heads of right distal foot phalanx 1 and 2, left distal phalanx 3, possible <u>septic arthritis</u>; striated lamellar bone on anterior and medial surfaces of tibiae affecting distal 1/3, healed; no pathology observed on fibulae. <u>Possible lepromatous leprosy</u>.</p>															
Dental health	Slight-moderate periodontal disease. Periodontal pocket located between maxillary right 2 <sup>nd</sup> and 3 <sup>rd</sup> molar. AMTL (1/27), calculus (21/25), caries (1/25), DEH (0/25), abscess (0/22), tooth positions (22/27), enamel chipping (0/25).															
Right dentition								Left dentition								
Present	P	P	P	P	P	-	-	-	P	-	P	P	P	P	P	P
Calculus	sld	sb	mb	Sdl	mb	-	-	-	sbl	-	sb	fl	-	-	-	sd
DEH	-	-	-	-	-	-	-	-	-	-	-	-	-	-	-	-
Caries	-	-	DI	-	-	-	-	-	-	-	-	-	-	-	-	-
Wear	6	5	7	5	4	-	-	-	6	-	5	4	5	8	7	7
Maxilla	8	7	6	5	4	3	2	1	1	2	3	4	5	6	7	8
Mandible	8	7	6	5	4	3	2	1	1	2	3	4	5	6	7	8
Present	P	P	AM	P	P	P	P	P	-	PM	P	P	P	P	P	P
Calculus	mlsb	mb	-	mb	sl	mlf	mls	sb	-	-	sbh	-	sl	sl	sbl	sbl
DEH	-	-	-	-	-	-	-	-	-	-	-	-	-	-	-	-
Caries	-	-	-	-	-	-	-	-	-	-	-	-	-	-	-	-
Wear	5	5	-	4	4	4	5	5	-	-	4	3	3	6	5	5
Comments	Post-mortem damage to anterior maxilla. Vertebrae are highly fragmented. Animal bone in grave fill.															

Skeleton Number	33 (Phase 2)																
Preservation	1?																
Completeness	21-40%																
Fragmentation	Severe																
Age	Prime adult (26-35 years)																
Sex	?																
Stature	n/d																
Non-metric traits	Transverse foramen bipartite (right).																
Pathology	<p><u>Spinal joint disease</u>: 1 cervical body, 9 thoracic bodies (slight osteophytes and porosity, moderate Schmorl's nodes).</p> <p><u>Extra-spinal joint disease</u>: left and right medial clavicle, left and right manubrium.</p>																
Dental health	Slight to moderate mandibular periodontal disease. AMTL (1/18), calculus (3/17), DEH (0/17), abscess (0/12), tooth positions (12/18). Slight displacement of mandibular left 1 <sup>st</sup> premolar towards midline.																
Right dentition									Left dentition								
Present	P	P	P	-	-	-	-	-	-	-	-	P	-	-	-	-	
Calculus	fa	sd	sm	-	-	-	-	-	-	-	-	-	-	-	-	-	
DEH	-	-	-	-	-	-	-	-	-	-	-	-	-	-	-	-	
Caries	-	sm	-	-	-	-	-	-	-	-	-	lmo	-	-	-	-	
Wear	2	3	3	-	-	-	-	-	-	-	-	6	-	-	-	-	
Maxilla	8	7	6	5	4	3	2	1	1	2	3	4	5	6	7	8	
Mandible	8	7	6	5	4	3	2	1	1	2	3	4	5	6	7	8	
Present	P	-	P	P	P	P	P	P	P	P	P	P	AM	P	P	PM	
Calculus	fb	-	mlsd	sm	sb	mb	ml	hbmd	hbmd	sa	ma	ha	-	Hbld mo	Hbl mm	-	
DEH	-	-	-	-	-	-	-	-	-	-	-	-	-	-	-	-	
Caries	-	-	-	-	-	-	-	-	-	-	-	-	-	ld	-	-	
Wear	2	-	4	3	3	3	3	3	2	2	3	-	-	-	-	-	
Comments	No maxilla, hands, lower legs or feet. Radiocarbon dated. Sample 2, 1280-1430 cal AD (95.4% probability).																

Skeleton Number	34 (Phase 2)															
Preservation	1															
Completeness	81-100%															
Fragmentation	Severe															
Age	Adult (18+ years)															
Sex	Male?															
Stature	n/d															
Non-metric traits	Ossicle in lambdoid (bilateral), ossicle at asterion (left), sutural mastoid foramen (left).															
Pathology	<p><u>Spinal joint disease</u>: 3 cervical bodies and 1 facet (mild-moderate osteophytes, moderate-severe porosity).</p> <p><u>Extra-spinal joint disease</u>: right clavicle, right ulna, left hamate, right trapezium, hands and fingers, right tibia, calcanei, tali, cuboids, left navicular, feet and toes.</p> <p><u>Extra-spinal OA</u>: right and left hips.</p> <p><u>Non-specific infection</u>: striated lamellar bone on medial and lateral surfaces of tibiae, midshaft, less severe on right; striated lamellar bone and woven bone on distal 1/3 of left fibula; right is highly fragmented, no obvious pathology; woven bone on dorsal surfaces of right 2<sup>nd</sup>, 3<sup>rd</sup> and 5<sup>th</sup> metatarsals, proximal end; left 4<sup>th</sup> metatarsal, modification of medial side of articulation, exostosis present, left 3<sup>rd</sup> metatarsal is normal.</p>															
Dental health	Considerable mandibular periodontal disease. AMTL (4/12), calculus (3/7), caries (2/7), DEH (2/7), abscess (0/9), tooth positions (9/12), enamel chipping (1/7).															
Right dentition								Left dentition								
Present	P	-	-	P	-	P	-	-	-	-	-	-	-	-	-	-
Calculus	mld	-	-	Md	-	Sm	-	-	-	-	-	-	-	-	-	-
DEH	-	-	-	-	-	-	-	-	-	-	-	-	-	-	-	-
Caries	-	-	-	-	-	-	-	-	-	-	-	-	-	-	-	-
Wear	3	-	-	6	-	5	-	-	-	-	-	-	-	-	-	-
Maxilla	8	7	6	5	4	3	2	1	1	2	3	4	5	6	7	8
Mandible	8	7	6	5	4	3	2	1	1	2	3	4	5	6	7	8
Present	CON	AM	AM	-	-	-	-	-	-	P	PM	P	P	AM	P	AM
Calculus	-	-	-	-	-	-	-	-	-	-	-	-	-	-	-	-
DEH	-	-	-	-	-	-	-	-	-	-	-	-	-	-	-	-
Caries	-	-	-	-	-	-	-	-	-	ld	-	-	-	-	ld	-
Wear										5	-	6	6	-	6	-
Comments	No maxilla															

Skeleton Number	35 (Phase 1)															
Preservation	1															
Completeness	21-40%															
Fragmentation	Moderate															
Age	Adult (18+ years)															
Sex	?															
Stature	n/d															
Non-metric traits	None															
Pathology	<p><u>Extra-spinal joint disease</u>: right proximal ulna, right navicular, left medial cuneiform.</p> <p><u>Extra-spinal OA</u>: right proximal radius, right proximal femur</p> <p><u>Trauma</u>: well healed vertical fracture on medial side of right patella.</p> <p><u>Non-specific infection</u>: woven bone deposition on tibia, distal third, medial surfaces, deposits are not thick but have active appearance, right has more striated appearance; striated lamellar bone on right fibula, proximal third of shaft, woven bone deposition on distal 1/3, medial and anterior surfaces, striated lamellar bone on left fibula, medial surface, distal 1/3; right 1<sup>st</sup> metatarsal, woven bone deposition on dorsal, lateral and medial surfaces of shaft, full length affected; ?right proximal 1<sup>st</sup> foot phalanx, distal end much expanded with increased porosity on dorsal and plantar surfaces; left 1<sup>st</sup> proximal foot phalanx, destruction of head, woven bone deposition and abnormal porosity on dorsal surface, circular lytic defect on plantar surface at proximal end, destruction is suggestive of <u>septic arthritis</u>. <u>Possible lepromatous leprosy</u>.</p>															
Dental health	AMTL (0/6), calculus (5/6), caries (1/6), DEH (0/6), abscess (0/0), tooth positions (0/6).															
Right dentition										Left dentition						
Present	-	-	-	-	-	-	-	-	-	-	P	P	-	-	-	-
Calculus	-	-	-	-	-	-	-	-	-	-	sb	smdl	-	-	-	-
DEH	-	-	-	-	-	-	-	-	-	-	-	-	-	-	-	-
Caries	-	-	-	-	-	-	-	-	-	-	-	-	-	-	-	-
Wear	-	-	-	-	-	-	-	-	-	2	3	-	-	-	-	-
Maxilla	8	7	6	5	4	3	2	1	1	2	3	4	5	6	7	8
Mandible	8	7	6	5	4	3	2	1	1	2	3	4	5	6	7	8
Present	-	-	P	-	-	-	P	-	P	P	-	-	-	-	-	-
Calculus	--	-	-	-	-	-	smd	-	mbmd	ma	-	-	-	-	-	-
DEH	-	-	-	-	-	-	-	-	-	-	-	-	-	-	-	-
Caries	-	-	sm	-	-	-	-	-	-	-	-	-	-	-	-	-
Wear	-	-	5	-	-	-	3	-	3	3	-	-	-	-	-	-
Comments	No maxilla															

Skeleton Number	36 (Phase 2)
Preservation	1
Completeness	21-40%
Fragmentation	Severe
Age	Adult (18+ years)
Sex	?
Stature	n/d
Non-metric traits	None
Pathology	<u>Non-specific infection</u> : plantar surface of shaft of right 1 <sup>st</sup> metatarsal has periostitis and increased porosity; right and left 1 <sup>st</sup> proximal foot phalanges have new bone deposition on plantar and dorsal surfaces, active, increased porosity on dorsal surface, destruction of both distal articulations is underway, suggestive of <u>septic arthritis</u> ; left 1 <sup>st</sup> proximal foot phalanx has plaque of new bone on dorsal shaft at proximal end, increased porosity; shaft of probable left 5 <sup>th</sup> metatarsal exhibits blade-like remodelling. <u>Probable lepromatous leprosy</u> .
Dental health	No dentition
Comments	No maxilla

keleton Number	37 (Phase 2)															
Preservation	0															
Completeness	61-80%															
Fragmentation	Severe															
Age	Adult (18+ years)															
Sex	Male															
Stature	n/d															
Non-metric traits	None															
Pathology	<p><u>Spinal joint disease</u>: 3 thoracic facets, 5 lumbar bodies, 1 sacral body, 2 sacral facets (mild-moderate osteophytes, porosity, Schmorl's nodes)</p> <p><u>Extra-spinal joint disease</u>: right and left radii, left femur, right 1<sup>st</sup> metatarsal.</p> <p><u>Extra-spinal OA</u>: left capitate, right and left acetabulum, right femur, left navicular, left talus.</p> <p><u>Non-specific infection</u>: striated lamellar bone on medial surfaces of tibiae and fibulae, confined to distal third;</p> <p><u>Trauma</u>: possible healed fracture of left tibia, well healed, good apposition of ends.</p>															
Dental health	2 loose teeth. AMTL (0/2), calculus (1/2), caries (1/2), DEH (0/2), abscess (0/5), tooth positions (5/7).															
Right dentition									Left dentition							
Present	-	-	-	-	-	-	-	-	-	-	-	-	-	-	-	-
DEH	-	-	-	-	-	-	-	-	-	-	-	-	-	-	-	-
Caries	-	-	-	-	-	-	-	-	-	-	-	-	-	-	-	-
Wear	-	-	-	-	-	-	-	-	-	-	-	-	-	-	-	-
Maxilla	8	7	6	5	4	3	2	1	1	2	3	4	5	6	7	8
Mandible	8	7	6	5	4	3	2	1	1	2	3	4	5	6	7	8
Present	-	-	-	-	-	P	PM	PM	PM	PM	PM	-	-	-	-	P
Calculus	-	-	-	-	-	Mm	-	-	-	-	-	-	-	-	-	-
DEH	-	-	-	-	-	-	-	-	-	-	-	-	-	-	-	-
Caries	-	-	-	-	-	-	-	-	-	-	-	-	-	-	-	la
Wear	-	-	-	-	-	4	-	-	-	-	-	-	-	-	-	-
Comments	No maxilla. Animal bone present. Radiocarbon dated. Sample 1, 1380-1530 cal AD (89% probability), 1310-1530 cal AD (95.4% probability).															

Skeleton Number	38 (Phase 1)
Preservation	1
Completeness	0-20%
Fragmentation	Moderate
Age	Adult (18+ years)
Sex	?
Stature	n/d
Non-metric traits	Os trigonum (left). Left 1 <sup>st</sup> metatarsal has marked circular facet on lateral side at proximal end.
Pathology	<u>Extra-spinal joint disease</u> : tali, left lateral cuneiform, feet and toes.  <u>Non-specific infection</u> : destruction of distal articulation of left 2 <sup>nd</sup> distal foot phalanx, possible <u>septic arthritis</u> ; surviving metatarsal shafts have increased porosity on dorsal shafts, left 5 <sup>th</sup> metatarsal also has increased porosity on plantar shaft; new bone deposition on anterior and lateral distal half of shaft of left tibia, distal third, posterior surface; new bone deposition on distal two thirds of left fibula shaft is thicker and more severe, anterior, medial and posterior surfaces, deposits become more diffuse on proximal shaft; right tibia and fibula are less severely affected, all deposits active. <u>Possible lepromatous leprosy</u> .
Dental health	No surviving dentition.
Comments	No maxilla, forearms, or hands

Skeleton Number	39 (unphased)
Preservation	1
Completeness	0-20%
Fragmentation	Severe
Age	Adult (18+ years)
Sex	?
Stature	n/d
Non-metric traits	Transverse foramen bipartite (left).
Pathology	<u>Spinal joint disease</u> : mild osteophytes (1 cervical body).  <u>Extra-spinal joint disease</u> : left glenoid (mild porosity).
Dental health	No surviving dentition.
Intrusive bone	Left lateral clavicle (adult). There are two left clavicles, one of which has unfused medial epiphyses. It is not clear which one is associated.
Comments	Described as charnel in backfill of grave. Appears to be one Skeleton.

Skeleton Number	40 (Phase 2)
Preservation	0
Completeness	41-60%
Fragmentation	Moderate
Age	Adult (18+ years)
Sex	?
Stature	n/d
Non-metric traits	None
Pathology	<p><u>Spinal joint disease</u>: 2 thoracic bodies, 1 thoracic facet, 2 lumbar bodies, 1 lumbar facet (mild osteophytes).</p> <p><u>Extra-spinal joint disease</u>: left hamate and scaphoid, left hand and fingers, left patella and tibia, left foot, left and right toes, small exostosis on calcaneal facet of left cuboid.</p> <p><u>Non-specific infection</u>: tibiae, medial and lateral surfaces of shafts, striated lamellar bone affecting distal 2/3, also woven new bone, active; fibulae, grey woven new bone, active, distal 2/3 of left, medial and anterior surfaces, distal half of right, all surfaces, more severe than left.</p>
Dental health	No surviving dentition.
Comments	No maxilla



Skeleton Number	42 (Phase 1)															
Preservation	1															
Completeness	81-100%															
Fragmentation	Slight															
Age	Mature adult (36-45 years)															
Sex	Female															
Stature	n/d															
Non-metric traits	Ossicle in lambdoid (bilateral), ossicle in coronal (bilateral), posterior atlas bridging (left).															
Pathology	<p><u>Spinal joint disease</u>: 3 cervical bodies, 2 cervical facets, 10 thoracic bodies, 2 thoracic facets, 2 lumbar bodies, 1 sacral facet (mild-severe osteophytes, mild-moderate porosity).</p> <p><u>Extra-spinal joint disease</u>: humeri, right radius, ulnae, acetabuli, right medial cuneiform, left distal foot phalanx.</p> <p><u>Extra-spinal OA</u>: femora.</p> <p><u>Trauma</u>: bony exostosis on anterior surface of left proximal fibula (ligament trauma), 12.72 x 5.22 x 4.59 mm, tip has broken off; compression fractures of TV10-11 resulting in a moderate degree of kyphosis, both bodies exhibit anterior wedging, TV11 more severely affected, thickness of body of TV10 measures 14.39 mm, thickness of TV11 measures 13.82 mm, normal body thickness is c 17 mm. X-ray would be required to confirm the presence of a fracture and discount age related change.</p> <p><u>?Lepromatous leprosy</u>: possible rhino-maxillary changes, left side of nasal aperture is smoother than right which remains sharp, anterior maxillary sockets are normal, post-mortem damage.</p> <p><u>Non-specific infection</u>: tibiae have diffuse deposits of grey woven bone, active, all surfaces, extends at least over distal 2/3, left has patch of thicker woven new bone on medial surface at midpoint, possible chronic ulcer; fibulae have grey woven bone deposition, lateral surface, diffuse spread almost to proximal end; right 3<sup>rd</sup> intermediate foot phalanx has abnormal porosity on plantar surface.</p> <p><u>Miscellaneous</u>: areas of abnormal porosity and irregular new bone deposition on left and right supra-orbital ridges immediately above orbits, extends across glabella, ectocranial surface, left and right zygomatics are also affected.</p>															
Dental health	Moderate mandibular and considerable maxillary periodontal disease. AMTL (1/28), calculus (24/27), caries (5/27), DEH (5/27), abscess (3/17), tooth positions (17/27), enamel chipping (2/27). Crown of mandibular left 1 <sup>st</sup> molar completely destroyed by decay, over-eruption of roots, externally draining abscess, 2 smooth-walled perforations exposing roots, abnormal porosity of alveolar bone, diameters 2.83 and 3.42 mm. Externally draining abscess associated with maxillary left 2 <sup>nd</sup> molar, smooth-walled. Externally draining abscess associated with maxillary left 3 <sup>rd</sup> molar, semi-circular and smooth-walled, abnormal porosity of alveolar bone, max. diameter 7.54 mm.															
Right dentition									Left dentition							
Present	-	-	AM	P	P	P	P	P	P	P	P	P	P	P	P	P
Calculus	-	-	-	sb	sb	sb	sb	sb	sb	sb	md	sb	mb	sb	-	-
DEH	-	-	-	-	-	-	-	-	-	-	-	-	-	-	-	-
Caries	-	-	-	ld	-	-	-	-	-	-	-	-	-	-	ld	md
Wear	-	-	-	4	5	4	4	4	4	4	3	5	4	8	6	4
Maxilla	8	7	6	5	4	3	2	1	1	2	3	4	5	6	7	8
Mandible	8	7	6	5	4	3	2	1	1	2	3	4	5	6	7	8
Present	P	P	P	-	P	P	P	P	P	P	-	P	P	P	P	P
Calculus	sib md	sb md	Fd	-	sm db	sl	mlsb	sb md	sml	sbmd	-	smd	sl	-	sbl	Sd
DEH	-	-	-	-	-	4L	1L	-	2L	1L	-	1L	-	-	-	-
Caries	-	-	Lom	-	-	-	-	-	-	-	-	-	-	la	-	-
Wear	4	5	7	-	4	3	3	3	3	3	-	3	4	-	7	5
Comments	Vertebrae are highly fragmented.															

Skeleton Number	43 (Phase 1)
Preservation	1
Completeness	61-80%
Fragmentation	Severe
Age	Adult (18+ years)
Sex	?
Stature	n/d
Non-metric traits	Double anterior calcaneal facet (left), double inferior talar facet (bilateral).
Pathology	<p><u>Extra-spinal joint disease</u>: left ulna, left capitate, right scaphoid, left fingers, right patella, left tibia, right fibula, calcanei, right talus, right cuboid, left foot and toes.</p> <p><u>Extra-spinal OA</u>: proximal femora</p> <p>Enthesal change: marked new bone deposition running length of left and right linea aspera; tibiae and fibula have new bone deposition at sites of tendon and ligament insertions.</p> <p>?<u>Tarsal bar</u>: Right cuboid has bony exostosis on dorsal surface, lateral side, adjacent to calcaneal facet, no surviving navicular, other tarsals unaffected.</p> <p><u>Non-specific infection</u>: tibiae have woven bone, medial, anterior and lateral surfaces, most severe on lateral, creamy-white in colour, distal 2/3 of shaft affected; fibulae have woven bone on lateral and medial surfaces, distal 2/3; gross destruction of right 1<sup>st</sup>, 2<sup>nd</sup> and 3<sup>rd</sup> metatarsals, only proximal articulation and small part of shaft survive, abnormal porosity and woven bone deposition on plantar surfaces (see Ortner 2008, fig. 14.12, pencilling, concentric diaphyseal remodelling) of shafts of 2<sup>nd</sup> and 3rd; surviving shaft of left 1<sup>st</sup> metatarsal has abnormal porosity and exostosis on plantar surface; left 2<sup>nd</sup>, 4<sup>th</sup> and 5<sup>th</sup> metatarsals have woven bone on dorsal and plantar surfaces, commencement of blade-like remodelling; 2 x left proximal foot phalanges have pencilling of shafts (sucked candy appearance), destruction of distal articulations, possible <u>septic arthritis</u>, ?cupping of proximal articulations, changes suggest transverse arch collapse; proliferation of new bone and abnormal porosity on posterior surface of left calcaneus. <u>Probable lepromatous leprosy</u>.</p> <p>Left femur has possible small ossified haematoma on medial side just above midshaft, evidenced by swelling.</p>
Dental health	No surviving dentition.
Comments	Vertebrae are highly fragmented. No surviving maxilla.

Skeleton Number	44 (Phase 2)															
Preservation	1															
Completeness	61-80%															
Fragmentation	Moderate															
Age	Young adult (18-25 years)															
Sex	Female?															
Stature	n/d															
Non-metric traits	None															
Pathology	<p><u>Extra-spinal joint disease</u>: right distal radius, left distal tibia.</p> <p><u>Extra-spinal OA</u>: left proximal ulna.</p> <p><u>Trauma</u>: possible dislocation of left proximal ulna, radial notch has been completely remodelled, post-mortem loss of coronoid process, new bone deposition on lateral side of trochlear notch, proximal edge of olecranon has post-mortem damage, entire olecranon much reduced in thickness, sub-chondral pitting in trochlear notch, differential diagnosis olecranon fracture, possible septic arthritis.</p> <p><u>Non-specific infection</u>: striated lamellar bone on left tibia, lateral surface, distal 2/3, more severe on distal 1/3, 2 small patches of disorganised woven bone on lateral surface, third patch immediately below lateral epicondyle is lighter in colour; right tibia is highly fragmented, multiple diffuse patches of woven bone, anterior, medial, lateral, most severe in distal 1/3, extends at least as far as nutrient foramen, grey in colour, at least 2 mm thick in some areas; right fibula has diffuse patches of woven bone deposition affecting distal 2/3 of shaft, anterior and medial surfaces, grey colour, at least 2.5 mm thick at ?distal end; right 2<sup>nd</sup> metatarsal has deposit of woven new bone on dorsal shaft, grey, up to 5 mm thick, covers proximal 1/3 of shaft, 2 much smaller deposits on plantar surface at midshaft; less severe on dorsal surface of right 3<sup>rd</sup> metatarsal; dorsal surface of right proximal 2<sup>nd</sup> and 3<sup>rd</sup> foot phalanges affected; left 3<sup>rd</sup> proximal foot phalanx has abnormal porosity on dorsal surface, deposits are active.</p>															
Dental health	AMTL (0/26), calculus (20/26), caries (4/26), DEH (0/26), abscess (0/2), tooth positions (2/26), enamel chipping (2/26).															
Right dentition									Left dentition							
Present	-	P	P	P	P	P	-	P	P	-	P	P	P	P	P	-
Calculus	-	-	-	sl	Fd	sl	-	sd	sd	-	smb	mbl	sd	sm	-	-
DEH	-	-	-	-	-	-	-	-	-	-	-	-	-	-	-	-
Caries	-	-	lm	-	-	-	-	-	-	-	-	sb	-	-	-	-
Wear	-	5	6	4	3	3	-	3	3	-	3	4	3	6	4	-
Maxilla	8	7	6	5	4	3	2	1	1	2	3	4	5	6	7	8
Mandible	8	7	6	5	4	3	2	1	1	2	3	4	5	6	7	8
Present	-	P	P	P	P	P	P	P	P	P	P	P	P	P	P	-
Calculus	-	-	fmd	-	Sb	sb	mbm	mbml	mb	mbd	sb	sb	sb	-	fm	-
DEH	-	-	-	-	-	-	-	-	-	-	-	-	-	-	-	-
Caries	-	-	-	ds	-	-	-	-	-	-	-	-	-	loml	-	-
Wear	-	5	6	4	4	5	3	3	3	2	3	4	4	-	5	-
Comments	No maxilla															

Skeleton Number	45 (Phase 1)															
Preservation	0															
Completeness	81-100%															
Fragmentation	Moderate															
Age	Prime adult (26-35 years)															
Sex	Female															
Stature	n/d															
Non-metric traits	Ossicle in lambdoid (right and left), ossicle in coronal (bilateral), mastoid foramen extra-sutural (right), double condylar facet (left), mandibular torus (left), double atlas facet (right)															
Pathology	<p><u>Spinal joint disease</u>: 2 cervical, 5 lumbar (osteophytes, Schmorl's nodes)</p> <p><u>Extra-spinal OA</u>: left medial clavicle, right proximal femur (mild osteophytes and porosity).</p> <p><u>Lepromatous leprosy</u>: rhino-maxillary changes, resorption of anterior maxillary sockets, abnormal palatal porosity, new bone deposition and abnormal porosity on left and right nasal floor, remodelling of anterior nasal spine, surviving portion of nasal aperture (left and right) smooth and remodelled, concave facial profile.</p> <p><u>Non-specific infection</u>: healed periostitis on lateral side of distal third of right ulna shaft and medial side of shaft of right radius; active periostitis on distal two thirds of shaft of right and left fibula, anterior and lateral surfaces; more diffuse and less severe on right and left tibia, distal 2/3 of right tibia, left too fragmented to determine location.</p>															
Dental health	Moderate mandibular periodontal disease. AMTL (0/21), calculus (8/19), caries (3/19), DEH (0/19), abscess (0/17), tooth positions (17/19), enamel chipping (6/19)															
Right dentition									Left dentition							
Present	P	-	-	-	P	-	P	P	P	P	-	-	-	-	-	-
Calculus	-	-	-	-	-	-	mbsd	-	fb	-	-	-	-	-	-	-
DEH	-	-	-	-	-	-	-	-	-	-	-	-	-	-	-	-
Caries	-	-	-	-	-	-	-	-	-	-	-	-	-	-	-	-
Wear	8	-	-	-	5	-	4	3	3	3	-	-	-	-	-	-
Maxilla	8	7	6	5	4	3	2	1	1	2	3	4	5	6	7	8
Mandible	8	7	6	5	4	3	2	1	1	2	3	4	5	6	7	8
Present	P	P	P	P	P	P	PM	PM	-	-	P	P	-	P	P	P
Calculus	sbd	sbd	hb	Mb	sbml	slo	-	-	-	-	sblm	slo	-	slo	slo	slo
DEH	-	-	-	-	-	-	-	-	-	-	-	-	-	-	-	-
Caries	-	la	-	-	-	-	-	-	-	-	-	-	-	-	ld	la
Wear	4	5	4	4	4	4	-	-	-	-	0	4	-	7	4	-
Intrusive bone	Right maxilla, adult, rhino-maxillary changes.															
Comments																

Skeleton Number	46 (Phase 1)															
Preservation	1															
Completeness	0-20%															
Fragmentation	Moderate															
Age	Adult (18+ years)															
Sex	?															
Stature	n/d															
Non-metric traits	None															
Pathology	None															
Dental health	AMTL (0/4), calculus (2/4), DEH (0/4), abscess (0/0), tooth positions (0/4).															
Right dentition								Left dentition								
Present	-	-	-	-	-	-	-	-	-	-	-	-	-	-	-	-
Calculus	-	-	-	-	-	-	-	-	-	-	-	-	-	-	-	-
DEH	-	-	-	-	-	-	-	-	-	-	-	-	-	-	-	-
Caries	-	-	-	-	-	-	-	-	-	-	-	-	-	-	-	-
Wear	-	-	-	-	-	-	-	-	-	-	-	-	-	-	-	-
Maxilla	8	7	6	5	4	3	2	1	1	2	3	4	5	6	7	8
Mandible	8	7	6	5	4	3	2	1	1	2	3	4	5	6	7	8
Present	-	-	-	P	P	P	-	-	-	-	-	P	-	-	-	-
Calculus	-	-	-	-	sb	-	-	-	-	-	-	sb	-	-	-	-
DEH	-	-	-	-	-	-	-	-	-	-	-	-	-	-	-	-
Caries	-	-	-	-	-	-	-	-	-	-	-	-	-	-	-	-
Wear	-	-	-	6	7	5	-	-	-	-	-	7	-	-	-	-
Comments	No maxilla, forearms, hands, lower legs or feet															

Skeleton Number	47 (Phase 2)
Preservation	1
Completeness	41-60%
Fragmentation	Moderate
Age	Adult (18+ years)
Sex	?
Stature	n/d
Non-metric traits	Double anterior calcaneal facet (bilateral).
Pathology	<p><u>Spinal joint disease</u>: 2 thoracic bodies (mild porosity, moderate osteophytes, severe Schmorl's nodes)</p> <p><u>Extra-spinal OA</u>: right lateral clavicle (mild marginal osteophytes and porosity)</p> <p><u>Trauma</u>: left ?3<sup>rd</sup> rib has a healed fracture located at the angle of the bone, good apposition of ends, callus surviving; left ?8<sup>th</sup> rib has healed neck fracture, bone is slightly misshapen with callus surviving; right 3<sup>rd</sup> rib has healed fracture at neck of bone, poor apposition of, ends, anterior portion of rib is displaced in distal direction, callus surviving; bony exostosis located on posterior surface of proximal third of shaft of left fibula.</p> <p><u>Non-specific infection</u>: two areas of woven bone deposition on left tibia, located on anterior/medial surface of distal shaft; woven bone deposition and striated lamellar bone, lateral surface of right tibia at midshaft.</p>
Dental health	No surviving dentition
Comments	No maxilla. Vertebrae are highly fragmented.

Skeleton Number	48 (Phase 1)
Preservation	2
Completeness	21-40%
Fragmentation	Severe
Age	Adult (18+ years)
Sex	?
Stature	n/d
Non-metric traits	None
Pathology	<p><u>Spinal joint disease</u>: 1 cervical facet (mild osteophytes).</p> <p><u>Extra-spinal joint disease</u>: right scapula, left and right proximal radius, left distal radius, left proximal ulna, left trapezoid. Left lateral cuneiform, left 1<sup>st</sup> distal phalanx.</p> <p><u>Extra-spinal OA</u>: left scapula, right proximal ulna</p> <p><u>Trauma</u>: probable healed fracture of left 5<sup>th</sup> metacarpal, bone is angulated in palmar direction.</p> <p><u>Non-specific infection</u>: striated lamellar bone and woven bone on ?medial and lateral surfaces of highly fragmented left tibia and fibula; small patch of woven bone on plantar surface of probable left 2<sup>nd</sup> metatarsal, distal end, active.</p>
Dental health	No surviving dentition.
Comments	No surviving maxilla.

Skeleton Number	49 (Phase 1)
Preservation	2
Completeness	0-20%
Fragmentation	Moderate
Age	Adult (18+ years)
Sex	?
Stature	n/d
Non-metric traits	Double inferior talar facet (right).
Pathology	<u>Extra-spinal joint disease</u> : right talus, navicular, medial cuneiform and toes (mild osteophytes).
Dental health	No surviving dentition.
Comments	No maxilla, forearms or hands

Skeleton Number	50 (Phase 1)
Preservation	3
Completeness	0-20%
Fragmentation	Moderate
Age	Adult (18+ years)
Sex	?
Stature	n/d
Non-metric traits	None
Pathology	<u>Non-specific infection</u> : striated lamellar bone lateral surfaces of left and right tibia, distal half, healed.
Dental health	No surviving dentition.
Comments	No surviving maxilla.

Skeleton Number	51 (Phase 1)																
Preservation	0																
Completeness	61-80%																
Fragmentation	Moderate																
Age	Young adult (18-20 years)																
Sex	Male																
Stature	n/d																
Non-metric traits	Allen's fossa (right and left)																
Pathology	<p><u>Lepromatous leprosy</u>: rhino-maxillary changes, abnormal porosity of palate, destruction of the nasal aperture, post-mortem damage.</p> <p><u>Maxillary sinusitis</u>: new bone deposition in left and right maxillary sinuses (notes from previous record, maxilla could not be located); tibiae and fibulae have striated lamellar bone on anterior, medial and lateral surfaces, running length of shaft; left fibula has possible chronic ulcer on distal third of shaft, anterior surface, slight swelling associated with thicker and slightly more disorganised deposit of lamellar bone.</p> <p><u>Trauma</u>: small bony exostosis on lateral third of shaft of right clavicle, distal surface, ligament trauma.</p>																
Dental health	Moderate maxillary periodontal disease. AMTL (0/12), calculus (6/6), caries (0/6), DEH (0/6), abscess (0/12), tooth positions (12/12). AMTL (4/28), calculus (10/13), caries (0/13), DEH (0/13), abscess (0/27), tooth positions (27/32).																
Right dentition									Left dentition								
Present	P	PM	P	P	P	P	AM	AM	AM	AM	PM	PM	PM	P	P	PM	
Calculus	-	-	sblmd	sbl	sbl	sbl	-	-	-	-	-	-	-	-	sblmd	sblmd	-
DEH	-	-	-	-	-	-	-	-	-	-	-	-	-	-	-	-	-
Caries	-	-	-	-	-	-	-	-	-	-	-	-	-	-	-	-	-
Wear	-	-	2	2	2	3	-	-	-	-	-	-	-	-	-	-	-
Maxilla	8	7	6	5	4	3	2	1	1	2	3	4	5	6	7	8	
Mandible	8	7	6	5	4	3	2	1	1	2	3	4	5	6	7	8	
Present	PM	P	P	P	PM	PM	-	-	-	-	PM	PM	P	P	P	PM	
Calculus	-	dbs lh	bs lh	As	-	-	-	-	-	-	-	-	ms	bds	mdls	-	
DEH	-	-	-	-	-	-	-	-	-	-	-	-	-	-	-	-	
Caries	-	-	-	-	-	-	-	-	-	-	-	-	-	-	-	-	
Wear	-	2	4	2	-	-	-	-	-	-	-	-	2	4	3	-	
Intrusive bone	Incomplete left orbit, adult, no cribra orbitalia																
Comments																	



Skeleton Number	52 (Phase 1)
Preservation	1
Completeness	0-20%
Fragmentation	Severe
Age	Adult (18+ years)
Sex	?
Stature	n/d
Non-metric traits	None
Pathology	<u>Non-specific infection</u> : tibiae, remodelling woven bone and striated lamellar bone, ?medial surface; right fibula, distal 2/3, remodelling woven bone and striated lamellar bone, medial and lateral; same on left fibula though less surviving. Both active and healed lesions.
Dental health	No surviving dentition
Comments	No maxilla, forearms or hands

Skeleton Number	54 (Phase 2)															
Preservation	2															
Completeness	21-40%															
Fragmentation	Extreme															
Age	Adult (18+ years)															
Sex	?															
Stature	n/d															
Non-metric traits	None.															
Pathology	<u>Spinal joint disease</u> : 2 cervical facets (mild osteophytes). <u>Extra-spinal joint disease</u> : right ulna (mild osteophytes). <u>Spinal OA</u> : 3 cervical facets (mild-moderate eburnation).															
Dental health	AMTL (1/3), calculus (0/1), caries (0/1), DEH (0/1), abscess (0/2), enamel chipping (0/1), tooth positions (2/3).															
Right dentition								Left dentition								
Present	-	P	-	-	-	-	-	-	-	-	-	-	-	-	-	-
Calculus	-	-	-	-	-	-	-	-	-	-	-	-	-	-	-	-
DEH	-	-	-	-	-	-	-	-	-	-	-	-	-	-	-	-
Caries	-	-	-	-	-	-	-	-	-	-	-	-	-	-	-	-
Wear	-	7	-	-	-	-	-	-	-	-	-	-	-	-	-	-
Maxilla	8	7	6	5	4	3	2	1	1	2	3	4	5	6	7	8
Mandible	8	7	6	5	4	3	2	1	1	2	3	4	5	6	7	8
Present	-	-	-	-	-	-	-	-	-	-	-	-	-	-	AM	P
Calculus	-	-	-	-	-	-	-	-	-	-	-	-	-	-	-	-
DEH	-	-	-	-	-	-	-	-	-	-	-	-	-	-	-	-
Caries	-	-	-	-	-	-	-	-	-	-	-	-	-	-	-	-
Wear	-	-	-	-	-	-	-	-	-	-	-	-	-	-	-	-
Comments	No maxilla or hands															

Skeleton Number	55 (Phase 1)															
Preservation	1															
Completeness	41-60%															
Fragmentation	Severe															
Age	Adult (18+ years)?															
Sex	Indeterminate															
Stature	n/d															
Non-metric traits	None															
Pathology	<p><u>Spinal joint disease</u>: 1 cervical body, 4 cervical facets (mild osteophytes).</p> <p><u>Extra-spinal joint disease</u>: manubrium, left scapula, right and left ulna.</p> <p><u>Extra-spinal OA</u>: right medial clavicle.</p> <p><u>Lepromatous leprosy</u>: rhino-maxillary changes, poor preservation, abnormal porosity of nasal floor (left and right), resorption of anterior sockets, remodelling of nasal aperture.</p>															
Dental health	Considerable maxillary and mandibular periodontal disease. AMTL (1/31), calculus (21/28), caries (9/28), DEH (0/28), abscess (0/18), enamel chipping (1/28), tooth positions (18/31).															
Right dentition									Left dentition							
Present	P	P	P	P	P	P	P	-	PM	P	PM	P	P	AM	P	P
Calculus	-	-	-	-	-	sb	-	-	-	sd	-	sd	sd	-	mm	-
DEH	-	-	-	-	-	-	-	-	-	-	-	-	-	-	-	-
Caries	la	md	mm	Md	-	-	hlm	-	-	-	-	-	mm	-	ld	Lm
Wear	-	4	5	4	5	3	3	-	3	3	3	3	3	6	5	4
Maxilla	8	7	6	5	4	3	2	1	1	2	3	4	5	6	7	8
Mandible	8	7	6	5	4	3	2	1	1	2	3	4	5	6	7	8
Present	P	P	P	P	P	P	P	P	P	P	P	P	P	P	P	P
Calculus	sdl	sb	sbl	Sl	sl	hbl	slbdm	hbl	hbl	mbl	sb	mbl	mbl	slid	ml	mbd
DEH	-	-	-	-	-	-	-	-	-	-	-	-	-	-	-	-
Caries	md	-	-	-	-	-	-	-	-	-	-	-	-	-	-	-
Wear	3	5	6	5	4	3	3	3	3	3	3	3	3	6	5	4
Comments	Very little of hands, lower legs and feet surviving.															

Skeleton Number	56 (Phase 2)															
Preservation	0															
Completeness	41-60%															
Fragmentation	Severe															
Age	Adult (18+ years)															
Sex	Female															
Stature	n/d															
Non-metric traits	Ossicle in lambdoid (right and left), ossicle in coronal (right and left), absent zygomatico-facial foramen (right and left).															
Pathology	<p><u>Spinal joint disease</u>: 4 cervical bodies (mild to moderate osteophytes and porosity), 1 sacral body (mild to moderate osteophytes and porosity).</p> <p><u>Spinal OA</u>: mild eburnation on anterior surface of odontoid peg.</p> <p><u>Extra-spinal joint disease</u>: left and right proximal femora.</p> <p><u>Metabolic</u>: healed cribra orbitalia, type I, left side only, right does not survive.</p> <p><u>Non-specific infection</u>: tibiae have striated lamellar bone on all surfaces of shafts, slightly more severe on lateral surfaces, cannot determine extent of shaft affected. Fibulae are similarly affected, slightly more severe on anterior surfaces.</p>															
Dental health	Considerable periodontal disease. AMTL (5/10), calculus (3/5), caries (1/5), DEH (1/5), abscess (0/6), tooth positions (6/10). Mandibular right 2 <sup>nd</sup> molar has large carious cavity which has destroyed most of crown and exposed pulp cavity.															
Right dentition								Left dentition								
Present	-	-	-	-	-	-	-	-	-	-	-	-	-	-	-	-
Calculus	-	-	-	-	-	-	-	-	-	-	-	-	-	-	-	-
DEH	-	-	-	-	-	-	-	-	-	-	-	-	-	-	-	-
Caries	-	-	-	-	-	-	-	-	-	-	-	-	-	-	-	-
Wear	-	-	-	-	-	-	-	-	-	-	-	-	-	-	-	-
Maxilla	8	7	6	5	4	3	2	1	1	2	3	4	5	6	7	8
Mandible	8	7	6	5	4	3	2	1	1	2	3	4	5	6	7	8
Present	NP	P	AM	AM	AM	-	-	-	-	P	P	P	P	AM	AM	NP
Calculus	-	-	-	-	-	-	-	-	-	ls	lbf	ls	-	-	-	-
DEH	-	-	-	-	-	-	-	-	-	-	L	-	-	-	-	-
Caries	-	al	-	-	-	-	-	-	-	-	-	-	-	-	-	-
Wear	-	-	-	-	-	-	-	-	-	5	5	6	6	-	-	-
Intrusive bone	Mandible and loose dentition															
Comments	No maxilla or hands. Fragmentation of right leg and tarsals is severe.															

Skeleton Number	57 (Phase 1)															
Preservation	1															
Completeness	41-60%															
Fragmentation	Severe															
Age	Adult (18+ years)															
Sex	Male															
Stature	n/d															
Non-metric traits	Ossicle in lambdoid (bilateral), bridging of supra-orbital notch (bilateral), vastus notch (left)															
Pathology	<p><u>Spinal joint disease</u>: 4 cervical bodies (mild to severe osteophytes, porosity and Schmorl's nodes)</p> <p><u>Spinal OA</u>: 1 cervical facet (severe eburation)</p> <p><u>Extra-spinal joint disease</u>: left mandible (mild osteophytes), left scapula (mild osteophytes), left acetabulum (mild osteophytes), right auricular surface (mild osteophytes), left patella (marginal osteophytes), right talus (marginal osteophytes), right 1<sup>st</sup> proximal metatarsal (mild osteophytes).</p> <p><u>Extra-spinal OA</u>: proximal femora, right 1<sup>st</sup> distal metatarsal (mild eburation and porosity).</p> <p><u>Trauma</u>: small bony exostosis on left fibula shaft, fragment unidentified, ligament trauma.</p> <p><u>Lepromatous leprosy</u>: possible rhino-maxillary changes, only small portion of right side survives, resorption of anterior sockets, remodelling of nasal aperture; distal 2/3 of tibiae shafts have striated lamellar bone on medial surface, more severe on left, healed.</p>															
Dental health	AMTL (14/15), calculus (0/1), caries (1/1), DEH (0/1), abscess (0/15), tooth positions (15/15).															
Right dentition								Left dentition								
Present	-	-	AM	AM	R	AM	AM	-	-	-	-	-	-	-	-	-
Calculus	-	-	-	-	-	-	-	-	-	-	-	-	-	-	-	-
DEH	-	-	-	-	-	-	-	-	-	-	-	-	-	-	-	-
Caries	-	-	-	-	la	-	-	-	-	-	-	-	-	-	-	-
Wear	-	-	-	-	-	-	-	-	-	-	-	-	-	-	-	-
Maxilla	8	7	6	5	4	3	2	1	1	2	3	4	5	6	7	8
Mandible	8	7	6	5	4	3	2	1	1	2	3	4	5	6	7	8
Present	AM	AM	-	-	-	-	-	-	AM	AM	AM	AM	AM	AM	AM	AM
Calculus	-	-	-	-	-	-	-	-	-	-	-	-	-	-	-	-
DEH	-	-	-	-	-	-	-	-	-	-	-	-	-	-	-	-
Caries	-	-	-	-	-	-	-	-	-	-	-	-	-	-	-	-
Wear	-	-	-	-	-	-	-	-	-	-	-	-	-	-	-	-
Comments																

Skeleton Number	58 (Phase 1)
Preservation	1
Completeness	0-20%
Fragmentation	Severe
Age	Adult (18+ years)
Sex	?
Stature	n/d
Non-metric traits	None
Pathology	<u>Extra-spinal joint disease</u> : left scapula (mild osteophtyes)
Dental health	No surviving dentition.
Comments	No maxilla, hands, lower legs or feet

Skeleton Number	59 (Phase 1)															
Preservation	0															
Completeness	81-100%															
Fragmentation	Moderate															
Age	Young adult (18-25 years)															
Sex	Male?															
Stature	n/d															
Non-metric traits	Transverse foramen bipartite (bilateral).															
Pathology	<u>Spinal joint disease</u> : 1 cervical body, 2 cervical facets, 5 thoracic bodies (mild osteophtyes). <u>Extra-spinal joint disease</u> : left and right scapula, left scaphoid.															
Dental health	Moderate maxillary and mandibular periodontitis. AMTL (0/17), calculus (16/17), caries (1/17), DEH (0/17), enamel chipping (0/17), abscess (0/11), tooth positions (11/17).															
Right dentition								Left dentition								
Present	P	-	P	P	P	P	-	-	-	-	-	P	P	-	-	-
Calculus	hb	-	mb	ml	ml	ml	-	-	-	-	-	sb	sbl	-	-	-
DEH	-	-	-	-	-	-	-	-	-	-	-	-	-	-	-	-
Caries	-	-	-	-	-	-	-	-	-	-	-	-	-	-	-	-
Wear	3	-	4	3	3	3	-	-	-	-	-	3	3	-	-	-
Maxilla	8	7	6	5	4	3	2	1	1	2	3	4	5	6	7	8
Mandible	8	7	6	5	4	3	2	1	1	2	3	4	5	6	7	8
Present	P	P	P	P	P	P	P	P	P	P	-	-	-	-	-	-
Calculus	-	hl	mbl	fb	fb	mb	mb	mb	mlb	mbl	-	-	-	-	-	-
DEH	-	-	-	-	-	-	-	-	-	-	-	-	-	-	-	-
Caries	-	-	sd	-	-	-	-	-	-	-	-	-	-	-	-	-
Wear	2	4	5	3	3	3	3	3	3	3	-	-	-	-	-	-
Comments	No maxilla or feet. Animal bone in grave fill.															

Skeleton Number	60 (Phase 1)															
Preservation	1															
Completeness	61-80%															
Fragmentation	Severe															
Age	Adolescent (15-17 years)															
Sex	n/a															
Stature	n/a															
Non-metric traits	Ossicle in lambdoid (bilateral).															
Pathology	<p><u>Metabolic</u>: cribra orbitalia (right only, left not present), active.</p> <p><u>Non-specific infection</u>: active periostitis on midshaft of left radius, anterior and posterior surfaces, distal half of left ulna, anterior; striated lamellar bone on lateral and medial surfaces of left tibia, midshaft, 3 well demarcated areas of irregular woven bone associated with slight swelling of shaft, possible chronic ulcers; woven bone on medial surface of right tibia at midshaft, grey in colour, deposits on distal third, lateral surface lighter in colour, fibulae, medial and lateral surfaces affected, more severe on right than left; left 5<sup>th</sup> metatarsal, right 4<sup>th</sup> and 5<sup>th</sup> metatarsals, woven bone on plantar and dorsal surfaces. <u>Possible lepromatous leprosy</u>.</p>															
Dental health	AMTL (0/28), calculus (1/23), caries (0/23), DEH (0/23), enamel chipping (0/23), abscess (0/21), tooth positions (21/28).															
Right dentition									Left dentition							
Present	P	P	P	P	PM	P	P	PM	-	-	-	-	P	P	P	P
Calculus	-	-	-	-	-	-	-	-	-	-	-	-	-	-	-	-
DEH	-	-	-	-	-	-	-	-	-	-	-	-	-	-	-	-
Caries	-	-	-	-	-	-	-	-	-	-	-	-	-	-	-	-
Wear	1	2	3	3	-	1	1	-	-	-	-	-	2	4	2	1
Maxilla	8	7	6	5	4	3	2	1	1	2	3	4	5	6	7	8
Mandible	8	7	6	5	4	3	2	1	1	2	3	4	5	6	7	8
Present	PM	P	P	P	P	P	PM	PM	P	P	P	P	P	P	P	P
Calculus	-	fl	-	-	-	-	-	-	-	-	-	-	-	-	-	-
DEH	-	-	-	-	-	-	-	-	-	-	-	-	-	-	-	-
Caries	-	-	-	-	-	-	-	-	-	-	-	-	-	-	-	-
Wear	-	1	3	2	3	2	-	-	2	2	2	2	2	4	2	1
Comments																

Skeleton Number	61 (Phase 1)
Preservation	1
Completeness	0-20%
Fragmentation	Moderate
Age	Adult (18+ years)
Sex	?
Stature	n/d
Non-metric traits	None
Pathology	<p><u>Extra-spinal joint disease</u>: left proximal ulna (mild osteophtyes).</p> <p><u>Non-specific infection</u>: woven bone on distal half of left tibia, medial and lateral surfaces, slightly more severe on lateral; distal half of left fibula, lateral surface.</p>
Dental health	No surviving dentition.
Comments	No maxilla or hands

Skeleton Number	62 (Phase 1)															
Preservation	0															
Completeness	41-60%															
Fragmentation	Severe															
Age	Adult (18+ years)															
Sex	Male															
Stature	n/d															
Non-metric traits	Mastoid foramen extra-sutural (left).															
Pathology	<p><u>Spinal joint disease</u>: 4 cervical bodies, 1 cervical facet, 8 thoracic bodies, 1 thoracic facet, 2 lumbar facets (mild-moderate osteophytes, porosity and Schmorl's nodes).</p> <p><u>Spinal OA</u>: 2 lumbar facets (mild-moderate osteophytes, porosity and eburnation).</p> <p><u>Extra-spinal joint disease</u>: right clavicle, right scapula, right radius, left ulna, right lunate, right and left scaphoid, right hand, right trapezium, left femur, left fibula.</p> <p><u>Extra-spinal OA</u>: right distal ulna.</p> <p><u>Trauma</u>: possible healed fracture of right proximal 2<sup>nd</sup> hand phalanx, some swelling of shaft and angulation in lateral direction.</p>															
Dental health	AMTL (3/5), calculus (0/1), caries (0/1), DEH (0/1), enamel chipping (0/1), abscess (0/4), tooth positions (4/5).															
Right dentition								Left dentition								
Present	-	-	-	-	-	-	-	-	-	-	-	-	-	-	-	-
Calculus	-	-	-	-	-	-	-	-	-	-	-	-	-	-	-	-
DEH	-	-	-	-	-	-	-	-	-	-	-	-	-	-	-	-
Caries	-	-	-	-	-	-	-	-	-	-	-	-	-	-	-	-
Wear	-	-	-	-	-	-	-	-	-	-	-	-	-	-	-	-
Maxilla	8	7	6	5	4	3	2	1	1	2	3	4	5	6	7	8
Mandible	8	7	6	5	4	3	2	1	1	2	3	4	5	6	7	8
Present	-	-	-	P	-	-	-	-	-	-	PM	-	-	AM	AM	AM
Calculus	-	-	-	-	-	-	-	-	-	-	-	-	-	-	-	-
DEH	-	-	-	-	-	-	-	-	-	-	-	-	-	-	-	-
Caries	-	-	-	-	-	-	-	-	-	-	-	-	-	-	-	-
Wear	-	-	-	5	-	-	-	-	-	-	-	-	-	-	-	-
Comments	No maxilla or feet															



Skeleton Number	63 (Phase 1)
Preservation	0
Completeness	41-60%
Fragmentation	Severe
Age	Adult (18+ years)
Sex	?
Stature	n/d
Non-metric traits	None
Pathology	<p><u>Spinal joint disease</u>: 1 sacral body (mild Schmorl's nodes).</p> <p><u>Extra-spinal joint disease</u>: right radius, left ulna, right patella, calcanei, left talus, left and right cuboid, left lateral cuneiform, right foot (mild osteophytes).</p> <p><u>Non-specific infection</u>: 3 small areas of active periostitis on proximal end of left ulna, lateral side; woven bone deposits on shafts of right 1<sup>st</sup>-5<sup>th</sup> and left 5<sup>th</sup> metacarpals, deposits on 1<sup>st</sup> and 4<sup>th</sup> are most severe; right 5<sup>th</sup>? proximal hand phalanx also affected; tibiae have striated lamellar bone on medial and lateral surfaces, distal 2/3 of shafts are affected, more severe on lateral; fibulae, medial and lateral, distal 2/3 of shafts are affected; woven bone deposition on shafts of left 1<sup>st</sup> and 2<sup>nd</sup>, right 2<sup>nd</sup>, 4<sup>th</sup> and 5<sup>th</sup> metatarsals.</p>
Dental health	No surviving dentition.
Comments	No maxilla

Skeleton Number	64 (Phase 1)
Preservation	0
Completeness	0-20%
Fragmentation	Moderate
Age	Adult (18+ years)
Sex	?
Stature	n/d
Non-metric traits	None
Pathology	<p><u>Extra-spinal joint disease</u>: right radius, left ulna, left hamate, lunate and scaphoid, left hand.</p> <p><u>Extra-spinal OA</u>: right femur (mild osteophytes and porosity).</p> <p><u>Non-specific infection</u>: woven bone on lateral surface of right tibia, distal end; nothing observed on left tibia which is highly fragmented; fibulae shafts also affected, more severe on left side, left 5<sup>th</sup> metatarsal shaft has striated lamellar bone, lateral side.</p> <p><u>Miscellaneous</u>: left and right 1<sup>st</sup> metacarpo-phalangeal joints have abnormal appearance, metacarpal heads are flattened, proximal end of 1<sup>st</sup> proximal hand phalange also flattened.</p>
Dental health	No surviving dentition.
Comments	No maxilla

Skeleton Number	66 (Phase 1)
Preservation	1
Completeness	0-20%
Fragmentation	Severe
Age	Adult (18+ years)
Sex	?
Stature	n/d
Non-metric traits	None
Pathology	None
Dental health	No surviving dentition.
Comments	No maxilla, forearms, hands, lower legs or feet

Skeleton Number	67 (Phase 2)																
Preservation	0																
Completeness	81-100%																
Fragmentation	Severe																
Age	Mature adult (36-45 years)																
Sex	Male																
Stature	n/d																
Non-metric traits	Double anterior calcaneal facet (right), double inferior talar facet (left).																
Pathology	<p><u>Spinal joint disease</u>: 1 thoracic body, 3 lumbar bodies, 1 lumbar facet, 1 sacral facet (mild osteophytes, porosity and Schmorl's nodes);</p> <p><u>Extra-spinal joint disease</u>: right and left medial clavicle (mild porosity), right lunate (small cyst), right and left auricular surface (mild marginal osteophytes), right 3<sup>rd</sup> proximal metacarpal (small cyst), left 5<sup>th</sup> proximal foot phalanx (moderate marginal osteophytes).</p> <p>?<u>Lepromatous leprosy</u>: 2 small fragments of left and right maxilla have abnormal porosity affecting palatal area, nasal area does not survive; striated lamellar bone on medial surface of left tibia at midshaft; fibulae have striated lamellar bone on anterior surfaces, more severe on right, ?distal 2/3 affected; <u>tarsal bars</u>: right navicular has 2 small dorsal exostoses.</p> <p>LV2 has small circular plaque of new bone on anterior surface of body, superior half, max. diameter 5.15 mm (M-L).</p>																
Dental health	AMTL (1/19), calculus (16/18), caries (0/18), DEH (0/18), abscess (0/2), tooth positions (2/19). Four molars have not been identified. Mandibular right canine has and maxillary right 2 <sup>nd</sup> incisor have curved wear facets on distal side of crown.																
Right dentition									Left dentition								
Present	P	-	-	AM	P	P	P	-	-	-	-	P	P	-	-	P	
Calculus	mbImd	-	-	-	mb	mb	sbl	-	-	-	-	hl	sm	-	-	-	
DEH	-	-	-	-	-	-	-	-	-	-	-	-	-	-	-	-	
Caries	-	-	-	-	-	-	-	-	-	-	-	-	-	-	-	-	
Wear	4	-	-	-	5	4	4	-	-	-	-	5	6	-	-	3	
Maxilla	8	7	6	5	4	3	2	1	1	2	3	4	5	6	7	8	
Mandible	8	7	6	5	4	3	2	1	1	2	3	4	5	6	7	8	
Present	P	-	P	P	-	P	-	P	P	P	-	P	P	P	-	P	
Calculus	sbl	-	smd	-	-	hb	-	sbl	fbl	mb	-	mb	sb	sa	-	sblmd	
DEH	-	-	-	-	-	-	-	-	-	-	-	-	-	-	-	-	
Caries	-	-	-	-	-	-	-	-	-	-	-	-	-	-	-	-	
Wear	4	-	5	4	-	3	-	4	4	3	-	3	3	5	-	4	
Comments																	

Skeleton Number	68 (Phase 1)																
Preservation	1																
Completeness	21-40%																
Fragmentation	Moderate																
Age	Prime adult (26-35 years)																
Sex	Male?																
Stature	n/d																
Non-metric traits	Ossicle in lambdoid (bilateral).																
Pathology	<p><u>Extra-spinal joint disease</u>: left radius, left hamate, left acetabulum.</p> <p><u>Non-specific infection</u>: small patch of periostitis on medial surface of left ilium, adjacent to sciatic notch;</p> <p>?<u>Lepromatous leprosy</u>: rhino-maxillary changes, abnormal palatal porosity, resorption of anterior sockets, nasal region does not survive.</p> <p><u>Miscellaneous</u>: abnormal porosity affects ectocranial surfaces of occipital and parietals, also present on ectocranial surfaces of left zygomatic with focus around foramen.</p>																
Dental health	Considerable mandibular periodontal disease. AMTL (4/23), calculus (6/19), caries (3/19), DEH (0/19), enamel chipping (0/19), abscess (0/8), tooth positions (8/23).																
Right dentition									Left dentition								
Present	P	-	-	-	-	P	-	-	AM	AM	3	4	5	6	7	8	
Calculus	-	-	-	-	-	sb	-	-	-	-	fb	fb	-	-	-	-	
DEH	-	-	-	-	-	-	-	-	-	-	-	-	-	-	-	-	
Caries	-	-	-	-	-	-	-	-	-	-	-	-	la	-	-	-	
Wear	3	-	-	-	-	3	-	-	-	-	3	-	3	4	3	3	
Maxilla	8	7	6	5	4	3	2	1	1	2	3	4	5	6	7	8	
Mandible	8	7	6	5	4	3	2	1	1	2	3	4	5	6	7	8	
Present	-	P	AM	P	P	-	P	-	P	P	P	P	AM	P	P	P	
Calculus	-	-	-	-	-	-	mb	-	mbdm	sb	-	-	-	-	-	-	
DEH	-	-	-	-	-	-	-	-	-	-	-	-	-	-	-	-	
Caries	-	sm	-	so	-	-	-	-	-	-	-	-	-	-	-	-	
Wear	-	3	-	3	3	-	3	-	3	3	3	3	-	5	4	3	
Comments	No lower legs or feet. Vertebrae are highly fragmented.																

Skeleton Number	69 (Phase 1)															
Preservation	0															
Completeness	81-100%															
Fragmentation	Moderate															
Age	Mature adult (36-45 years)															
Sex	Female															
Stature	n/d															
Non-metric traits	Ossicle in lambdoid (bilateral), ossicle in coronal (bilateral), absent zygomatic foramen (right), vastus notch (left), double anterior calcaneal facet (right). Crowding and rotation of mandibular incisors.															
Pathology	<p><u>Spinal joint disease</u>: radii, ulnae, right femur, right patella, right tibia, right fibula, right navicular, left medial cuneiform, right foot.</p> <p><u>Maxillary sinusitis</u>: globules of new bone in left and right maxillary sinuses.</p> <p><u>Lepromatous leprosy</u>: rhino-maxillary changes, ante-mortem loss of maxillary incisors, extreme destructive remodelling of anterior alveolar process, some resorption of sockets for maxillary canines and right 1<sup>st</sup> premolar, abnormal porosity of palate, destruction of anterior nasal spine, concave facial profile, small portion of left side of nasal aperture survives, smooth and remodelled; striated lamellar bone on tibiae, lateral surfaces, distal half, healed; probable left 2<sup>nd</sup> metatarsal has woven bone on plantar shaft.</p>															
Dental health	Slight maxillary and mandibular periodontal disease. AMTL (4/29), calculus (16/25), caries (2/25), DEH (0/25), abscess (0/26), enamel chipping (0/25), tooth positions (26/29).															
Right dentition									Left dentition							
Present	CON	P	P	P	P	P	AM	AM	AM	AM	P	P	P	P	-	-
Calculus	-	fb	-	-	-	fb	-	-	-	-	sb	-	-	mbdl	-	-
DEH	-	-	-	-	-	-	-	-	-	-	-	-	-	-	-	-
Caries	-	-	-	-	-	-	-	-	-	-	-	-	sd	lom	-	-
Wear	-	5	7	6	5	3	-	-	-	-	3	5	6	6	-	-
Maxilla	8	7	6	5	4	3	2	1	1	2	3	4	5	6	7	8
Mandible	8	7	6	5	4	3	2	1	1	2	3	4	5	6	7	8
Present	P	P	P	P	P	P	P	P	P	P	P	P	P	P	P	P
Calculus	-	-	-	-	sb	sb	sb	mmd	hbml	sb	sb	ml	sl	sl	sl	so
DEH	-	-	-	-	-	-	-	-	-	-	-	-	-	-	-	-
Caries	-	-	-	-	-	-	-	-	-	-	-	-	-	-	-	-
Wear	5	6	7	4	3	2	2	2	3	3	2	3	4	6	5	4
Comments																

Skeleton Number	70 (Phase 1)																
Preservation	0																
Completeness	41-60%																
Fragmentation	Severe																
Age	Adult (18+ years)																
Sex	Male?																
Stature	n/d																
Non-metric traits	Double atlas facet (right).																
Pathology	<p><u>Extra-spinal joint disease</u>: right foot (mild osteophytes).</p> <p><u>Non-specific infection</u>: woven bone deposits on tibiae, medial and lateral surfaces, more severe on lateral, distal 2/3 of shaft; right fibula, distal2/3 of shaft, medial and anterior surfaces; left fibula, medial surface, distal half of shaft affected, becomes more diffuse towards midshaft.</p> <p><u>Miscellaneous</u>: lesions on endocranial surface of left temporal, abnormal porosity and new bone deposition, confined to squamous portion, immediately posterior to petrous.</p>																
Dental health	AMTL (0/12), calculus (2/8), caries (0/8), DEH (0/8), enamel chipping (2/8), abscess (0/8), tooth positions (8/12). Maxillary left 1 <sup>st</sup> premolar has unusual sloping wear, most of crown is destroyed.																
Right dentition									Left dentition								
Present	P	-	-	-	-	P	PM	PM	P	-	-	-	-	P	-	-	
Calculus	-	-	-	-	-	-	-	-	-	-	-	-	-	-	-	-	
DEH	-	-	-	-	-	-	-	-	-	-	-	-	-	-	-	-	
Caries	-	-	-	-	-	-	-	-	-	-	-	-	-	-	-	-	
Wear	5	-	-	-	-	4	-	-	2	-	-	-	-	7	-	-	
Maxilla	8	7	6	5	4	3	2	1	1	2	3	4	5	6	7	8	
Mandible	8	7	6	5	4	3	2	1	1	2	3	4	5	6	7	8	
Present	-	-	-	-	-	-	-	-	P	-	-	P	P	PM	P	PM	
Calculus	-	-	-	-	-	-	-	-	sa	-	-	smd	-	-	-	-	
DEH	-	-	-	-	-	-	-	-	-	-	-	-	-	-	-	-	
Caries	-	-	-	-	-	-	-	-	-	-	-	-	-	-	-	-	
Wear	-	-	-	-	-	-	-	-	3	-	-	3	5	-	4	-	
Comments																	

Skeleton Number	71 (Phase 2)															
Preservation	1															
Completeness	81-100%															
Fragmentation	Moderate															
Age	Adult (18+ years)															
Sex	Male															
Stature	n/d															
Non-metric traits	Ossicle in lambdoid (bilateral).															
Pathology	<p><u>Spinal joint disease</u>: 2 thoracic bodies, 4 lumbar bodies, 1 sacral facet (mild osteophytes, mild-moderate Schmorl's nodes).</p> <p><u>Extra-spinal joint disease</u>: right scapula, left humerus, ulnae, capitates, hamates, lunates, fingers, scaphoids, left trapezium, right trapezoid, femora.</p> <p><u>Trauma</u>: right distal ulna, swelling on anterior surface of shaft, possible ossified haematoma.</p> <p><u>Non-specific infection</u>: woven bone deposition on palmar surfaces of all surviving hand phalanges; left tibia has marked new bone deposition located on distal half of shaft, all surfaces, most severe on lateral/anterior, some deposits are white and molten in appearance, others are grey and more active in appearance, these become more diffuse towards midshaft of bone; right tibia is highly fragmented, much less severely affected; left fibula, distal 2/3 of shaft, most severe on medial/anterior, some deposits are white and molten in appearance, others are grey and more active in appearance, these become more diffuse towards midshaft of bone; single surviving fragment of right fibula also severely affected; left calcaneus, woven bone deposition, white in colour. <u>Possible lepromatous leprosy</u>.</p>															
Dental health	Slight maxillary periodontal disease. AMTL (0/2), calculus (2/2), caries (0/2), DEH (0/2), enamel chipping (0/2), abscess (0/2), tooth positions (2/2).															
Right dentition								Left dentition								
Present	-	-	-	-	-	-	-	-	-	-	-	-	-	-	P	P
Calculus	-	-	-	-	-	-	-	-	-	-	-	-	-	-	smd	fd
DEH	-	-	-	-	-	-	-	-	-	-	-	-	-	-	-	-
Caries	-	-	-	-	-	-	-	-	-	-	-	-	-	-	-	-
Wear	-	-	-	-	-	-	-	-	-	-	-	-	-	-	4	4
Maxilla	8	7	6	5	4	3	2	1	1	2	3	4	5	6	7	8
Mandible	8	7	6	5	4	3	2	1	1	2	3	4	5	6	7	8
Present	-	-	-	-	-	-	-	-	-	-	-	-	-	-	-	-
Calculus	-	-	-	-	-	-	-	-	-	-	-	-	-	-	-	-
DEH	-	-	-	-	-	-	-	-	-	-	-	-	-	-	-	-
Caries	-	-	-	-	-	-	-	-	-	-	-	-	-	-	-	-
Wear	-	-	-	-	-	-	-	-	-	-	-	-	-	-	-	-
Comments	No maxilla															

Skeleton Number	72 (Phase 1)															
Preservation	0															
Completeness	81-100%															
Fragmentation	Moderate															
Age	Young adult (18-20 years)															
Sex	Male															
Stature	n/d															
Non-metric traits	Ossicle in lambdoid (bilateral), mastoid foramen extra-sutural (left).															
Pathology	<p><u>Extra-spinal joint disease</u>: left foot.</p> <p><u>Trauma</u>: small bony exostosis on posterior surface of left fibula, immediately below proximal articulation, ligament trauma.</p> <p><u>Respiratory infection</u>: periosteal lesions on visceral surfaces of at least 3 right ribs and 1 left rib, all areas of rib affected, extends from costal to sternal end, 14 fragments, deposits comprise thin, grey woven new bone.</p> <p><u>Non-specific infection</u>: small patch of periostitis on superior surface of left clavicle, midshaft; right radius, woven bone on anterior surface adjacent to distal articulation, posterior surface of left radius, distal half; right and left ulna, distal half, posterior surface; right and left humerus, distal 1/3, anterior and posterior surfaces; left tibia, woven bone deposits on medial, anterior, lateral surfaces, extends as far as tibial tuberosity, grey in colour; left fibula, distal half affected, less severe than tibia, active; left 3<sup>rd</sup> metatarsal, grey woven bone on plantar surface; left 4<sup>th</sup> metatarsal, striated lamellar bone, plantar surface.</p>															
Dental health	Slight mandibular and maxillary periodontal disease. AMTL (0/25), calculus (19/25), caries (5/25), DEH (0/25), enamel chipping (0/25), abscess (0/16), tooth positions (16/25).															
Right dentition									Left dentition							
Present	P	P	P	P	P	P	P	P	P	-	-	P	P	P	P	P
Calculus	sd	sm	-	-	-	-	sb	sb	sb	-	-	-	sm	sb	-	sl
DEH	-	-	-	-	-	-	-	-	-	-	-	-	-	-	-	-
Caries	-	-	-	-	-	-	-	-	-	-	-	-	-	-	-	-
Wear	3	3	4	2	3	3	3	3	3	-	-	3	3	4	3	3
Maxilla	8	7	6	5	4	3	2	1	1	2	3	4	5	6	7	8
Mandible	8	7	6	5	4	3	2	1	1	2	3	4	5	6	7	8
Present	P	P	P	-	P	P	-	-	-	-	P	P	P	P	P	P
Calculus	sd	slm	sdm	-	sbl	fb	-	-	-	-	sb	sb	sb	sb	sl	sd
DEH	-	-	-	-	-	-	-	-	-	-	-	-	-	-	-	-
Caries	ppb	ppb	-	-	-	-	-	-	-	-	-	-	-	ppb	ppb	ppb
Wear	3	3	4	-	3	1	-	-	-	-	1	3	3	4	3	3
Comments																



Skeleton Number	73 (Phase 1)
Preservation	1
Completeness	61-80%
Fragmentation	Severe
Age	Adult (18+ years)
Sex	Male
Stature	n/d
Non-metric traits	Ossicle in lambdoid (bilateral), ossicle in coronal (bilateral), vastus notch (left), os trigonum (left).
Pathology	<p><u>Spinal joint disease</u>: 7 lumbar facets (mild osteophytes).</p> <p><u>Extra-spinal joint disease</u>: right lateral clavicle (moderate porosity), proximal ulnae (mild marginal osteophytes).</p> <p><u>Non-specific infection</u>: tibiae, all surfaces affected, most severe on posterior, striated lamellar bone on distal 2/3 of shafts, thick florid deposits of woven bone largely confined to distal 1/3, active; left fibula, thick and florid woven bone, all surfaces, distal 2/3, active; right fibula absent; left 5<sup>th</sup> metatarsal, woven bone deposits, active, plantar surface; right 1<sup>st</sup> proximal foot phalanx, abnormal porosity on plantar surface, possible destruction at distal end, obscured by post-mortem damage; right 1<sup>st</sup> distal foot phalanx, destruction at distal end, destruction of articulations suggestive of <u>septic arthritis</u>. <u>Possible lepromatous leprosy</u>.</p>
Dental health	No surviving dentition
Comments	Animal bone in grave fill. Vertebrae highly fragmented. No right fibula or maxilla.

Skeleton Number	74 (Phase 1)															
Preservation	1															
Completeness	81-100%															
Fragmentation	Moderate															
Age	Adult (18+ years)															
Sex	Indeterminate															
Stature	n/d															
Non-metric traits	Double atlas facet (left).															
Pathology	<p><u>Spinal joint disease</u>: 5 cervical bodies, 5 thoracic bodies, 6 thoracic facets, 1 lumbar body, 6 lumbar facets, 1 sacral body (mild-moderate osteophytes, porosity and Schmorl's nodes).</p> <p><u>Spinal OA</u>: 2 lumbar facets (mild porosity, osteophytes and eburnation).</p> <p><u>Extra-spinal joint disease</u>: radius, ulna, right hand, right tibia and fibula, left navicular, left foot.</p> <p><u>Extra-spinal OA</u>: right lateral clavicle, right scapula and proximal humerus (severe osteophytes, porosity and eburnation), femora, right 1<sup>st</sup> metatarso-phalangeal joint.</p> <p><u>Trauma</u>: right humerus, very poorly healed fracture of surgical neck, post-mortem damage to humeral head, humeral head has been displaced both anteriorly and medially, false joint has formed on anterior surface of body of scapula, severe eburnation covers the surviving posterior portion of the humeral head (secondary OA), severe osteophytes encircling surviving portion of humeral head, grooving on medial side of this surface, humeral head is flattened and deformed, severe eburnation on anterior scapula, glenoid cavity is almost entirely obscured by new bone deposition, left humerus does not survive; healed fracture of shaft of right 3<sup>rd</sup> metacarpal, adjacent to proximal articulation, good apposition, shaft is thickened and angulated in palmar direction, bony exostosis on shaft adjacent to distal articulation, palmar surface; probable healed rib fracture, right 8<sup>th</sup> rib?, callus present on caudal surface.</p> <p><u>Non-specific infection</u>: fibulae have woven bone deposits, distal 1/3 of right is affected, medial and lateral, distal 2/3 of left affected, active, probable chronic ulcer on posterior surface of left fibula, proximal 1/3, area of reactive bone formation combined with swelling, well demarcated border; striated lamellar bone present on tibiae; destruction of distal end of right 1<sup>st</sup> distal phalanx, possible <u>septic arthritis</u>.</p> <p><u>Tarsal bar</u> on left navicular. <u>Possible lepromatous leprosy</u>.</p>															
Dental health	Considerable mandibular periodontal disease. AMTL (7/20), calculus (2/13), caries (2/13), DEH (0/13), enamel chipping (0/13), abscess (1/10), tooth positions (10/20). Internally draining abscess associated with mandibular right 3 <sup>rd</sup> molar, semi-circular, smooth-walled, max. diameter 3.75 mm.															
Right dentition								Left dentition								
Present	-	-	-	-	-	P	P	-	-	-	P	-	-	P	P	-
Calculus	-	-	-	-	-	bms0	ms	-	-	-	as	-	-	-	bdh	-
DEH	-	-	-	-	-	-	-	-	-	-	-	-	-	-	-	-
Caries	-	-	-	-	-	-	-	-	-	-	-	-	-	-	-	-
Wear	-	-	-	-	-	2	3	-	-	-	3	-	-	8	6	-
Maxilla	8	7	6	5	4	3	2	1	1	2	3	4	5	6	7	8
Mandible	8	7	6	5	4	3	2	1	1	2	3	4	5	6	7	8
Present	P	AM	AM	P	P	-	P	P	P	P	P	AM	AM	AM	AM	AM
Calculus	-	-	-	-	bs	-	bs	bs	as	as	bh	-	-	-	-	-
DEH	-	-	-	-	-	-	-	-	-	-	-	-	-	-	-	-
Caries	blms	-	-	-	-	-	-	-	-	-	-	-	-	-	-	-
Wear	4	-	-	7	7	-	4	4	4	4	6	-	-	-	-	-
Comments	No maxilla															

Skeleton Number	75 (Phase 1)																
Preservation	1																
Completeness	21-40%																
Fragmentation	Severe																
Age	Adult (18+ years)																
Sex	Male																
Stature	n/d																
Non-metric traits	None																
Pathology	<p><u>Spinal joint disease</u>: 3 cervical bodies, 2 thoracic bodies, 2 lumbar bodies, 1 lumbar facet (mild-moderate osteophytes, porosity and Schmorl's nodes).</p> <p><u>Extra-spinal joint disease</u>: left clavicle, left scapula, left ulna, left and right femora.</p> <p><u>Non-specific infection</u>: woven bone on posterior surface of left ulna near proximal end, at least 2 mm in thickness, less severe on lateral surface of right ulna.</p>																
Dental health	AMTL (0/2), calculus (0/2), caries (2/2), DEH (0/2), abscess (0/0), tooth positions (0/2)																
Right dentition									Left dentition								
Present	-	-	-	-	P	P	-	-	-	-	-	-	-	-	-	-	-
Calculus	-	-	-	-	-	-	-	-	-	-	-	-	-	-	-	-	-
DEH	-	-	-	-	-	-	-	-	-	-	-	-	-	-	-	-	-
Caries	-	-	-	-	sm	sd	-	-	-	-	-	-	-	-	-	-	-
Wear	-	-	-	-	6	6	-	-	-	-	-	-	-	-	-	-	-
Maxilla	8	7	6	5	4	3	2	1	1	2	3	4	5	6	7	8	
Mandible	8	7	6	5	4	3	2	1	1	2	3	4	5	6	7	8	
Present	-	-	-	-	-	-	-	-	-	-	-	-	-	-	-	-	
Calculus	-	-	-	-	-	-	-	-	-	-	-	-	-	-	-	-	
DEH	-	-	-	-	-	-	-	-	-	-	-	-	-	-	-	-	
Caries	-	-	-	-	-	-	-	-	-	-	-	-	-	-	-	-	
Wear	-	-	-	-	-	-	-	-	-	-	-	-	-	-	-	-	
Comments	No maxilla, lower legs or feet																

Skeleton Number	76 (Phase 1)															
Preservation	0															
Completeness	81-100%															
Fragmentation	Moderate															
Age	Mature adult (36-45 years)															
Sex	Male															
Stature	n/d															
Non-metric traits	Ossicle in lambdoid (bilateral), ossicle in coronal (bilateral), double atlas facet (bilateral).															
Pathology	<p><u>Spinal joint disease</u>: 2 cervical bodies, 4 cervical facets, 6 thoracic bodies, 5 lumbar bodies, 1 sacral body (mild osteophytes and porosity).</p> <p><u>Extra-spinal joint disease</u>: right and left TMJ, left pisiform, tali, right cuboids, naviculars, right intermediate and lateral cuneiforms, feet.</p> <p><u>Extra-spinal OA</u>: left lunate (mild porosity and eburnation).</p> <p><u>Trauma</u>: possible healed fracture of right clavicle, slight swelling of posterior surface at midshaft.</p> <p>Tarsal bars on right cuboid bone, left and right navicular bones.</p> <p><u>Lepromatous leprosy</u>: possible rhino-maxillary change, abnormal porosity on palate; mild new bone deposition along midline; tibiae, striated lamellar bone, distal 2/3, medial and lateral surfaces, woven bone, distal 1/3, lateral surface, probable chronic ulcer at midshaft on lateral side; slight swelling demarcated by periostitis; left fibula, all surfaces of shaft affected, woven bone on most of shaft, right fibula is less severely affected; new bone deposition and abnormal porosity on right 1<sup>st</sup>, 3<sup>rd</sup>, 5<sup>th</sup>, left 2<sup>nd</sup>, 3<sup>rd</sup>, 4<sup>th</sup> and 5<sup>th</sup> metacarpal shafts; shaft of right 1<sup>st</sup> is thickened; destruction of distal articulations of left 2<sup>nd</sup> and 3<sup>rd</sup> metacarpals; destruction of distal end of probable 1<sup>st</sup> distal hand phalanx; right 2<sup>nd</sup> intermediate hand phalanx is fused to distal, head of latter is destroyed; probable right 3<sup>rd</sup> intermediate hand phalanx, destruction of distal end; right 4<sup>th</sup> intermediate and distal hand phalanges are fused, distal phalanx is angled laterally; left intermediate hand phalanx is fused to distal, claw hand deformity;; transverse arch collapse; destruction of distal articulation of right 1<sup>st</sup> 5<sup>th</sup> metatarsal, right 1<sup>st</sup> proximal foot phalanx; thickening of shaft of right 5<sup>th</sup> metatarsal, possible <u>osteomyelitis</u>, commencement of blade-like remodelling, woven bone on plantar surface; identification of left 2<sup>nd</sup>, 3<sup>rd</sup> and 4<sup>th</sup> metatarsals is problematic, destruction of distal articulations, blade-like remodelling and woven bone deposition; left 5<sup>th</sup> metatarsal similarly affected; destruction of articulations probable <u>septic arthritis</u>.</p> <p><u>Non-specific infection</u>: area of abnormal porosity and hyper-vascularity immediately above left and right orbits;</p>															
Dental health	Slight maxillary and mandibular periodontal disease, AMTL (0/26), calculus (18/25), caries (0/25), DEH (0/25), enamel chipping (1/25), abscess (0/26), tooth positions (26/26). Crown of mandibular right 1 <sup>st</sup> molar has chip at lingual/distal corner.															
Right dentition								Left dentition								
Present	P	P	P	P	P	P	PM	P	P	P	P	P	P	P	P	P
Calculus	sd	sb	sd	sm	sb	sb	-	sm	sm	sb	sm	-	-	-	-	-
DEH	-	-	-	-	-	-	-	-	-	-	-	-	-	-	-	-
Caries	-	-	-	-	-	-	-	-	-	-	-	-	-	-	-	-
Wear	4	4	6	4	4	4	-	4	4	4	4	5	5	7	4	4
Maxilla	8	7	6	5	4	3	2	1	1	2	3	4	5	6	7	8
Mandible	8	7	6	5	4	3	2	1	1	2	3	4	5	6	7	8
Present	P	P	P	P	P	-	-	-	-	-	-	P	P	P	P	P
Calculus	fmd	sdl	sl	slm	slmbd	-	-	-	-	-	-	slmbd	sm	-	-	sbl
DEH	-	-	-	-	-	-	-	-	-	-	-	-	-	-	-	-
Caries	-	-	-	-	-	-	-	-	-	-	-	-	-	-	-	-
Wear	4	4	6	4	4	-	-	-	-	-	-	3	4	7	6	5
Comments	Animal bone in grave fill															

Skeleton Number	77 (Phase 1)
Preservation	1
Completeness	21-40%
Fragmentation	Moderate
Age	Adult (18+ years)
Sex	?
Stature	n/d
Non-metric traits	Medial tibial squatting facet (right).
Pathology	<p><u>Extra-spinal joint disease</u>: left patella, right talus, left navicular, medial, intermediate and lateral cuneiforms, left foot (mild osteophytes).</p> <p><u>Non-specific infection</u>: tibiae have striated lamellar bone on medial and lateral surfaces, distal 2/3 of shaft, probable chronic ulcer on lateral surface of right tibia at midpoint, well demarcated by thicker deposits of woven bone; distal 2/3 of right fibula and distal 1/3 of left fibula, striated lamellar bone; right 3<sup>rd</sup>, 4<sup>th</sup> and 5<sup>th</sup> metatarsals have woven bone deposits.</p>
Dental health	No surviving dentition.
Comments	No maxilla or forearms

Skeleton Number	78 (Phase 2)																
Preservation	1																
Completeness	41-60%																
Fragmentation	Severe																
Age	Older adult (45+ years)																
Sex	Male																
Stature	n/d																
Non-metric traits	Ossicle in lambdoid (bilateral), metopic suture, ossicle in coronal (bilateral, bridging of supra-orbital notch (bilateral)), accessory supraorbital foramen (right).																
Pathology	<p><u>Spinal joint disease</u>: 1 cervical body (mild osteophytes).</p> <p><u>Extra-spinal joint disease</u>: left femur, patellae (mild osteophytes).</p> <p><u>Metabolic</u>: cribra orbitalia, left only, right does not survive.</p> <p><u>Lepromatous leprosy</u>: rhino-maxillary changes, resorption of anterior sockets, abnormal porosity of palate, nasal floor is normal, nasal aperture and anterior nasal spine do not survive; tibiae, woven bone, light in colour, distal 1/3, active; right fibula, distal half, lateral surface; left fibula, disorganised woven new bone, grey in colour, active.</p>																
Dental health	Moderate mandibular and considerable maxillary periodontal disease. AMTL (0/32), calculus (13/30), caries (0/30), DEH (0/30), enamel chipping (0/30), abscess (1/26), tooth positions (26/32). Extreme maxillary molar wear sloping down from buccal to lingual, most of maxillary anterior dentition heavily worn. Externally draining abscess associated with maxillary right 2 <sup>nd</sup> molar, small smooth-walled semi-circular, exposing distal root.																
Right dentition									Left dentition								
Present	P	P	P	PM	P	P	P	P	P	P	P	P	P	P	P	P	P
Calculus	-	-	-	-	sb	-	-	-	-	mbl	-	-	-	-	-	-	-
DEH	-	-	-	-	-	-	-	-	-	-	-	-	-	-	-	-	-
Caries	-	-	-	-	-	-	-	-	-	-	-	-	-	-	-	-	-
Wear	5	8	8	-	3	8	8	7	7	7	8	8	8	8	8	8	6
Maxilla	8	7	6	5	4	3	2	1	1	2	3	4	5	6	7	8	
Mandible	8	7	6	5	4	3	2	1	1	2	3	4	5	6	7	8	
Present	P	P	P	P	P	P	P	P	P	P	P	PM	P	P	P	P	
Calculus	-	-	-	-	-	mlsb	mbl	hl	mbl	hl	hl	-	mml	ml	ml	ml	
DEH	-	-	-	-	-	-	-	-	-	-	-	-	-	-	-	-	
Caries	-	-	-	-	-	-	-	-	-	-	-	-	-	-	-	-	
Wear	5	6	6	3	3	3	2	3	3	2	3	-	3	5	7	7	
Comments	No feet. Vertebrae are highly fragmented.																

Skeleton Number	79 (Phase 2)															
Preservation	1															
Completeness	81-100%															
Fragmentation	Moderate															
Age	Adult (18+ years)															
Sex	Male?															
Stature	n/d															
Non-metric traits	Ossicle in lambdoid (bilateral), transverse foramen bipartite (left).															
Pathology	<p><u>Spinal joint disease</u>: 3 cervical bodies, 12 cervical facets, 8 thoracic bodies, 3 lumbar bodies, 3 lumbar facets (mild osteophytes, porosity and Schmorl's nodes). Lytic defect on superior left process of CV2.</p> <p><u>Extra-spinal joint disease</u>: clavicles, radii, ulnae, hamates, left scaphoid, right trapezium and triquetral, left trapezoid, left and right hands, left femur, left talus, left foot.</p> <p><u>Non-specific infection</u>: striated lamellar bone on right distal ulna, anterior surface; woven bone on tibiae, distal 1/3 of shaft, medial and lateral surfaces; fibulae, medial and lateral surfaces, distal 1/3.</p>															
Dental health	Moderate periodontal disease. AMTL (0/7), calculus (2/2), caries (0/2), DEH (0/2), enamel chipping (0/2), abscess (0/7), tooth positions (7/7).															
Right dentition									Left dentition							
Present	-	-	-	-	-	-	-	-	-	-	-	-	-	-	-	-
Calculus	-	-	-	-	-	-	-	-	-	-	-	-	-	-	-	-
DEH	-	-	-	-	-	-	-	-	-	-	-	-	-	-	-	-
Caries	-	-	-	-	-	-	-	-	-	-	-	-	-	-	-	-
Wear	-	-	-	-	-	-	-	-	-	-	-	-	-	-	-	-
Maxilla	8	7	6	5	4	3	2	1	1	2	3	4	5	6	7	8
Mandible	8	7	6	5	4	3	2	1	1	2	3	4	5	6	7	8
Present	-	-	P	PM	P	PM	PM	PM	-	-	PM	-	-	-	-	-
Calculus	-	-	sbl	-	smd	-	-	-	-	-	-	-	-	-	-	-
DEH	-	-	-	-	-	-	-	-	-	-	-	-	-	-	-	-
Caries	-	-	-	-	-	-	-	-	-	-	-	-	-	-	-	-
Wear	-	-	-	-	-	-	-	-	-	-	-	-	-	-	-	-
Comments	No maxilla															

Skeleton Number	80 (Phase 1)																
Preservation	0																
Completeness	81-100%																
Fragmentation	Moderate																
Age	Prime adult (26-35 years)																
Sex	Indeterminate																
Stature	n/d																
Non-metric traits	Transverse foramen bipartite (right), septal aperture (bilateral).																
Pathology	<p><u>Spinal joint disease</u>: 1 cervical body, 2 cervical facets, 2 thoracic bodies (mild-moderate osteophytes and Schmorl's nodes).</p> <p><u>Extra-spinal joint disease</u>: left clavicle, radii, ulnae, left hamate and trapezium, right scaphoid, patellae, right talus.</p> <p><u>Lepromatous leprosy</u>: rhino-maxillary changes, abnormal porosity on right side of nasal floor, remodelling of nasal aperture, new bone deposition, post-mortem destruction of sockets on right side, no resorption of sockets on left side.</p> <p><u>Osteomyelitis</u>: right tibia, marked thickening of distal half of shaft, involvement of medullary cavity, woven bone on lateral and medial surfaces; woven bone on distal 1/3 of shaft of left tibia, medial and lateral surfaces, medullary cavity not involved; left fibula, complete, in 4 fragments, gross pathological changes to almost all of shaft, all surfaces affected though much more severe on lateral surface, distal half, profusion of woven new bone which measures up to 10.15 mm in thickness, involvement of medullary cavity; right fibula, slight woven bone deposition on a probable distal fragment; right 5<sup>th</sup> metatarsal, abnormal porosity on shaft; right 3<sup>rd</sup> and 4<sup>th</sup> metatarsals, woven bone.</p>																
Dental health	Slight maxillary and mandibular periodontal disease. AMTL (0/32), calculus (8/32), caries (0/32), DEH (0/32), enamel chipping (1/32), abscess (0/23), tooth positions (23/32).																
Right dentition									Left dentition								
Present	P	P	P	P	P	P	P	P	P	P	P	P	P	P	P	P	P
Calculus	-	-	-	-	-	-	-	-	-	-	-	sb	-	-	-	-	-
DEH	-	-	-	-	-	-	-	-	-	-	-	-	-	-	-	-	-
Caries	-	-	-	-	-	-	-	-	-	-	-	-	-	-	-	-	-
Wear	3	4	5	3	3	3	3	3	3	3	3	3	3	5	4	3	
Maxilla	8	7	6	5	4	3	2	1	1	2	3	4	5	6	7	8	
Mandible	8	7	6	5	4	3	2	1	1	2	3	4	5	6	7	8	
Present	P	P	P	P	P	P	P	P	P	P	P	P	P	P	P	P	P
Calculus	-	-	-	-	-	sbl	mblm	hbimd	mbhl	hbl	mmld	sb	-	-	-	-	-
DEH	-	-	-	-	-	-	-	-	-	-	-	-	-	-	-	-	-
Caries	-	-	-	-	-	-	-	-	-	-	-	-	-	-	-	-	-
Wear	3	4	5	3	3	3	4	4	4	4	3	3	3	5	4	3	
Comments																	



Skeleton Number	81 (Phase 2)																
Preservation	0																
Completeness	81-100%																
Fragmentation	Moderate																
Age	Prime adult (26-35 years)																
Sex	Male																
Stature	n/d																
Non-metric traits	Ossicle in lambdoid (bilateral), ossicle in coronal (bilateral), double anterior calcaneal facet (right), double inferior talar facet (bilateral). Accessory facet on posterior surface of left clavicle, immediately below conoid tubercle.																
Pathology	<p><u>Spinal joint disease</u>: 7 thoracic bodies, 1 lumbar body (mild-moderate osteophytes, porosity and Schmorl's nodes).</p> <p><u>Extra-spinal OA</u>: femora (severe osteophytes), encircling entire head, slightly more severe on lateral side, extends across femoral neck.</p> <p><u>Non-specific infection</u>: tibiae and fibulae shafts, striated lamellar bone, location unclear.</p>																
Dental health	Considerable mandibular periodontal disease. AMTL (1/8), calculus (1/7), caries (0/7), DEH (3/7), enamel chipping (0/7), abscess (0/6), tooth positions (6/8). Externally draining abscess, mandibular right 2 <sup>nd</sup> molar, sharp-walled, semi-circular.																
Right dentition									Left dentition								
Present	P	-	-	-	-	-	-	-	-	-	-	-	-	-	-	-	P
Calculus	-	-	-	-	-	-	-	-	-	-	-	-	-	-	-	-	-
DEH	-	-	-	-	-	-	-	-	-	-	-	-	-	-	-	-	-
Caries	-	-	-	-	-	-	-	-	-	-	-	-	-	-	-	-	-
Wear	3	-	-	-	-	-	-	-	-	-	-	-	-	-	-	-	3
Maxilla	8	7	6	5	4	3	2	1	1	2	3	4	5	6	7	8	
Mandible	8	7	6	5	4	3	2	1	1	2	3	4	5	6	7	8	
Present	P	AM	P	P	P	P	-	-	-	-	-	-	-	-	-	-	
Calculus	fd	-	-	-	sm	-	-	-	-	-	-	-	-	-	-	-	
DEH	-	-	1L	1L	1L	-	-	-	-	-	-	-	-	-	-	-	
Caries	-	-	-	-	-	-	-	-	-	-	-	-	-	-	-	-	
Wear	3	-	4	4	4	1	-	-	-	-	-	-	-	-	-	-	
Comments	No maxilla																

Skeleton Number	82 (Phase 2)																
Preservation	1																
Completeness	81-100%																
Fragmentation	Slight																
Age	Young adult (18-25 years)																
Sex	Male?																
Stature	167.084 +/- 4.32 cm																
Non-metric traits	Ossicle in lambdoid (bilateral), ossicle in coronal (bilateral), absent zygomaticofacial foramen (left), transverse foramen bipartite (CV5, right). Spina bifida occulta.																
Pathology	<p><u>Extra-spinal joint disease</u>: right medial cuneiform (mild osteophytes).</p> <p><u>Trauma</u>: 3<sup>rd</sup> sacral body is compressed anteriorly, resulting in a marked increase to sacral curvature, [broken bones p 187], a hairline crack is visible on left side of 3<sup>rd</sup> sacral arch.</p> <p><u>Lepromatous leprosy</u>: rhino-maxillary change, advanced resorption of anterior sockets, almost to roots on buccal surface, abnormal porosity of palate, little of nasal aperture survives although margins appear normal; striated lamellar bone on medial surface of right tibia, distal 2/3 of shaft; fibulae have striated lamellar bone and woven bone on lateral surface, distal 1/3; right intermediate and distal 5<sup>th</sup> foot phalanges are fused together, probable remodelling and abnormal porosity, also post-mortem damage. Possible claw toe deformity.</p>																
Dental health	AMTL (0/30), calculus (23/29), caries (0/29), DEH (15/29), enamel chipping (1/29), abscess (0/26), tooth positions (26/30).																
Right dentition									Left dentition								
Present	UE	P	P	P	P	P	PM	P	P	P	P	P	P	P	P	P	UE
Calculus	-	sd	sml	-	sbd	sb	-	mb	sb	sbm	sb	-	-	-	sd	-	-
DEH	-	-	-	-	3L	3L	-	3L	3L	3L	3L	3L	3L	-	-	-	-
Caries	-	-	-	-	-	-	-	-	-	-	-	-	-	-	-	-	-
Wear	-	2	3	2	2	2	-	2	2	2	2	2	2	2	2	2	2
Maxilla	8	7	6	5	4	3	2	1	1	2	3	4	5	6	7	8	8
Mandible	8	7	6	5	4	3	2	1	1	2	3	4	5	6	7	8	8
Present	CON	P	P	P	P	P	P	P	P	P	P	P	P	P	P	P	P
Calculus	-	fbl	fbl	fm	sm	mbd	mb	mb	mb	sb	sb	smd	sd	sd	sdl	-	-
DEH	-	-	-	-	3L	3L	3L	3L	3L	3L	3L	3L	3L	-	-	-	-
Caries	-	-	-	-	-	-	-	-	-	-	-	-	-	-	-	-	-
Wear	-	2	3	2	2	2	2	2	2	2	2	2	2	2	2	2	-
Comments																	

Skeleton Number	83 (Phase 2)															
Preservation	0															
Completeness	41-60%															
Fragmentation	Moderate															
Age	Prime adult (26-35 years)															
Sex	Female															
Stature	n/d															
Non-metric traits	None															
Pathology	<p><u>Non-specific infection</u>: small area of striated lamellar bone on midshaft of left tibia, lateral side of anterior crest.</p> <p><u>Trauma</u>: possible healed fracture of right 1<sup>st</sup> proximal foot phalanx, poor alignment.</p>															
Dental health	Slight mandibular periodontal disease, AMTL (0/15), calculus (12/15), caries (1/15), DEH (0/15), abscess (0/4), tooth positions (4/15).															
Right dentition								Left dentition								
Present	-	-	-	-	-	-	-	-	-	-	-	-	-	-	-	-
Calculus	-	-	-	-	-	-	-	-	-	-	-	-	-	-	-	-
DEH	-	-	-	-	-	-	-	-	-	-	-	-	-	-	-	-
Caries	-	-	-	-	-	-	-	-	-	-	-	-	-	-	-	-
Wear	-	-	-	-	-	-	-	-	-	-	-	-	-	-	-	-
Maxilla	8	7	6	5	4	3	2	1	1	2	3	4	5	6	7	8
Mandible	8	7	6	5	4	3	2	1	1	2	3	4	5	6	7	8
Present	P	P	P	P	P	P	-	P	P	P	P	P	P	P	P	P
Calculus	sd	mdblm	hbld	hbsd	hbsd	sb	-	sbl	sb	sb	sb	-	-	sl	-	sd
DEH	-	-	-	-	-	-	-	-	-	-	-	-	-	-	-	-
Caries	-	-	-	-	-	-	-	-	-	-	-	-	-	sb	-	-
Wear	3	4	4	3	3	3	-	4	4	4	3	3	3	4	3	3
Comments	Area of green staining on distal end of right tibia, medial and lateral surfaces.															

Skeleton Number	84 (Phase 1)															
Preservation	1															
Completeness	81-100%															
Fragmentation	Moderate															
Age	Prime adult (26-35 years)															
Sex	Male															
Stature	n/d															
Non-metric traits	Ossicle in lambdoid (bilateral), ossicle in coronal (bilateral).															
Pathology	<p><u>Extra-spinal joint disease</u>: left and right medial clavicles, right hamate, lunate and trapezium, left triquetral, left acetabulum, left and right auricular surface, left 5<sup>th</sup> metatarsal.</p> <p>Possible Perthes disease. Left femur head has expanded mushroom-like appearance, there is marked flattening of femur shaft in anterior-posterior plane, right femur is normal.</p> <p><u>Extra-spinal OA</u>: left proximal femur.</p> <p>?<u>Lepromatous leprosy</u>: possible rhino-maxillary changes, post-mortem damage, resorption of anterior alveolar bone in region of right maxillary incisors and right canine, abnormal porosity of palate; fragment of left ilium has small area of woven new bone deposition on medial surface above acetabulum; left tibia, 2 patches of active periostitis on lateral surface, proximal half, a 3<sup>rd</sup> patch located on medial surface at distal end, 2 further areas of localised periostitis with distinct margins are possible chronic ulcers; a further 2 probable chronic ulcers on right tibia, distal third, both have associated swelling of shaft and periostitis.</p>															
Dental health	Moderate maxillary and mandibular periodontal disease. AMTL (2/22), calculus (15/19), DEH (0/19), caries (7/19), abscess (0/9), tooth positions present (9/22), enamel chipping (3/19). Maxillary 1 <sup>st</sup> incisors have staining on buccal surfaces.															
Right dentition									Left dentition							
Present	P	P	P	P	P	-	P	P	P	-	-	P	P	P	P	P
Calculus	sd	-	sd	Mmd	md	-	sb	-	-	-	-	sm	fa	mbm	sa	sa
DEH	-	-	-	-	-	-	-	-	-	-	-	-	-	-	-	-
Caries	lm	md	mdl	-	-	-	-	-	-	-	-	sd	-	ldo	mbd	-
Wear	3	3	4	3	3	-	2	3	3	-	-	4	5	6	3	3
Maxilla	8	7	6	5	4	3	2	1	1	2	3	4	5	6	7	8
Mandible	8	7	6	5	4	3	2	1	1	2	3	4	5	6	7	8
Present	P	P	PM	-	-	-	-	P	-	P	-	-	P	P	AM	AM
Calculus	sdl	sl	-	-	-	-	-	sb	-	mbl	-	-	sl	mbl	-	-
DEH	-	-	-	-	-	-	-	-	-	-	-	-	-	-	-	-
Caries	-	-	-	-	-	-	-	-	-	-	-	-	-	-	-	-
Wear	4	3	-	-	-	-	-	3	-	3	-	-	4	5	-	-
Comments																

Skeleton Number	85 (Phase 1)															
Preservation	1															
Completeness	21-40%															
Fragmentation	Severe															
Age	Prime adult (26-35 years)															
Sex	Female															
Stature	n/d															
Non-metric traits	Ossicle in lambdoid (bilateral), ossicle in coronal (bilateral), bridging of supra-orbital notch (left).															
Pathology	<p><u>Spinal joint disease</u>: 2 cervical facets, 9 thoracic bodies, 5 thoracic facets (mild-moderate osteophytes and porosity).</p> <p><u>Extra-spinal joint disease</u>: distal fibula (moderate lytic lesion).</p> <p><u>Metabolic</u>: cribra orbitalia (bilateral).</p> <p><u>Trauma</u>: right ulna, distal end, healed fracture, slight swelling of shaft on medial side; left proximal humerus has bony exostosis on lateral side at deltoid insertion, much smaller exostosis in same location on right humerus.</p> <p><u>Lepromatous leprosy</u>: rhino-maxillary changes, remodelling of nasal aperture, destruction of anterior nasal spine, woven bone on floor of nasal aperture, marked resorption of anterior sockets, facial profile is concave; right tibia, distal third, medial surface, striated lamellar bone; right fibula, medial surface, distal 1/3, small patch of woven bone, lighter in colour than surrounding bone; left 5<sup>th</sup> metatarsal, grey woven bone on medial surface of shaft.</p>															
Dental health	Considerable mandibular and maxillary periodontal disease. AMTL (1/29), calculus (15/28), caries (7/28), DEH (1/28), enamel chipping (3/28), abscess (2/20), tooth positions (20/29). Externally draining abscesses associated with mandibular right 1 <sup>st</sup> molar and mandibular left 2 <sup>nd</sup> molar, one is small and sharp-walled, max. diameter 2.65 mm, the other is smooth-walled, max. diameter 4.08 mm.															
Right dentition									Left dentition							
Present	P	-	P	P	P	P	P	-	P	P	P	P	AM	R	7	-
Calculus	-	-	-	Fa	fd	sm	sm	-	-	fm	mbm	-	-	-	-	-
DEH	-	-	-	-	-	-	-	-	1L	-	-	-	-	-	-	-
Caries	-	-	-	-	-	-	-	-	-	-	-	-	-	la	mm	-
Wear	5	-	6	3	3	-	3	-	4	3	4	3	-	-	5	-
Maxilla	8	7	6	5	4	3	2	1	1	2	3	4	5	6	7	8
Mandible	8	7	6	5	4	3	2	1	1	2	3	4	5	6	7	8
Present	P	P	P	P	R	P	P	P	P	P	P	P	P	P	P	P
Calculus	hl	-	-	-	-	hb	hb	hbl	hbl	hbl	hb	sb	-	sbl	-	-
DEH	-	-	-	-	-	-	-	-	-	-	-	-	-	-	-	-
Caries	-	mb	mdlml	-	-	-	-	-	-	-	-	-	-	-	mb	sd
Wear	4	4	5	4	-	3	3	3	3	3	3	4	4	6	4	3
Comments	Radiocarbon dated. Sample 6, 1280-1420 cal AD (95.4% probability).															

Skeleton Number	86 (Phase 2)															
Preservation	0															
Completeness	41-60%															
Fragmentation	Moderate															
Age	Prime adult (26-35 years)															
Sex	Male															
Stature	n/d															
Non-metric traits	Ossicle in lambdoid (bilateral), ossicle in coronal (bilateral), absent zygomaticofacial foramen (bilateral).															
Pathology	<p><u>Spinal joint disease</u>: 7 thoracic bodies, 1 lumbar body, 4 lumbar facets (mild-moderate osteophytes, porosity and Schmorl's nodes).</p> <p><u>Extra-spinal joint disease</u>: left ulna (mild osteophytes).</p> <p><u>Miscellaneous</u>: left clavicle, capsule attachment for costo-clavicular ligament has 2 large lytic defects, solid medullary cavity; areas of abnormal porosity on left and right zygomatics, anterior surface, more severe on right, lighter in colour; possible erosive lesions on anterior surface of SV3 and 4, trabecular bone is visible.</p>															
Dental health	Slight mandibular and maxillary periodontal disease. AMTL (4/32), calculus (20/24), caries (2/24), DEH (0/24), enamel chipping (1/24), abscess (2/32), tooth positions (32/32). Externally draining abscess located at mandibular right 1 <sup>st</sup> molar, smooth-walled, semi-circular, max. diameter 4.53 mm. Large abscess located at maxillary right 1 <sup>st</sup> molar, both internally and externally draining, external is smooth-walled and semi-circular, max. diameter 4.93, internal is sharp-walled circular perforation, max. diameter 7.55 mm.															
Right dentition									Left dentition							
Present	P	P	AM	R	P	P	PM	PM	P	P	P	P	AM	AM	7	8
Calculus	sl	sl	-	-	-	sb	-	-	sb	sb	-	fb	-	-	-	fd
DEH	-	-	-	-	-	-	-	-	-	-	-	-	-	-	-	-
Caries	-	-	-	La	-	-	-	-	-	-	-	sm	-	-	-	-
Wear	2	3	-	-	2	2	-	-	2	2	2	3	-	-	2	2
Maxilla	8	7	6	5	4	3	2	1	1	2	3	4	5	6	7	8
Mandible	8	7	6	5	4	3	2	1	1	2	3	4	5	6	7	8
Present	P	P	AM	PM	P	P	P	PM	P	P	P	P	P	P	P	P
Calculus	fd	fm	-	-	sbd	mbsl	mbsl	-	mb	mb	sd	smd	MI	fl	fl	fl
DEH	-	-	-	-	-	-	-	-	-	-	-	-	-	-	-	-
Caries	-	-	-	-	-	-	-	-	-	-	-	-	-	-	-	-
Wear	3	4	-	-	2	3	2	-	3	3	2	3	3	2	2	2
Comments	No lower legs or feet. Radiocarbon dated. Sample 7, 1444-1634 cal AD (95.4% probability).															

Skeleton Number	87 (Phase 1)															
Preservation	1															
Completeness	21-40%															
Fragmentation	Severe															
Age	Older adult (45+ years)															
Sex	Male?															
Stature	n/d															
Non-metric traits	Double atlas facet (left).															
Pathology	<u>Spinal joint disease</u> : 1 cervical body, 1 cervical facet, 5 thoracic bodies (mild, moderate osteophytes and Schmorl's nodes)															
Dental health	Moderate maxillary periodontal disease. AMTL (1/30), calculus (20/29), caries (2/29), DEH (0/29), enamel chipping (0/29), abscess (0/11), tooth positions (11/30).															
Right dentition									Left dentition							
Present	P	-	P	AM	P	P	P	P	P	P	P	P	P	P	-	P
Calculus	-	-	-	-	fa	fa	fd	fl	fl	-	fa	fd	-	fb	-	-
DEH	-	-	-	-	-	-	-	-	-	-	-	-	-	-	-	-
Caries	sd	-	-	-	-	-	-	-	-	-	-	-	-	-	-	-
Wear	5	-	8	-	5	4	4	5	5	4	5	5	6	8	-	4
Maxilla	8	7	6	5	4	3	2	1	1	2	3	4	5	6	7	8
Mandible	8	7	6	5	4	3	2	1	1	2	3	4	5	6	7	8
Present	P	P	P	P	P	P	P	P	P	P	P	P	P	P	P	P
Calculus	sblm	fm	-	fl	fd	fb	sl	sl	sl	sl	sl	fd	-	-	-	sl
DEH	-	-	-	-	-	-	-	-	-	-	-	-	-	-	-	-
Caries	sd	-	-	-	-	-	-	-	-	-	-	-	-	-	-	-
Wear	4	7	7	4	4	4	4	4	4	4	4	4	4	7	7	4
Comments	No forearms, lower legs or feet															

Skeleton Number	88 (Phase 1)															
Preservation	0															
Completeness	81-100%															
Fragmentation	Moderate															
Age	Adult (18+ years)															
Sex	Male															
Stature	n/d															
Non-metric traits	Accessory acromial facet (right).															
Pathology	<p><u>Spinal joint disease</u>: 2 cervical bodies, 2 cervical facets, 2 thoracic bodies, 5 lumbar bodies, 5 lumbar facets (mild-severe osteophytes and porosity).</p> <p><u>Spinal OA</u>: 1 lumbar facet (mild eburnation).</p> <p><u>Extra-spinal joint disease</u>: right manubrium, right clavicle, scapulae, right ulna, right tibia, left foot.</p> <p><u>Extra-spinal OA</u>: clavicles, left scaphoid, femora (mild-severe osteophytes, porosity and eburnation).</p> <p><u>Trauma</u>: small bony exostosis on right fibula, anterior surface, distal end, ligament trauma; right ribs, 5 midshaft fragments have well healed fractures, surviving callus on visceral surfaces.</p> <p><u>Non-specific infection</u>: tibiae, striated lamellar bone on medial side running length of shaft, more severe on right; diffuse patches of woven bone on right fibula, proximal 1/3, lateral surface; calcanei have woven bone on lateral surfaces, more active on left.</p>															
Dental health	Considerable mandibular periodontal disease. AMTL (13/20), calculus (0/7), caries (0/7), DEH (2/7), abscess (0/17), tooth positions (17/20). Five unidentified roots, five possible intrusive teeth.															
Right dentition									Left dentition							
Present	-	-	-	-	-	P	-	P	P	AM	AM	AM	AM	AM	-	-
Calculus	-	-	-	-	-	-	-	-	-	-	-	-	-	-	-	-
DEH	-	-	-	-	-	-	-	-	2L	-	-	-	-	-	-	-
Caries	-	-	-	-	-	-	-	-	-	-	-	-	-	-	-	-
Wear	-	-	-	-	-	8	-	8	8	-	-	-	-	-	-	-
Maxilla	8	7	6	5	4	3	2	1	1	2	3	4	5	6	7	8
Mandible	8	7	6	5	4	3	2	1	1	2	3	4	5	6	7	8
Present	AM	P	AM	AM	AM	P	AM	-	P	P	-	-	-	AM	AM	AM
Calculus	-	-	-	-	-	-	-	-	-	-	-	-	-	-	-	-
DEH	-	-	-	-	-	2L	-	-	-	-	-	-	-	-	-	-
Caries	-	-	-	-	-	-	-	-	-	-	-	-	-	-	-	-
Wear	-	5	-	-	-	6	-	-	8	7	-	-	-	-	-	-
Comments																



Skeleton Number	89 (Phase 2)															
Preservation	0															
Completeness	21-40%															
Fragmentation	Moderate															
Age	Prime adult (26-35 years)															
Sex	Male															
Stature	180.714 +/- 4.05 cm															
Non-metric traits	Ossicle in lambdoid ossicles (bilateral), parietal foramen (bilateral), ossicle in coronal (bilateral), mastoid foramen extrasutural (bilateral), double talar facet (right), circumflex sulcus (right). Crowding of right mandibular 1 <sup>st</sup> and 2 <sup>nd</sup> incisors, rotation of right mandibular canine.															
Pathology	<p><u>Spinal joint disease</u>: 2 cervical bodies, 1 cervical facet, 7 thoracic bodies, 1 thoracic facet (mild-severe osteophytes, porosity and Schmorl's nodes).</p> <p><u>Extra-spinal joint disease</u>: manubrium, clavicles.</p> <p><u>Trauma</u>: possible healed fracture of acromial end of left clavicle, shaft or joint??? possible atrophy of lateral epiphysis; possible healed fracture of left 6<sup>th</sup> rib, located at angle, new bone deposition on caudal surface.</p> <p><u>Non-specific infection</u>: area of healed periostitis on left clavicle, medial side of conoid tubercle; left and right petrous pyramids, small areas of porosity.</p> <p><u>Miscellaneous</u>: conoid tubercle on left clavicle is much enlarged. Costo-clavicular lytic defect</p>															
Dental health	Slight mandibular and maxillary periodontal disease. AMTL (0/25), calculus (19/25), caries (2/25), DEH (2/25), enamel chipping (1/25), abscess (0/25), tooth positions (25/25). Wear on most of mandibular left dentition obscured by occlusal change.															
Right dentition									Left dentition							
Present	P	P	P	P	P	P	P	P	-	P	P	-	-	-	-	-
Calculus	-	-	-	fb	fb	fb	-	fb	-	sb	sb	-	-	-	-	-
DEH	-	-	-	-	-	-	-	-	-	-	-	-	-	-	-	-
Caries	ml	-	-	-	-	-	-	-	-	-	-	-	-	-	-	-
Wear	1	2	5	4	4	3	3	3	-	3	3	-	-	-	-	-
Maxilla	8	7	6	5	4	3	2	1	1	2	3	4	5	6	7	8
Mandible	8	7	6	5	4	3	2	1	1	2	3	4	5	6	7	8
Present	P	P	P	P	P	P	P	P	P	-	P	P	P	P	P	P
Calculus	fd	-	-	sl	sl	ml	ml	ml	sl	-	sbl	so	mo	mo	mo	mod
DEH	-	-	-	-	-	1L	-	-	-	-	1L	-	-	-	-	-
Caries	-	-	-	-	-	-	-	-	-	-	-	-	-	-	-	so
Wear	1	1	4	3	2	1	3	3	3	-	2	-	-	-	-	-
Comments	No forearms, hands, lower legs or feet															

Skeleton Number	90 (Phase 2)																
Preservation	1																
Completeness	0-20%																
Fragmentation	Moderate																
Age	Prime adult (26-35 years)																
Sex	Male																
Stature	n/d																
Non-metric traits	Ossicle in lambdoid (bilateral), ossicle in coronal (bilateral).																
Pathology	<p><u>Spinal joint disease</u>: 3 cervical bodies, 2 cervical facets, 1 thoracic body, 1 thoracic facet (mild osteophytes, porosity and Schmorl's nodes). CV7; TV 3 and 4 have new bone deposition on inferior bodies immediately within annular rings. TV1 has smooth-walled broadly circular lytic defect on right side immediately below right rib facet, max. diameter 6.12 mm, left side does not survive.</p> <p><u>Extra-spinal joint disease</u>: left proximal humerus (mild porosity).</p> <p><u>Miscellaneous</u>: left proximal humerus has broadly linear defect on anterior surface which runs vertically along the shaft. 30.64 mm (P-D) x 1.90 mm (M-L). A second more oval defect is diagonally aligned and located on lateral side of the 1<sup>st</sup>, 13.24 mm (P-D) x 3.11 mm (M-L). A third is irregular and located below the second. Trabecular bone is visible in all three defects.</p>																
Dental health	AMTL (0/32), calculus (18/31), caries (1/31), DEH (1/31), abscess (0/31), tooth positions (31/32). Mandibular right 1 <sup>st</sup> molar has distal chip. Mandibular right canine has bifurcated root. Retention of part of deciduous root between maxillary 1 <sup>st</sup> and 2 <sup>nd</sup> premolar.																
Right dentition									Left dentition								
Present	P	P	P	P	P	P	P	PM	P	P	P	P	P	P	P	P	P
Calculus	-	-	-	sb	-	sb	-	-	-	-	sb	-	-	smd	sm	fb	
DEH	-	-	-	-	-	-	-	-	-	-	-	-	-	-	-	-	-
Caries	-	-	-	-	-	-	-	-	-	-	-	-	-	-	-	-	-
Wear	3	3	5	3	3	3	2	-	3	2	2	3	3	5	5	3	
Maxilla	8	7	6	5	4	3	2	1	1	2	3	4	5	6	7	8	
Mandible	8	7	6	5	4	3	2	1	1	2	3	4	5	6	7	8	
Present	P	P	P	P	P	P	P	P	P	P	P	P	P	P	P	P	P
Calculus	fb	-	fb	fb	fm	sb	sl	sl	sl	sl	slm	-	-	sm	-	sd	
DEH	-	-	-	-	-	p	-	-	-	-	-	-	-	-	-	-	-
Caries	-	-	-	-	-	-	-	-	-	-	-	-	sm	-	-	-	-
Wear	3	4	5	3	3	3	3	3	3	3	3	3	3	5	4	3	
Comments	No forearms, hands, lower legs or feet.																

Skeleton Number	91 (Phase 1)															
Preservation	0															
Completeness	0-20%															
Fragmentation	Severe															
Age	Prime adult (26-35 years)															
Sex	Male															
Stature	n/d															
Non-metric traits	None															
Pathology	<p><u>Spinal joint disease</u>: 2 cervical bodies (mild osteophytes).</p> <p><u>Extra-spinal OA</u>: left medial clavicle (mild marginal osteophytes and porosity).</p> <p><u>?Lepromatous leprosy</u>: right side of nasal floor has abnormal porosity and sub-woven bone deposition; only part of right side survives, right side of nasal aperture does not survive, nor does the anterior nasal spine; there appears to be remodelling of nasal aperture on left side; left nasal floor also has sub-woven bone deposition, post-mortem damage has removed most of anterior maxillary dentition. The left and right maxilla do not belong together.</p> <p><u>Miscellaneous</u>: left clavicle has enlarged conoid tubercle.</p>															
Dental health	Considerable mandibular periodontal disease, slight to moderate maxillary periodontal disease. AMTL (1/29), calculus (21/28), caries (4/28), DEH (0/28), abscess (0/22), tooth positions (22/29). Mandibular right 1 <sup>st</sup> molar has lingual and buccal chips; mandibular 2 <sup>nd</sup> molar has mesial, lingual and distal chips. Slight rotation of mandibular left canine.															
Right dentition									Left dentition							
Present	P	P	P	P	P	P	P	P	P	-	P	P	P	P	-	-
Calculus	sbl	sbl	sbl	sbl	sbl	sd	sb	fbl	fbl	-	mb	fb	-	-	-	-
DEH	-	-	-	-	-	-	-	-	-	-	-	-	-	-	-	-
Caries	-	-	-	-	-	-	-	-	-	-	-	-	-	dmlbl	-	-
Wear	-	-	4	3	3	3	3	3	4	-	3	3	3	6	-	-
Maxilla	8	7	6	5	4	3	2	1	1	2	3	4	5	6	7	8
Mandible	8	7	6	5	4	3	2	1	1	2	3	4	5	6	7	8
Present	P	P	P	P	P	P	P	P	P	P	P	P	P	P	P	AM
Calculus	bs	-	-	bs	ls	bmm	hblm	hblm	hblm	hblm	mdl	sl	-	-	-	-
DEH	-	-	-	-	-	-	-	-	-	-	-	-	-	-	-	-
Caries	bm l	bmm s	-	-	-	-	-	-	-	-	-	-	-	-	-	-
Wear	4	5	5	4	3	3	3	3	3	3	3	3	3	6	6	-
Comments	No forearms, hands, lower legs or feet.															

Skeleton Number	92 (Phase 1)
Preservation	0
Completeness	21-40%
Fragmentation	Moderate
Age	Adult (18+ years)
Sex	Female?
Stature	n/d
Non-metric traits	Plaque (bilateral)
Pathology	<u>Spinal joint disease</u> : 6 thoracic bodies, 7 lumbar bodies, 1 sacral (mild-moderate osteophytes, porosity and Schmorl's nodes). <u>Extra-spinal joint disease</u> : right elbow, right and left auricular surface, right proximal femur (mild-moderate osteophytes)
Dental health	No surviving dentition
Intrusive bone	Yes
Comments	No lower legs or feet

Skeleton Number	93 (Phase 2)															
Preservation	0															
Completeness	81-100%															
Fragmentation	Moderate															
Age	Young adult (18-25 years)															
Sex	Male															
Stature	n/d															
Non-metric traits	Crowding of mandibular incisors, rotation of left mandibular canine.															
Pathology	<p><u>Extra-spinal joint disease</u>: right scaphoid, left trapezium, left tibia, left talus (mild osteophytes).</p> <p><u>Miscellaneous</u>: abnormal porosity on ectocranial surface of occipital, overlying nuchal crest, new bone deposition, light grey in colour.</p>															
Dental health	Slight periodontal disease. AMTL (0/11), calculus (10/11), caries (0/11), DEH (0/11), enamel chipping (0/11), abscess (0/10), tooth positions (10/11).															
Right dentition								Left dentition								
Present	-	-	-	-	P	-	-	-	-	-	-	-	-	-	-	-
Calculus	-	-	-	-	sb	-	-	-	-	-	-	-	-	-	-	-
DEH	-	-	-	-	-	-	-	-	-	-	-	-	-	-	-	-
Caries	-	-	-	-	-	-	-	-	-	-	-	-	-	-	-	-
Wear	-	-	-	-	2	-	-	-	-	-	-	-	-	-	-	-
Maxilla	8	7	6	5	4	3	2	1	1	2	3	4	5	6	7	8
Mandible	8	7	6	5	4	3	2	1	1	2	3	4	5	6	7	8
Present	-	-	-	-	P	P	P	P	P	P	P	P	P	P	-	-
Calculus	-	-	-	-	sbl	sbl	mbl	mbl	mbl	mbl	mbl	fl	Sl	-	-	-
DEH	-	-	-	-	-	-	-	-	-	-	-	-	-	-	-	-
Caries	-	-	-	-	-	-	-	-	-	-	-	-	-	-	-	-
Wear	-	-	-	-	3	2	3	3	3	3	2	2	2	5	-	-
Comments	No maxilla. Green staining on anterior body of SV1, lateral surface of right ilium, immediately proximal to rim of acetabulum. Radiocarbon dated. Sample 9, 1470-1690 cal AD (82.5% probability), 1470-1810 cal AD (95.4% probability).															

Skeleton Number	94 (Phase 1)																
Preservation	0																
Completeness	61-80%																
Fragmentation	Severe																
Age	Prime adult (26-35 years)																
Sex	Female?																
Stature	n/d																
Non-metric traits	Ossicle in lambdoid (bilateral), ossicle in coronal (bilateral), absent zygomaticofacial foramen (bilateral), supracondyloid process (left), Poirier's facet (right), vastus notch (left).																
Pathology	<p><u>Spinal joint disease</u>: 1 lumbar body (mild porosity).</p> <p><u>Extra-spinal joint disease</u>: left trapezium (lytic defect).</p> <p><u>Non-specific infection</u>: tibiae, striated lamellar bone, medial and lateral surfaces, proximal 2/3, more severe towards distal end; fibulae, striated lamellar bone, medial surface, patches of more active woven bone on distal 1/3, lateral surface.</p>																
Dental health	Moderate mandibular periodontal disease. AMTL (0/29), calculus (22/29), caries (4/29), DEH (0/29), enamel chipping (1/29), abscess (0/3), tooth positions (3/29).																
Right dentition									Left dentition								
Present	P	P	P	P	P	P	P	P	P	P	P	P	P	P	P	P	-
Calculus	-	mlsd	hb	-	fbl	sbd	sbl	sbl	fbl	fbl	sbm	-	fd	-	md	-	-
DEH	-	-	-	-	-	-	-	-	-	-	-	-	-	-	-	-	-
Caries	-	-	md	-	-	-	-	-	-	-	-	-	-	lbsl	sm	-	-
Wear	3	3	6	4	4	3	3	5	6	2	3	3	3	5	3	-	-
Maxilla	8	7	6	5	4	3	2	1	1	2	3	4	5	6	7	8	-
Mandible	8	7	6	5	4	3	2	1	1	2	3	4	5	6	7	8	-
Present	P	P	P	-	P	P	P	-	P	P	P	P	P	P	P	P	P
Calculus	-	mb	mb	-	fbl	hml	ha	-	hld	ha	mdl	-	fd	hbsm	sl	sbd	-
DEH	-	-	-	-	-	-	-	-	-	-	-	-	-	-	-	-	-
Caries	-	-	-	-	-	-	-	-	-	-	-	-	-	-	-	-	-
Wear	3	4	5	4	4	3	3	-	4	3	3	3	3	5	4	3	-
Comments	Animal tooth in grave fill. No maxilla surviving.																

Skeleton Number	95 (Phase 1)																
Preservation	1																
Completeness	0-20%																
Fragmentation	Severe																
Age	Prime adult (26-35 years)																
Sex	Male																
Stature	n/d																
Non-metric traits	Absent zygomaticofacial foramen (bilateral).																
Pathology	<u>Spinal joint disease</u> : 2 thoracic bodies, 1 lumbar body (mild-severe Schmorl's nodes).																
Dental health	Moderate mandibular and maxillary periodontal disease. AMTL (0/21), calculus (0/12), caries (0/12), DEH (0/12), enamel chipping (0/12), abscess (0/16), tooth positions (16/21).																
Right dentition									Left dentition								
Present	-	P	P	P	P	PM	PM	PM	-	-	-	-	P	P	P	-	
Calculus	-	-	-	-	-	-	-	-	-	-	-	-	-	-	-	-	
DEH	-	-	-	-	-	-	-	-	-	-	-	-	-	-	-	-	
Caries	-	-	-	-	-	-	-	-	-	-	-	-	-	-	-	-	
Wear	-	3	3	3	3	-	-	-	-	-	-	-	3	3	3	-	
Maxilla	8	7	6	5	4	3	2	1	1	2	3	4	5	6	7	8	
Mandible	8	7	6	5	4	3	2	1	1	2	3	4	5	6	7	8	
Present	-	P	P	PM	PM	PM	-	-	-	-	PM	PM	P	P	P	PM	
Calculus	-	-	-	-	-	-	-	-	-	-	-	-	-	-	-	-	
DEH	-	-	-	-	-	-	-	-	-	-	-	-	-	-	-	-	
Caries	-	-	-	-	-	-	-	-	-	-	-	-	-	-	-	-	
Wear	-	3	3	-	-	-	-	-	-	-	-	-	3	4	3	-	
Comments	No maxilla, forearms, hands, lower legs or feet. Bag containing Skull fragments is labelled as charnel, unclear why.																

Skeleton Number	96 (Phase 2)															
Preservation	1															
Completeness	21-40%															
Fragmentation	Moderate															
Age	Young adult (18-25 years)															
Sex	Male															
Stature	n/d															
Non-metric traits	Parietal foramen (bilateral), mastoid foramen extra-sutural (right), posterior atlas bridging (left).															
Pathology	<p><u>Extra-spinal joint disease</u>: left scapula, right radius and ulna, right lunate, pisiform and trapezium, right and left hands, right femur.</p> <p><u>Miscellaneous</u>: right zygomatic, abnormal porosity on ectocranial surface.</p>															
Dental health	Considerable mandibular periodontal disease. AMTL (2/28), calculus (4/23), caries (4/23), DEH (2/23), enamel chipping (0/23), abscess (0/20), tooth positions (20/28).															
Right dentition									Left dentition							
Present	P	P	P	P	P	P	-	P	P	P	P	P	P	-	P	P
Calculus	-	-	-	-	-	-	-	-	-	-	-	-	-	-	-	-
DEH	-	-	-	-	-	-	-	3L	3L	-	-	-	-	-	-	-
Caries	mm	md	-	-	-	-	-	-	-	-	-	-	-	-	-	-
Wear	2	2	3	2	2	2	-	2	2	2	2	2	2	2	2	2
Maxilla	8	7	6	5	4	3	2	1	1	2	3	4	5	6	7	8
Mandible	8	7	6	5	4	3	2	1	1	2	3	4	5	6	7	8
Present	CON	7	AM	P	P	PM	P	PM	P	P	P	PM	P	AM	P	CON
Calculus	-	-	-	-	-	-	sml	-	hb	sbm	sb	-	-	-	-	-
DEH	-	-	-	-	-	-	-	-	-	-	-	-	-	-	-	-
Caries	-	-	-	-	-	-	-	-	-	-	-	-	lodl	-	sm	-
Wear	-	2	-	2	2	-	2	-	2	2	2	-	-	-	2	-
Comments	No lower legs or feet															



Skeleton Number	97 (Phase 2)															
Preservation	1															
Completeness	81-100%															
Fragmentation	Moderate															
Age	Adult (18+ years)															
Sex	Male															
Stature	n/d															
Non-metric traits	Ossicle in coronal (bilateral), double condylar facet (left), double atlas facet (left).															
Pathology	<p><u>Spinal joint disease</u>: 2 cervical bodies, 5 cervical facets, 4 thoracic bodies, 4 lumbar bodies, 1 lumbar facet, 2 sacral facets (mild-severe osteophytes, porosity and Schmorl's nodes).</p> <p><u>Extra-spinal joint disease</u>: left scapula, left and right radius and ulna, left capitate, left and right pisiform, right scaphoid, left hands, acetabuli, femora, patellae, tibiae, fibulae, calcanei, tali, right navicular, feet.</p> <p><u>Spinal OA</u>: 1 cervical facet (mild eburnation).</p> <p><u>Extra-spinal OA</u>: left hamate (mild porosity and eburnation).</p> <p><u>Trauma</u>: 2 healed rib fractures, probable left side, located at midshaft, good apposition though significant callus survival on caudal surface.</p> <p><u>Lepromatous leprosy</u>: rhino-maxillary changes, abnormal porosity of palate, resorption of anterior sockets of maxilla with associated abnormal porosity of alveolar bone, no remodelling of anterior nasal spine or the very small surviving portion of the nasal aperture; striated lamellar bone covers medial and lateral surfaces of right tibia, distal 1/3, area of woven bone deposition overlying anterior crest at distal end, probable chronic ulcer on medial side at midpoint of shaft, demarcated by woven bone deposition and swelling of shaft; more severe on left tibia, distal 2/3 affected, 2 probable chronic ulcers, not as clearly demarcated as example on right tibia;</p> <p><u>Miscellaneous</u>: abnormal porosity on ectocranial surface of parietals, frontal bone and right zygomatic, new bone deposition across glabella and above left supra-orbital ridge, right is damaged.</p>															
Dental health	Considerable maxillary periodontal disease. AMTL (5/24), calculus (9/18), caries (7/18), DEH (3/18), enamel chipping (0/18), abscess (0/3), tooth positions (3/24). Maxillary left incisors have wear or erosion at CEJ. Four roots and 1 heavily decayed partial single rooted tooth have not been identified.															
Right dentition								Left dentition								
Present	-	-	PM	P	P	AM	P	-	P	P	AM	P	P	AM	P	P
Calculus	-	-	-	-	-	-	-	-	sl	sm	-	-	-	-	-	-
DEH	-	-	-	-	-	-	-	-	-	-	-	-	-	-	-	-
Caries	-	-	-	-	-	-	-	-	-	-	-	-	-	-	ldm	lm
Wear	-	-	-	3	3	-	5	-	5	4	-	3	3	-	3	3
Maxilla	8	7	6	5	4	3	2	1	1	2	3	4	5	6	7	8
Mandible	8	7	6	5	4	3	2	1	1	2	3	4	5	6	7	8
Present	CON	AM	AM	P	P	P	P	-	P	-	P	P	P	AM	P	CON
Calculus	-	-	-	Sbm	-	sm	mbl	-	sbl	-	hl	-	sib	-	sm	-
DEH	-	-	-	-	1L	2L	-	-	-	-	3L	-	-	-	-	-
Caries	-	-	-	Lm	sm	md	-	-	-	-	-	ppo	-	-	lb	-
Wear	-	-	-	3	3	3	3	-	3	-	3	3	3	-	4	-
Comments	Animal bone present. Green staining on dorsal surface of right 1 <sup>st</sup> proximal hand phalanx, palmar surface of left 1 <sup>st</sup> metacarpal, anterior surface of body of TV1.															

Skeleton Number	98 (Phase 2)
Preservation	1
Completeness	21-40%
Fragmentation	Moderate
Age	Adolescent (13-17 years)
Sex	n/a
Stature	n/a
Non-metric traits	None
Pathology	<u>Non-specific infection</u> : right scapula, small area of periostitis on anterior surface of blade, adjacent to glenoid.
Dental health	No surviving dentition.
Comments	No maxilla, lower legs or feet. Only a few bones of the right hand are present.

Skeleton Number	99 (Phase 1)
Preservation	0
Completeness	21-40%
Fragmentation	Moderate
Age	Adult (18+ years)
Sex	Female
Stature	n/d
Non-metric traits	None
Pathology	<u>Extra-spinal joint disease</u> : left acetabulum and femur, tibiae, left fibula.
Dental health	No surviving dentition.
Comments	No maxilla, forearms or hands. Right leg labelled as charnel is clearly part of this Skeleton. Radiocarbon dated. Sample 10, 1300-1450 cal AD (95.4% probability).

Skeleton Number	100 (Phase 1)
Preservation	2
Completeness	21-40%
Fragmentation	Severe
Age	Adult (18+ years)
Sex	Male?
Stature	n/d
Non-metric traits	None
Pathology	<u>Spinal joint disease</u> : 2 thoracic bodies, 2 lumbar bodies, 1 sacral body (mild-moderate osteophytes, porosity and Schmorl's nodes). <u>Extra-spinal OA</u> : left and right proximal femora.
Dental health	No surviving dentition
Comments	Many of bones affected by iron concretion. No maxilla, lower legs or feet. Few bones of the hands survive.

Skeleton Number	101 (Phase 2)
Preservation	0
Completeness	0-20%
Fragmentation	Severe
Age	Adult (18+ years)
Sex	Male?
Stature	n/d
Non-metric traits	None
Pathology	<p><u>Extra-spinal joint disease</u>: right acetabulum and femur, tibiae, fibulae, left talus, right navicular.</p> <p><u>?Osteomyelitis</u>: right distal ulna exhibits marked thickening of shaft, woven bone deposition, involvement of medullary cavity; tibiae, chronic infectious process, marked thickening of shafts, involvement of medullary cavities, distal 2/3 affected; right fibula is less severely affected.</p> <p><u>Non-specific infection</u>: left fibula, woven bone affecting distal 2/3 of shaft, no involvement of medullary cavity.</p>
Dental health	No surviving dentition
Comments	No maxilla, hands or feet

Skeleton Number	102 (Phase 2)
Preservation	1
Completeness	41-60%
Fragmentation	Moderate
Age	Young adult (18-25 years)
Sex	?
Stature	n/d
Non-metric traits	None
Pathology	<p><u>Non-specific infection</u>: woven bone on lateral surfaces of calcanei.</p> <p><u>Trauma</u>: right tibia, small exostosis immediately distal to proximal facet for fibula.</p>
Dental health	No surviving dentition
Comments	No maxilla

Skeleton Number	103 (Phase 2)
Preservation	0
Completeness	21-40%
Fragmentation	Moderate
Age	Adult (18+ years)
Sex	Male
Stature	n/d
Non-metric traits	Lateral tibial squatting facet (left), absent anterior calcaneal facet (bilateral).
Pathology	<u>Extra-spinal joint disease</u> : left acetabulum, right femur, right tibia, left fibula. <u>Non-specific infection</u> : woven bone on left 1 <sup>st</sup> , 3 <sup>rd</sup> and 4 <sup>th</sup> metatarsals, most severe on 3 <sup>rd</sup> , deposits measure 3 mm in thickness, active.
Dental health	No surviving dentition.
Comments	No maxilla. Animal bone in grave fill

Skeleton Number	104 (Phase 1)
Preservation	0
Completeness	61-80%
Fragmentation	Moderate
Age	Prime adult (26-35 years)
Sex	Male
Stature	n/d
Non-metric traits	Peroneal tubercle (right).
Pathology	<u>Spinal joint disease</u> : 2 thoracic bodies, 2 lumbar bodies (mild-moderate osteophytes and Schmorl's nodes). <u>Extra-spinal joint disease</u> : radii, left acetabulum, naviculars; right auricular surface has lytic defect at its centre, circular, 6.79 mm diameter, trabecular bone exposed, defect has a circle of dense bone within, corresponding ala is damaged; <u>Non-specific infection</u> : right ulna, area of active periostitis on medial surface immediately below olecranon, grey in colour; right 2 <sup>nd</sup> , 3 <sup>rd</sup> , 4 <sup>th</sup> and 5 <sup>th</sup> and left 3 <sup>rd</sup> and 5 <sup>th</sup> metacarpals have deposits of woven bone, active; left proximal 2 <sup>nd</sup> hand phalanx also affected; right tibia, active periosteal lesions on proximal 1/3 of shaft, also striated lamellar bone, medial and lateral surfaces; left tibia, diffuse patches of active periostitis combined with ?healed lesions, medial and lateral surfaces; fibulae, anterior surface, distal 2/3 of shaft, striated lamellar bone; right 1 <sup>st</sup> metatarsal, destruction of distal articulation and loss of at least 1/3 of distal shaft; right 2 <sup>nd</sup> metatarsal, severe destruction of distal articulation, proliferation of new bone; right 3 <sup>rd</sup> metatarsal, destruction of distal articulation underway; right 4 <sup>th</sup> metatarsal has abnormal porosity and a small patch of active periostitis on dorsal shaft, destruction of articulations suggestive of <u>septic arthritis</u> , probable <u>transverse arch collapse</u> ; <u>tarsal bars</u> : navicular exostoses, left and right. <u>Probable lepromatous leprosy</u> .
Dental health	No surviving dentition.
Intrusive bone	Right 4 <sup>th</sup> metatarsal, adult, missing distal end.
Comments	No maxilla

Skeleton Number	105 (Phase 1)
Preservation	0
Completeness	0-20%
Fragmentation	Moderate
Age	Adult (18+ years)
Sex	?
Stature	n/d
Non-metric traits	Septal aperture (right).
Pathology	<p><u>Spinal joint disease</u>: 9 thoracic bodies, 6 thoracic facets.</p> <p><u>Extra-spinal joint disease</u>: left manubrium, right acetabulum.</p> <p><u>Extra-spinal OA</u>: right manubrium</p> <p><u>Trauma</u>: possible compression fracture of TV12, kyphosis affects TV2-12, anterior body width 19.12 mm, posterior body width 24.57 mm. X-ray would be required to confirm this is not age-related loss of body height.</p> <p><u>Non-specific infection</u>: right radius, posterior surface, distal 1/3, striated lamellar bone, reasonably well organised reflecting process of remodelling of woven bone into bone following the healing of the periosteal lesion (Walker 2012, 35).</p>
Dental health	No surviving dentition.
Intrusive bone	Sternum, adult.
Comments	No maxilla, lower legs or feet

Skeleton Number	106 (Phase 1)
Preservation	0
Completeness	0-20%
Fragmentation	Moderate
Age	Adult (18+ years)
Sex	?
Stature	n/d
Non-metric traits	Double anterior calcaneal facet (right).
Pathology	<u>Extra-spinal joint disease</u> : left foot.
Dental health	No surviving dentition.
Intrusive bone	Skull fragments
Comments	No maxilla or forearms

Skeleton Number	107 (Phase 2)
Preservation	1
Completeness	0-20%
Fragmentation	Moderate
Age	Adult (18+ years)
Sex	Male
Stature	n/d
Non-metric traits	None
Pathology	<u>Extra-spinal joint disease</u> : left hamate, femora, left hand.
Dental health	No surviving dentition.
Comments	No maxilla, lower legs or feet. Animal bone in grave fill.

Skeleton Number	108 (Phase 1)
Preservation	1
Completeness	0-20%
Fragmentation	Severe
Age	Adult (18+ years)
Sex	?
Stature	n/d
Non-metric traits	None
Pathology	<u>Trauma</u> : right fibula, small exostosis at proximal end of shaft, posterior surface, ligament trauma.
Dental health	No surviving dentition.
Comments	No maxilla, forearms, hands or feet. Highly fragmented lower legs, no pathology identified. Probable tarsal fragments not identified.

Skeleton Number	109 (Phase 2)
Preservation	0
Completeness	0-20%
Fragmentation	Moderate
Age	Adult (18+ years)
Sex	?
Stature	n/d
Non-metric traits	None
Pathology	<u>Extra-spinal joint disease</u> : tali (mild porosity). <u>Non-specific infection</u> : new bone deposition on plantar shaft of left 3 <sup>rd</sup> , and ?4 <sup>th</sup> and right 4 <sup>th</sup> metatarsal shafts.
Dental health	No surviving dentition.
Comments	No maxilla, forearms or hands

Skeleton Number	110 (Phase 1)
Preservation	1
Completeness	21-40%
Fragmentation	Moderate
Age	Adult (18+ years)
Sex	?
Stature	n/d
Non-metric traits	None
Pathology	<u>Extra-spinal joint disease</u> : right radius and ulna, left hand (mild osteophytes). <u>Non-specific infection</u> : left 3 <sup>rd</sup> proximal foot phalanx, destruction of distal articulation, possible <u>septic arthritis</u> .
Dental health	No surviving dentition.
Comments	

Skeleton Number	111 (Phase 1)															
Preservation	1															
Completeness	0-20%															
Fragmentation	Moderate															
Age	Adult (18+ years)															
Sex	?															
Stature	n/d															
Non-metric traits	Ossicle in lambdoid (bilateral).															
Pathology	<u>Extra-spinal joint disease</u> : left clavicle (mild porosity).															
Dental health	AMTL (0/3), calculus (0/3), caries (0/3), DEH (0/3), enamel chipping (0/3), abscess (0/0), tooth positions (0/3).															
Right dentition								Left dentition								
Present	P	-	-	-	-	-	-	-	-	-	-	-	-	-	-	-
Calculus	sa	-	-	-	-	-	-	-	-	-	-	-	-	-	-	-
DEH	-	-	-	-	-	-	-	-	-	-	-	-	-	-	-	-
Caries	-	-	-	-	-	-	-	-	-	-	-	-	-	-	-	-
Wear	3	-	-	-	-	-	-	-	-	-	-	-	-	-	-	-
Maxilla	8	7	6	5	4	3	2	1	1	2	3	4	5	6	7	8
Mandible	8	7	6	5	4	3	2	1	1	2	3	4	5	6	7	8
Present	-	-	-	-	-	-	-	-	-	-	-	-	-	-	P	P
Calculus	-	-	-	-	-	-	-	-	-	-	-	-	-	-	sa	sa
DEH	-	-	-	-	-	-	-	-	-	-	-	-	-	-	-	-
Caries	-	-	-	-	-	-	-	-	-	-	-	-	-	-	-	-
Wear	-	-	-	-	-	-	-	-	-	-	-	-	-	-	-	-
Comments	No maxilla, forearms, hands, lower legs or feet															

Skeleton Number	112 (Phase 1)																
Preservation	1																
Completeness	41-60%																
Fragmentation	Moderate																
Age	Prime adult (26-35 years)																
Sex	Female																
Stature	n/d																
Non-metric traits	Ossicle in lambdoid (bilateral), ossicle in coronal (bilateral).																
Pathology	<p><u>Spinal joint disease</u>: 1 sacral body (mild porosity).</p> <p><u>Extra-spinal joint disease</u>: right ulna, left femur.</p> <p><u>Non-specific infection</u>: right 1<sup>st</sup> proximal hand phalanx, small area of new bone deposition on dorsal shaft, volar groove on palmar surface; right 2<sup>nd</sup> proximal hand phalanx, small area of new bone deposition on medial and lateral sides; right 3<sup>rd</sup> proximal hand phalanx has probable volar groove; right 4<sup>th</sup> proximal hand phalanx, destruction of distal articulation, abnormal porosity; right 4<sup>th</sup> intermediate hand phalanx, destruction of proximal articulation; right 5<sup>th</sup> proximal hand phalanx, probable volar groove; destruction of articulations suggestive of <u>septic arthritis</u>; increased porosity on right side of palate. <u>Probable lepromatous leprosy</u>.</p>																
Dental health	Moderate maxillary and mandibular periodontal disease. AMTL (0/25), calculus (19/25), caries (0/25), DEH (0/25), enamel chipping (1/25), abscess (0/13), tooth positions (13/25). Identification of mandibular left premolars is uncertain. Both are microdontic with bent roots.																
Right dentition									Left dentition								
Present	-	P	P	P	P	P	P	P	P	P	P	P	P	P	P	P	-
Calculus	-	-	fb	sbl	sd	mb	sm	-	fb	-	sb	sb	sm	sb	-	-	
DEH	-	-	-	-	-	-	-	-	-	-	-	-	-	-	-	-	
Caries	-	-	-	-	-	-	-	-	-	-	-	-	-	-	-	-	
Wear	-	3	5	3	3	2	2	3	2	3	2	3	3	5	3	-	
Maxilla	8	7	6	5	4	3	2	1	1	2	3	4	5	6	7	8	
Mandible	8	7	6	5	4	3	2	1	1	2	3	4	5	6	7	8	
Present	-	P	P	P	P	P	P	P	P	P	-	P	P	-	-	CON	
Calculus	-	sb	sbl	sld	fb	sb	md	mhbld	hbld	hb	-	-	-	-	-	-	
DEH	-	-	-	-	-	-	-	-	-	-	-	-	-	-	-	-	
Caries	-	-	-	-	-	-	-	-	-	-	-	-	-	-	-	-	
Wear	-	3	5	4	4	3	3	3	3	3	-	3	3	-	-	-	
Intrusive bone	Proximal half of right ulna, adult, preservation 1, completeness 50%.																
Comments	Anterior maxilla does not survive. No lower legs or feet.																



Skeleton Number	113 (Phase 1)
Preservation	0
Completeness	21-40%
Fragmentation	Severe
Age	Adult (18+ years)
Sex	Male?
Stature	n/d
Non-metric traits	None
Pathology	<p><u>Extra-spinal joint disease</u>: left, clavicle, humerus, radius, hamate, left hand, calcaneus, cuboids, medial cuneiforms, left lateral cuneiform, left foot.</p> <p><u>Extra-spinal OA</u>: left scapula (moderate osteophytes, porosity and eburnation, lytic defects).</p> <p><u>Miscellaneous</u>: New bone on fragment of left fibula, enthesal rather than infectious.</p>
Dental health	No surviving dentition.
Intrusive bone	
Comments	No maxilla or left hand, little of lower legs survive.

Skeleton Number	114 (Phase 2)
Preservation	0
Completeness	0-20%
Fragmentation	Moderate
Age	Adult (18+ years)
Sex	?
Stature	n/d
Non-metric traits	Double anterior calcaneal facet (bilateral), double inferior talar facet (bilateral).
Pathology	<u>Extra-spinal joint disease</u> : left lateral cuneiform, left foot (mild osteophytes).
Dental health	No surviving dentition.
Comments	No maxilla, forearms or hands

Skeleton Number	115 (Phase 1)
Preservation	1
Completeness	0-20%
Fragmentation	Moderate
Age	Adult (18+ years)
Sex	?
Stature	n/d
Non-metric traits	None
Pathology	None
Dental health	No surviving dentition.
Comments	No maxilla or forearms

Skeleton Number	116 (Phase 2)															
Preservation	1															
Completeness	21-40%															
Fragmentation	Moderate															
Age	Adult (18+ years)															
Sex	Male?															
Stature	n/d															
Non-metric traits	None															
Pathology	<u>Extra-spinal joint disease</u> : left hamate and trapezoid (mild osteophytes).															
Dental health	AMTL (0/3), calculus (3/3), caries (0/3), DEH (1/3), enamel chipping (0/3), abscess (0/0), tooth positions (0/3).															
Right dentition								Left dentition								
Present	-	-	-	-	-	-	-	-	-	-	-	-	-	-	-	-
Calculus	-	-	-	-	-	-	-	-	-	-	-	-	-	-	-	-
DEH	-	-	-	-	-	-	-	-	-	-	-	-	-	-	-	-
Caries	-	-	-	-	-	-	-	-	-	-	-	-	-	-	-	-
Wear	-	-	-	-	-	-	-	-	-	-	-	-	-	-	-	-
Maxilla	8	7	6	5	4	3	2	1	1	2	3	4	5	6	7	8
Mandible	8	7	6	5	4	3	2	1	1	2	3	4	5	6	7	8
Present	-	-	-	-	P	P	P	-	-	-	-	-	-	-	-	-
Calculus	-	-	-	-	fmd	fbdm	lsm	-	-	-	-	-	-	-	-	-
DEH	-	-	-	-	-	-	-	-	-	-	-	-	-	-	-	-
Caries	-	-	-	-	-	-	-	-	-	-	-	-	-	-	-	-
Wear	-	-	-	-	3	3	4	-	-	-	-	-	-	-	-	-
Comments	No maxilla															

Skeleton Number	118 (Phase 1)															
Preservation	1															
Completeness	0-20%															
Fragmentation	Severe															
Age	Young adult (18-25 years)															
Sex	Male?															
Stature	n/d															
Non-metric traits	None															
Pathology	<p><u>Spinal joint disease</u>: 1 thoracic body (moderate Schmorl's nodes).</p> <p><u>?Lepromatous leprosy</u>: rhino-maxillary changes, abnormal porosity on left side of palate, probable remodelling of surviving portion of nasal aperture, edges are smoothed, slight pitting of palatine process, only part of left side survives, inflammatory pitting of left nasal aperture, severe recession of alveolar process around socket for maxillary left 1<sup>st</sup> incisor.</p> <p><u>Maxillary sinusitis</u>: spicules of irregular new bone on medial side of left maxillary sinus, right does not survive.</p>															
Dental health	AMTL (5/6), calculus (0/1), caries (0/1), DEH (0/1), enamel chipping (0/1), abscess (0/6), tooth positions (6/6).															
Right dentition									Left dentition							
Present	-	-	-	-	-	-	-	-	AM	AM	R	AM	AM	AM	-	-
Calculus	-	-	-	-	-	-	-	-	-	-	-	-	-	-	-	-
DEH	-	-	-	-	-	-	-	-	-	-	-	-	-	-	-	-
Caries	-	-	-	-	-	-	-	-	-	-	-	-	-	-	-	-
Wear	-	-	-	-	-	-	-	-	-	-	-	-	-	-	-	-
Maxilla	8	7	6	5	4	3	2	1	1	2	3	4	5	6	7	8
Mandible	8	7	6	5	4	3	2	1	1	2	3	4	5	6	7	8
Present	-	-	-	-	-	-	-	-	-	-	-	-	-	-	-	-
Calculus	-	-	-	-	-	-	-	-	-	-	-	-	-	-	-	-
DEH	-	-	-	-	-	-	-	-	-	-	-	-	-	-	-	-
Caries	-	-	-	-	-	-	-	-	-	-	-	-	-	-	-	-
Wear	-	-	-	-	-	-	-	-	-	-	-	-	-	-	-	-
Comments	No lower legs or feet															

Skeleton Number	119 (Phase 1)															
Preservation	1															
Completeness	0-20%															
Fragmentation	Severe															
Age	Adolescent (16-18 years)															
Sex	n/a															
Stature	n/a															
Non-metric traits	None															
Pathology	None															
Dental health	No surviving dentition.															
Comments	No maxilla, forearms, hands, lower legs or feet															

Skeleton Number	120 (Phase 2)															
Preservation	1															
Completeness	81-100%															
Fragmentation	Slight															
Age	Older adult (45+ years)															
Sex	Male															
Stature	n/d															
Non-metric traits	Ossicle in coronal (bilateral), maxillary torus (left), double anterior calcaneal facet (left), double inferior talar facet (left).															
Pathology	<p><u>Spinal joint disease</u>: 5 cervical bodies, 8 thoracic bodies, 2 thoracic facets, 5 lumbar bodies, 18 lumbar facets, 1 sacral body, 2 sacral facets (mild-severe osteophytes, porosity and Schmorl's nodes). TV11 and 12, new bone deposition.</p> <p><u>Extra-spinal joint disease</u>: right clavicle, scapula, right and left humerus, radius and ulna, left lunate, right acetabulum, femur, patella, left fibula, right foot.</p> <p><u>Spinal OA</u>: 1 cervical facet (mild eburnation).</p> <p>?<u>Lepromatous leprosy</u>: possible rhino-maxillary changes, abnormal porosity on left and right palatine process, very little of nasal aperture survives, possible remodelling on left side, bone in region of anterior maxillary dentition is much resorbed, no change to nasal floor.</p> <p><u>Miscellaneous</u>: left fibula, distal end, immediately above malleolus, linear defect in shaft, new bone within it, margins of the defect are well demarcated.</p>															
Dental health	Considerable mandibular periodontal disease. AMTL (13/19), calculus (2/5), caries (2/5), DEH (0/5), enamel chipping (0/5), abscess (1/5), tooth positions (18/19). Probable externally draining abscess located at socket for mandibular right 1 <sup>st</sup> molar, sharp-walled, max. diameter 9.12 mm, abnormal porosity of surrounding bone.															
Right dentition									Left dentition							
Present	-	-	-	-	-	-	-	-	AM	AM	AM	AM	AM	AM	-	-
Calculus	-	-	-	-	-	-	-	-	-	-	-	-	-	-	-	-
DEH	-	-	-	-	-	-	-	-	-	-	-	-	-	-	-	-
Caries	-	-	-	-	-	-	-	-	-	-	-	-	-	-	-	-
Wear	-	-	-	-	-	-	-	-	-	-	-	-	-	-	-	-
Maxilla	8	7	6	5	4	3	2	1	1	2	3	4	5	6	7	8
Mandible	8	7	6	5	4	3	2	1	1	2	3	4	5	6	7	8
Present	AM	AM	P	AM	AM	P	P	-	-	-	PM	AM	P	AM	P	AM
Calculus	-	-	hd lb m	-	-	hbl	mb dm	-	-	-	-	-	fm	-	fd	-
DEH	-	-	-	-	-	-	-	-	-	-	-	-	-	-	-	-
Caries	-	-	L m	-	-	-	-	-	-	-	-	-	-	-	lb md	-
Wear	-	-	-	-	-	-	-	-	-	-	-	-	-	-	-	-
Comments	Radiocarbon dated. Sample 8, 1300-1450 cal AD (95.4% probability).															

Skeleton Number	121 (Phase 1)																
Preservation	1																
Completeness	0-20%																
Fragmentation	Severe																
Age	Prime adult (26-35 years)																
Sex	Female?																
Stature	n/d																
Non-metric traits	Absent zygomaticofacial foramen (right).																
Pathology	<u>Spinal joint disease</u> : 6 cervical bodies, 1 cervical facet (mild-moderate osteophytes and porosity). <u>Extra-spinal joint disease</u> : left scapula (mild osteophytes). <u>Spinal OA</u> : anterior surface of odontoid peg (moderate eburnation).																
Dental health	Considerable maxillary and mandibular periodontal disease. AMTL (6/24), calculus (4/14), caries (6/14), DEH (0/14), enamel chipping (0/14), abscess (0/16), tooth positions (16/24).																
Right dentition									Left dentition								
Present	-	P	AM	P	P	P	AM	AM	P	PM	PM	P	-	P	P	P	
Calculus	-	-	-	-	-	-	-	-	-	-	-	sbd	-	-	-	-	
DEH	-	-	-	-	-	-	-	-	-	-	-	-	-	-	-	-	
Caries	-	mm	-	lo	lo	-	-	-	-	-	-	mm	-	-	-	-	
Wear	-	5	-	-	-	6	-	-	6	-	-	5	-	6	5	4	
Maxilla	8	7	6	5	4	3	2	1	1	2	3	4	5	6	7	8	
Mandible	8	7	6	5	4	3	2	1	1	2	3	4	5	6	7	8	
Present	P	AM	AM	P	P	-	P	P	-	P	-	-	-	AM	AM	AM	
Calculus	-	-	-	sbm	-	-	sd	sd	-	-	-	-	-	-	-	-	
DEH	-	-	-	-	-	-	-	-	-	-	-	-	-	-	-	-	
Caries	mm	-	-	-	-	-	-	-	-	la	-	-	-	-	-	-	
Wear	7	-	-	5	6	-	-	5	5	-	-	-	-	-	-	-	
Comments	No forearms, hands, lower legs or feet.																

Skeleton Number	122 (Phase 2)																
Preservation	2																
Completeness	21-40%																
Fragmentation	Severe																
Age	Adult (18+ years)																
Sex	?																
Stature	n/d																
Non-metric traits	Septal aperture (right).																
Pathology	<u>Extra-spinal joint disease</u> : right ulna (mild osteophytes). <u>Non-specific infection</u> : left tibia, area of woven bone on medial surface, midshaft.																
Dental health	No surviving dentition.																
Comments	No maxilla or feet																

Skeleton Number	123 (Phase 2)
Preservation	1
Completeness	0-20%
Fragmentation	Severe
Age	Adult (18+ years)
Sex	?
Stature	n/d
Non-metric traits	None
Pathology	<u>Non-specific infection</u> : left 1 <sup>st</sup> proximal foot phalanx has increased porosity, diffuse patches of periostitis on plantar and dorsal surfaces; left 2 <sup>nd</sup> distal foot phalanx, destruction of head, probable <u>septic arthritis</u> , new bone deposition on dorsal surface.
Dental health	No surviving dentition.
Intrusive bone	Additional right foot and right leg fragments, gross pathological change. Context sheet demonstrates that there was no right foot.
Comments	No maxilla, forearms, hands or lower legs

Skeleton Number	124 (Phase 2)																
Preservation	1																
Completeness	41-60%																
Fragmentation	Extreme																
Age	Adult (18+ years)																
Sex	?																
Stature	n/d																
Non-metric traits	Double inferior talar facet (left).																
Pathology	<p><u>Spinal joint disease</u>: 2 thoracic facets, 1 lumbar body, 1 lumbar facet (moderate osteophytes and porosity).</p> <p><u>Extra-spinal joint disease</u>: femora, left patella.</p> <p><u>Spinal OA</u>: 4 lumbar facets (moderate osteophytes and eburnation).</p>																
Dental health	Moderate mandibular periodontal disease. AMTL (0/8), calculus (3/5), caries (0/5), DEH (0/5), enamel chipping (0/5), abscess (0/6), tooth positions (6/8).																
Right dentition									Left dentition								
Present	-	-	-	-	-	-	-	P	P	-	-	-	-	-	-	-	-
Calculus	-	-	-	-	-	-	-	-	-	-	-	-	-	-	-	-	-
DEH	-	-	-	-	-	-	-	-	-	-	-	-	-	-	-	-	-
Caries	-	-	-	-	-	-	-	-	-	-	-	-	-	-	-	-	-
Wear	-	-	-	-	-	-	4	4	-	-	-	-	-	-	-	-	
Maxilla	8	7	6	5	4	3	2	1	1	2	3	4	5	6	7	8	
Mandible	8	7	6	5	4	3	2	1	1	2	3	4	5	6	7	8	
Present	-	-	-	-	-	-	-	-	-	-	P	PM	PM	PM	P	P	
Calculus	-	-	-	-	-	-	-	-	-	-	hb	-	-	-	smb	sdb	
DEH	-	-	-	-	-	-	-	-	-	-	-	-	-	-	-	-	
Caries	-	-	-	-	-	-	-	-	-	-	-	-	-	-	-	-	
Wear	-	-	-	-	-	-	-	-	-	-	3	-	-	-	5	4	
Comments	No maxilla																

Skeleton Number	125 (Phase 1)															
Preservation	0															
Completeness	0-20%															
Fragmentation	Severe															
Age	Young adult (18-25 years)															
Sex	Female															
Stature	n/d															
Non-metric traits	None															
Pathology	<p><u>Spinal joint disease</u>: 2 thoracic bodies (moderate Schmorl's nodes).</p> <p><u>Miscellaneous</u>: left 1<sup>st</sup> proximal hand phalanx, proximal articulation is very mis-shapen, cause unclear.</p>															
Dental health	AMTL (0/16), calculus (4/11), caries (1/11), DEH (0/11), enamel chipping (0/11), abscess (0/14), tooth positions (14/16).															
Right dentition								Left dentition								
Present	-	-	-	-	-	-	-	-	-	-	-	-	-	P	P	P
Calculus	-	-	-	-	-	-	-	-	-	-	-	-	-	-	-	-
DEH	-	-	-	-	-	-	-	-	-	-	-	-	-	-	-	-
Caries	-	-	-	-	-	-	-	-	-	-	-	-	-	sl	-	-
Wear	-	-	-	-	-	-	-	-	-	-	-	-	-	3	3	3
Maxilla	8	7	6	5	4	3	2	1	1	2	3	4	5	6	7	8
Mandible	8	7	6	5	4	3	2	1	1	2	3	4	5	6	7	8
Present	P	P	P	-	P	P	PM	PM	PM	PM	PM	-	-	P	P	P
Calculus	sm	sl	slm	-	smd	-	-	-	-	-	-	-	-	-	-	-
DEH	-	-	-	-	-	-	-	-	-	-	-	-	-	-	-	-
Caries	-	-	-	-	-	-	-	-	-	-	-	-	-	-	-	-
Wear	3	3	4	-	3	3	-	-	-	-	-	-	-	4	3	3
Comments	No maxilla, lower legs or feet. Animal bone in grave fill.															

Skeleton Number	126 (Phase 2)															
Preservation	1															
Completeness	41-60%															
Fragmentation	Severe															
Age	Older adult (45+ years)															
Sex	Female															
Stature	n/d															
Non-metric traits	Transverse foramen bipartite (left).															
Pathology	<p><u>Spinal joint disease</u>: 1 cervical body, 1 cervical facet, 1 sacral facet (mild osteophytes).</p> <p><u>Extra-spinal joint disease</u>: left clavicle, right radius and ulna, right hamate (mild osteophytes).</p> <p><u>Non-specific infection</u>: right radius, small patch of striated lamellar bone on anterior surface, midshaft; left tibia, 2 fragments, striated lamellar bone, also woven bone which appears to be in the process of remodelling, lateral and medial surfaces, midshaft; right tibia, fragment of midshaft, striated lamellar bone, lateral surface, well remodelled.</p>															
Dental health	No surviving dentition.															
Comments	No maxilla or feet															



Skeleton Number	127 (Phase 1)															
Preservation	2															
Completeness	61-80%															
Fragmentation	Severe (fragmentation of right leg is extreme)															
Age	Adult (18+ years)															
Sex	Male?															
Stature	n/d															
Non-metric traits	Double anterior calcaneal facet (bilateral).															
Pathology	<p><u>Spinal joint disease</u>: 3 cervical bodies, 1 thoracic body, 5 thoracic facets, 5 lumbar bodies (mild-severe osteophytes, porosity and Schmorl's nodes).</p> <p><u>Extra-spinal joint disease</u>: right scapula, right and left humerus, left radius, left and right capitate, hamate, right lunate, scaphoid, trapezium, right trapezoid and triquetral, right and left hands, fibulae, calcanei, left talus, left cuboids, left navicular, intermediate cuneiforms, left foot.</p> <p><u>Extra-spinal OA</u>: left lunate, left and right hips, right proximal tibia, right cuboid, left medial cuneiform. Exostosis on dorsal rim of left navicular.</p> <p><u>Trauma</u>: left 2<sup>nd</sup> metacarpal has healed fracture of proximal shaft, shaft is thickened, quite poor apposition of ends, bone is angulated in a palmar direction; Probable 7<sup>th</sup> right rib has moderate degenerative change at sternal end, also abnormally angulated at the head end, possible fracture.</p> <p>DISH: TV4-12, large flowing osteophytes from calcification of anterior longitudinal ligament down right side of spine, intervertebral joint spaces have been maintained, no surviving apophyseal joint, LV1-5 also affected, although joint spaces not maintained, fusion of lumbar vertebrae on left side as well as right; the changes to the lumbar vertebrae are seen in other types of spondylo-arthropathy such as ankylosing spondylitis. An X-ray would be desirable.</p> <p>Marked enthesal change affecting femora, tibiae, fibulae, left patella, iliac crest, left and right acetabulum, no sacro-iliac joint or ischial tuberosities.</p>															
Dental health	AMTL (0/6), calculus (2/2), caries (2/2), DEH (0/2), enamel chipping (0/2), abscess (1/5), tooth positions (5/6). Externally draining abscess located at 2 <sup>nd</sup> left mandibular incisor, smooth-walled, irregular perforation, max. diameter 4.15 mm.															
Right dentition								Left dentition								
Present	-	P	-	-	-	-	-	-	-	-	-	-	-	-	-	-
Calculus	-	-	-	-	-	-	-	-	-	-	-	-	-	-	-	-
DEH	-	-	-	-	-	-	-	-	-	-	-	-	-	-	-	-
Caries	-	sb	-	-	-	-	-	-	-	-	-	-	-	-	-	-
Wear	-	6	-	-	-	-	-	-	-	-	-	-	-	-	-	-
Maxilla	8	7	6	5	4	3	2	1	1	2	3	4	5	6	7	8
Mandible	8	7	6	5	4	3	2	1	1	2	3	4	5	6	7	8
Present	-	-	-	-	-	-	-	-	-	P	-	-	-	-	-	-
Calculus	-	-	-	-	-	-	-	-	-	Sb	-	-	-	-	-	-
DEH	-	-	-	-	-	-	-	-	-	-	-	-	-	-	-	-
Caries	-	-	-	-	-	-	-	-	-	ld	-	-	-	-	-	-
Wear	-	-	-	-	-	-	-	-	-	5	-	-	-	-	-	-
Comments	No maxilla															

Skeleton Number	128 (Phase 1)															
Preservation	1															
Completeness	61-80%															
Fragmentation	Extreme															
Age	Prime adult (26-35 years)															
Sex	Male															
Stature	n/d															
Non-metric traits	Ossicle in lambdoid (bilateral), ossicle in coronal (bilateral).															
Pathology	<p><u>Spinal joint disease</u>: 5 cervical bodies, 10 thoracic bodies, 1 sacral (mild-moderate osteophytes, porosity and Schmorl's nodes).</p> <p><u>Extra-spinal joint disease</u>: left medial clavicle.</p> <p><u>Extra-spinal OA</u>: right lateral clavicle, left and right acetabulum and left femur, feet (mild osteophytes and eburnation).</p> <p><u>Non-specific infection</u>: diffuse areas of striated lamellar bone on distal half of tibiae shafts, medial and lateral surfaces; fibulae, striated lamellar bone, distal 1/3, medial surface.</p>															
Dental health	Moderate mandibular and maxillary periodontal disease. AMTL (0/25), calculus (19/22), caries (2/22), DEH (0/22), enamel chipping (0/22), abscess (0/15), tooth positions (15/25).															
Right dentition								Left dentition								
Present	P	P	P	P	P	P	P	-	-	PM	P	P	P	P	P	-
Calculus	-	bs	-	ls	ls	bls	bls	-	-	-	bls	ls	bm	bm	bm	-
DEH	-	-	-	-	-	-	-	-	-	-	-	-	-	-	-	-
Caries	mlb	dm	-	-	-	-	-	-	-	-	-	-	-	-	-	-
Wear	2	4	5	5	5	4	4	-	-	-	5	4	4	4	3	-
Maxilla	8	7	6	5	4	3	2	1	1	2	3	4	5	6	7	8
Mandible	8	7	6	5	4	3	2	1	1	2	3	4	5	6	7	8
Present	CON	P	P	P	P	P	-	P	-	P	PM	PM	R	P	P	CON
Calculus	-	ms	msb	bs	ms	bmds	-	sbl	-	bls	-	-	-	bs	bms	-
DEH	-	-	-	-	-	-	-	-	-	-	-	-	-	-	-	-
Caries	-	-	-	-	-	-	-	-	-	-	-	-	-	-	-	-
Wear	-	5	6	4	4	4	-	5	-	4	-	-	-	6	5	-
Intrusive bone	1 left 3 <sup>rd</sup> metacarpal, proximal 1/3, adult, 50%, 1.															
Comments	No maxilla or hands. Animal bone tooth and shaft fragment in grave fill.															

Skeleton Number	129 (Phase 1)
Preservation	1
Completeness	0-20%
Fragmentation	Severe
Age	Prime adult (26-35 years)
Sex	Male
Stature	n/d
Non-metric traits	Ossicle in coronal (bilateral), sutural mastoid foramen (left).
Pathology	<u>Spinal joint disease</u> : 9 thoracic bodies, 5 thoracic facets (mild osteophytes and porosity). <u>Extra-spinal joint disease</u> : clavicles, right scapula, right ulna.
Dental health	No surviving dentition.
Comments	No maxilla, lower legs or feet. Two animal rib shaft fragments. Bones of the right hand are much lighter in colour than the rest of the Skeleton.

Skeleton Number	130 (phase1)															
Preservation	2															
Completeness	0-20%															
Fragmentation	Severe															
Age	Adult (18+ years)															
Sex	?															
Stature	n/d															
Non-metric traits	None															
Pathology	<u>Spinal joint disease</u> : 1 cervical body, 2 cervical facets (mild osteophytes), possible lytic lesion on posterior surface of axis body. Nodule of bone, oval in shape, located on medial side between facets on right side. <u>Non-specific infection</u> : left fibula, 2 conjoining fragments, distal half, woven bone deposition, medial and anterior surfaces, diffuse, same on right fibula.															
Dental health	AMTL (0/2), calculus (2/2), caries (0/2), DEH (0/2), enamel chipping (0/2), abscess (0/2), tooth positions (0/2).															
Right dentition									Left dentition							
Present	-	-	-	-	-	-	-	-	-	-	-	-	-	-	-	-
Calculus	-	-	-	-	-	-	-	-	-	-	-	-	-	-	-	-
DEH	-	-	-	-	-	-	-	-	-	-	-	-	-	-	-	-
Caries	-	-	-	-	-	-	-	-	-	-	-	-	-	-	-	-
Wear	-	-	-	-	-	-	-	-	-	-	-	-	-	-	-	-
Maxilla	8	7	6	5	4	3	2	1	1	2	3	4	5	6	7	8
Mandible	8	7	6	5	4	3	2	1	1	2	3	4	5	6	7	8
Present	-	-	-	-	-	-	-	-	-	-	P	-	P	-	-	-
Calculus	-	-	-	-	-	-	-	-	-	-	sb	-	sb	-	-	-
DEH	-	-	-	-	-	-	-	-	-	-	-	-	-	-	-	-
Caries	-	-	-	-	-	-	-	-	-	-	-	-	-	-	-	-
Wear	-	-	-	-	-	-	-	-	-	-	3	-	3	-	-	-
Comments	No maxilla, forearms, hands or feet															

Skeleton Number	132 (Phase 2)															
Preservation	0															
Completeness	61-80%															
Fragmentation	Severe															
Age	Younger juvenile (3-5 years)															
Sex	n/a															
Stature	n/a															
Non-metric traits	None															
Pathology	<p><u>Non-specific infection</u>: abnormal porosity of left palate, no surviving nasal aperture; right tibia, portion of midshaft has striated lamellar bone on medial surface; same on left tibia, highly fragmented, surface not determined; right fibula, distal 2/3, anterior surface; left fibula similarly affected, highly fragmented.</p> <p><u>Maxillary sinusitis</u>: small area of new bone deposition, left sinus, right does not survive</p>															
Dental health	AMTL (0/17), calculus (4/17), caries (0/17), DEH (0/17), enamel chipping (0/17), abscess (0/6), tooth positions.															
Right dentition									Left dentition							
Present		UE	UE	P	-	P	-	P	P	P	P	P	P	UE	UE	
Calculus		-	-	sob	-	-	-	-	-	-	-	fb	fb	-	-	
DEH		-	-	-	-	-	-	-	-	-	-	-	-	-	-	
Caries		-	-	-	-	-	-	-	-	-	-	-	-	-	-	
Wear		-	-	2	2	2	2	2	2	2	2	2	2	-	-	
Maxilla	8	7	6	e	d	c	b	a	a	b	c	d	e	6	7	8
Mandible	8	7	6	e	d	c	b	a	a	b	c	d	e	6	7	8
Present		-	P	P	P	P	P	P	P	P	-	P	P	UE	-	
Calculus		-	-	-	-	-	-	-	-	-	-	fm	-	-	-	
DEH		-	-	-	-	-	-	-	-	-	-	-	-	-	-	
Caries		-	-	-	-	-	-	-	-	-	-	-	-	-	-	
Wear		-	-	2	2	2	2	2	2	2	2	2	2	-	-	
Comments	No maxilla, forearms, hands or feet. Radiocarbon dated. Sample 11, 1411-1486 cal AD (95.4% probability).															

Skeleton Number	133 (Phase 1)															
Preservation	0															
Completeness	21-40%															
Fragmentation	Severe															
Age	Young adult (18-25 years)															
Sex	Male?															
Stature	n/d															
Non-metric traits	Vastus notch (left)															
Pathology	None															
Dental health	AMTL (0/1), calculus (0/1), caries (0/1), DEH (0/1), enamel chipping, abscess (0/0), tooth positions (0/1).															
Right dentition								Left dentition								
Present	-	-	-	-	-	-	-	-	-	-	-	-	-	-	-	-
Calculus	-	-	-	-	-	-	-	-	-	-	-	-	-	-	-	-
DEH	-	-	-	-	-	-	-	-	-	-	-	-	-	-	-	-
Caries	-	-	-	-	-	-	-	-	-	-	-	-	-	-	-	-
Wear	-	-	-	-	-	-	-	-	-	-	-	-	-	-	-	-
Maxilla	8	7	6	5	4	3	2	1	1	2	3	4	5	6	7	8
Mandible	8	7	6	5	4	3	2	1	1	2	3	4	5	6	7	8
Present	-	-	-	P	-	-	-	-	-	-	-	-	-	-	-	-
Calculus	-	-	-	-	-	-	-	-	-	-	-	-	-	-	-	-
DEH	-	-	-	-	-	-	-	-	-	-	-	-	-	-	-	-
Caries	-	-	-	-	-	-	-	-	-	-	-	-	-	-	-	-
Wear	-	-	-	4	-	-	-	-	-	-	-	-	-	-	-	-
Comments	No maxilla, lower legs or feet															

Skeleton Number	134 (Phase 1)															
Preservation	0															
Completeness	0-20%															
Fragmentation	Severe															
Age	Adult (18+ years)															
Sex	Male															
Stature	n/d															
Non-metric traits	None															
Pathology	<u>Spinal joint disease</u> : 1 sacral facet (mild osteophytes). <u>Extra-spinal joint disease</u> : right acetabulum <u>Trauma</u> : spondylolysis of LV5, left side, right is normal.															
Dental health	No surviving dentition.															
Comments	No maxilla, lower legs or feet															

Skeleton Number	135 (Phase 2)															
Preservation	0															
Completeness	21-40%															
Fragmentation	Severe															
Age	Adult (18+ years)															
Sex	Male															
Stature	n/d															
Non-metric traits	None															
Pathology	<p><u>Spinal joint disease</u>: 2 cervical bodies, 1 cervical facet, 6 thoracic bodies, 4 thoracic facets (mild-severe osteophytes, porosity and Schmorl's nodes).</p> <p><u>Extra-spinal joint disease</u>: clavicles, right scapula, left radius, left hand.</p> <p><u>Non-specific infection</u>: right radius, midshaft, posterior surface, small patch of striated lamellar bone, posterior to interosseous crest, healed.</p>															
Dental health	AMTL (0/6), calculus (0/6), caries (2/6), DEH (0/6), enamel chipping (0/6), abscess (0/0), tooth positions (0/6).															
Right dentition									Left dentition							
Present	-	-	-	-	-	-	-	-	-	-	-	-	-	-	-	-
Calculus	-	-	-	-	-	-	-	-	-	-	-	-	-	-	-	-
DEH	-	-	-	-	-	-	-	-	-	-	-	-	-	-	-	-
Caries	-	-	-	-	-	-	-	-	-	-	-	-	-	-	-	-
Wear	-	-	-	-	-	-	-	-	-	-	-	-	-	-	-	-
Maxilla	8	7	6	5	4	3	2	1	1	2	3	4	5	6	7	8
Mandible	8	7	6	5	4	3	2	1	1	2	3	4	5	6	7	8
Present	-	-	-	-	-	-	p	p	p	p	p	-	-	-	-	p
Calculus	-	-	-	-	-	-	-	-	-	-	-	-	-	-	-	-
DEH	-	-	-	-	-	-	-	-	-	-	-	-	-	-	-	-
Caries	-	-	-	-	-	-	sm	-	-	-	-	-	-	-	-	lm
Wear	-	-	-	-	-	-	6	6	6	6	6	-	-	-	-	6
Comments	No maxilla, lower legs or feet															

Skeleton Number	136 (Phase 1)
Preservation	0
Completeness	21-40%
Fragmentation	Slight
Age	Adolescent (13-17 years)
Sex	n/a
Stature	n/a
Non-metric traits	Double anterior calcaneal facet (right).
Pathology	<u>Non-specific infection</u> : left tibia, area of active periostitis on lateral side of shaft, medial third, anterior to interosseous crest, striated lamellar bone running length of medial shaft; right tibia has area of active periostitis with well-defined margins, medial surface at distal end, broadly oval in shape, probable chronic ulcer, striated lamellar bone running length of medial shaft; fibulae, striated lamellar bone running length of medial shaft; lateral side of right fibula, proximal 1/3 of shaft, area of active periostitis associated with slight periostitis associated with slight swelling of shafts, margins are well defined, probable chronic ulcer; right 1 <sup>st</sup> metatarsal, marked destruction of distal articulation, shaft is severely thickened, possible <u>osteomyelitis</u> , dorsal surface of midshaft has abnormal porosity and woven bone at midshaft; right 1 <sup>st</sup> proximal foot phalanx, abnormal porosity on dorsal shaft; right 1 <sup>st</sup> distal phalanx, slight destruction of distal end, abnormal porosity and woven bone on dorsal shaft, possible <u>septic arthritis</u> ; left 5 <sup>th</sup> intermediate and distal foot phalanges are fused, possible <u>claw toe deformity</u> . Probable <u>lepromatous leprosy</u> .
Dental health	No surviving dentition.
Comments	No maxilla, forearms or hands

Skeleton Number	137 (Phase 2)
Preservation	1
Completeness	61-80%
Fragmentation	Moderate
Age	Adult (18+ years)
Sex	Male
Stature	n/d
Non-metric traits	None
Pathology	<u>Spinal joint disease</u> : 3 thoracic bodies, 1 lumbar body, 1 sacral body (mild-severe osteophytes, porosity and Schmorl's nodes). <u>Extra-spinal joint disease</u> : humeri, radii, ulnae, left trapezoid, acetabuli, femora, tibiae, left cuboid, feet. <u>Extra-spinal OA</u> : radii, ulna, lunates, right femur, patellae and tibiae (osteophytes, porosity, lytic defects and eburnation). <u>Non-specific infection</u> : left and right 1 <sup>st</sup> metatarsal, abnormal porosity and woven bone on plantar surface, distal end; left 4 <sup>th</sup> proximal foot phalanx, ?destructive remodelling of distal articulation, possible <u>septic arthritis</u> , abnormal porosity of plantar surface.
Dental health	No surviving dentition.
Comments	No maxilla

Skeleton Number	138 (Phase 1)
Preservation	0
Completeness	0-20%
Fragmentation	Severe
Age	Adult (18+ years)
Sex	?
Stature	n/d
Non-metric traits	None
Pathology	<u>Extra-spinal joint disease</u> : left talus (mild osteophytes).
Dental health	No surviving dentition
Comments	No maxilla, forearms or hands

Skeleton Number	139 (Phase 2)															
Preservation	1															
Completeness	41-60%															
Fragmentation	Moderate															
Age	Adult (18+ years)															
Sex	Male															
Stature	n/d															
Non-metric traits	Transverse foramen bipartite (left).															
Pathology	<u>Spinal joint disease</u> : 1 cervical vertebra, 8 thoracic vertebrae, 3 lumbar (osteophytes, porosity and Schmorl's nodes). <u>Extra-spinal joint disease</u> : right medial clavicle, left lateral clavicle, right proximal femur.															
Dental health	AMTL (0/2), calculus (1/2), caries (0/2), DEH (0/2), abscess (0/0), tooth positions present (0/2).															
Right dentition									Left dentition							
Present	-	-	-	-	-	-	-	-	-	-	-	-	-	-	-	-
Calculus	-	-	-	-	-	-	-	-	-	-	-	-	-	-	-	-
DEH	-	-	-	-	-	-	-	-	-	-	-	-	-	-	-	-
Caries	-	-	-	-	-	-	-	-	-	-	-	-	-	-	-	-
Wear	-	-	-	-	-	-	-	-	-	-	-	-	-	-	-	-
Maxilla	8	7	6	5	4	3	2	1	1	2	3	4	5	6	7	8
Mandible	8	7	6	5	4	3	2	1	1	2	3	4	5	6	7	8
Present	-	-	-	P	-	-	-	-	-	-	-	-	P	-	-	-
Calculus	-	-	-	mlbdm	-	-	-	-	-	-	-	-	-	-	-	-
DEH	-	-	-	-	-	-	-	-	-	-	-	-	-	-	-	-
Caries	-	-	-	-	-	-	-	-	-	-	-	-	-	-	-	-
Wear	-	-	-	5	-	-	-	-	-	-	-	-	5	-	-	-
Comments	No maxilla, lower legs or feet. Green staining on left and right ribs, both surfaces. Radiocarbon dated. Sample 12, 1442-1633 cal AD (95.4% probability).															



Skeleton Number	140 (Phase 2)															
Preservation	0															
Completeness	21-40%															
Fragmentation	Moderate															
Age	Young adult (18-25 years)															
Sex	Male															
Stature	n/a															
Non-metric traits	Ossicle in lambdoid (bilateral), ossicle in coronal (bilateral), mastoid foramen extrasutural (left), third trochanter (bilateral).															
Pathology	<p><u>Extra-spinal joint disease</u>: right sacro-iliac joint, exposed trabecular bone covers most of right auricular surface, right ala does not survive.</p> <p><u>Metabolic</u>: cribra orbitalia, right, left does not survive.</p> <p><u>Miscellaneous</u>: irregular new bone deposition and abnormal porosity, 2 patches on body of sphenoid, left mandible, below condyle, lateral surface, also right side, condylar neck, medial surface. Inflammation in these areas is seen in cases of scurvy (Ortner and Erikson 1997).</p>															
Dental health	Slight mandibular periodontal disease. AMTL (0/18), calculus (6/18), caries (0/18), DEH (3/18), enamel chipping (0/18), abscess (0/2), tooth positions (2/18).															
Right dentition									Left dentition							
Present	-	-	-	P	P	P	P	P	P	P	-	-	-	6	-	-
Calculus	-	-	-	-	-	-	-	-	-	-	-	-	-	sd	-	-
DEH	-	-	-	-	-	-	-	-	-	-	-	-	-	-	-	-
Caries	-	-	-	-	-	-	-	-	-	-	-	-	-	-	-	-
Wear	-	-	-	2	2	2	2	3	3	2	-	-	-	4	-	-
Maxilla	8	7	6	5	4	3	2	1	1	2	3	4	5	6	7	8
Mandible	8	7	6	5	4	3	2	1	1	2	3	4	5	6	7	8
Present	UE	P	P	P	P	P	-	P	-	-	P	-	-	P	P	-
Calculus	-	-	sb	-	-	sb	-	sb	-	-	fb	-	-	sb	-	-
DEH	-	-	-	2L	2L	-	-	-	-	-	2L	-	-	-	-	-
Caries	-	-	-	-	-	-	-	-	-	-	-	-	-	-	-	-
Wear	-	3	4	2	2	3	-	3	-	-	3	-	-	4	3	-
Comments	No maxilla, forearms, hands, lower legs or feet															

Skeleton Number	141 (Phase 1)
Preservation	1
Completeness	21-40%
Fragmentation	Moderate
Age	Adult (18+ years)
Sex	?
Stature	n/d
Non-metric traits	None
Pathology	<p><u>Spinal joint disease</u>: 1 cervical body, 1 cervical facet, 8 thoracic bodies, 1 lumbar (mild-moderate osteophytes, porosity and Schmorl's nodes).</p> <p><u>Extra-spinal joint disease</u>: right ulna, left capitate, right foot.</p> <p><u>Extra-spinal OA</u>: left scaphoid, right proximal and distal femur, left and right tibia, right talus and navicular (mild-severe osteophytes, porosity and eburnation).</p> <p><u>Trauma</u>: healed fracture of left femoral neck, marked displacement of the neck in a posterior direction, though not distally, gross proliferation of irregular new bone on medial side, less severe on anterior and posterior surfaces, lateral surface is normal, lesser trochanter is obscured by new bone and post-mortem damage, greater trochanter does not survive, new bone extends up to 48.39 mm from shaft in medial direction, suggestion of a false hip joint indicated by a much smoother area, difficult to be certain due to post-mortem damage, very little survives of left and right pelvis, right femur is too fragmented for comparison, femoral shaft appears normal. No secondary OA.</p>
Dental health	No surviving dentition.
Comments	No maxilla

Skeleton Number	142 (Phase 1)
Preservation	1
Completeness	21-40%
Fragmentation	Severe
Age	Adult (18+ years)
Sex	?
Stature	n/d
Non-metric traits	None
Pathology	<p><u>Spinal joint disease</u>: 9 thoracic bodies, 2 lumbar bodies (mild-severe osteophytes, porosity and Schmorl's nodes).</p> <p><u>Extra-spinal joint disease</u>: right hamate, pisiform and acetabulum (mild osteophytes).</p> <p><u>Non-specific infection</u>: right tibia, single fragment survives, woven bone deposition, light in colour, light in colour, medial side of anterior crest, striated lamellar bone on lateral and anterior surfaces; left tibia, midshaft only, more severe than left, thick layer of woven bone on medial surface, overlying anterior crest.</p>
Dental health	No surviving dentition
Intrusive bone	One bag of Skull fragments labelled as Sk. 141 or 142.
Comments	No maxilla, hands or feet

Skeleton Number	143 (Phase 1)																
Preservation	1																
Completeness	41-60%																
Fragmentation	Severe																
Age	Older adult (45+ years)																
Sex	?																
Stature	n/d																
Non-metric traits	None																
Pathology	<p><u>Spinal joint disease</u>: 1 cervical body, 4 thoracic bodies, 1 thoracic facet, 2 lumbar bodies, 1 sacral body, 2 sacral facets (mild-moderate osteophytes, porosity and Schmorl's nodes).</p> <p><u>Extra-spinal joint disease</u>: right clavicle (mild porosity).</p> <p><u>Non-specific infection</u>: left tibia, lateral surface, midshaft, woven bone; more severe on central portion of right tibia; fibulae, woven bone on medial surface, distal half.</p>																
Dental health	Moderate mandibular periodontal disease. AMTL (0/16), calculus (3/14), caries (0/14), DEH (0/14), enamel chipping (0/14), abscess (0/16), tooth positions (16/16). Unusual wear pattern, advanced on mandibular molars, and all other teeth except the right premolars, which have very little. Advanced wear slopes down from lingual to buccal.																
Right dentition									Left dentition								
Present	-	-	-	-	-	-	-	-	-	-	-	-	-	-	-	-	-
Calculus	-	-	-	-	-	-	-	-	-	-	-	-	-	-	-	-	-
DEH	-	-	-	-	-	-	-	-	-	-	-	-	-	-	-	-	-
Caries	-	-	-	-	-	-	-	-	-	-	-	-	-	-	-	-	-
Wear	-	-	-	-	-	-	-	-	-	-	-	-	-	-	-	-	-
Maxilla	8	7	6	5	4	3	2	1	1	2	3	4	5	6	7	8	
Mandible	8	7	6	5	4	3	2	1	1	2	3	4	5	6	7	8	
Present	P	P	P	P	P	P	P	PM	P	P	PM	P	P	P	P	P	
Calculus	-	-	-	-	-	-	sl	-	sl	slm	-	-	-	-	-	-	
DEH	-	-	-	-	-	-	-	-	-	-	-	-	-	-	-	-	
Caries	-	-	-	-	-	-	-	-	-	-	-	-	-	-	-	-	
Wear	6	6	7	3	3	6	6	-	6	6	-	7	7	8	6	7	
Comments	No maxilla or forearms																

Skeleton Number	144 (Phase 2)
Preservation	1 (tarsals are 3)
Completeness	61-80%
Fragmentation	Severe
Age	Adult (18+ years)
Sex	Male
Stature	n/d
Non-metric traits	Septal aperture (left)
Pathology	<p><u>Spinal joint disease</u>: 8 thoracic bodies, 6 thoracic facets, 5 lumbar bodies, 1 sacral body, 1 sacral facet (mild-moderate osteophytes, porosity and Schmorl's nodes).</p> <p><u>Extra-spinal joint disease</u>: right scapula, humerus, radius, left and right ulna, hamates, right lunate, left scaphoid, right triquetral, left femur, right patella, tibiae, fibulae, right calcaneus, tali, feet.</p> <p><u>Extra-spinal OA</u>: right 3<sup>rd</sup> distal hand phalanx (osteophytes and porosity).</p> <p><u>DISH</u>: bodies of TV5-TV9 are fused anteriorly on right side, disc spaces are preserved, no fusion of vertebral processes of TV5-7, inferior facets of TV8 are fused to those of TV9, bony proliferation continues on right anterior side down to TV11, though no fusion beyond TV8.</p> <p><u>Non-specific infection</u>: right 1<sup>st</sup> metatarsal, partial destruction of distal articulation, exostosis on dorsal surface; right 2<sup>nd</sup> metatarsal, partial destruction of proximal articulation; 1<sup>st</sup> proximal right foot phalanx, destructive remodelling of proximal articulation, 2 exostosis on plantar surface, concentric remodelling; proximal articulation of 1<sup>st</sup> distal right foot phalanx similarly affected; 2<sup>nd</sup> intermediate right foot phalanx, some destruction of distal articulation; destruction of articulations possible <u>septic arthritis</u>; 4<sup>th</sup> intermediate and distal foot phalanges are fused, possible claw toe deformity; possible <u>tarsal bar</u>: substantial bony exostosis on right talus. <u>Probable lepromatous leprosy</u>.</p>
Dental health	No surviving dentition.
Comments	No maxilla

## Appendix 1b - Disarticulated human bone

### *Quantification and assemblage composition*

A large assemblage of disarticulated human bone was recovered during excavation. All the material was scanned and a rapid record was made. This information has been presented as a table and is available in the archive though it should be noted that the table does not serve as an exhaustive catalogue. The main aims of the work were to provide a basic quantification of the material, to identify pathology, and to identify non-adult remains.

The assemblage comprises a minimum of 3267 fragments. A count of the right temporal bone provides a count of 12 as the MNI.

The majority appeared to be adult bones, although a small quantity of non-adult bone was recovered. A partially complete young juvenile Skull was found in association with Skeleton 32. In addition to the Skull, a total of 27 non-adult fragments were recovered from other contexts. There is no reason, therefore, to suggest that large quantities of non-adult graves had been disturbed. The very small proportion of non-adults observed in the articulated assemblage is likely to be a true reflection of the composition of the burial population. Two infant bones were found in association with Skeleton 3 and a single bone was associated with 132 or 133. These are the only infant bones that have been identified in the entire assemblage.

A total of 20 elements were identified as possibly male, compared with 10 that could be identified as possibly female.

### *The evidence for leprosy*

Changes consistent with likely or definite rhino-maxillary syndrome were observed in fragments from seven contexts. Two of these may be associated with articulated Skeletons.

The young juvenile Skull found in association with Skeleton 32 exhibited type 3 cribra orbitalia and dental enamel hypoplasia. Abnormal porosity of the palate was observed. There was also possible anterior alveolar resorption although this was partly obscured by post-mortem damage.

A left maxilla from context 21/1012 exhibited abnormal porosity of the palate and the nasal floor. There was also remodelling of the surviving portion of the nasal aperture. Skeleton 21 had no surviving maxilla although it was diagnosed with possible lepromatous leprosy based on diagnostic changes to the feet. It is conceivable that the maxilla is associated with the Skeleton.

A left maxilla from context 26 exhibited remodelling of the left nasal aperture with marked alveolar resorption. The incisors, canine and premolars had all been lost ante-mortem. There was also abnormal porosity of the palate with woven bone deposition and abnormal porosity on the left nasal floor.

A right maxilla from context 45 exhibited advanced alveolar resorption and remodelling of the nasal aperture. There was also abnormal porosity and new bone deposition on the nasal floor with a concave facial profile. It is conceivable that this maxilla is associated with Skeleton 45.

A right maxilla from context 612 exhibited resorption of the anterior sockets and mild abnormal porosity on the nasal floor. There was also probable remodelling of the surviving portion of the nasal aperture.

A right maxilla from context 864 exhibited abnormal porosity of the right nasal floor and resorption of the anterior sockets.

A right maxilla from context 920 exhibited possible abnormal porosity on the nasal floor and possible remodelling of the nasal aperture. There was also post-mortem damage.

Periosteal lesions on the forearm were observed in bone from a single context, while changes to the hand were seen in bone from two contexts. Periosteal lesions affecting the lower legs were observed in fragments from 27 contexts. This number included two probable examples of chronic ulcers. Three cases of changes to the feet probably due to septic arthritis were recorded. Two tarsal bars and a single example of blade-like remodelling of a metatarsal were observed. A single calcaneus had woven bone on its medial surface.

#### *Other pathology*

Low rates of joint disease, spinal joint disease, spinal osteoarthritis and extra-spinal osteoarthritis were recorded. This is comparable with the pattern seen among the articulated Skeletons. The prevalence of dental pathology also seems to reflect what was observed in the articulated Skeletons, apart from calculus which was less common, possibly as result of post-mortem disturbance.

Three orbits exhibited evidence of cribra orbitalia.

A single example of a healed fracture was observed. It was a mal-aligned fracture of the distal shaft of a right radius. Moderate marginal osteophytes were present on the distal articulation.

#### *Conclusion*

There is some potential for re-associating disarticulated material with articulated Skeletons. Much of the site recording is confused. It would be difficult, if not impossible to attempt re-association in most cases.

The pathological maxillae referred to above have been repackaged independently. It would be desirable for all the pathological fragments to be retrieved from the disarticulated assemblage for proper processing and detailed osteological recording in the future.

## APPENDIX 2 – CARBON 14 DATING

Compiled by G. Millward

### Introduction

In total twelve samples were sent to the Scottish Universities Environmental Research Centre (SUERC) for radiocarbon dating. These samples were sent in two batches with the first being processed on the 1<sup>st</sup> of April 2016 and the second being processed on the 27<sup>th</sup> of June 2017.

### Notes

Due to the different cycling of carbon in the atmosphere and the marine environment, there will be an offset in the radiocarbon ages between samples, originating in the same calendar year, obtained from the two environments. A marine shell can appear 400 years older than charcoal from the same period. Where a diet contains both terrestrial and marine components, both will contribute to the carbon in the sample and can affect the radiocarbon age obtained.

However, the marine element will also have an effect on the  $\delta^{13}\text{C}$  and  $\delta^{15}\text{N}$  values for a sample, allowing a correction to be made when calibrating the date range to take into account the contribution of carbon from the different sources.

Bone collagen samples with a  $\delta^{13}\text{C}$  value higher than -20‰ (in conjunction with a raised  $\delta^{15}\text{N}$ ) are interpreted as indicative of a component of marine resources in the diet. Taking -21.0‰ as a fully terrestrial diet and -12.5‰ as a fully marine diet, the percentage of the diet made up from marine sources can be calculated. A 10% uncertainty is then applied to this.

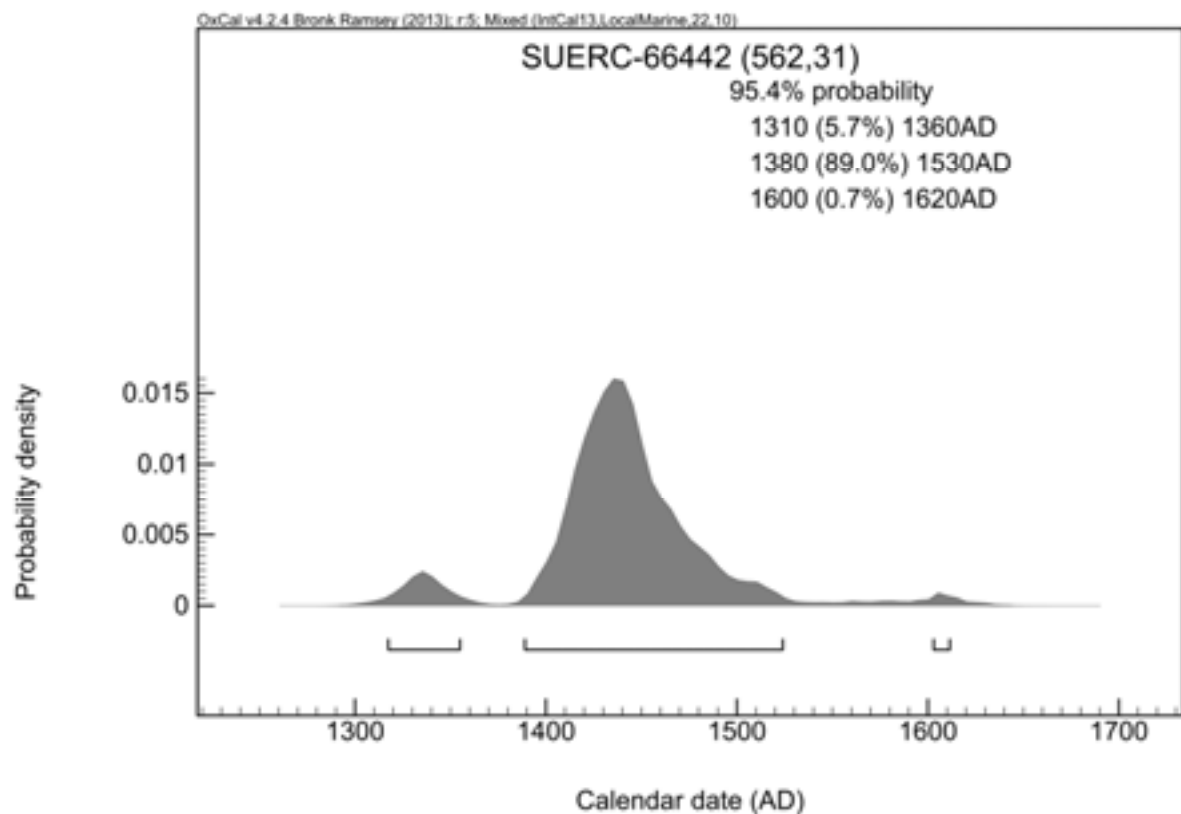
As it would be complex to show all this information on a calibration plot, only the final marine-corrected calibrated date ranges are shown in the graphics. The numeric ranges given in the top corner of the plot are also marine-corrected.

### Results

The following  $^{14}\text{C}$  ages are quoted in conventional years BP (before 1950 AD). The error, which is expressed at the one sigma level of confidence, includes components from the counting statistics on the sample, modern reference standard and blank and the random machine error.

The calibrated age ranges are determined from the University of Oxford Radiocarbon Accelerator Unit calibration program (OxCal4).

Samples with a SUERC coding are measured at the Scottish Universities Environmental Research Centre AMS Facility and should be quoted as such in any reports within the scientific literature. Any questions directed to the Radiocarbon Laboratory should also quote the GU coding given in parentheses after the SUERC code. The contact details for the laboratory are email [Gordon.Cook@glasgow.ac.uk](mailto:Gordon.Cook@glasgow.ac.uk) or telephone 01355 270136 direct line.

**Radiocarbon dating certificate (Sample 1, Skeleton 37)****Laboratory Code** SUERC-66442 (GU40300)**Site Reference** Midland Road PMR14**Material** Bone : Human (R ulna midshaft) **$\delta^{13}\text{C}$  relative to VPDB** -19.1 ‰ **$\delta^{15}\text{N}$  relative to air** 11.9 ‰**C/N ratio (Molar)** 3.2**Radiocarbon Age BP** 562  $\pm$  31**Calibration Plot**



**Radiocarbon dating certificate (Sample 2, Skeleton 33)**

**Laboratory Code** SUERC-66443 (GU40301)

**Site Reference** Midland Road PMR14

**Material** Bone : Human (L humerus midshaft)

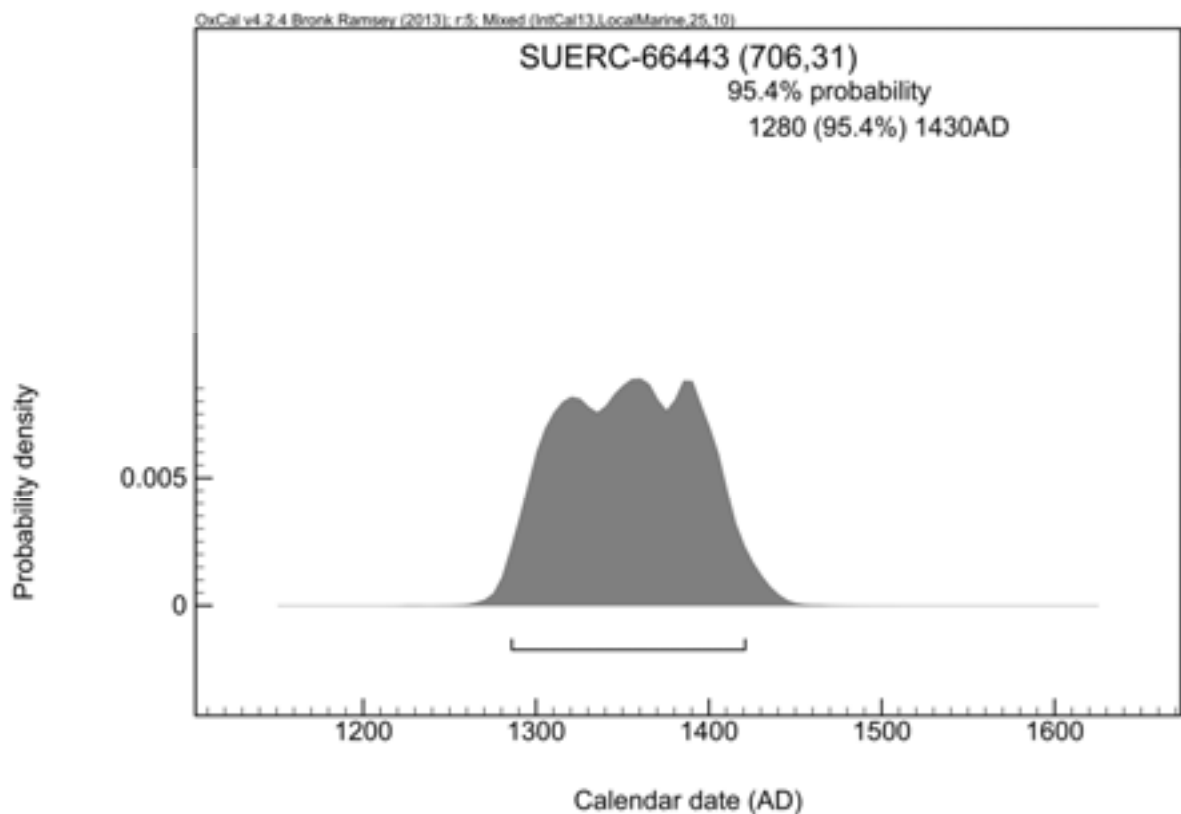
**δ13C relative to VPDB** -18.9 ‰

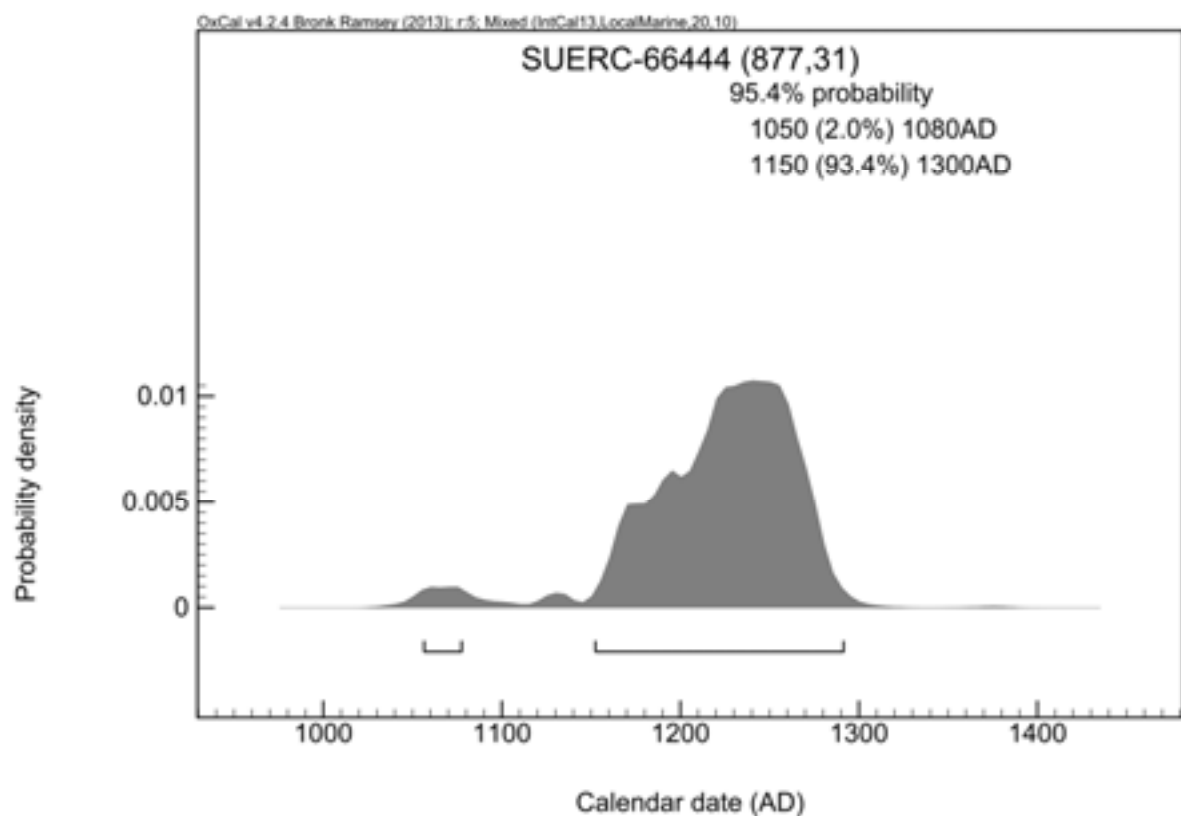
**δ15N relative to air** 13.4 ‰

**C/N ratio (Molar)** 3.3

**Radiocarbon Age BP** 706 ± 31

**Calibration Plot**



**Radiocarbon dating certificate (Sample 3, Skeleton 21)****Laboratory Code** SUERC-66444 (GU40302)**Site Reference** Midland Road PMR14**Material** Bone : Human (R ulna mid/distl shft) **$\delta^{13}\text{C}$  relative to VPDB** -19.3 ‰ **$\delta^{15}\text{N}$  relative to air** 11.1 ‰**C/N ratio (Molar)** 3.3**Radiocarbon Age BP** 877  $\pm$  31**Calibration Plot**

**Radiocarbon dating certificate (Sample 4, Skeleton 4)**

**Laboratory Code** SUERC-73714 (GU44093)

**Site Reference** Midland Road, Peterborough

**Material** Human bone : Midshaft of left ulna

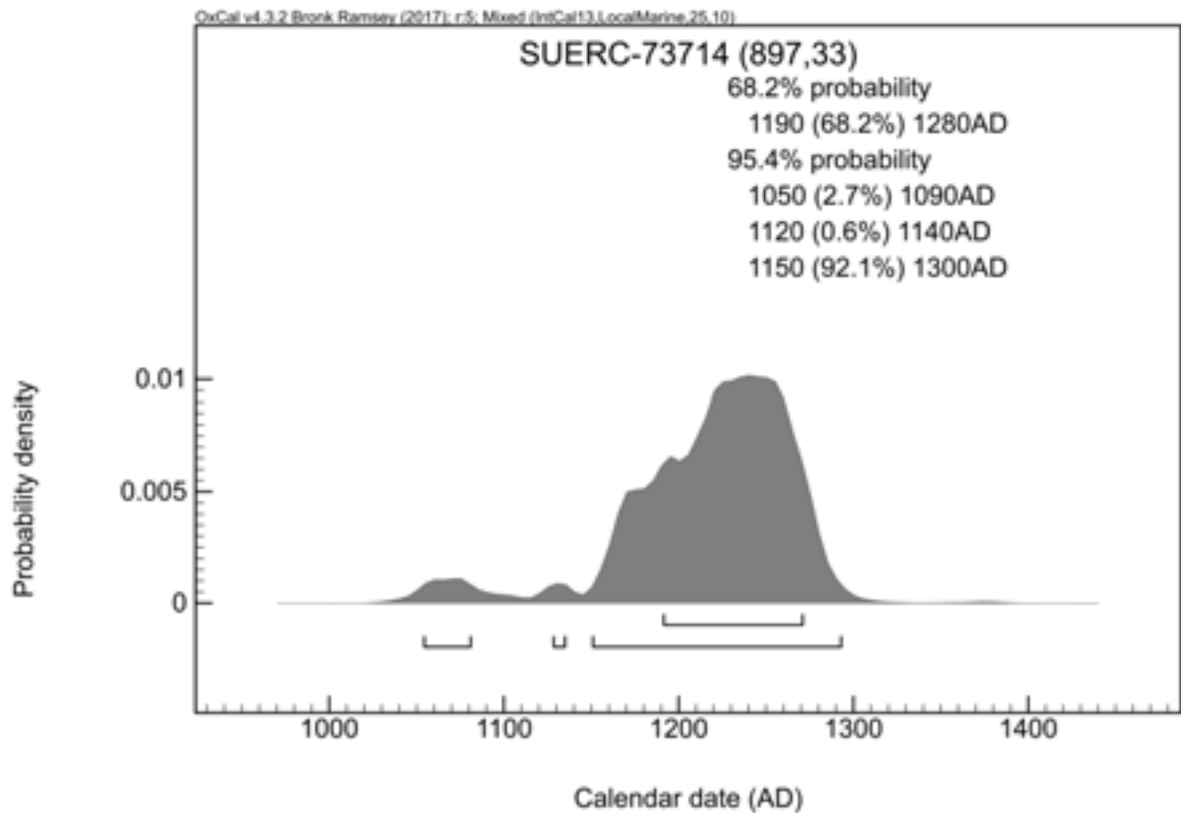
**δ 13C relative to VPDB** -18.9 ‰

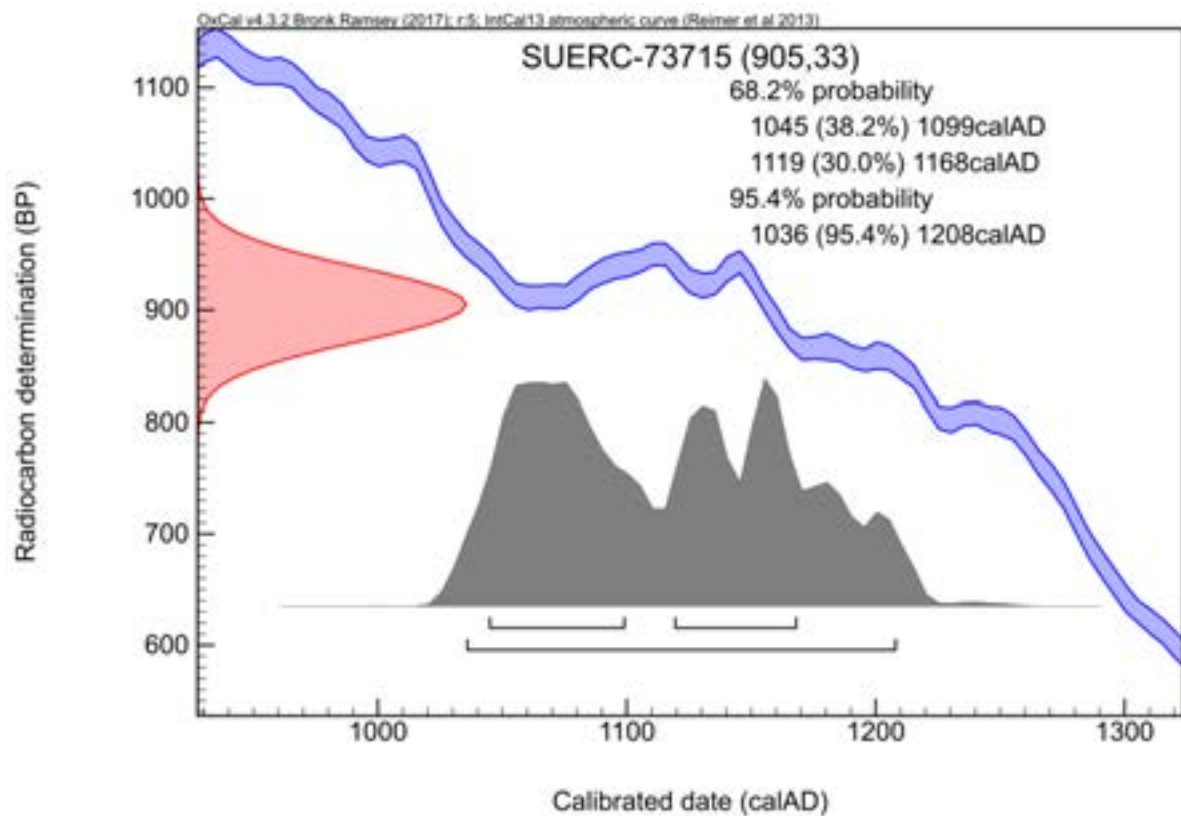
**δ 15N relative to air** 13.3 ‰

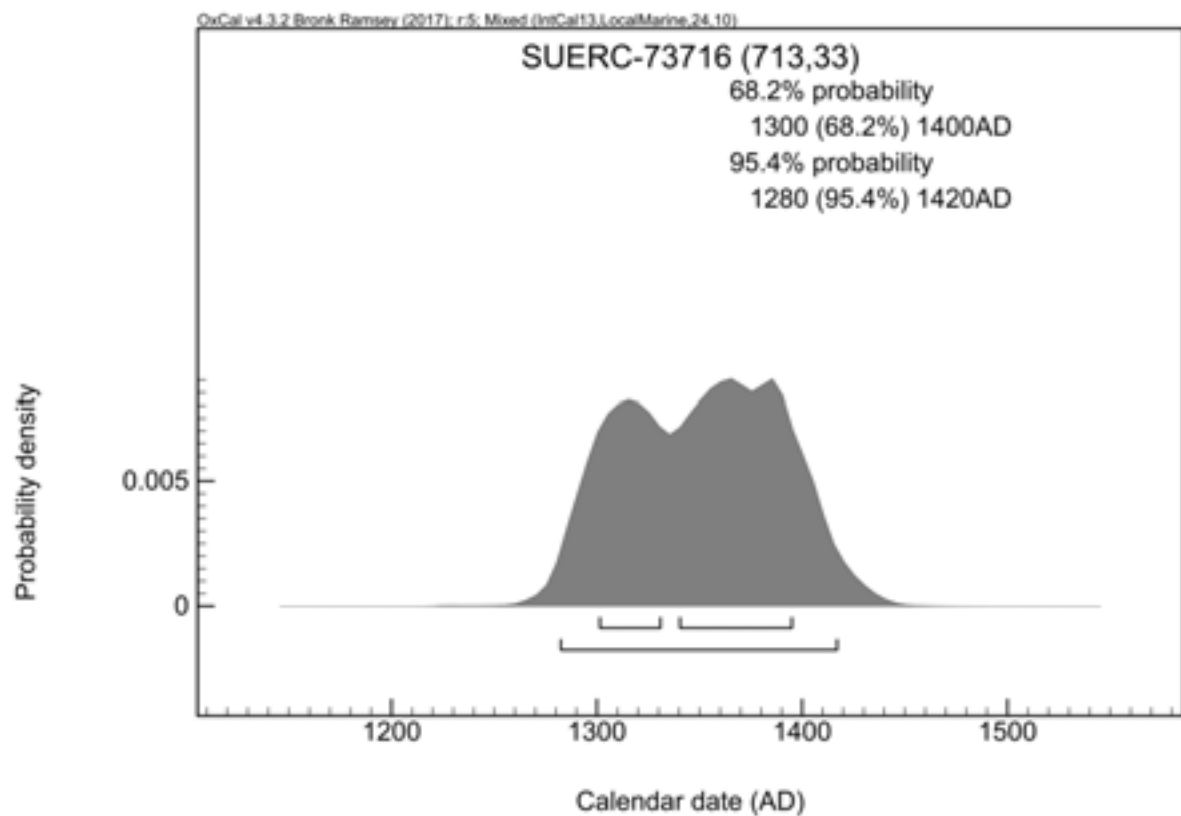
**C/N ratio (Molar)** 2.9

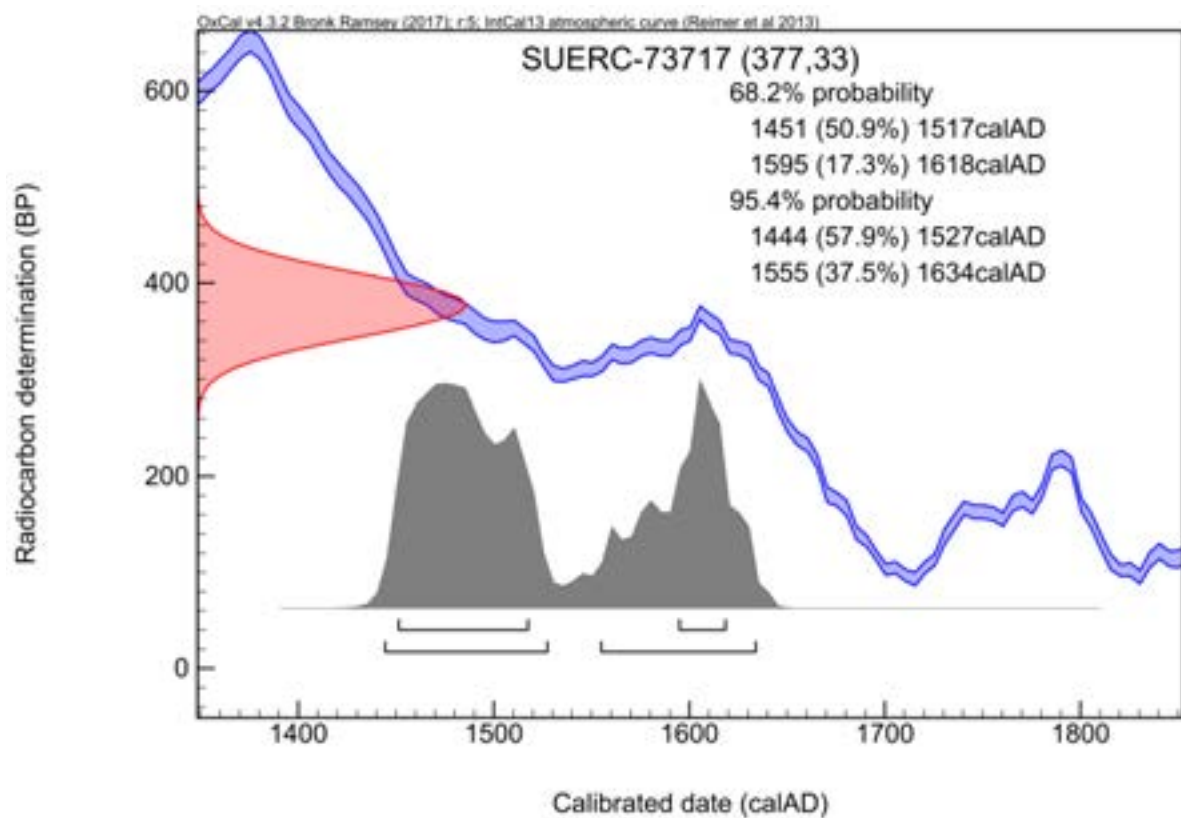
**Radiocarbon Age BP** 897 ± 33

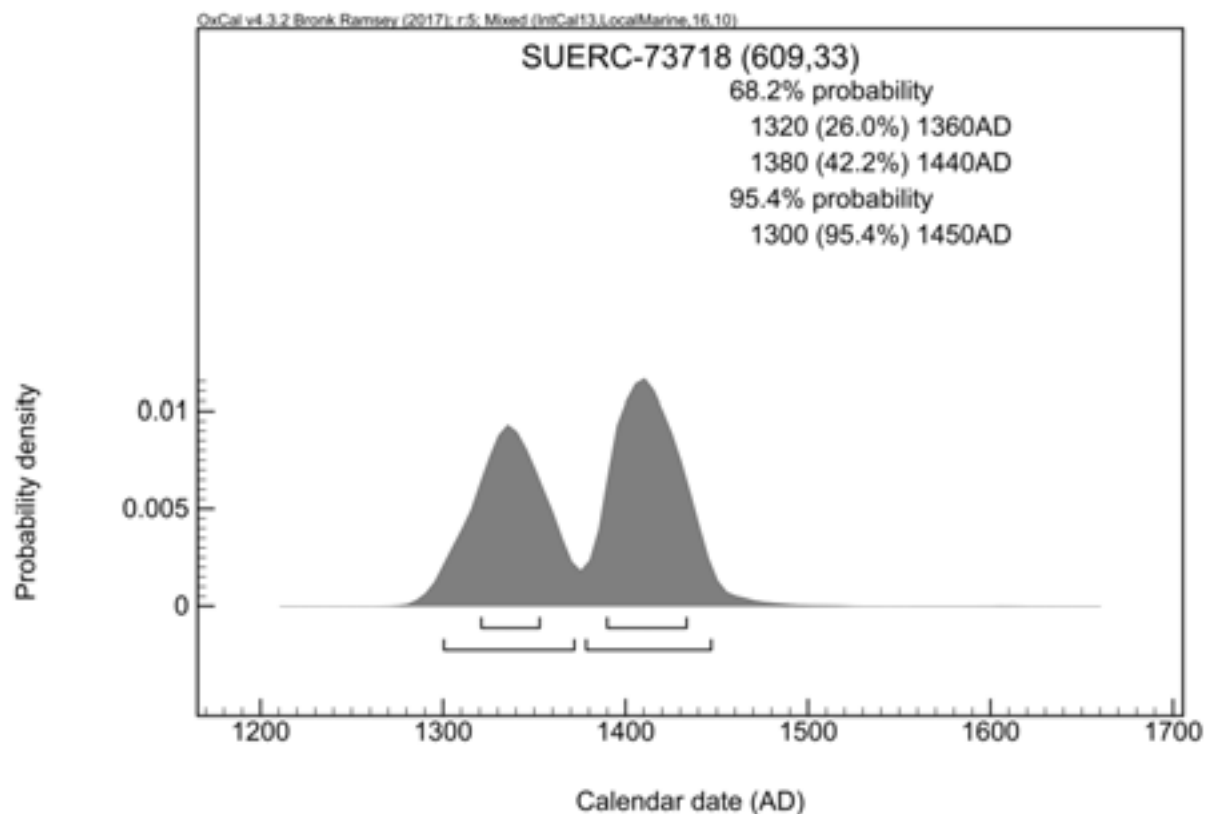
**Calibration Plot**



**Radiocarbon dating certificate (Sample 5, Skeleton 18)****Laboratory Code** SUERC-73715 (GU44094)**Site Reference** Midland Road, Peterborough**Material** Human bone : Midshaft of right radius **$\delta$  13C relative to VPDB** -20.2 ‰ **$\delta$  15N relative to air** 12.4 ‰**C/N ratio (Molar)** 3.0**Radiocarbon Age BP** 905  $\pm$  33**Calibration Plot**

**Radiocarbon dating certificate (Sample 6, Skeleton 85)****Laboratory Code** SUERC-73716 (GU44095)**Site Reference** Midland Road, Peterborough**Material** Human bone : Distal shaft of right humerus **$\delta$  13C relative to VPDB** -19.0 ‰ **$\delta$  15N relative to air** 12.1 ‰**C/N ratio (Molar)** 3.1**Radiocarbon Age BP** 713  $\pm$  33**Calibration Plot**

**Radiocarbon dating certificate (Sample 7, Skeleton 86)****Laboratory Code** SUERC-73717 (GU44096)**Site Reference** Midland Road, Peterborough**Material** Human bone : Midshaft of left radius **$\delta$  13C relative to VPDB** -20.4 ‰ **$\delta$  15N relative to air** 9.9 ‰**C/N ratio (Molar)** 3.1**Radiocarbon Age BP** 377  $\pm$  33**Calibration Plot**

**Radiocarbon dating certificate (Sample 8, Skeleton 120)****Laboratory Code** SUERC-73718 (GU44097)**Site Reference** Midland Road, Peterborough**Material** Human bone : Proximal shaft of left ulna **$\delta$  13C relative to VPDB** -19.6 ‰ **$\delta$  15N relative to air** 12.6 ‰**C/N ratio (Molar)** 3.1**Radiocarbon Age BP** 609  $\pm$  33**Calibration Plot**

**Radiocarbon dating certificate (Sample 9, Skeleton 93)**

**Laboratory Code** SUERC-66445 (GU40303)

**Site Reference** Midland Road PMR14

**Material** Bone : Human (L ulna shaft)

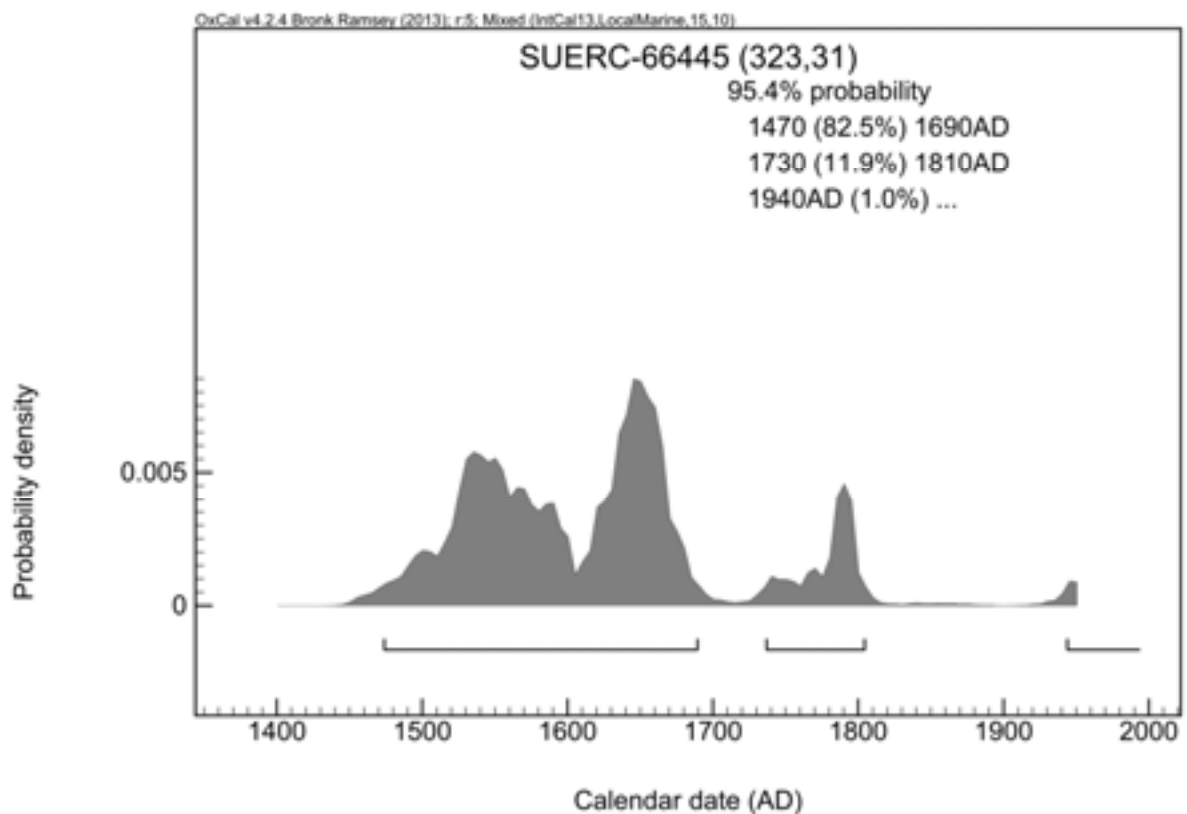
**δ13C relative to VPDB** -19.7 ‰

**δ15N relative to air** 11.5 ‰

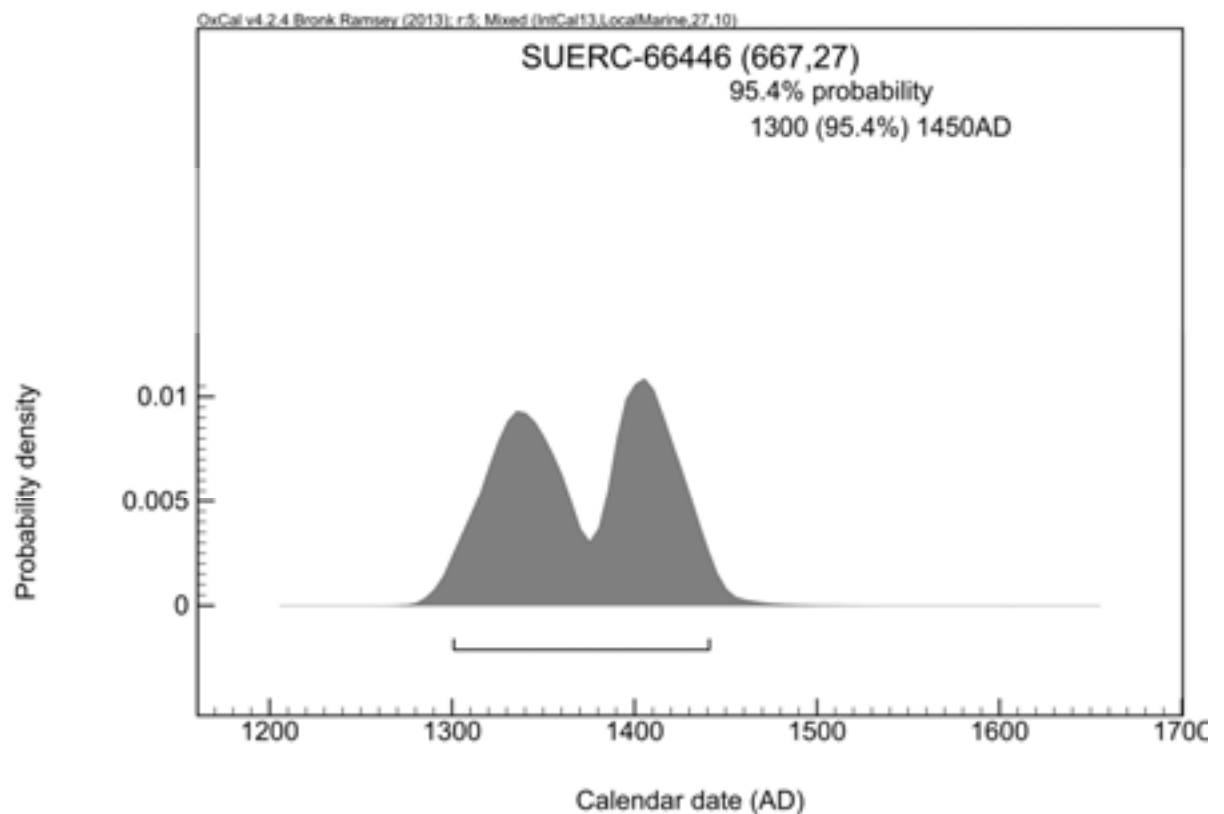
**C/N ratio (Molar)** 3.2

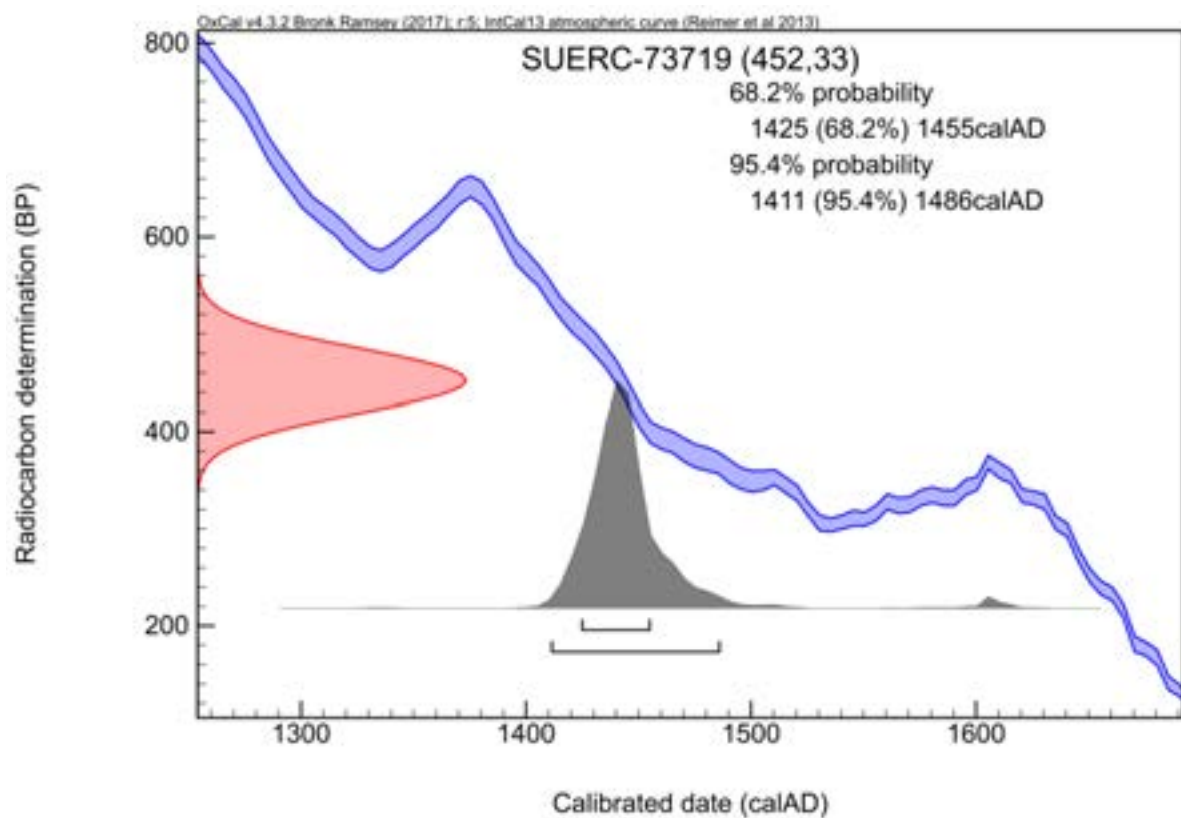
**Radiocarbon Age BP** 323 ± 31

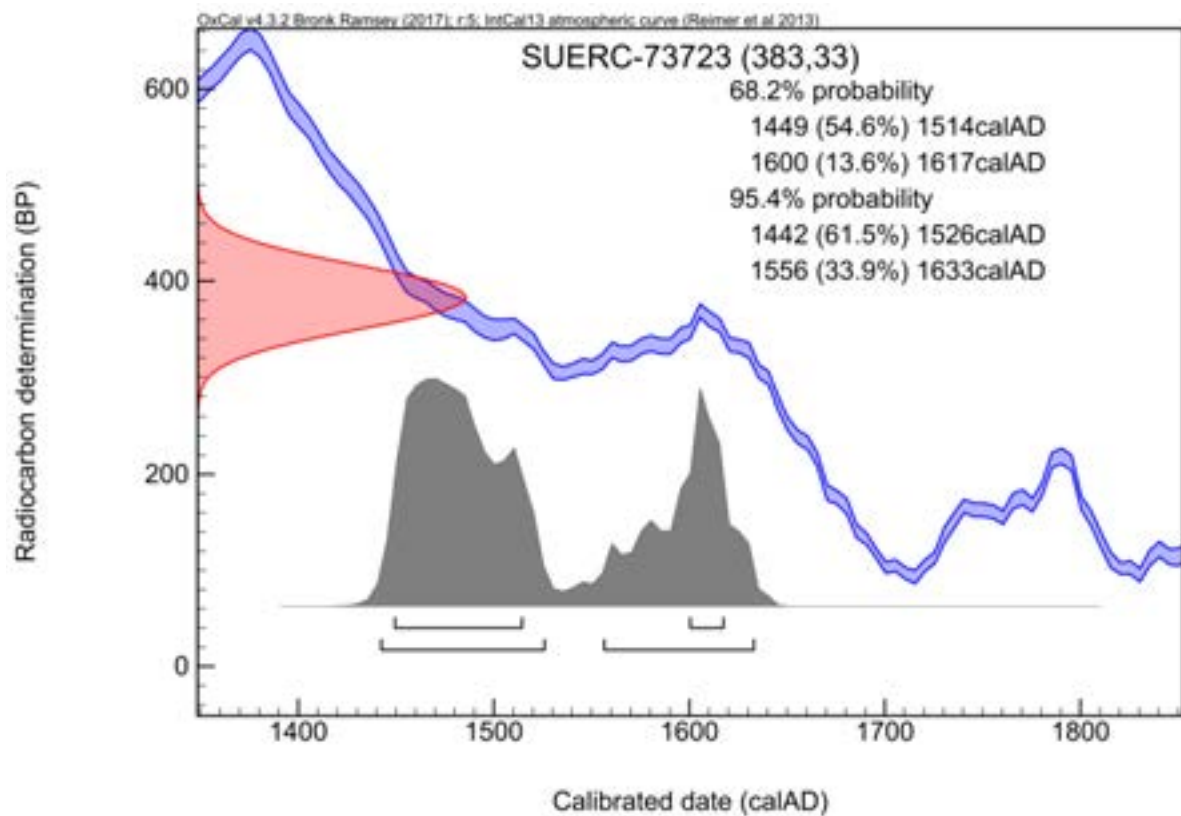
**Calibration Plot**





**Radiocarbon dating certificate (Sample 10, Skeleton 98)****Laboratory Code** SUERC-66446 (GU40304)**Site Reference** Midland Road PMR14**Material** Bone : Human (R radius distal shaft) **$\delta^{13}\text{C}$  relative to VPDB** -18.7 ‰ **$\delta^{15}\text{N}$  relative to air** 12.2 ‰**C/N ratio (Molar)** 3.3**Radiocarbon Age BP** 667  $\pm$  27**Calibration Plot**

**Radiocarbon dating certificate (Sample 11, Skeleton 132)****Laboratory Code** SUERC-73719 (GU44098)**Site Reference** Midland Road, Peterborough**Material** Human bone : Proximal shaft of left ulna **$\delta$  13C relative to VPDB** -20.3 ‰ **$\delta$  15N relative to air** 12.1 ‰**C/N ratio (Molar)** 3.2**Radiocarbon Age BP** 452  $\pm$  33**Calibration Plot**

**Radiocarbon dating certificate (Sample 12, Skeleton 139)****Laboratory Code** SUERC-73723 (GU44099)**Site Reference** Midland Road, Peterborough**Material** Human bone : Distal shaft of right ulna **$\delta$  13C relative to VPDB** -20.2 ‰ **$\delta$  15N relative to air** 11.3 ‰**C/N ratio (Molar)** 2.9**Radiocarbon Age BP** 383 ± 33**Calibration Plot**

## APPENDIX 3 – CONSERVATION OF THE LACE TAGS

Conservator: B. Beekman

*Date: 18<sup>th</sup> March 2016*

York Archaeological Trust Conservation Report Number 2016/25

### Introduction

This report describes the conservation treatment of 21 copper alloy finds from Midland Road, Peterborough. The work carried out has been the cleaning and consolidating of the objects submitted, including the extraction of Minerally Preserved Organics (MPO's) for further analysis. Once the artefacts had been treated they were packed appropriately for return to the client and for archive storage.

### Description

21 copper alloy objects arrived at the lab in a Stewart box. 4 objects were individually packed in crystal boxes supported with acid-free tissue paper, others were individually packaged in a finds bag and placed in a crystal box together.

All but 2 objects were identified as lace tags or chapes. Most are highly corroded, fragmentary and incomplete, with some pieces still encased in the lumps of soil in which they were found. The lace tags are associated with specific Skeletons (see table 1.7. in Swann 2015), which suggests that people were interred clothed.

Lace tags or chapes were made from thin sheet copper alloy rolled into a tube with the long edges butted, overlapped or slightly turned in. Some examples have a tiny transverse rivet. These dress accessories were in use in large numbers from the 15th century until around the 17th and were used to facilitate the threading of laces (leather, fibre or cord) through garments. There is a proposed typology, with the tapered and transverse riveted examples thought to be the earlier 15th century type. Most examples here are too damaged or fragmentary to determine all the characteristics required for close typological dating, but X-radiography reveals that SF's 9, 10, 12 and 17 have transverse rivets and several, including SF's 17, 20, 21 and 26, are tapered (information from Swann 2015).

Details on each individual copper alloy object (before conservation treatment commenced) are set out in the table below.

SF	ID	Description (before conservation)	Measurements Lace tags: (length x diam)	Complete	MP O	Tapered	Transverse rivet
1	Washer ?	Round disc with 6.5mm diam central perforation in the middle with a slightly raised ring around it. Covered in soil and corrosion products. Metal core is fairly intact.	22mm (diam), 2mm (thick)	Yes			
6	Lace tag	Large lace tag. Metal core and original surface fairly intact. Mostly soil inside, but mineralised organics might be present. Tapered	53mm x 7mm	Yes	X	X	
7	Lace tag	Small fragment. Fairly mineralised core. Possible mineralised organics inside.	6mm x 2.5mm		X		
8	Lace tag	2 fragments: both halves of the lace tag.	9mm x 2mm				
9	Lace tag	2 fragments with matching breaks. Quite mineralised and pitted core. Contains transverse rivet. Possible mineralised organics inside both fragments.	(1) 18mm x 3mm (2) 14mm x 3mm	Yes	X		X
10	Lace tag	Core is slightly mineralised. Contains transverse rivet. Possible mineralised organics inside.	20mm x 2.5mm	Yes	X		X
11	Lace tag	2 fragments. Fairly mineralised and pitted core. Mineralised organics inside both fragments.	(1) 12mm x 2.5mm (2) 10mm x 2.5mm		X		
12	Lace tag	Fairly mineralised and pitted core with a crack running along the width. Contains transverse rivet. Possible mineralised organics inside.	19mm x 2.5mm		X		X
13	Lace tag	2 fragments. The larger one has traces of mineralised thread or hair on its surface.  Fairly mineralised core, the smaller fragment is more mineralised than the larger fragment.	(1) 10mm x 2mm (2) 7mm x 2mm		X		
14	Lace tag	Fairly mineralised core. Evidence of mineralised thread or cord inside.	24mm x 2.5mm		X		
15	Lace tag	Small fragment. Fairly mineralised core. Nothing remains inside. A small rivet with a lump of concretion attached to it is present in the bag.	4mm x 2mm				X
16	Lace tag?	2 lumps of soil with small fragments of cu alloy encased in it. Possibly part of lace tag, but indefinable shape. Do not show up on x-ray, metal is completely mineralised.	Largest fragment 4mm x 1mm				
17	Lace tag	Lace tag encased in lump of soil. Metal core slightly mineralised. Contains transverse rivet. Tapered. Possible mineralised organics inside.	28mm x 3mm	Yes	X	X	X
18	Lace tag	Fragmented lace tag encased in lump of soil with a detached small fragment. Mineralised core. Possible mineralised organics inside.	10mm x 2mm		X		
19	Lace tag	Fairly mineralised and pitted core. Evidence of mineralised organics inside and one mineralised thread present with SF.	21mm x 2mm		X		

SF	ID	Description (before conservation)	Measurements Lace tags: (length x diam)	Complete	MPO	Tapered	Transverse rivet
20	Lace tag	Fairly mineralised and pitted core. Possible mineralised organics inside.	16mm x 2.5mm		X		
21	Lace tag	Fairly mineralised core. Tapered. Possible mineralised organics inside.	21mm x 2mm		X	X	
23	Lace tag	2 fragments: 1 half still encased in lump of soil. The other half retains mineralised organics from the inside of the lace tag. Fairly mineralised and pitted core.	12mm x 3mm		X		
24	Lace tag	Lump of soil with small completely mineralised fragments of cu alloy encased in it. Likely the be part of lace tag. A fragment of MPO and a fragment of the lace tag were present in the crystal box as well.	Largest fragment 11mm x 2mm		X		
25	Sheet fragment	Sheet fragment covered in soil. Deliberate hole is present. Metal core is almost entirely mineralised and pitted.	13mm (length) x 6mm (width)				
26	Lace tag	Lace tag with the tip slightly bent. Fairly mineralised and pitted core. Tapered. Possible mineralised organics inside.	19mm x 2mm		X	X	

## Methodology

All copper objects were cleaned by softening the soil and corrosion products with 50:50 Industrial Methylated Spirits (IMS)/Reverse Osmosis water (R.O. water), which were then removed with a swab or scalpel, depending on the condition of the surface.

As the interior of the lace tags had a high possibility for organic preservation, the contents were carefully extracted with a needle and searched for MPO's such as fibres or thread. The MPO's were placed in an envelope made of acid-free tissue paper and placed in a finds bag, ready for further analysis. After extraction of the MPO's, the objects were consolidated with 5% Paraloid B72 (methyl methacrylate co-polymer) w/v in acetone, applied by brush.

In some cases, a fragment of the lace tag detached in the treatment process. These fragments were re-adhered to their original location with Paraloid B72 (methyl methacrylate co-polymer) supplied in a tube by HMG.





For SF7, 10 and 26, it was not possible to extract the MPO's without damaging the lace tag, therefore the MPO's were left in place and the object was not consolidated. It is recommended that these lace tags are consolidated after the MPO's have been subject to further analysis, as the surfaces are very fragile.

All finds bags with objects (except for the ones with lumps of soil in them) were lined with Jiffy foam, as well as the crystal boxes. All MPO's that are separately placed in finds bags were placed in the largest crystal box together. Everything was placed in the stewart box with silica gel bags. The desiccated environment will need to be maintained and silica gel bags will need to be reconditioned when depleted.



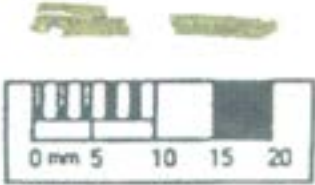
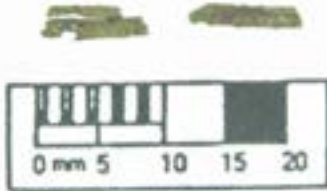
## **Recommendations**





The copper alloy objects are stable but should be stored in a dry environment of less than 15% Relative Humidity to avoid active corrosion. The objects should be handled with care due to the fragile nature of the exposed surfaces.

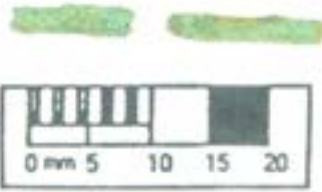

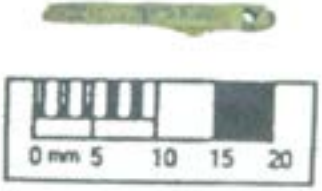

Treatment record table:

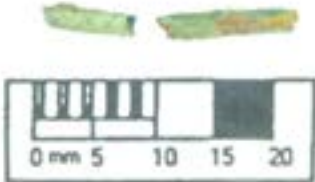



Photograph BEFORE	AFTER	Identification, Condition and Treatment
		<p><b>SF1</b></p> <p><b>Treatment</b></p> <ul style="list-style-type: none"> <li>• Soil and corrosion are cleaned off by softening it with 50:50 IMS/R.O. water, then removed with a scalpel.</li> <li>• Consolidated with 5% Paraloid B72 (methyl methacrylate co-polymer) w/v in acetone, applied by brush.</li> </ul>
		<p><b>SF6</b></p> <p><b>Treatment</b></p> <ul style="list-style-type: none"> <li>• Soil and corrosion are cleaned off by swabbing it with 50:50 IMS/R.O. water on a cotton wool swab. The surface was too fragile for removal with a scalpel.</li> <li>• Soil from the inside was removed with a toothpick and a fair amount of MPO's were extracted and bagged separately.</li> <li>• Consolidated with 5% Paraloid B72 (methyl methacrylate co-polymer) w/v in acetone, applied by brush to the whole exterior and only the outer edges of the interior.</li> </ul>











		<p><b>SF7</b></p> <p><b>Treatment</b></p> <ul style="list-style-type: none"> <li>• Soil and corrosion are cleaned off by softening it with 50:50 IMS/R.O. water, then removed with a scalpel.</li> <li>• MPO's are preserved on the interior, but these cannot be extracted in one piece or without breaking the lace tag, as it is too fragile.</li> <li>• The lace tag is not consolidated because MPO's are still present on the interior.</li> </ul> <p><b>Further treatment</b></p> <ul style="list-style-type: none"> <li>• After further analysis on the MPO's has taken place, this lace tag requires consolidation as the surface is very fragile.</li> </ul>
		<p><b>SF8</b></p> <p><b>Treatment</b></p> <ul style="list-style-type: none"> <li>• Soil and corrosion are cleaned off by softening it with 50:50 IMS/R.O. water, then removed with a scalpel.</li> <li>• Consolidated with 5% Paraloid B72 (methyl methacrylate co-polymer) w/v in acetone, applied by brush to the whole exterior and interior.</li> </ul>


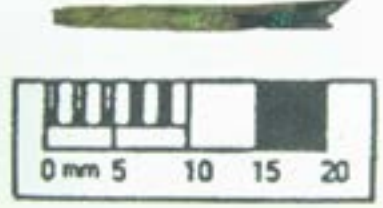
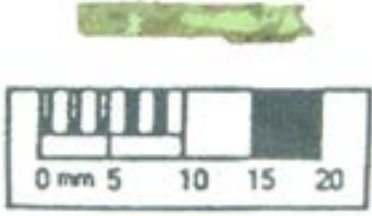
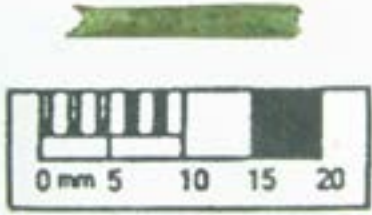
		<p><b>SF9</b></p> <p><b>Treatment</b></p> <ul style="list-style-type: none"> <li>• Soil and corrosion are cleaned off by softening it with 50:50 IMS/R.O. water, then removed with a scalpel.</li> <li>• An area of possible MPO's is present on the smaller lace tag.</li> <li>• Some MPO's from the inside were extracted with a needle and bagged separately. The rivet in the larger lace tag is holding a part of the MPO in place, and this cannot be removed without damaging the rivet, therefore it is left. During this process, one small fragment of the lace tag detached from its original location. It was not re-adhered, as it would obscure the MPO that is left in place and the adhesive will penetrate into the MPO.</li> <li>• Both fragments are consolidated with 5% Paraloid B72 (methyl methacrylate co-polymer) w/v in acetone, applied by brush, with the exception of the areas around the MPO's that remain on the objects.</li> <li>• The fragments are adhered together with HMG Paraloid B72.</li> <li>•</li> </ul>
		<p><b>SF10</b></p> <p><b>Treatment</b></p> <ul style="list-style-type: none"> <li>• Soil and corrosion are cleaned off by softening it with 50:50 IMS/R.O. water, then removed with a scalpel.</li> <li>• MPO's are preserved on the interior, but these cannot be removed in one piece or without breaking the lace tag. Therefore they are left in place.</li> <li>• The lace tag is not consolidated because MPO's are still present on the interior.</li> </ul> <p><b>Further treatment</b></p> <ul style="list-style-type: none"> <li>• After further analysis on the MPO's has taken place, this lace tag requires consolidation as the surface is very fragile.</li> </ul>

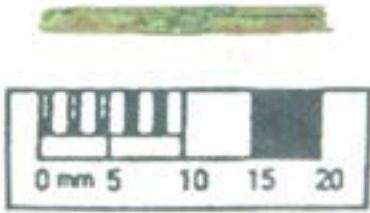
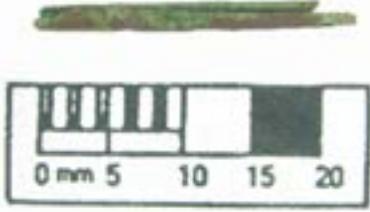

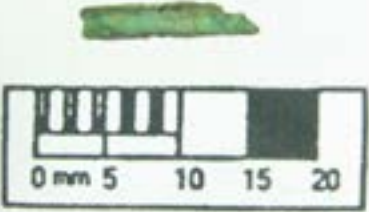
		<p><b>SF11</b></p> <p><b>Treatment</b></p> <ul style="list-style-type: none"> <li>• Soil and corrosion are cleaned off by softening it with 50:50 IMS/R.O. water, then removed with a scalpel.</li> <li>• MPO's from the inside were extracted with a needle and bagged separately.</li> <li>• Consolidated with 5% Paraloid B72 (methyl methacrylate co-polymer) w/v in acetone, applied by brush to the whole exterior and only the outer edges of the interior.</li> </ul>
		<p><b>SF12</b></p> <p><b>Treatment</b></p> <ul style="list-style-type: none"> <li>• Soil and corrosion are cleaned off by softening it with 50:50 IMS/R.O. water, then removed with a scalpel.</li> <li>• The majority of the MPO's from the inside were extracted with a needle and bagged separately. A little amount of MPO's and corrosion minerals remain on the inside, but as the lace tag is cracked through the middle, it will break if these are removed.</li> <li>• Although a little amount of MPO's remain on the interior, the lace tag is consolidated with 5% Paraloid B72 (methyl methacrylate co-polymer) w/v in acetone, applied by brush to the whole exterior and only the outer edges of the interior, in order to prevent it from breaking in 2 fragments.</li> </ul>

		<p><b>SF13</b></p> <p><b>Treatment</b></p> <ul style="list-style-type: none"> <li>• Soil and corrosion are cleaned off by softening it with 50:50 IMS/R.O. water, then removed with a scalpel. An area of MPO's is preserved on the exterior of the larger lace tag, which is left in place.</li> <li>• MPO's from the inside of the smaller fragment were extracted with a needle and bagged separately. There were a lot of individual fibres present. No MPO's were present on the interior of the larger lace tag.</li> <li>• The smaller lace tag is consolidated with 5% Paraloid B72 (methyl methacrylate co-polymer) w/v in acetone, applied by brush to the whole exterior and only the outer edges of the interior. The larger lace tag is only consolidated in the most fragile area, to prevent any consolidant going into the area of MPO's that is preserved on the exterior.</li> </ul>
		<p><b>SF14</b></p> <p><b>Treatment</b></p> <ul style="list-style-type: none"> <li>• Soil and corrosion are cleaned off by softening it with 50:50 IMS/50:50 IMS/R.O. water, then removed with a scalpel.</li> <li>• MPO's from the inside of the smaller fragment were extracted with a needle and bagged separately. During this process, one fragment of the lace tag came off.</li> <li>• Consolidated with 5% Paraloid B72 (methyl methacrylate co-polymer) w/v in acetone, applied by brush to the whole exterior and only the outer edges of the interior. The detached fragment of the lace tag was re-adhered to its original location with HMG Paraloid B72.</li> </ul>


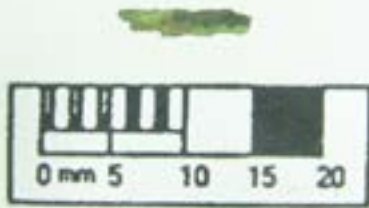
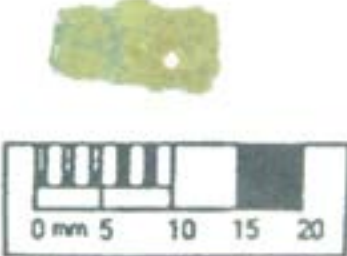

		<p><b>SF15</b></p> <p><b>Treatment</b></p> <ul style="list-style-type: none"> <li>• Soil and corrosion are cleaned off by softening it with 50:50 IMS/R.O. water, then removed with a scalpel.</li> <li>• A small rivet is present in the bag, which is placed inside an acid-free tissue paper and placed inside the bag.</li> <li>• Consolidated with 5% Paraloid B72 (methyl methacrylate co-polymer) w/v in acetone, applied by brush to the whole exterior and only the outer edges of the interior.</li> </ul>
		<p><b>SF16</b></p> <p><b>Treatment</b></p> <ul style="list-style-type: none"> <li>• The small fragment of lace tag that was present in the lump of soil was left in situ and consolidated with 5% Paraloid B72 (methyl methacrylate co-polymer) w/v in acetone, applied by brush.</li> </ul>


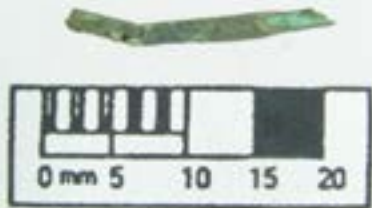
		<p><b>SF17</b></p> <p><b>Treatment</b></p> <ul style="list-style-type: none"> <li>• The lace tag was removed from the soil by softening it with 50:50 IMS/R.O. water, then removed with a scalpel. The lace tag itself was cleaned in the same way.</li> <li>• MPO's from the inside of the smaller fragment were extracted with a needle and bagged separately. There were a lot of individual fibres present. During this process, one fragment of the lace tag came off. A rivet is present which is holding a part of the MPO in place, and this cannot be removed without damaging the rivet, therefore it is left.</li> <li>• The exterior is consolidated with 5% Paraloid B72 (methyl methacrylate co-polymer) w/v in acetone, applied by brush, with the exception of the areas around the MPO's that remain on the objects. The detached fragment of the lace tag was re-adhered to its original location with HMG Paraloid B72.</li> </ul>
		<p><b>SF18</b></p> <p><b>Treatment</b></p> <ul style="list-style-type: none"> <li>• The lace tag and 2 tiny fragments were removed from the soil by softening it with 50:50 IMS/R.O. water, then removed with a scalpel. The lace tag itself was cleaned in the same way.</li> <li>• MPO's from the inside of the small fragment were extracted with a needle and bagged separately.</li> <li>• Consolidated with 5% Paraloid B72 (methyl methacrylate co-polymer) w/v in acetone, applied by brush to the whole exterior and only the outer edges of the interior of the lace tag and to the whole surfaces of the 2 fragments.</li> </ul>

		<p><b>SF19</b></p> <p><b>Treatment</b></p> <ul style="list-style-type: none"> <li>• Soil and corrosion are cleaned off by softening it with 50:50 IMS/R.O. water, then removed with a scalpel.</li> <li>• The mineralised thread, and the MPO's from the inside were extracted with a needle and bagged separately.</li> <li>• Consolidated with 5% Paraloid B72 (methyl methacrylate co-polymer) w/v in acetone, applied by brush to the whole exterior and only the outer edges of the interior.</li> </ul>
		<p><b>SF20</b></p> <p><b>Treatment</b></p> <ul style="list-style-type: none"> <li>• Soil and corrosion are cleaned off by softening it with 50:50 IMS/R.O. water, then removed with a scalpel.</li> <li>• MPO's from the inside were extracted with a needle and bagged separately.</li> <li>• Consolidated with 5% Paraloid B72 (methyl methacrylate co-polymer) w/v in acetone, applied by brush to the whole exterior and only the outer edges of the interior.</li> </ul>

		<p><b>SF21</b></p> <p><b>Treatment</b></p> <ul style="list-style-type: none"> <li>• Soil and corrosion are cleaned off by softening it with 50:50 IMS/R.O. water, then removed with a scalpel.</li> <li>• MPO's from the inside were extracted with a needle and bagged separately.</li> <li>• Consolidated with 5% Paraloid B72 (methyl methacrylate co-polymer) w/v in acetone, applied by brush to the whole exterior and only the outer edges of the interior.</li> <li>• The original location of a detached fragment of the lace tag was identified and the fragment was re-adhered with HMG Paraloid B72.</li> </ul>
		<p><b>SF23</b></p> <p><b>Treatment</b></p> <ul style="list-style-type: none"> <li>• The lace tag fragment that detached from the lump of soil contains a large area of MPO's that cannot be removed without breaking the lace tag fragment. Therefore the MPO is not taken out and bagged separately for analysis while still sitting in the lace tag.</li> <li>• The lace tag fragment that is encased in the lump of soil is consolidated with 5% Paraloid B72 (methyl methacrylate co-polymer) w/v in acetone, applied by brush, before being removed from the soil. The soil was softened with 50:50 IMS/R.O. water and removed with a scalpel. Soil and corrosion were removed from the lace tag with 50:50 IMS/R.O. water, with a scalpel. The exterior was consolidated with 5% Paraloid B72 (methyl methacrylate co-polymer) w/v in acetone, applied by brush.</li> </ul>



		<p><b>SF24</b></p> <p><b>Treatment</b></p> <ul style="list-style-type: none"> <li>• The small fragment of lace tag that was present in the lump of soil was left in situ and consolidated with 5% Paraloid B72 (methyl methacrylate co-polymer) w/v in acetone, applied by brush.</li> <li>• A fragment of MPO was present in the crystal box. It was bagged separately.</li> <li>• A fragment of the lace tag was present in the crystal box. It was consolidated with 5% Paraloid B72 (methyl methacrylate co-polymer) w/v in acetone, applied by brush, and bagged separately.</li> </ul>
		<p><b>SF25</b></p> <p><b>Treatment</b></p> <ul style="list-style-type: none"> <li>• Soil and corrosion are cleaned off by swabbing it with 50:50 IMS/R.O. water on a cotton wool swab. The surface was too fragile for removal with a scalpel. In this process, one side of the object appeared to be plated with silver or tin.</li> <li>• Consolidated with 5% Paraloid B72 (methyl methacrylate co-polymer) w/v in acetone, applied by brush.</li> </ul>

		<p><b>SF26</b></p> <p><b>Treatment</b></p> <ul style="list-style-type: none"> <li>• Soil and corrosion are cleaned off by softening it with 50:50 IMS/R.O. water, then removed with a scalpel.</li> <li>• MPO's are preserved on the interior, of which some have been extracted with a needle and bagged separately, but not all could be removed without breaking the lace tag. Therefore they are left in place.</li> <li>• The lace tag is not consolidated because MPO's are still present on the interior.</li> </ul> <p><b>Further treatment</b></p> <ul style="list-style-type: none"> <li>• After further analysis on the MPO's has taken place, this lace tag requires consolidation as the surface is very fragile.</li> </ul>
---	--	---

©2017. York Archaeological Trust Conservation Laboratories,  
 47 Aldwark, York YO1 7BX  
 Tel: (01904) 663036 Fax: (01904) 663002 Email: [ipanter@yorkat.co.uk](mailto:ipanter@yorkat.co.uk)  
 Registered Charity in England & Wales (No. 509060) and Scotland (No. SCO42846)

## APPENDIX 4 – ANALYSIS OF FIBRES FROM THE LACE TAGS

by Dr. M Gleba of the McDonald Institute for Archaeological Research

### Introduction

The present report concerns fibre identification of eight fibre samples from lace tags found at the site of Midland Road 14, Peterborough. The samples were submitted for analysis by archaeological conservator Margrethe Felter of York Archaeological Trust for Excavation and Research Limited (one sample was analysed in 2016, the rest in 2017). The samples were sent in small plastic bags enclosed in acid-free tissue and consisted of several 1-5 mm long fragments.

### Analytical Procedures

Fibre identification and analysis of the first sample was carried out on 04.08.2016, while the rest were analysed in June-July 2017 at the McDonald Institute for Archaeological Research, University of Cambridge. The samples were analysed using Hitachi TM3000 TableTop Scanning Electron Microscope (SEM) in order to determine the morphological characteristics of the fibre and to acquire more detailed surface information for fibre identification. The following instrumental settings were used: analytical condition mode at 15.00 kV accelerating voltage, compositional imaging and working distance of 5-10 mm. The fibres were examined longitudinally and, where possible, in cross section for morphological features. The features were compared with the author's reference collection of plant, animal and synthetic fibres. The reference collection includes processed and unprocessed fibres from plants and animals. It includes the standard plant and animal fibres expected for the prehistoric (flax, nettle, various types of tree bast, sheep wool, goat hair, horse hair) and later periods (cotton, hemp, silk, ramie, camel hair, yak hair), as well as more unusual materials such as hair moss fibre (*Polytrichum commune*) and cotton grass (*Eriophorum angustifolium*).

### Results

Most of the fragments within the samples have a roughly cylindrical shape without any twist or structure (Plates 38-39), and measure 0.5-1-5 mm in diameter (with Sample 23 reaching 2.5 mm), likely reflecting the fact that they were inside hollow cylindrical tags made of sheet copper alloy. They are greenish in colour, having been preserved due to contact with copper alloy. They appear to be almost completely mineralised and are covered with dirt and degradation products. The degree of microstructure preservation varies between the samples, but all appear to be made of the same material. In most cases, fragments have one smoother side, while the other side appears to show its internal structure, consisting of interlacing fibrous strands and some globular structures (Plate 40). Globular structures were observed in half of the samples (Plate 41). These may be remaining fat granules. Samples 6 and 23 had areas of relatively smooth surface resembling epidermal tissue (Plate 42). Sample 11 also contained dark discoid structures with multiple perforations, possible microbial contamination (Plate 43).

The samples do not present any of the features characteristic of plant or animal textile fibres known to the author. However, a search of SEM images online found close comparisons with leather. It is likely that the smoother side of all fragments presents the grain surface, while the fibrous surface is probably corium or flesh layer (Plate 44; Michel 2014, 32).

### **Conclusion**

The fibre analysis of the samples from the lace tags found at Peterborough Midland Road 14 suggests that the material in all cases is leather. This interpretation is supported by the fact that laces are known to have been made of leather in the 15-17<sup>th</sup> centuries. According to Margeson (1993, 22), "lace-tags (or 'aiglets'), made of sheet copper alloy, were used to prevent the ends of laces fraying, and to ease threading, corresponding with the use of points for fastening doublets and hose, and the use of laces for various dress function from the 15th century onwards." Numerous examples of copper alloy lace tags dating to the 15<sup>th</sup>-17<sup>th</sup> centuries are known from across Great Britain, for example from Norwich (Margeson 1993) and London (Portable Antiquities Scheme website). None of the features present in the samples are diagnostic for species identification and further analysis is recommended to identify the animal species, possibly using ZooMS.




Plate 38: SEMicrographs of samples 1, 6, 11, 12, 21, 23, 24, 26 at the lowest magnification showing the cylindrical shape of the fragments (Images: Margarita Gleba).




Plate 39: SEMicrograph of sample 24 showing a cross section (Image:Margarita Gleba)

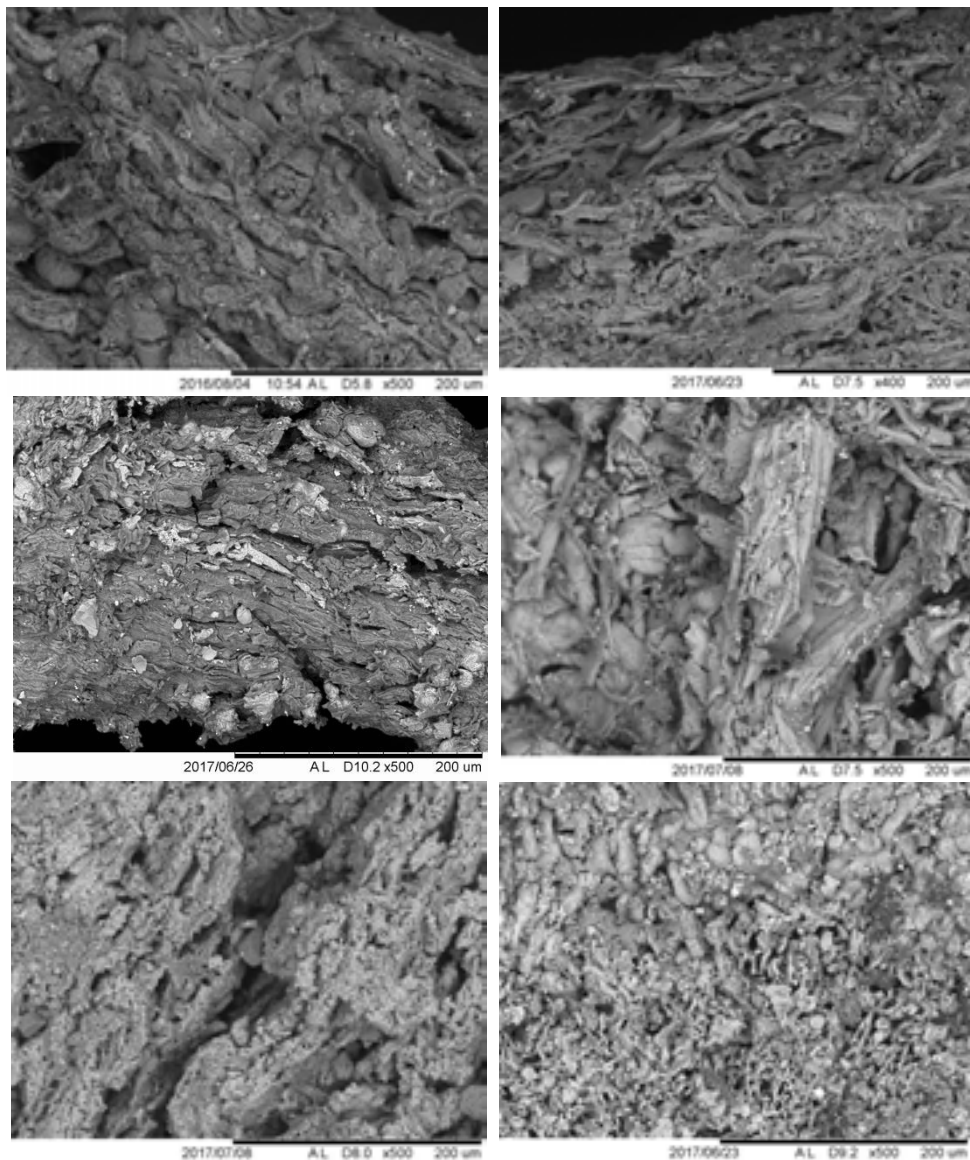


Plate 40: SEMicrographs of samples 1, 11, 12, 21, 23, 26 showing the interlaced fibrous internal structure of the fragments (Images: Margarita Gleba).




Plate 41: SEMicrographs of samples 1, 11, 12, 23, showing globular structures (Images: Margarita Gleba).




Plate 42: SEMicrographs of samples 6, 23, showing smooth surface (Images: Margarita Gleba).




Plate 43: SEMicrographs of sample 11 showing dark discoid structures with multiple perforations (Image: Margarita Gleba).

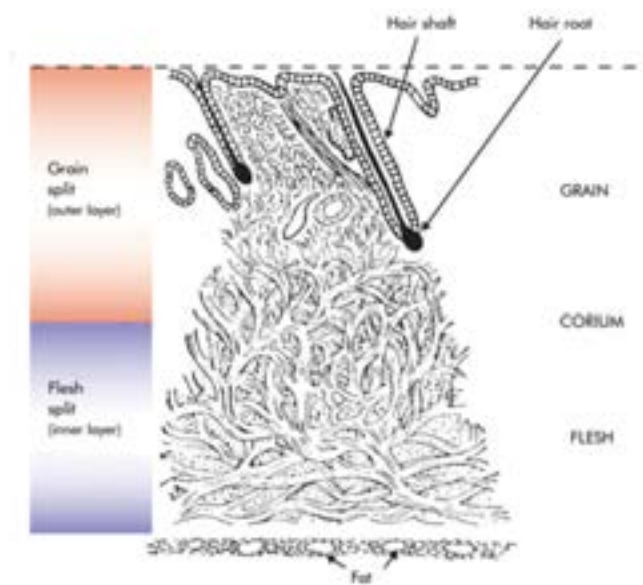


Plate 44: Fibre structure of leather ([https://www.satara.co.uk/spotlight/article\\_view.php?id=194](https://www.satara.co.uk/spotlight/article_view.php?id=194))



FIGURES

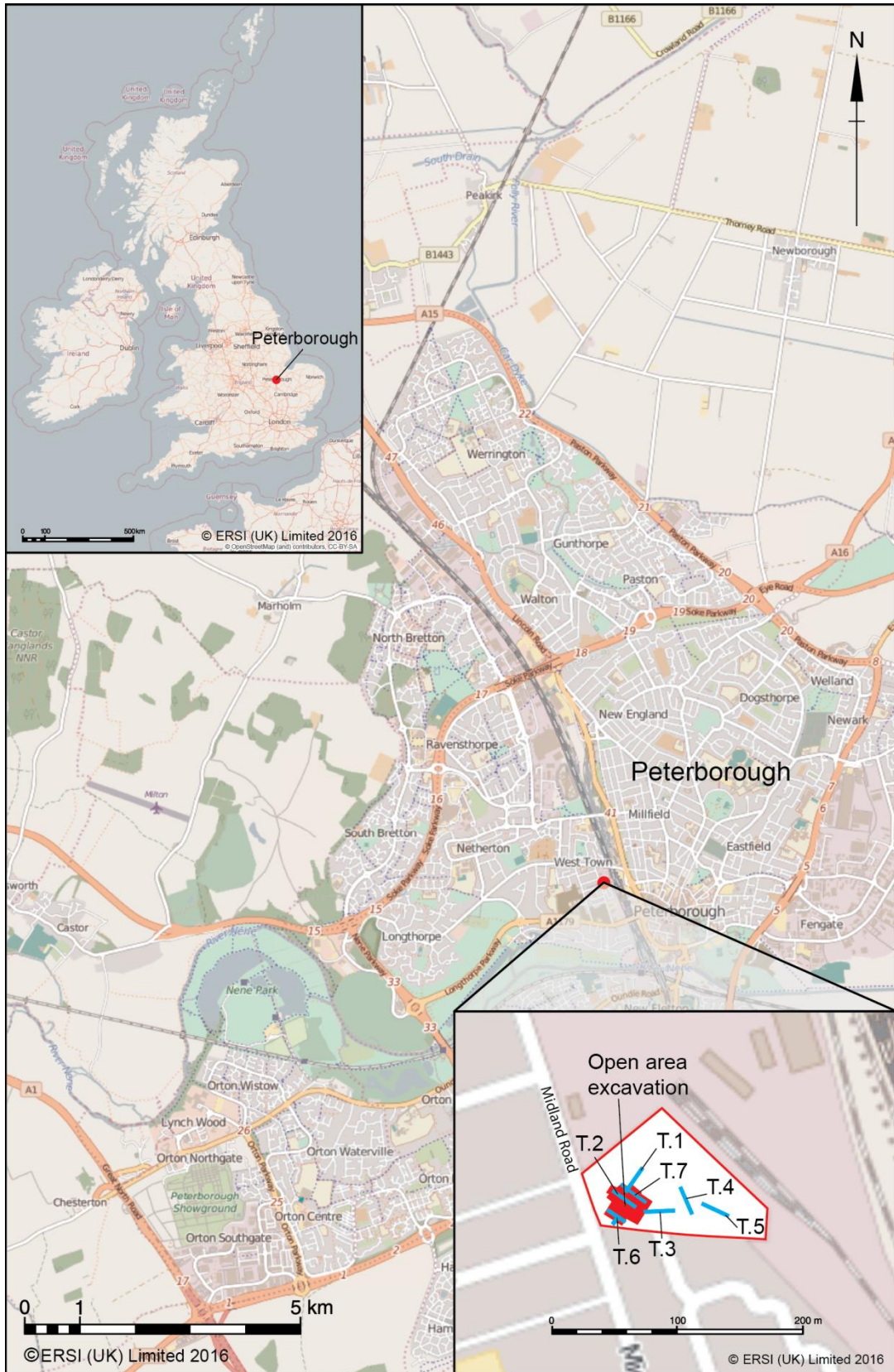
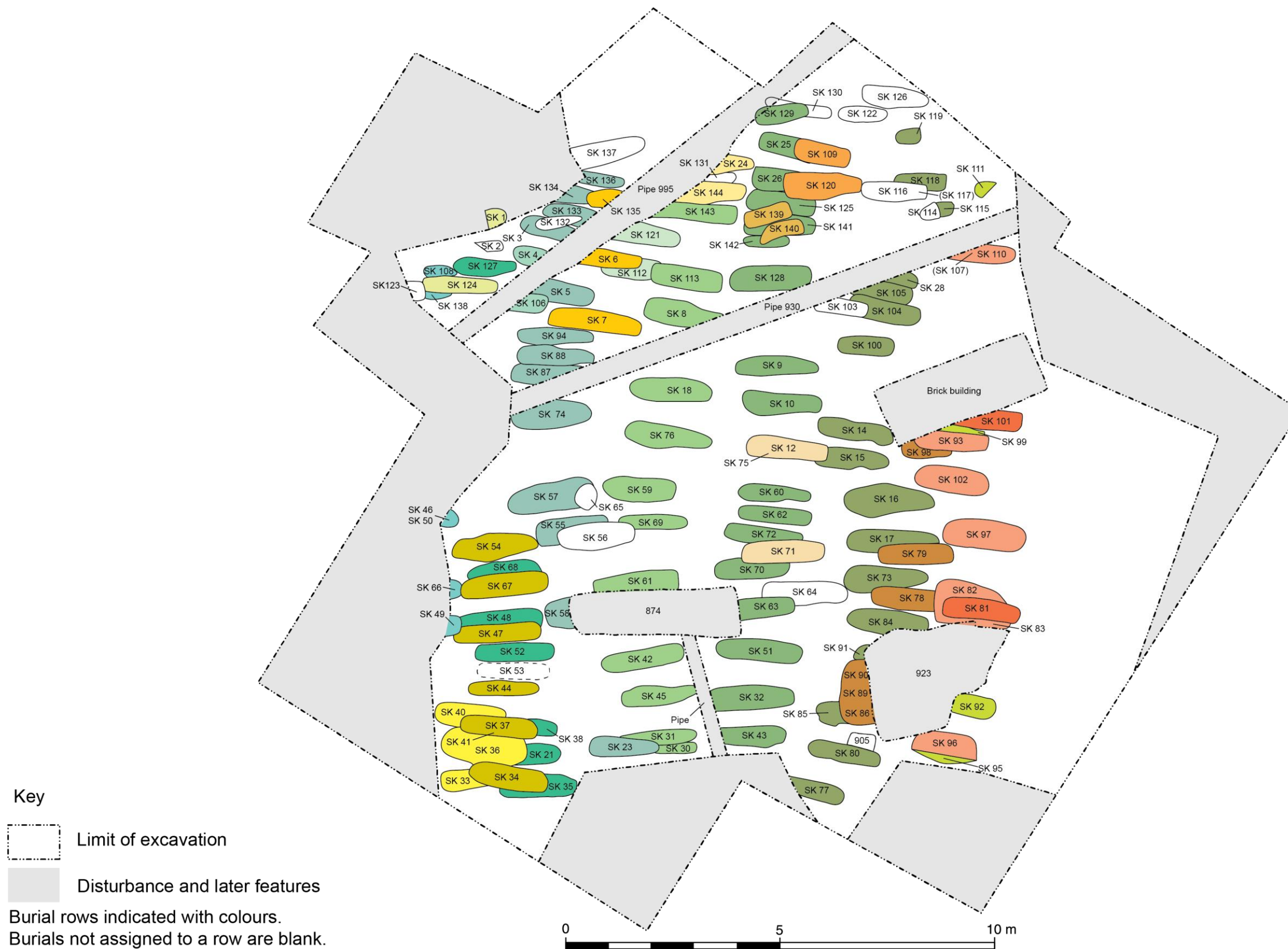


Figure 1: Site location



**Key**  
 [Dashed line] Limit of excavation  
 [Grey shaded area] Disturbance and later features  
 Burial rows indicated with colours.  
 Burials not assigned to a row are blank.

Figure 2: Skeleton numbers

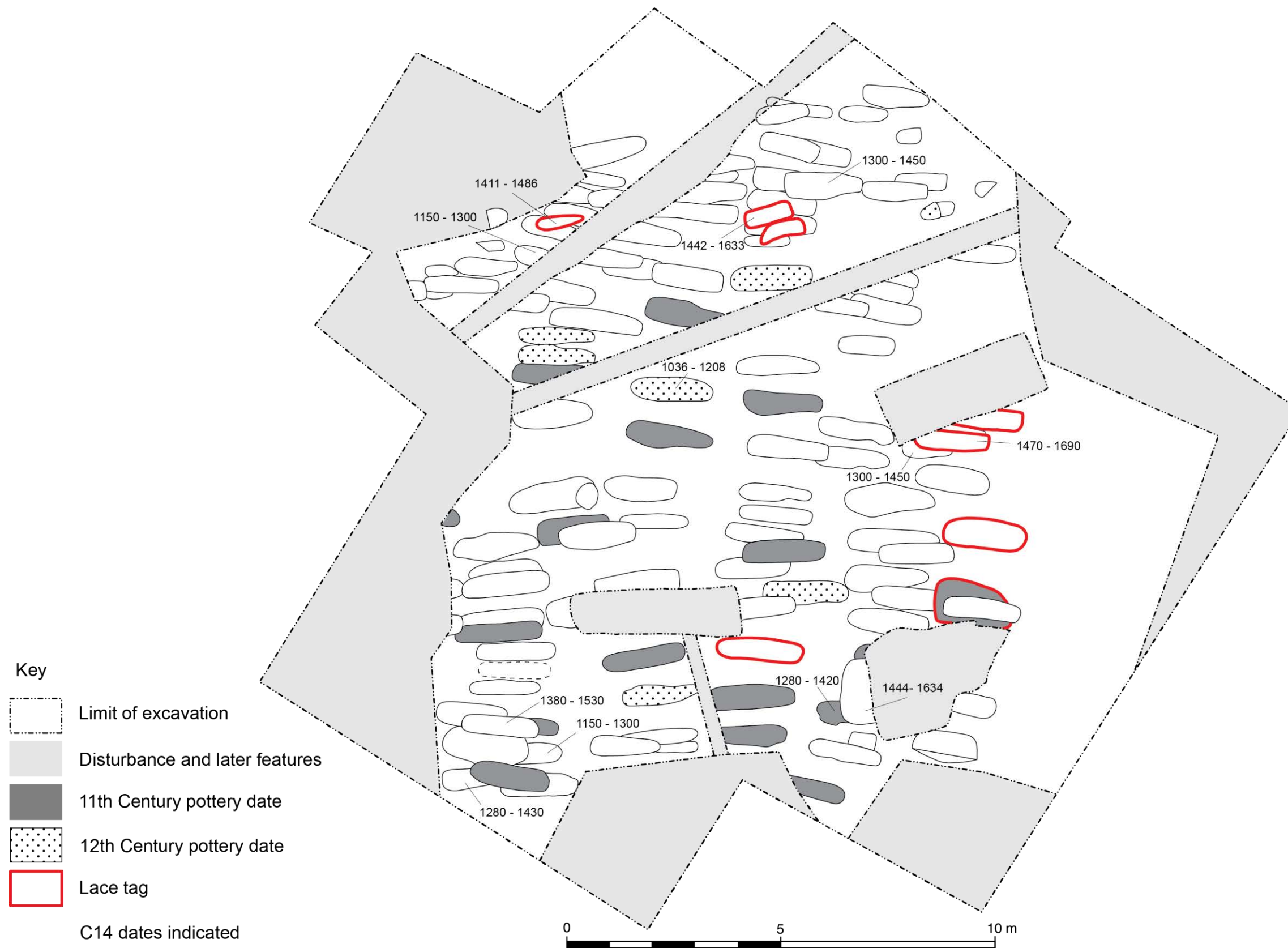

Figure 3: Dating evidence

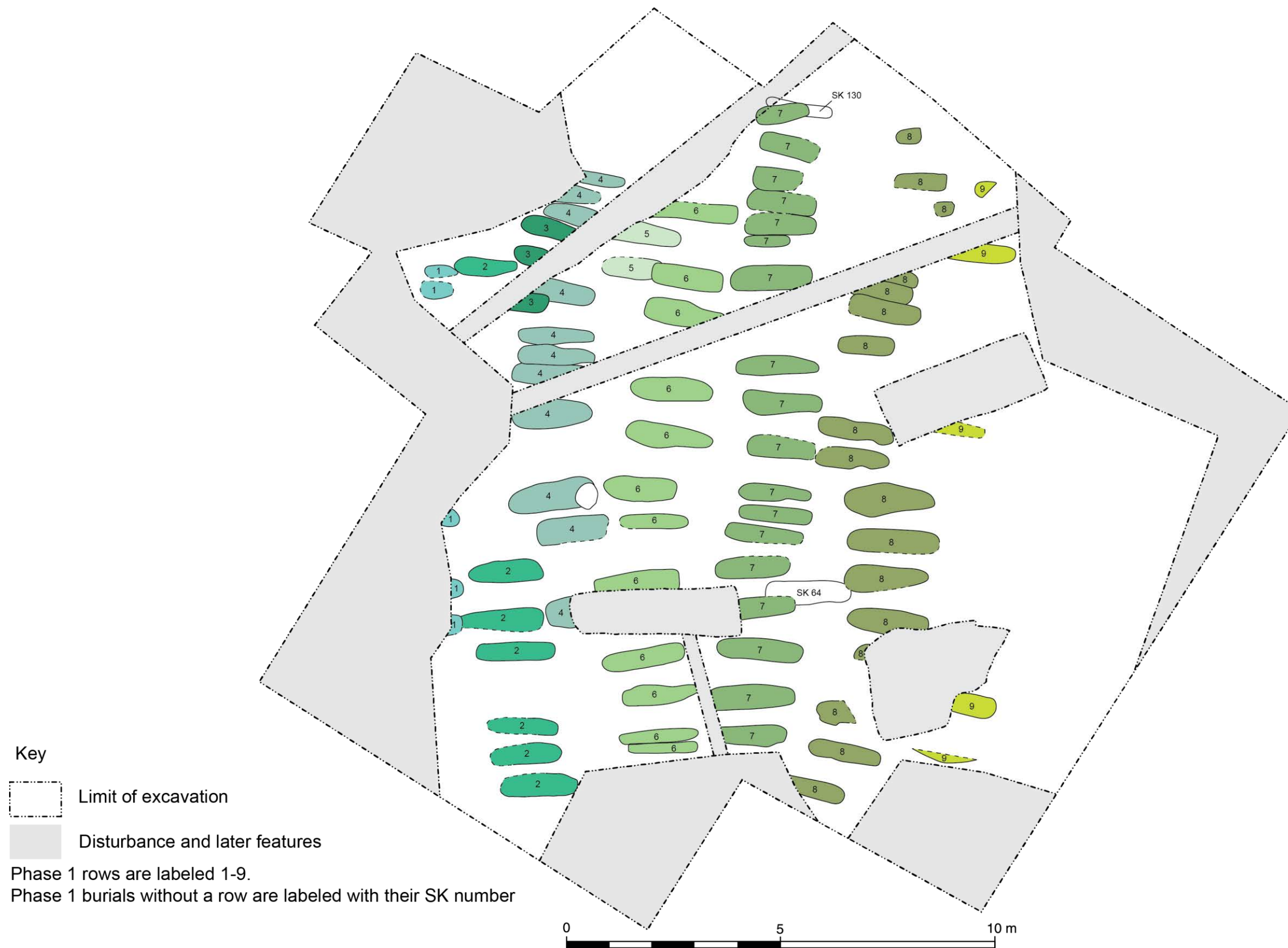


Figure 4: The Phase 1 burials and burial rows

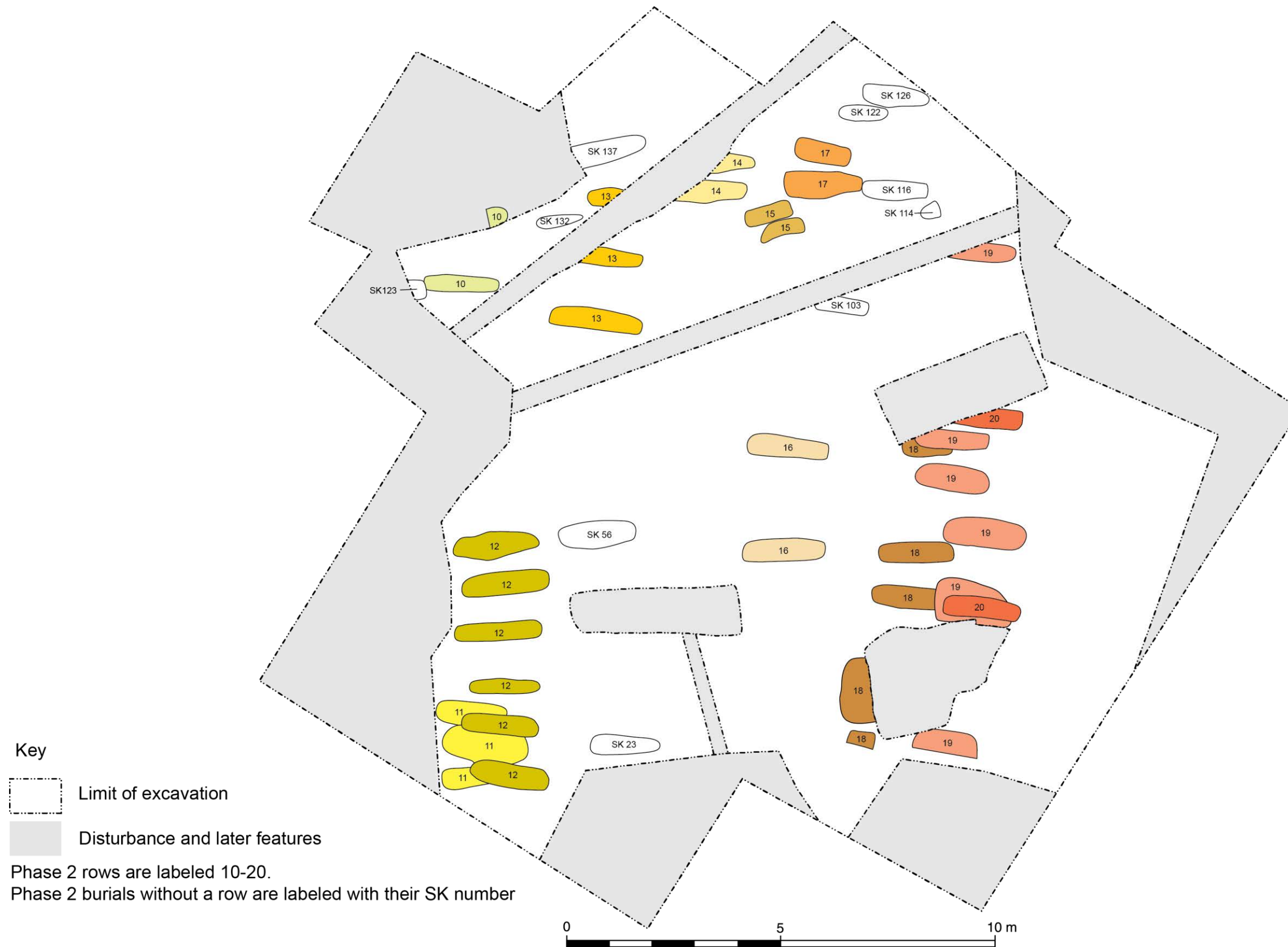

Figure 5: The Phase 2 burials and burial rows

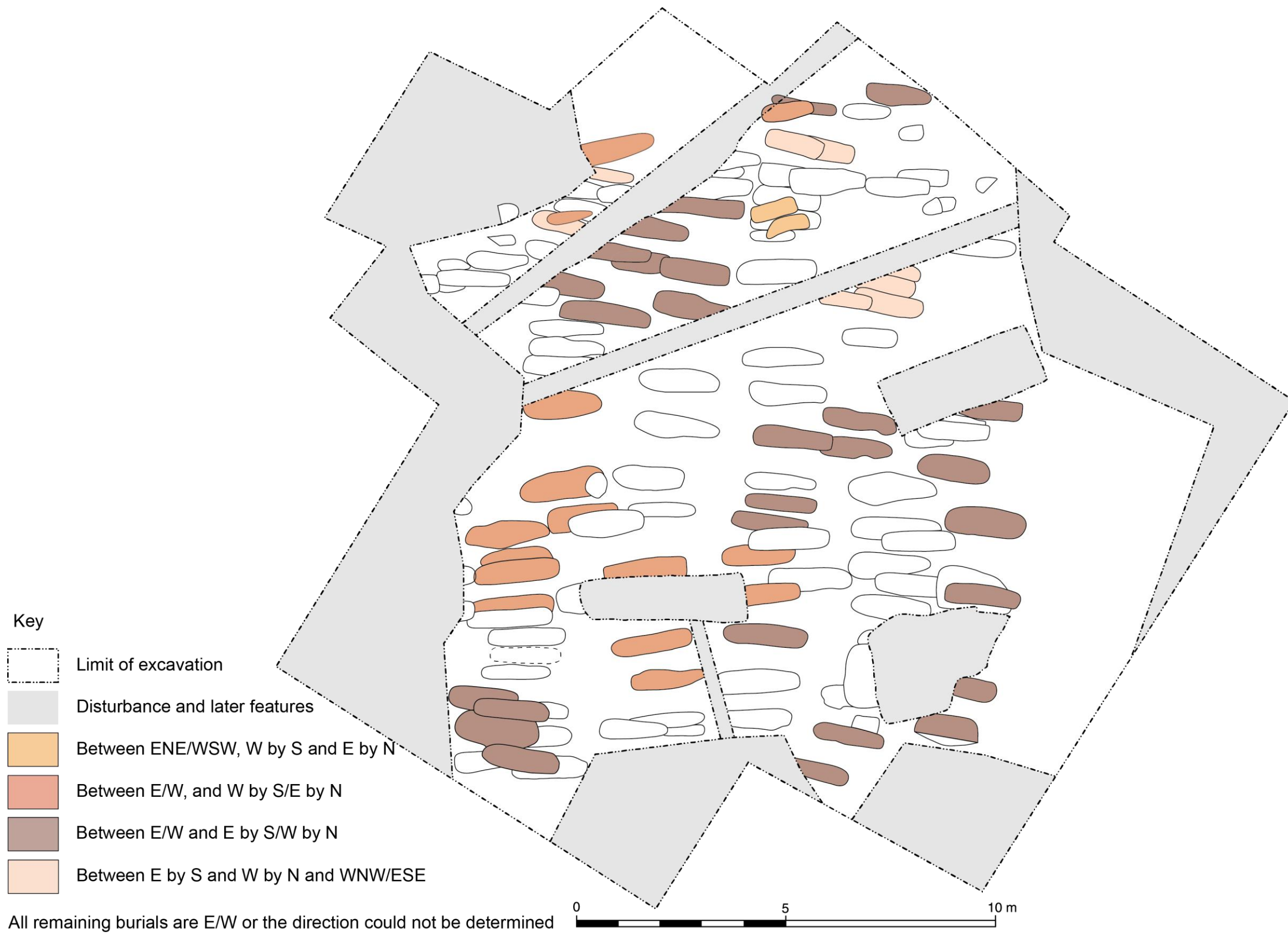


Figure 6: Orientation of burials

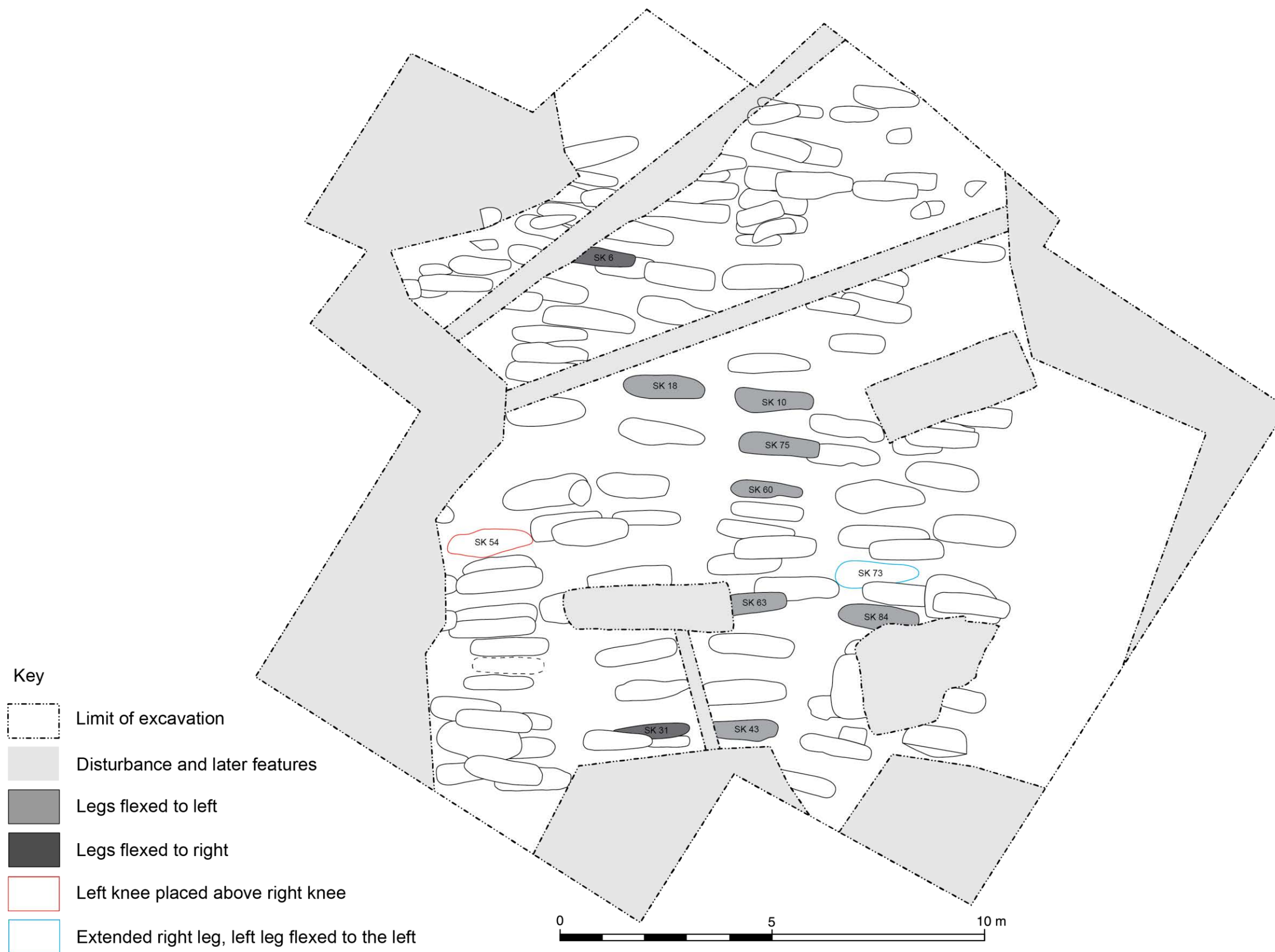

Figure 7: Burial leg positions

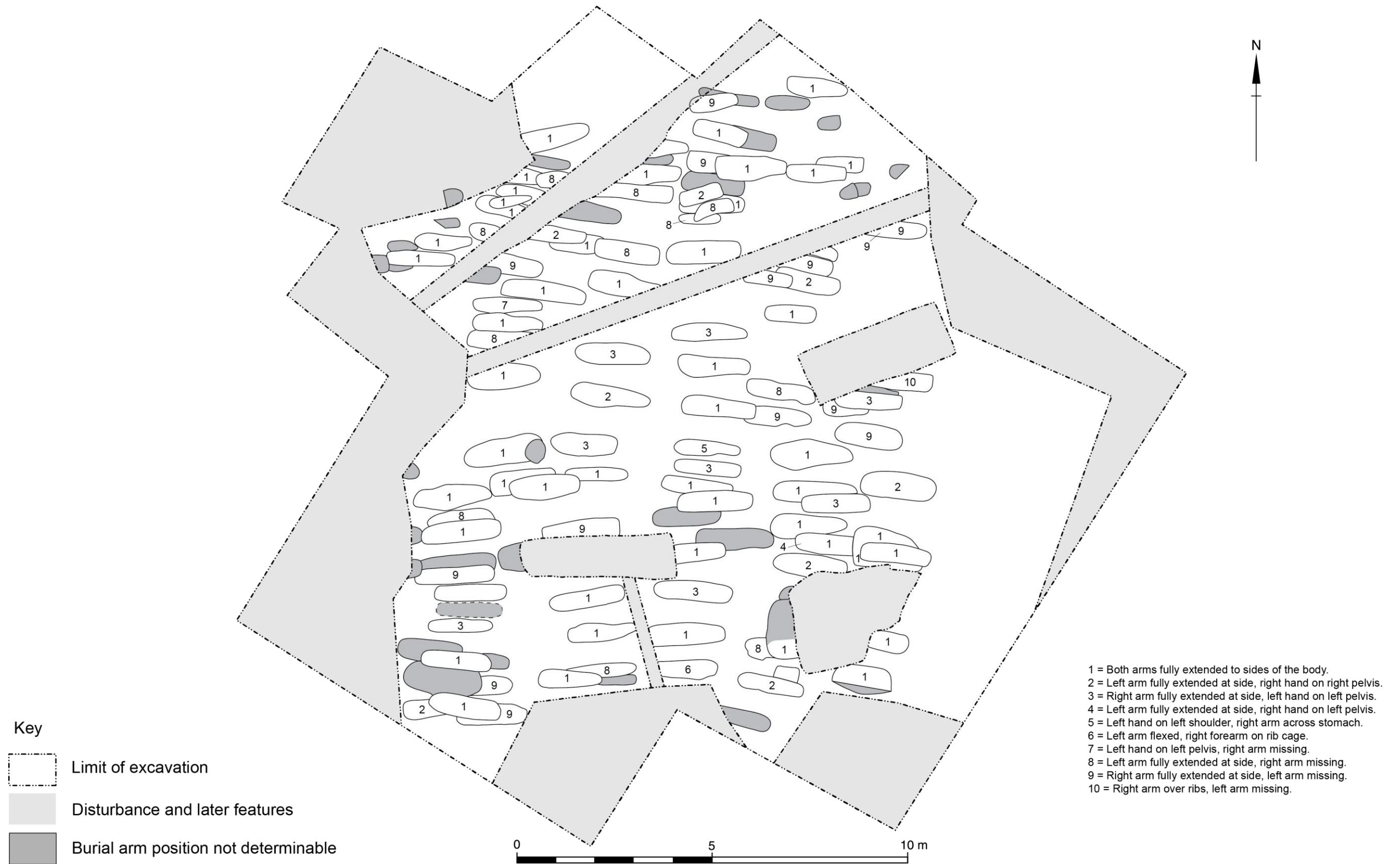


Figure 8: Burial arm positions



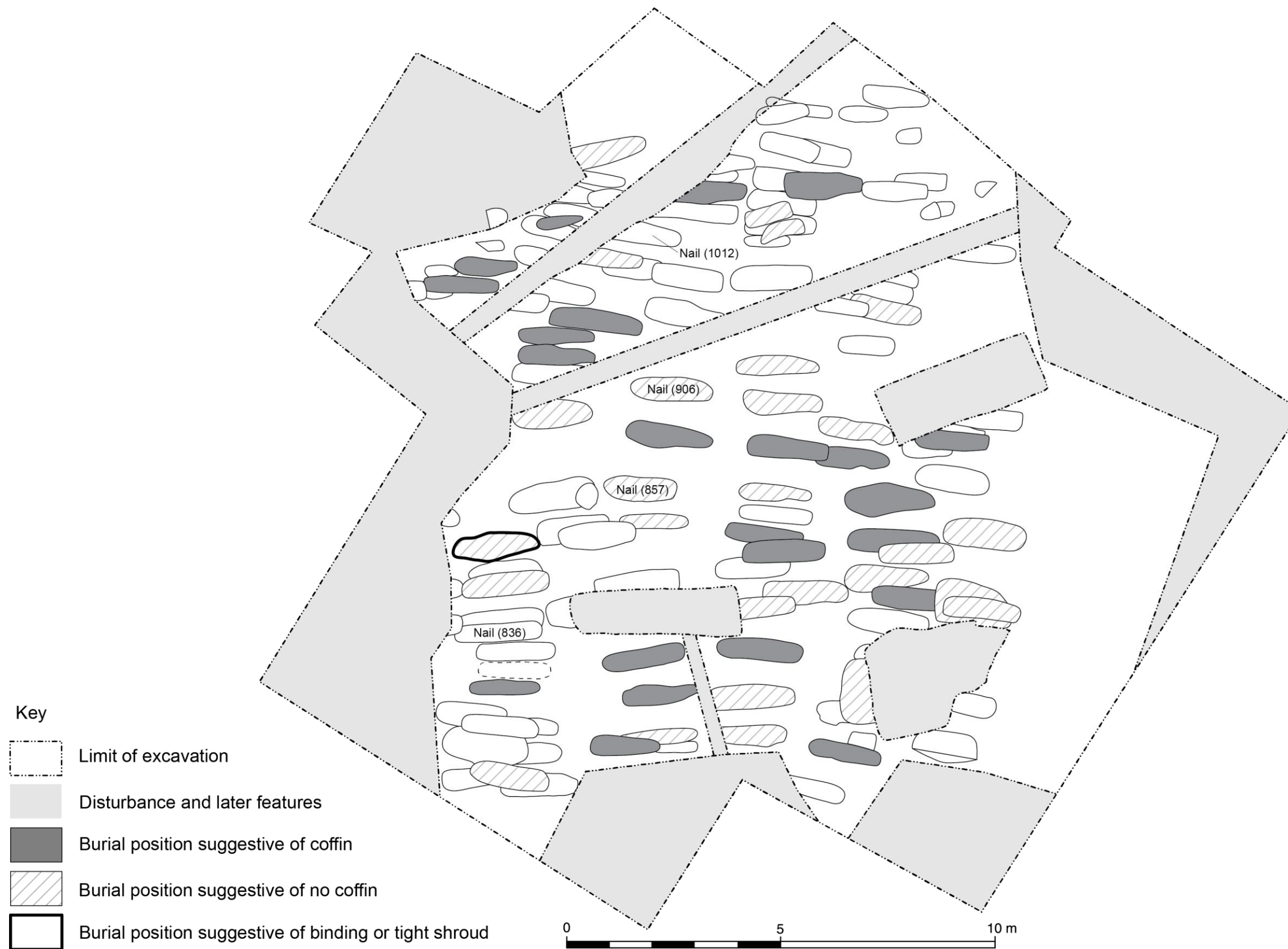

Figure 9: Iron nails and the evidence for coffins and shrouds

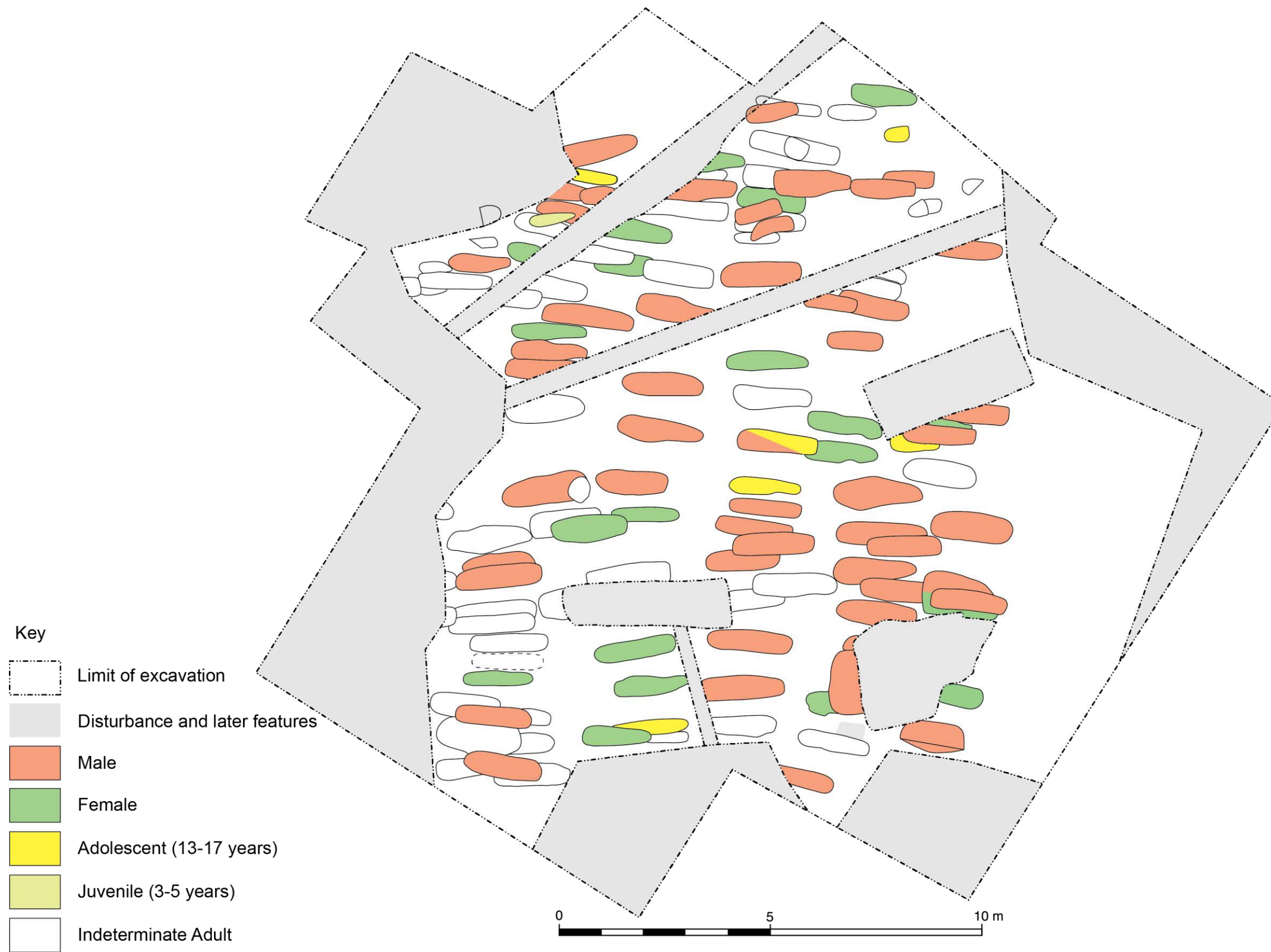


Figure 10: The locations of the males, females and children

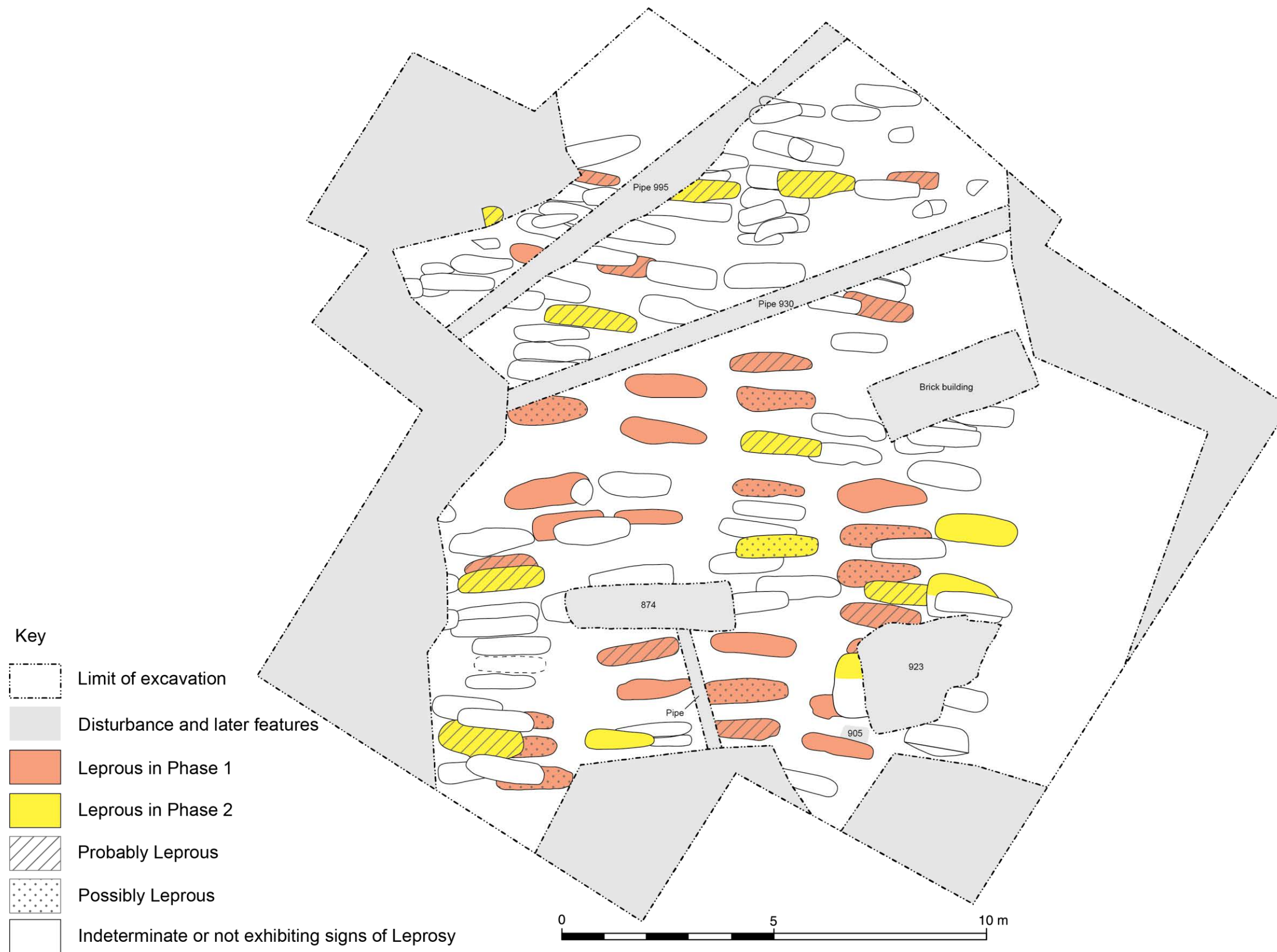


Figure 11: The locations of burials exhibiting leprosy

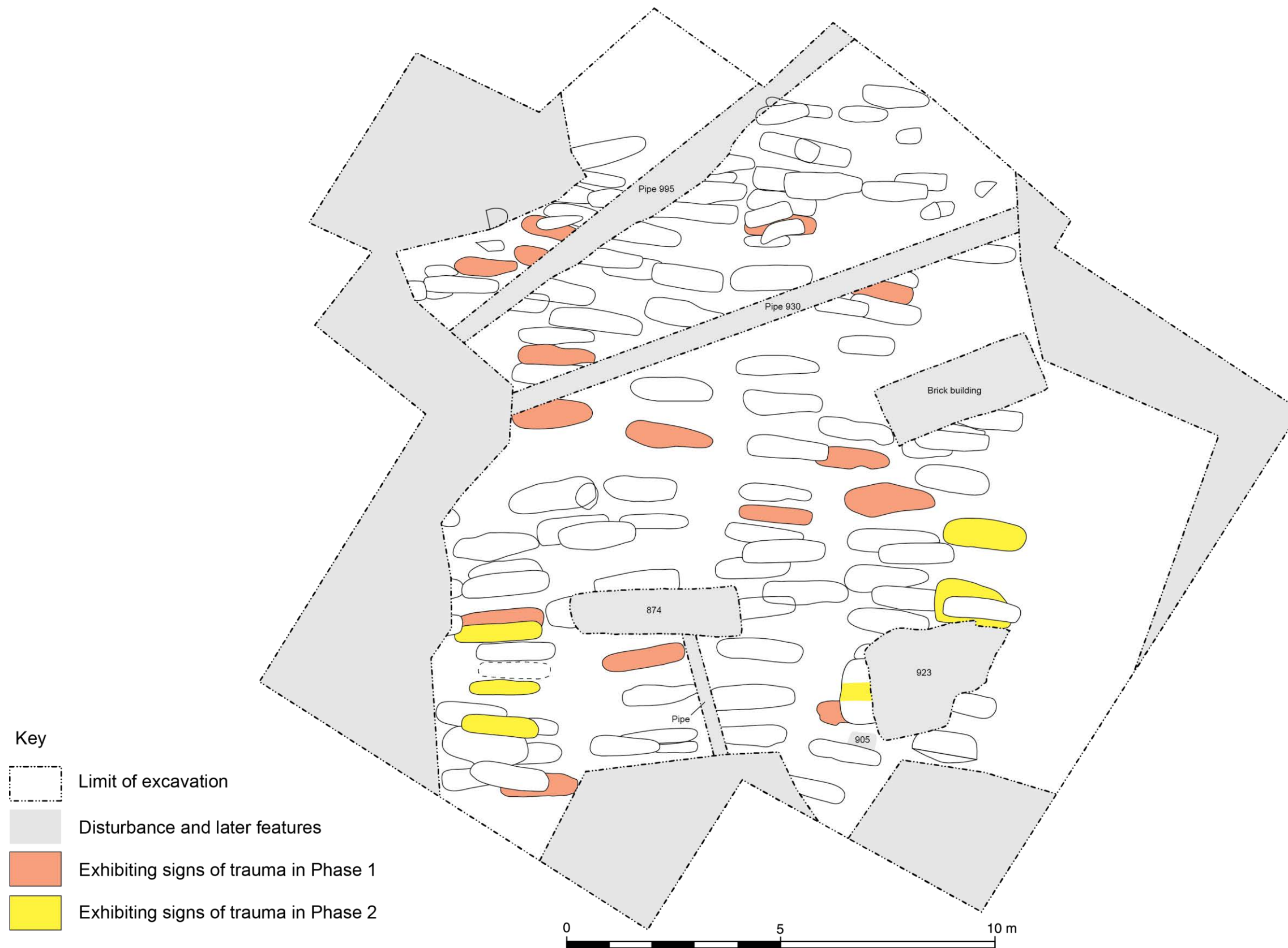


Figure 12: The locations of burials exhibiting signs of trauma and injury