

# **Osteological Analysis**

## **Coppergate**

### **York**

Site Code: 1981.7

NGR: SE 605 515

Report No 1110

August 2010

**Prepared for**

York Archaeological Trust For  
Excavation & Research Ltd  
Cuthbert Morrell House  
47 Aldwark  
York  
YO1 7BX

**Prepared by**

Malin Holst  
York Osteoarchaeology Ltd  
Ivy Cottage  
75 Main Street  
Bishop Wilton  
York YO42 1SR

Reviewed by Niki Gilding

© Copyright York Osteoarchaeology Ltd

**TABLE OF CONTENTS**

	<b>CONTENTS</b>	<b>Page</b>
	<b>Summary</b>	iv
	<b>Acknowledgements</b>	iv
<b>1.0</b>	<b>INTRODUCTION</b>	<b>1</b>
1.1	AIMS AND OBJECTIVES	2
1.2	METHODOLOGY	2
<b>2.0</b>	<b>OSTEOLOGICAL ANALYSIS</b>	<b>2</b>
2.1	PRESERVATION	2
2.2	MINIMUM NUMBER OF INDIVIDUALS	4
2.3	ASSESSMENT OF AGE	4
2.4	SEX DETERMINATION	5
2.5	METRIC ANALYSIS	5
2.6	NON-METRIC TRAITS	6
2.7	CONCLUSION	7
<b>3.0</b>	<b>PATHOLOGICAL ANALYSIS</b>	<b>7</b>
3.1	CONGENITAL CONDITIONS	7
3.1.1	Congenital Hip Dysplasia	8
3.1.2	<i>Coxa vara</i>	9
3.1.3	Transitional Vertebrae	9
3.1.4	Cleft Neural Arches	9
3.1.5	Further vertebral Congenital Anomalies	10
3.1.6	Malformed Manubrium	11
3.2	METABOLIC DISEASE	11
3.2.1	<i>Cribra Orbitalia</i>	11
3.3	INFECTIOUS DISEASE	11
3.3.1	Non-specific Infection	12
3.4	JOINT DISEASE	12
3.4.1	Schmorl's Nodes	12
3.4.2	Degenerative Joint Disease	13
3.4.3	Osteoarthritis	14

3.5	TRAUMA	14
3.5.1	<i>Os Acromiale</i>	14
3.5.2	Osteochondritis Dissecans	14
3.5.3	Excavated Muscle Attachment	15
3.6	CIRCULATORY DISORDERS	15
3.7	MISCELLANEOUS PATHOLOGY	15
3.8	CONCLUSION	16
<b>4.0</b>	<b>DENTAL HEALTH</b>	<b>16</b>
4.1	DENTAL CALCULUS	17
4.2	DENTAL CARIES	17
4.3	DENTAL ABSCESSSES	17
4.4	ANTE-MORTEM TOOTH LOSS	18
4.5	PERIODNTAL DISEASE	18
4.6	DENTAL ANOMALIES	18
4.7	DENTAL CONCLUSIONS	18
<b>5.0</b>	<b>MORTUARY PRACTICE</b>	<b>19</b>
<b>6.0</b>	<b>DISCUSSION AND SUMMARY</b>	<b>19</b>
<b>7.0</b>	<b>FUTURE RECOMMENDATIONS</b>	<b>20</b>
	<b>References</b>	<b>22</b>
	<b>Tables</b>	
1	Summary of archaeological information of complete skeletons	1
2	Summary of osteological and palaeopathological analysis	3
	<b>Plates</b>	
1	Right hip affected by hip dysplasia and healthy left hip (arrow points to new acetabulum)	8
2	Healthy left femur with muscle trauma (arrow) and right femur with CHD from the posterior	8
3	Eburnation and porosity (osteoarthritis) at newly formed hip joint (arrow)	8
4	Cleft neural arch (arrow) in sacrum of Sk30944 and osteoarthritis in articular	10
5	Twisted spinous process (arrow) in fifth cervical vertebra of Sk30944	10

---

6	Distorted manubrium of Sk 30944	11
7	Periosteal reaction at right fibula of Sk 15548	12
8	Schmorl's node in Lumbar vertebra of Sk 15548 (also differently sized transverse processes and porosity and slight osteophyte formation at body)	13
9	Osteochondritis dissecans lesion in calcaneus of Sk 30944	15
10	Caries in right mandible of Sk 15548	17

### **Appendices**

A	APPENDIX A	A
---	------------	---

## Summary

In July 2010 York Osteoarchaeology Ltd was commissioned by the York Archaeological Trust for Excavation and Research Ltd to carry out the osteological analysis of four inhumed skeletons. These were excavated between 1976 and 1981, prior to the redevelopment of 16-22 Coppergate, York (SE 605 515). Based on the artefactual evidence, the skeletons were thought to be Anglo-Scandinavian, dating to around the late ninth century AD. The individuals were buried in pits in a variety of positions and orientations, similar to those from nearby Spurriergate, two of which were radiocarbon dated to the late eighth century AD.

Osteological analysis found that the individuals buried at Coppergate included a young adult female, a mature adult female, an old middle adult male and a possible male adult. Evidence for disc herniation in the spine was noted in three adults. Muscular trauma was observed in all four individuals, particularly in the upper arms.

The two older adults suffered from a variety of congenital anomalies, the majority of which affected the spine and would have had little effect on the individuals. The mature adult female also had congenital hip dislocation, which led to secondary problems; a limp, formation of an artificial hip joint with secondary osteoarthritis, inflammation, disuse and wasting of the affected leg and hip, over-use of the opposite leg causing muscular trauma and osteoarthritis and one-sided degenerative joint disease and osteoarthritis of the spine. She may have used crutches and had unusually robust arms and shoulders, as well as degenerative joint disease in the shoulders, hips and right hand.

The old middle adult male had further congenital defects; a cleft spinous process of the first sacral vertebra and a distorted breast bone. He also suffered from degenerative joint disease and osteoarthritis of the spine and mild degeneration of the shoulders, hips and ribs. He had receding inflammation of the lower limbs and skull.

Both males showed evidence for damage or restriction to their blood supply in the left elbow of the male adult and the heel bones of the old middle adult.

Evidence for childhood stress due to infection or malnutrition was noted in the young adult female.

Dental health was moderate, with poor cleaning practices causing dental plaque concretions to build up and more ante-mortem tooth loss and a larger number of abscesses than the norm, though there were fewer cavities than the early medieval average.

## Acknowledgements

York Osteoarchaeology Ltd would like to thank Christine McDonnell, Richard Hall and Dave Evans of the York Archaeological Trust for Excavation and Research Ltd for their help and support during this project.

## 1.0 INTRODUCTION

York Osteoarchaeology Ltd was commissioned by the York Archaeological Trust for Excavation and Research Ltd to carry out the osteological analysis of four inhumed skeletons. The skeletal remains were recovered during archaeological excavations between 1976 and 1981 at 16-22 Coppergate, York (SE605515) in advance of re-development of the site. According to stratigraphic relationships and artefactual evidence the skeletons are thought to date to the ninth century AD, the Anglo-Scandinavian period.

It is thought that the population of Anglo-Scandinavian Jorvik was between 9,000 and 18,000 (Hall 1994, 42). Very few remains of the inhabitants of Jorvik have been excavated and as a result, the skeletons found at Coppergate provide a vital insight into life in the city during this period. The few other examples that have been found were at St Mary Bishophill, where two skeletons were interred with grave goods indicative of the late ninth or early tenth century (Wenham *et al.* 1987). Further skeletons at this site and at St Mary Bishophill Senior may also date to the Anglo-Scandinavian period, though their date is less certain (Hall 1994, 45). The 131 early phase skeletons from St Andrew's, Fishergate, date from around the Norman Conquest (Stroud and Kemp 1993). Prior to the construction of the Norman Minster in York, a cemetery went out of use beneath it, which contained 155 skeletons dating to the Anglo-Scandinavian period (Hall 1994).

Three of the skeletons from Coppergate were found in close proximity to one another. Skeleton 30944 was complete, though partly disturbed (Table 1) and had been buried in a large pit, either with associated clothing or within a shroud. The skeleton lay with the skull to the northeast in a supine and semi-flexed position, with the left arm bent upwards and the left hand behind the head. Skeleton 30979 lay on a slope or in a large cut only 1m from Skeleton 30944; unfortunately the majority of this skeleton was inaccessible. It appears that this individual lay with the head to the south and that the arm was bent in a similar manner to that of Skeleton 30944. The disarticulated remains of Skeleton 36318 were found in a pit 7m to the south of these two burials. Although this pit also dates to the 9<sup>th</sup> century, as did the features containing the other two skeletons, it is possible that the remains of this individual had been disturbed and removed from an earlier grave.

Table 1 Summary of archaeological information of complete skeletons

Skeleton No	Position	Orientation	Artefacts	Feature Type	Date
15548	Supine, extended. Right arm flexed across abdomen, left arm flexed across lower chest	East-west	None	Pit	Anglo-Scandinavian
30944	Supine, right leg partly disarticulated; left hand behind skull, right arm flexed beside right side of body, left leg extended, right leg semi-flexed	Northeast-southwest	Textile remains adhering to mandible, over chest and below vertebrae and scapulae	Pit	Anglo-Scandinavian
30979	Supine, only parts of left arm, with the upper arm extended beside the head and the forearm bent at an	South-north	None	Slope or pit	Anglo-Scandinavian

	angle to it				
36318	Disarticulated – skull on its side beside the humeri and ribs	-	None	Pit	Anglo-Scandinavian or earlier

Finally, Skeleton 15548 was partly truncated by shoring and was located some distance from the others, in close proximity to the River Foss. This individual was buried more formally in a supine and extended position in an east to west orientation in a shallow grave (see Table 1). It is thought that this burial might be slightly later, dating to the early or mid eleventh century AD.

Notably, five skeletons from nearby Spurriergate were also found in pits. Two of these burials were radiocarbon dated to around 760AD, so predating the Viking conquest of York (Holst 2005). The skeletons were buried in south to north or north to south orientations. Three were laid out supine and extended, one was flexed on the right and the fifth burial had been disturbed and was disarticulated, but had probably been prone. It is likely that all of these burials date to the same period.

## 1.1 AIMS AND OBJECTIVES

The aim of the skeletal analysis was to determine the age, sex and stature of the skeletons, as well as to record and diagnose any skeletal manifestations of disease and trauma.

## 1.2 METHODOLOGY

The skeletons were analysed in detail, assessing the preservation and completeness, as well as determining the age, sex and stature of the individuals (Appendix A). All pathological lesions were recorded and described.

## 2.0 OSTEOLOGICAL ANALYSIS

Osteological analysis is concerned with the determination of the demographic profile of the assemblage based on the assessment of sex, age and non-metric traits. This information is essential in order to determine the prevalence of disease types and age-related changes. It is also crucial for identifying sex dimorphism in occupation, lifestyle and diet, as well as the role of different age groups in society.

### 2.1 PRESERVATION

Skeletal preservation depends upon a number of factors, including the age and sex of the individual as well as the size, shape and robusticity of the bone. Burial environment, post-depositional disturbance and treatment following excavation can also have a considerable impact on bone condition. Preservation of human skeletal remains is assessed subjectively, depending upon the severity of bone surface erosion and post-mortem breaks, but disregarding completeness. Preservation is important, as it can have a large impact on the quantity and quality of information that it is possible to obtain from the skeletal remains.

Surface preservation, concerning the condition of the bone cortex, was assessed using the seven-category grading system defined by McKinley (2004), ranging from 0 (excellent) to 5+ (extremely poor). Excellent preservation implied no bone surface erosion and a clear surface morphology, whereas extremely poor preservation indicated heavy and penetrating erosion of the bone surface resulting in complete loss of surface morphology and modification of the bone profile. The degree of fragmentation was recorded, using categories ranging from ‘minimal’ (little or no fragmentation of bones) to ‘extreme’ (extensive fragmentation with bones in multiple small fragments). Finally, the completeness of the skeletons was assessed and expressed as a percentage: the higher the percentage, the more complete the skeleton.

The bone condition in three of the skeletons was excellent (Grade 0), without surface erosion while the fourth skeleton had moderate bone preservation, with some surface erosion (Table 2). Little fragmentation was observed in any of the skeletons. However, they were of varying completeness, between 5% and 90% complete.

Table 2 Summary of osteological and palaeopathological results

Skeleton No	Preservation*			Age	Sex	Stature (cm)	Dental Pathology	Pathology
	SP	F	C					
15548	0 (Excellent)	Excellent	70%	46+	F	159.32cm	Calculus, caries, periodontitis, lower left incisor rotated, duplication of upper left second incisor (supernumerary teeth)	Schmorl's nodes, spinal DJD, DJD in clavicles, ribs, scapulae, right first metacarpal, right 5 <sup>th</sup> hand phalanx, right trapezium, hips, right proximal femur, osteoarthritis in right hip, right proximal femur, left distal femur, left proximal tibia, sacrum and L5, congenital hip dysplasia on right side, atrophy of right hip, femur, tibia and fibula, coxa vara, spinal congenital anomalies, periosteal reaction at right fibula, bone excavations, enthesopathies
30944	0 (Excellent)	Good	95%	36-45	M	161.5cm	Calculus, periodontitis, three dental abscesses	Schmorl's nodes, DJD in spine, left scapula, right proximal ulna, hips, ribs, osteoarthritis in T2, T3, L5 and sacrum, bilateral os acromiale, congenital anomalies of the spine, manubrium, sacrum, coxa vara, periosteal reactions at tibiae and fibulae, osteochondritis dissecans at calcanei, bone excavations,



								enthesopathies
30979	0 (Excellent)	Good	5%	19+	M	173.63cm	-	Ischemia at ulnar ligament of left humerus, bone excavations
36318	2 (Moderate)	Good	25%	19- 25	F	163.47cm	Calculus	Schmorl's nodes, cribra orbitalia, bone excavation

\* Preservation: SP = surface preservation, graded according to McKinley (2004); F = fragmentation; C = completeness

## 2.2 MINIMUM NUMBER OF INDIVIDUALS

A count of the 'minimum number of individuals' (MNI) recovered from a cemetery is carried out as standard procedure in osteological reports on inhumations in order to establish how many individuals are represented by the articulated and disarticulated human bones (without taking the archaeologically defined graves into account). The MNI is calculated by counting all long bone ends, as well as other larger skeletal elements recovered. The largest number of these is then taken as the MNI. The MNI is likely to be lower than the actual number of skeletons which would have been interred on the site, but represents the minimum number of individuals which can be scientifically proven to be present.

The MNI was four, with four left humeri and scapulae recovered.

## 2.3 ASSESSMENT OF AGE

Age was determined using standard ageing techniques, as specified in Scheuer and Black (2000a; 2000b) and Cox (2000). For non-adults, age estimation is based on dental development and eruption, skeletal development (epiphyseal fusion) and long bone lengths (Scheuer and Black 2000b). In adults, age estimation largely relies on the presence of the pelvis and ribs and uses different stages of bone development and degeneration in order to calculate the age of an individual. It can be supplemented though the examination of dental wear (Brothwell 1981). Age is split into a number of categories, from foetus (up to 40 weeks in *utero*), neonate (around the time of birth), infant (newborn to one year), juvenile (1-12 years), adolescent (13-17 years), young adult (ya; 18-25 years), young middle adult (yma; 26-35 years), old middle adult (oma; 36-45 years), mature adult (ma; 46+) to adult (an individual whose age could not be determined more accurately than that they were eighteen or over).

Skeleton 15548 was a mature adult (46+ years), who exhibited moderate dental wear, but whose auricular surface and pubic symphysis of the hip suggested a mature age. This was corroborated by widespread degenerative joint disease.

The age of Skeleton 30944 was more difficult to assess accurately, as the ageing criteria suggested different ages. The dental wear, rib ossification and left auricular surface suggested an age of 36-45 years, whereas the right auricular surface and the pubic symphyses suggested an age of 26 to 35 years. Considering the widespread degenerative joint disease in this individual, it was decided that the older age was more plausible, indicating that this was an old middle adult.

It was also difficult to determine the age of Skeleton 30979, as this individual was only represented by one humerus and a scapula. Considering the fact the humerus was fully fused, this individual was aged nineteen

years old (the earliest age at which a humerus is fully fused; Scheuer and Black 2000b) or older and was therefore an adult.

Skeleton 36318 was a young adult, with a fusing epiphysis of the proximal left humerus, while the right side was still unfused. The humerus fuses between the ages of sixteen and 22 years (Scheuer and Black 2000b). Parts of the scapula, which fuse between c. 18-23 years (the acromion processes, borders and angles, *ibid*), had completed development. The fusion suggested that this individual was a young adult, aged between nineteen and 25 years. The minimal dental wear observed was also consistent with a young adult age.

## 2.4 SEX DETERMINATION

Sex determination was carried out using standard osteological techniques, such as those described by Mays and Cox (2000). Assessment of sex relies on the preservation of the skull and the pelvis and can only be carried out once sexual characteristics have developed, during late puberty and early adulthood.

The skull and pelvis suggested that Skeleton 15548 was female. The skeletal measurements implied that she was more robustly built than the average female, but was within the lower range of the undetermined measurements, with the exception of the clavicles, which were as long as those of an average male. The relatively robust nature of her arms may have been related to her pathology, which will be discussed below.

Skeleton 30944 was male, as determined using the skull and pelvis. However, his bone measurements suggested that he was relatively gracile, with very short clavicles for a male.

The sex of Skeleton 30979 could only be estimated based on the size of the humeral head and scapula glenoid. Considering the relatively robust nature of the female and gracile nature of the male, this cannot be considered reliable. However, while the scapula was in the undetermined measurement range, the humeral head suggests a male, implying that this could possibly be a male skeleton.

The skull shape and single possible measurement to determine sex of Skeleton 36318 indicated a female, though the young age and the fact that the bones were still fusing would have affected their size and shape.

## 2.5 METRIC ANALYSIS

Stature depends on two main factors, heredity and environment; it can also fluctuate between chronological periods. Stature can only be established in skeletons if at least one complete and fully fused long bone is present, but preferably using the combined femur and tibia. The bone is measured on an osteometric board, and stature is then calculated using a regression formula developed upon individuals of known stature (Trotter 1970).

It was possible to determine the stature of all four skeletons. Skeleton 15548 (mature adult female) was 159.32cm ( $\pm 3.72$ cm) tall, based on the length of her left femur. The second female, Skeleton 36318 (young adult female) was 163.47cm ( $\pm 4.45$ cm) tall. The female average height was 161cm (5ft 3½ in) in the early medieval period, with a range of 152-170cm (Roberts and Cox 2003, 195). However, it must be kept in mind that the majority of the skeletons in this study would have been Anglo-Saxon, rather than Anglo-Scandinavian.

Nevertheless, both females were close to the early medieval average in height. The late eighth century female skeleton from Spurriergate in York was 161.8cm tall (Holst 2005).

The males also differed in height. The more gracile male, Skeleton 30944 (old middle adult male) was 161.51cm ( $\pm 2.99$ cm) tall, while the incomplete male Skeleton 30979 (adult male) was 173.63cm ( $\pm 4.05$ cm) tall. The male mean stature for the early medieval period was 172cm (or 5ft 7 $\frac{3}{4}$ in), with a range of 170-182cm. While the height of Skeleton 30979 height was close to the early medieval mean, the height of the old middle adult Skeleton 30944 was considerably lower, even than the range of skeletal heights of 996 males from the early medieval period in Roberts and Cox's study (2003, 195).

Measurements of the femora and tibiae are used to calculate the shape of the shafts (Bass 1987). In femora this is termed the *meric* index, and in tibiae it is the *cnemic* index. It was only possible to calculate these indices in Skeletons 15548 and 30944. The femora of Skeleton 15548 were different in shape, with the left, healthy bone, being *platymeric* (broad or flat), while the right femur, which was affected by pathology discussed below, was *stenomeric*, a shape that is elongated anterior-posteriorly and is usually only seen in pathological cases. The femora of Skeleton 30944 were also different in shape, although neither was affected by pathology. The right femur was *platymeric* (broad and flat), while the femur leg was *eurymeric* (more rounded). The right tibia of Skeleton 15548 was *mesocnemic* (moderately broad), as was the right tibia of Skeleton 30944, while his left tibia was broad (*eurycnemic*).

The three skeletons whose cranial shape could be measured, had very differently shaped skulls. Skeleton 15548 (mature adult female) had a narrow skull (*dolichocephaly*), Skeleton 30944 (old middle adult male) had an average or medium shaped head (*mesocephaly*) and Skeleton 36318 (young adult female) had a broad or round head (*brachycephaly*).

## 2.6 NON-METRIC TRAITS

Non-metric traits are additional sutures, facets, bony processes, canals and foramina, which occur in a minority of skeletons and are believed to suggest hereditary affiliation between skeletons (Saunders 1989). The origins of non-metric traits have been extensively discussed in the osteological literature and it is now thought that while most non-metric traits have genetic origins, some can be produced by factors such as mechanical stress (Kennedy 1989) or environment (Trinkhaus 1978). A total of thirty cranial (skull) and thirty post-cranial (bones of the body and limbs) non-metric traits were selected from the osteological literature (Buikstra and Ubelaker 1994, Finnegan 1978, Berry and Berry 1967) and recorded.

Cranial traits were observed in Skeletons 15548, 30944 and 36318. These included ossicles at *pterion* (an extra bone on the temple) in Skeletons 15548 and 36318. Skeletons 30944 and 36318 both had *incomplete foramen ovale* (a small hole at the base of the skull that is split into two). Skeleton 30944 also had *ossicle in the lambdoid suture* (additional small bone at the back of the head), *mastoid foramen extrasutural* (a small hole near the ear), a *precondylar tubercle* (a small protrusion at the base of the skull) and *bridging of the supraorbital notch* (variation in the shape of the area above the orbit). Skeleton 36318 had *parietal foramen* (additional small hole towards the back of the head), a *double anterior condylar canal* (small hole at the base of the skull split into two), *accessory lesser palatine foramina* (variation in the number of small holes towards the back of the palate) and *absent zygomaticofacial foramen* (lack of a small hole in the zygomatic bone).

Shared post-cranial traits included *bipartite transverse foramina* (variation in the shape of holes in the neck vertebrae) in Skeletons 15548 and 30944, and *posterior atlas bridging* (an extra bony bridge) in Skeletons 30944 and 36318. Skeleton 15548 also had *septal aperture* (a foramen in the distal humerus), an *acetabular crease* (a fold in the hip joint), *exostosis in trochanteric fossa* (a protrusion of bone at a muscle attachment at the proximal femur) and a large *third trochanter* (a bony lump at the attachment site of the muscle *gluteus maximus* at the femur). Skeleton 30944 had a *vastus notch* and *vastus fossa* (notch and depression in the side of the patella), a *peroneal tubercle* (protruding bone on the medial side of the calcaneus) and *absent anterior calcaneal facets* (a lack of the anterior facet of the calcaneus).

## 2.7 CONCLUSION

The osteological analysis of the skeletal remains established that the skeletons excavated from Coppergate comprised a young adult female (Skeleton 36318) and a mature adult female (Skeleton 15548), both of whom were of average height for the early medieval period. Skeleton 15548 was of relatively robust build, though this might have been related to her pathology, discussed below. The pathological conditions also affected the shape of her right thigh bone.

There were also two male adults, one of whom could not be aged beyond stating that this was an adult (Skeleton 30979), while the other male was an old middle adult (Skeleton 30944). While Skeleton 30979 was of average height for the period, Skeleton 30944 was shorter than any of the early medieval skeletons included in Roberts and Cox's (2003) study and was of gracile build. Although the two females and old middle adult male shared some non-metric traits, these were too limited to make suggestions about genetic relationships between the different individuals.

## 3.0 PATHOLOGICAL ANALYSIS

Pathological conditions (disease) can manifest themselves on the skeleton, especially when these are chronic conditions or the result of trauma to the bone. The bone elements to which muscles attach can also provide information on muscle trauma and excessive use of muscles. All bones were examined macroscopically for evidence of pathological changes.

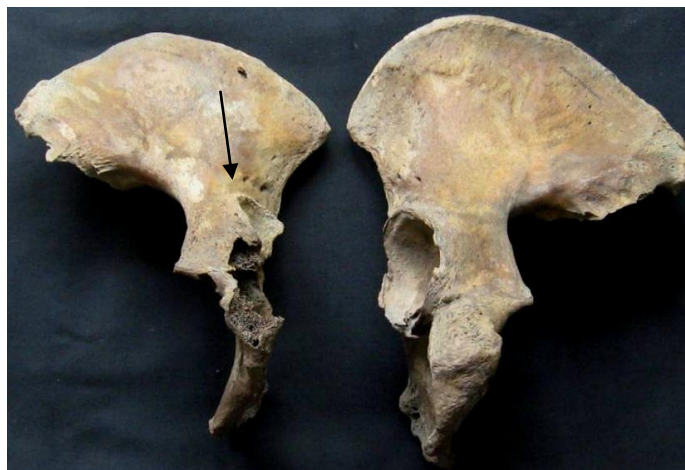### 3.1 CONGENITAL CONDITIONS

The embryological development of an individual can be affected by heredity and the environment, leading to the development of a congenital defect or anomaly (Barnes 1994). The most severe defects are not usually seen in archaeological populations as affected babies are usually miscarried or stillborn, or die shortly after birth. However, less severe developmental anomalies are frequently observed in archaeological populations, and in many cases the affected individual will not have been aware of their condition. The frequency with which these minor anomalies occur may provide information on the occurrence of the severe expressions of these defects in the population concerned (*ibid*). The prevalence of minor anomalies may also inform on maternal health, as poor maternal health can lead to increased frequencies of developmental anomalies (Sture 2001).

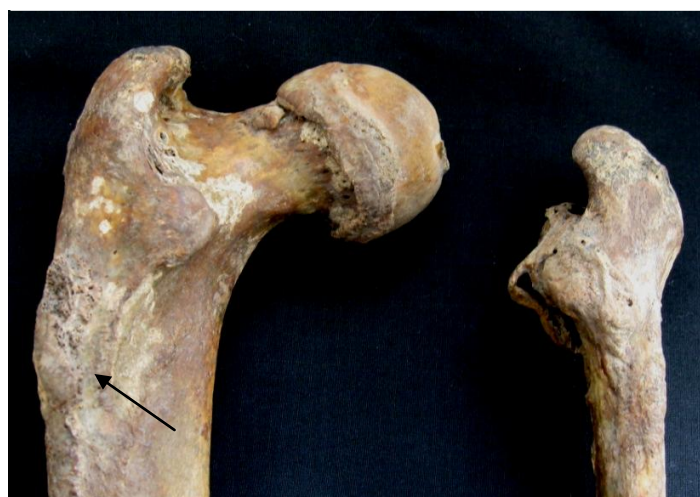### 3.1.1 Congenital Hip Dysplasia

A severe congenital defect was the congenital dislocation of the hip of the mature adult female Skeleton 15548. Congenital hip *dysplasia* (CHD) is characterised by the loss of the normal relationship between the femur and pelvis at the hip joint. CHD is a genetic disorder, which can be treated today, but in antiquity the condition was often not recognised until the child began to walk, and it was too late for treatment (Roberts and Manchester 1995, 38). As a result, the hip joint becomes displaced, which is subsequently exacerbated by muscle action and can cause an abnormal gait, as well as constant pain (*ibid*). The condition creates false hip joints, flat and oval femoral heads and shortened femoral necks (Aufderheide and Rodríguez-Martín 1998, 69). In Skeleton 15548, the right hip was affected (Plate 1). This had led to the formation of a new hip joint that was half circle shaped and slightly concave and was located supero-laterally to where a normal acetabulum would be. The femoral head and the neck of the femur was not formed (Plate 2) and instead the femur articulated with the hip at the point where normally the intertrochanteric line would be. Although an alternative diagnosis to congenital hip dysplasia must be slipped femoral epiphysis (stress fracture of the femoral neck with downward movement of the femoral head), this is unlikely to have been the case, as no evidence of any original acetabulum could be observed.

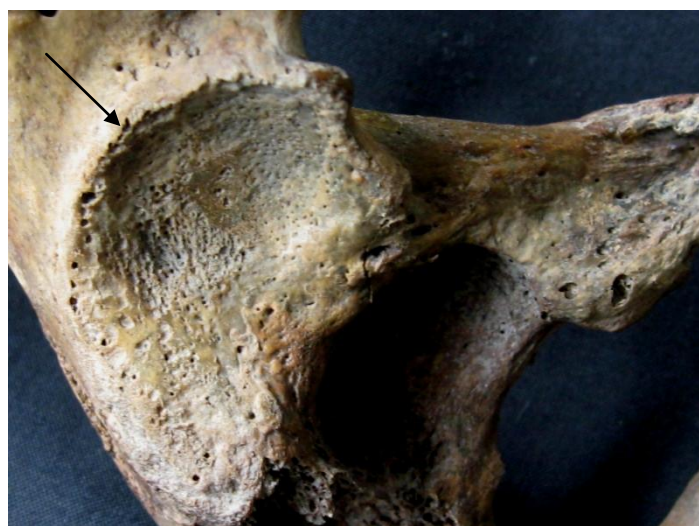
The female suffered from considerable secondary complications to the condition. The pseudoarthrosis (newly formed joint) displayed severe eburnation, indicative of osteoarthritis, both at the pelvis (Plate 3) and at the femur. It is clear that the right leg was hardly used, leading to severe atrophy (wasting) of the right whole femur (see Plate 2; including the distal epiphysis), tibia, fibula and also the pelvis. The left leg, on the other hand, seemed much more robust than normal (see Plate



**Plate 1** Right hip affected by hip dysplasia and healthy left hip (arrow points to new acetabulum)



**Plate 2** Healthy left femur with muscle trauma (arrow) and right femur with CHD from the posterior



**Plate 3** Eburnation and porosity (osteoarthritis) at newly formed hip joint (arrow)

2) and weighed considerably more than the right bone, giving an indication of the much greater bone density in the left femur. The left femur exhibited muscle trauma in the form of a severe enthesopathy (bony spur at the site of a muscle attachment which can be caused by trauma) for *gluteus maximus*, the main muscle of the bottom that moves the hip (see Plate 2). The proximal femoral shaft was unusually broad medio-laterally. The distal joint with the tibia displayed a tiny area of eburnation, indicative of osteoarthritis, as did the left proximal tibia. The right hip was smaller, lighter and generally diminished compared to the left side (see Plate 1). The evidence suggested that the left leg was used extensively and much strain was put on this limb. The bones of the arms and shoulders were well-developed and more robust than those of the average female, suggesting, perhaps, the use of crutches. The spine exhibited unilateral degenerative joint disease on the right side, which was probably also associated with the hip dislocation and also the possible use of a crutch or other walking aid.

CHD tends to be more common in females than males, and occurs most frequently on the left side (Anderson 2000, 213). Early medieval examples of the condition include a male adult from the Golden Minster, St Oswald in Gloucester (Rogers 1999) and another male from Nazeingbury in Essex (Puttnam 1978). Later medieval examples include a middle adult female from Hull Magistrates Court (Holst *et al* 1998) who suffered from bilateral hip dysplasia. An adult female from Jewbury in York had bilateral congenital hip dysplasia, the appearance of which was very similar to the Coppergate case, with atrophy (wasting) of both legs (Brothwell and Browne 1994).

### 3.1.2 *Coxa vara*

*Coxa vara* is a condition where the neck of the femur is short and horizontal and the head of the femur lies below the greater trochanter. It is not present at birth, but develops slowly due to a congenital ossification defect of the femoral neck (Salter 1999). Its cause is still debated, but it may be secondary to rickets, hypothyroidism and osteomalacia (Aufderheide and Rodríguez-Martín 1998, 74). Because of the defect, the muscles of the hip cannot hold the pelvis level during walking and the individual will have a lurching (although painless) type of limp (Salter 1999). Both Skeletons 15548 (mature adult female) and 30944 (old middle adult male) had *coxa vara*. In Skeleton 15548 only the left side was affected by *coxa vara*, with a horizontal femoral neck. The right side was distorted as a result of the congenital hip dysplasia. Both femoral necks of Skeleton 30944 were affected by *coxa vara*.

### 3.1.3 Transitional Vertebrae

Transitional vertebrae can occur at the borders between different types of vertebra, when a vertebra from one group takes on some or all of the characteristics of an adjacent group (Barnes 1994). The process by which this happens is known as ‘border shifting’. Skeleton 15548 (mature adult female) had a first sacral vertebra that had taken on the appearance of a lumbar vertebra at the posterior of the bone. The crude prevalence rate for lumbarisation for the early medieval period was 0.2% (Roberts and Cox 2003, 175).

### 3.1.4 Cleft Neural Arches

Cleft neural arches occur when the two halves of the neural arch, which surrounds and protects the spinal cord, fail to unite during development (Barnes 1994). The gap in the bone is filled with a tough fibrous tissue in life, and so the spinal cord remains protected and these defects are asymptomatic. Skeleton 30944 (old middle adult

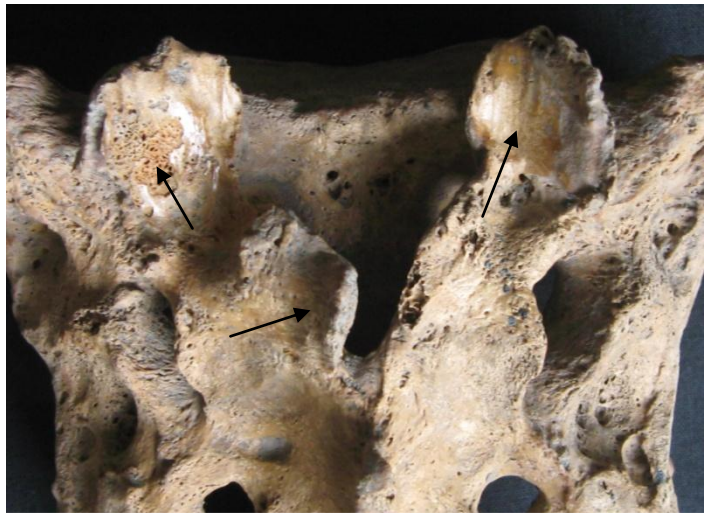male) had a cleft spinous process of the first sacral vertebra (Plate 4), which is relatively common (*ibid*).

### 3.1.5 Further vertebral Congenital Anomalies

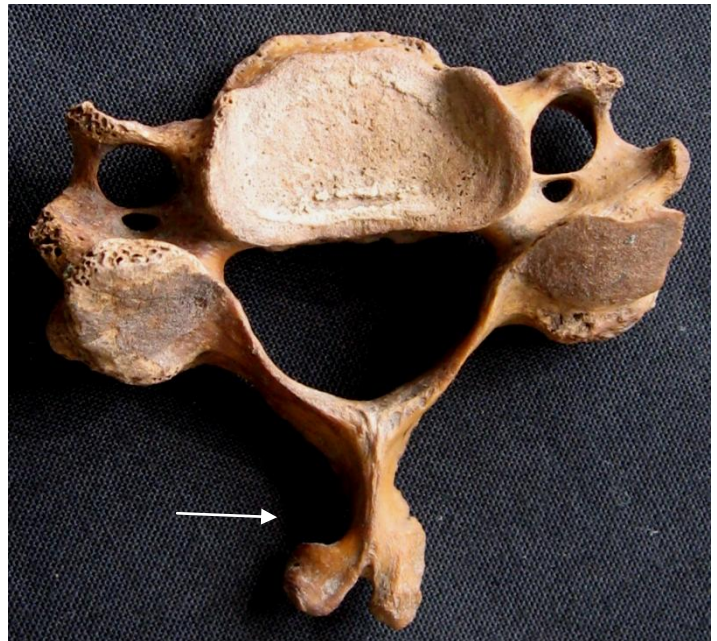
Minor congenital anomalies of the spine are very common. Most congenital anomalies, such as the majority of axial anomalies, develop as a result of abnormalities or disruptions during foetal development. Axial defects are commonly observed in archaeological skeletons, and are a result of the impact of developmental disturbances in the first trimester of pregnancy, when the axial skeleton forms.

Both Skeletons 15548 and 30944 had a number of congenital anomalies of the spine. Skeleton 30944 (old middle adult male) had a cleft or bifid first sacral vertebral neural arch, as discussed above. The spinous process of the fifth cervical vertebra was twisted to the left (Plate 5), while the left intertubercular lamella of the transverse process of the seventh cervical vertebra was unusually wide. These were minor congenital anomalies that would not have affected the well-being of this man.

A complete and well preserved spine is required to determine whether any variation in the expected number of vertebrae in each vertebral group is the result of a genuine extra vertebral segment (i.e. an additional vertebra) or due to a border shift, and if the latter, what kind of shift has taken place. Unfortunately, the spine of Skeleton 15548 was incomplete and as a result it was not possible to identify whether vertebrae were missing post-mortem or were congenitally absent. Skeleton 15548 possibly had only eleven, instead of the usual twelve thoracic (central) vertebrae. It is, however, possible that one of these vertebrae was lost post-mortem. The superior right articular facets protruded superiorly beyond the left side in the sacrum and the twelfth thoracic vertebra, while the inferior left articular facets protruded inferiorly by 3mm compared with the right side in the third, fourth and fifth lumbar vertebrae. The articular facets on the right side of the ninth, tenth and eleventh thoracic vertebrae were larger than those on the left. The transverse processes of the third, fourth and fifth lumbar vertebrae were twisted and the right sides were smaller than the left. The spinous process of the fourth cervical vertebra was also slightly twisted.



**Plate 4** Cleft neural arch (arrow) in sacrum of Sk30944 and osteoarthritis in articular facets (arrows)



**Plate 5** Twisted spinous process (arrow) in fifth cervical vertebra of Sk30944

### 3.1.6 Malformed Manubrium

Skeleton 30944 (old middle adult male) also had an unusually shaped manubrium (breast bone), which was 4mm longer at the left half compared with the right half (Plate 6). This would not have had any effect on the individual.

## 3.2 METABOLIC DISEASE

### 3.2.1 *Cribra Orbitalia*

*Cribra orbitalia* manifests as fine pitting in the orbital roof. It develops during childhood, and often recedes during adolescence and early adulthood. Until recently, it was thought that iron deficiency anaemia was a likely cause of the lesions (Stuart-Macadam 1992), but a recent study by Walker *et al.* (2009) has demonstrated that other types of anaemia, including megaloblastic anaemia and haemolytic anaemia, must be considered



**Plate 6** Distorted manubrium of Sk 30944

instead. Megaloblastic anaemia is considered a likely cause of the lesions in the New World, and would arise following a diet deficient in Vitamin B<sub>12</sub> (i.e. plant-based and lacking in animal products) and/or folic acid. Infections and infestations with gut parasites as a result of poor sanitation may have exacerbated such dietary deficiencies (*ibid*). Haemolytic anaemia (e.g. sickle cell anaemia and thalassemia) may have been important in the development of *cribra orbitalia* in areas of the Old World prone to malaria, but in Europe it was suggested that conditions such as scurvy (Vitamin C deficiency) or chronic infections may be more likely causes (*ibid*). *Cribra orbitalia* is often used as an indicator of general stress (Lewis 2000; Roberts and Manchester 2005) and is frequently found associated with agricultural economies (Roberts and Cox 2003).

*Cribra orbitalia* was present in the right orbit of Skeleton 36318 (young adult female), which indicates this individual had experienced a period of stress during childhood. *Cribra orbitalia* was not observed in the orbits of Skeletons 15548 or 30944. Roberts and Cox (2003, 187) note that 24.6% of orbits (and 7.6% of individuals or 6.1% of sexed adults) were affected by *cribra orbitalia* in early medieval populations. In the early medieval York Minster population, the crude prevalence rate was 10% (quoted in Roberts and Cox, *ibid*).

## 3.3 INFECTIOUS DISEASE

Bone can respond to infection through depositing new bone at the site of an inflammation. Initially this bone is disorganised and porous, and is termed ‘woven bone’; the presence of this type of bone indicates an infection that was active at the time of death. With time, the woven bone deposits are remodelled, becoming smooth and organised ‘lamellar bone’. The presence of lamellar bone suggests the infection had healed. Bone requires time to respond to infection, so new bone formation only occurs with chronic conditions (i.e. where the person survived for a time before recovery or death). Acute conditions, where the person either died or recovered



within a short space of time, will not leave evidence in the skeleton (Roberts and Manchester 2005; Ortner 2003).

### 3.3.1 Non-specific Infection

Identification of a specific infection is difficult in archaeological skeletal remains since the bone-changes caused by different infections are usually similar in appearance. The exceptions are tuberculosis, leprosy and treponemal disease (including syphilis), where the changes are distinctive enough to allow these diseases to be recognised (Roberts and Manchester 2005; Ortner 2003). Other infectious diseases are described as ‘non-specific’ infections, as the bone-changes observed are too general to allow diagnosis.

Skeleton 15548 (mature adult female) had distinct striated lamellar bone on the right fibula (Plate 7). She had suffered from a periosteal reaction (inflammatory lesions) of her left lower leg that was healing prior to her death. It is probable that these changes were also secondary to the congenital hip dysplasia and disuse of the right leg.



**Plate 7** Periosteal reaction at right fibula of Sk 15548

Both tibiae and fibulae of Skeleton 30944 showed evidence for marked striated lamellar bone at the shafts, suggesting periosteal reactions. The inflammation of the legs was healing at the time of death. Inflammation of the lower legs is a particularly common finding in archaeological populations (Roberts and Manchester 2005), and Roberts and Cox (2003, 235) observed that 14.05% of individuals from the early medieval period were affected.

The same individual also exhibited mild pitting on the outer (ectocranial) surface of the skull, around the sagittal suture at the top of the head. This is probably a periosteal reaction, most likely to be the result of mild scalp inflammation.

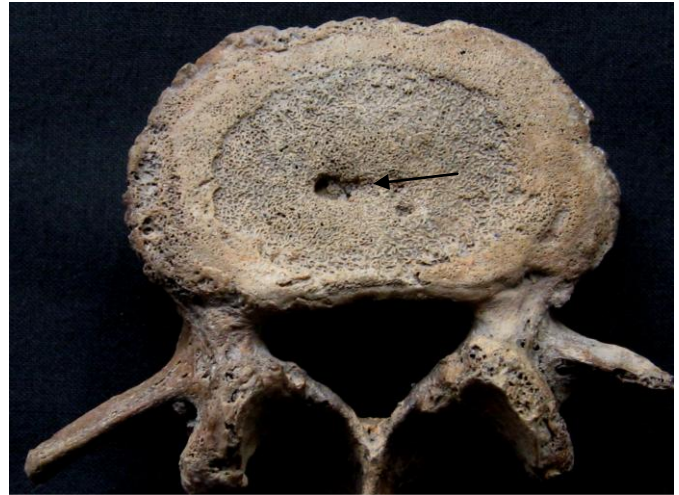## 3.4 JOINT DISEASE

### 3.4.1 Schmorl's nodes

Schmorl's nodes are indentations in the upper and lower surfaces of the vertebral bodies caused by the pressure of herniated vertebral discs (Aufderheide and Rodríguez-Martín 1998). Discs may rupture due to trauma, but vertebrae weakened by infection, osteoporosis or neoplastic disease may be more vulnerable (Roberts and Manchester 2005). Schmorl's nodes are often associated with degenerative changes to the vertebral bodies (Aufderheide and Rodríguez-Martín 1998, Hilton *et al.* 1976) and are most commonly seen in the lower thoracic vertebrae (*ibid.*).

Schmorl's nodes affected all three individuals with surviving spines. Skeleton 36318 (young adult female) had depressions in the 6<sup>th</sup>, 9<sup>th</sup>, 10<sup>th</sup>, 11<sup>th</sup> and 12<sup>th</sup> thoracic vertebrae and the 1<sup>st</sup> lumbar vertebra. The old middle adult male (Skeleton 30944) had Schmorl's nodes in the 6<sup>th</sup>, 7<sup>th</sup>, 9<sup>th</sup> and the 12<sup>th</sup> thoracic vertebrae and the 2<sup>nd</sup>, 3<sup>rd</sup> and

4<sup>th</sup> lumbar vertebrae. The old middle adult male (Skeleton 15548) had Schmorl's nodes in the 8<sup>th</sup> thoracic vertebra and all lumbar vertebrae (Plate 8). The lesions were mild in the two older adults and mild to moderate in the young adult female. The location of the lesions in the lower part of the thoracic spine and lumbar vertebrae was fairly typical for Schmorl's nodes (Hilton *et al.* 1976). Roberts and Cox (2003, 195) found that 2.9% of individuals and 16.6% of vertebrae were affected by Schmorl's nodes in the early medieval period, which was much less than the prevalence at Coppergate (35.8%).



**Plate 8** Schmorl's node in Lumbar vertebra of Sk 15548 (also differently sized transverse processes and porosity and slight osteophyte formation at body)

### 3.4.2 Degenerative Joint Disease

The most common type of joint disease observed tends to be degenerative joint disease (DJD). DJD is characterised by both bone formation (osteophytes) and bone resorption (porosity) at and around the articular surfaces of the joints, which can cause great discomfort and disability (Rogers 2000).

The two older adults, Skeletons 15548 (female) and 30944 (male) had DJD in the extraspinal skeleton. Skeleton 15548 (mature adult female) had mild to moderate DJD in the shoulders (scapula right glenoid, both acromiae, both medial and lateral clavicles), ribs, right trapezium (wrist bone), right first metacarpal, right fifth intermediate hand phalanx and left acetabulum. More severe DJD was observed in both auricular surfaces (joints between the hips and the sacrum). Skeleton 30944 (old middle adult male) showed evidence for mild extraspinal DJD in the ribs, right medial clavicle, left scapula glenoid, right proximal ulna, both hip sockets and also the auricular surfaces. Extraspinal DJD was noted in 8.3% of individuals in the early medieval period (Roberts and Cox 2003, 197).

Spinal DJD was not uncommon in the early medieval period, with a crude prevalence rate of 12.1% (Roberts and Cox 2003, 196). Although Skeleton 36318 (young adult female) had a partial spine, no DJD was observed, probably because this individual was so young. Skeletons 15548 (mature adult female) and 30944 (old middle adult male) had DJD of the spine. Skeleton 15548 had mild to moderate osteophytes in the bodies of the 1<sup>st</sup>, 5<sup>th</sup> and 6<sup>th</sup> cervical vertebrae and from the 7<sup>th</sup> thoracic vertebra to the sacrum (see Plate 8), with osteophytes becoming severe in the upper lumbar vertebrae. Notably, the osteophytes occurred only on the right side of the vertebral bodies. It is likely that the degenerative joint disease of this female was secondary to the disuse of her right leg and the use of a walking aid, such as a crutch, therefore causing unilateral degeneration. Notably, the articular vertebral facets of this individual were not affected by DJD. Skeleton 30944 showed evidence for mild to moderate DJD in the 2<sup>nd</sup> to 7<sup>th</sup> cervical vertebral bodies and the bodies from the 4<sup>th</sup> thoracic vertebra to the sacrum. The articular facets of the 3<sup>rd</sup> cervical vertebra, 1<sup>st</sup>, 2<sup>nd</sup>, 3<sup>rd</sup>, 10<sup>th</sup>, 11<sup>th</sup>, 12<sup>th</sup> thoracic vertebrae and from the 1<sup>st</sup> lumbar vertebra to the sacrum were affected by DJD.

### 3.4.3 Osteoarthritis

Osteoarthritis is a degenerative joint disease characterised by the deterioration of the joint cartilage, leading to exposure of the underlying bony joint surface. The resulting bone-to-bone contact can produce polishing of the bone termed 'eburnation', which is the most apparent expression of osteoarthritis. Osteoarthritis can be the result of mechanical stress and other factors, including lifestyle, food acquisition and preparation, social status, sex and general health (Larsen 1997).

Skeleton 30944 (old middle adult male) had mild eburnation on the articular facets of the 2<sup>nd</sup> and 3<sup>rd</sup> thoracic vertebrae and severe eburnation in the joints between the 5<sup>th</sup> lumbar vertebra and the sacrum (see Plate 4), indicative of osteoarthritis. The crude prevalence of spinal osteoarthritis in the early medieval period was 6.1% (Roberts and Cox 2003, 195).

Skeleton 15548 had mild eburnation in the joint between the 5<sup>th</sup> lumbar vertebra and the sacrum, but similarly to the DJD, only on the right side. Additionally, the left knee (distal left femur, proximal left tibia) was affected by a very small area of eburnation indicative of osteoarthritis and the right hip joint (affecting the pelvis and femur), which was severely malformed as a result of the congenital hip dysplasia forming a new joint (pseudoarthrosis), exhibited severe eburnation. The early medieval prevalence rate of extraspinal osteoarthritis was 4.6% of individuals (Roberts and Cox 2003, 195).

## 3.5 TRAUMA

### 3.5.1 *Os Acromiale*

The tip of the acromion process of the scapula, the part of the shoulder blade that projects over the shoulder joint and meets the clavicle, develops as a separate element which fuses to the rest of the scapula as the individual approaches adulthood. In a small percentage of individuals this fusion fails to occur, and the tip of the acromion remains separate, known as *os acromiale*. This developmental anomaly is thought to be caused by severe stress to the rotator cuff muscles during growth, preventing natural fusion of the bones. In modern populations, *os acromiale* was noted in two boxers, where it was attributed to their intensive training during adolescence (Hershkovitz *et al* 1996, 170). This condition had occurred in the both scapulae of Skeleton 30944 (old middle adult male). The frequency of *os acromiale* for the early medieval period was 0.4% of individuals (Roberts and Cox 2003, 203). Failure of this bone to fuse probably results in increased flexibility of the shoulder joint, allowing a greater range of movement without damaging the muscles (Knüsel 2000), and it has been suggested that *os acromiale* is associated with the practice of archery from a young age, or any kind of movement requiring the arm to be rotated over the shoulder (Knüsel 2000; Stirland 2005).

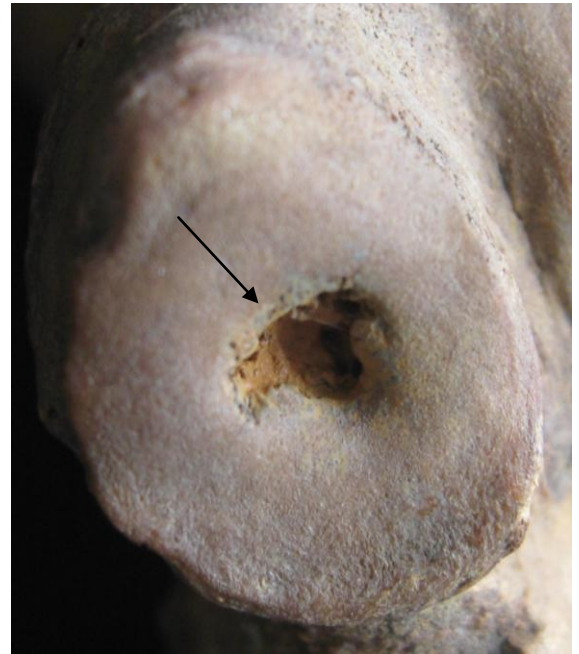### 3.5.2 *Osteochondritis Dissecans*

Skeleton 30944 (old middle adult male) had well defined depressions on the middle articular surfaces of both calcanei (heel bones), measuring 2.7mm in diameter on the right calcaneus and 4.2mm on the left bone (Plate 9). It is likely that a fragment of the joint surface had become detached following death of the bone tissue in that area due to damage to the blood supply, a condition known as *osteochondritis dissecans* (Roberts and Manchester 2005). *Osteochondritis dissecans* usually results in a circular and porous depression in the joint surface. It is a condition that affects young individuals, particularly males (Roberts and Manchester 2005, 121).

In their survey of health in the early medieval period, Roberts and Cox (2003, 210) observed that 1.5% of individuals had suffered osteochondritis dissecans, all in the knee.

### 3.5.3 Excavated Muscle Attachment

Skeletons 36318 (young adult female) and 30979 (adult male) had an elongated depression on their left humeri, at the location for the attachment of the *pectoralis major* muscle. This muscle acts to pull the humerus towards the body (adduction), as well as rotating the humerus inwards (Stone and Stone 1997). Skeletons 15548 and 30944 showed evidence for bone excavations at the right humeri for *subscapularis* (also on the left humerus of Skeleton 30944) and *infraspinatus* and Skeleton 15548 also had a bone excavation for *supraspinatus*. These muscles are part of the rotator cuff and aid in abduction and adduction of the shoulder, lateral and medial rotation of the arm and strengthen the shoulder joint (*ibid*). There was a severe bone excavation for *subscapularis* on the right humerus of Skeleton 15548, perhaps related to her need for walking aids. The clavicles of Skeleton 30944 had moderate bone excavations for the *costoclavicular* ligaments. Bone excavations at this site are very common in archaeological populations. There was also an unusual bone excavation at the attachment site for the *medial talocalcaneal* ligament at the left talus.



**Plate 9** Osteochondritis dissecans lesion in calcaneus of Sk 30944

Skeleton 30944 also showed evidence for enthesopathies at the attachments of *rectus femoris* on the left patella; this muscle laterally rotates the hip joint (Stone and Stone 1997, 160). The pelvis exhibited enthesopathies for *semimembranosus*, which extends at the hip and flexes at the knee (*ibid*, 173). A large enthesopathy for *gluteus maximus* was located on the left femur of Skeleton 15548, which was probably related to trauma to that leg.

Skeleton 30944 also showed evidence for enthesopathies at the attachments of *rectus femoris* on the left patella; this muscle laterally rotates the hip joint (Stone and Stone 1997, 160). The pelvis exhibited enthesopathies for *semimembranosus*, which extends at the hip and flexes at the knee (*ibid*, 173). A large enthesopathy for *gluteus maximus* was located on the left femur of Skeleton 15548, which was probably related to trauma to that leg.

## 3.6 CIRCULATORY DISORDERS

A smooth depression was located at the left distal humerus of Skeleton 30979 (adult male) between the trochlea and the medial epicondyle. It is likely to be ischemia (restriction of the blood supply) of the anterior part of the ulnar collateral ligament. Knüsel (*pers comm.* 23/12/2009) has observed these in the skeletons of the *Mary Rose* as well as skeletons from other periods.

## 3.7 MISCELLANEOUS PATHOLOGY

Skeleton 30944 (old middle adult male) had a slightly distorted joint of the left fifth metatarsal. The lateral part of the distal joint surface was not smooth, as would be the norm, but undulated and concave. It is not clear what caused this joint change, though this was not related to a degenerative condition and looked more like a crush fracture.

### 3.8 CONCLUSION

Considering that only four partial skeletons were recovered from the Anglo-Scandinavian period at Coppergate, a large number of pathological lesions were observed. Congenital anomalies were recorded in two individuals, with the mature adult female (15548) having congenital hip dysplasia on the right side, which meant that she probably had a severe limp and had to rely on a walking aid, such as crutches. There were numerous secondary complications, including one-sided degenerative joint disease of her spine, osteoarthritis of the lower spine, wasting of the right hip and whole right leg, probably as a result of disuse of the leg, osteoarthritis in the right hip joint, inflammatory lesions in the right fibula, additional strain on the left leg, causing muscular trauma and osteoarthritis in the left knee. Whether the degenerative joint disease in the shoulders, right hand and wrist were complications of her disability was not clear. This female also had numerous minor congenital anomalies of the spine, such as differently sized vertebral joints and possibly also only eleven instead of the usual twelve central vertebrae. In addition, she had a congenital anomaly of the left femur, leading to shortening of the femoral neck, which was also seen in both femora of the old middle adult male (30944). This would have caused a lurching limp.

The old middle adult male also had further developmental defects, such as spinal anomalies and a lopsided breast bone, none of which would have had an effect on his well-being. The male had mild degenerative joint disease of the spine, ribs, shoulders, right elbow and much more severe degenerative joint disease and osteoarthritis in the lower spine. Evidence for trauma was noted in the form of non-fusion of the lateral parts of the scapulae, which has often been associated with requirement for a greater degree of flexibility in the shoulder, as in archery. He also had evidence for muscular trauma. Both of his lower legs exhibited inflammatory lesions which were healing at the time of death.

Both the older male and female and also the young adult female (36318) had depressions in the vertebral bodies termed Schmorl's nodes, which are caused by ruptured discs. Discs can rupture as a result of trauma, axial pressure or through other causes. The young female had lesions in the eye orbits associated with infection or poor nutrition in childhood. Both she and the adult male ((30979) also had evidence for muscular trauma. The male also had a lesion on the elbow though to be caused by restriction to the blood supply.

The skeletons from nearby Spurriergate in York were generally incomplete and therefore did not exhibit much evidence for pathology. However, Skeleton 5031, a middle adult female, had degenerative joint disease and osteoarthritis of the spine, a congenital anomaly of the fifth lumbar vertebra and childhood stress lesions in the eye orbits (Holst 2005).

### 4.0 DENTAL HEALTH

Analysis of the teeth from archaeological populations provides vital clues about health, diet and oral hygiene, as well as information about environmental and congenital conditions.

Unusually, Skeleton 15548 (mature adult female) had 33 instead of the usual 32 tooth positions and sixteen of her permanent teeth were present, with the other teeth being lost post-mortem. Skeleton 30944 (old middle adult male) had all his 32 tooth positions but had also lost many teeth post-mortem, leaving twelve teeth to record. A

further five teeth were lost ante-mortem. Skeleton 36318 (young adult female) had a full surviving maxilla and all sixteen tooth positions were preserved. However, only three teeth were recovered, the remainder having been lost post-mortem. Skeleton 30979 (adult male) did not have any surviving teeth or jaw bones. In total, 81 tooth positions and 31 teeth were available for study.

Dental wear tends to be more common and severe in archaeological populations than in modern teeth. Severity of the dental wear was assessed using a chart developed by Smith (1984). Each tooth was scored using a grading system ranging from 1 (no wear) to 8 (severe attrition of the whole tooth crown). Dental wear was mild in the young adult female and moderate to severe (3 to 6) in the two older adults.

#### 4.1 DENTAL CALCULUS

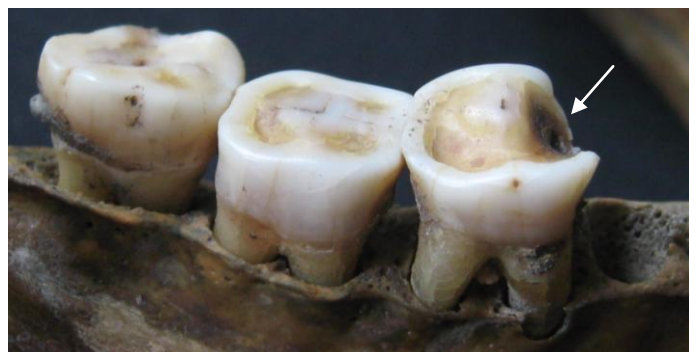Calculus (mineralised dental plaque) is commonly observed in archaeological populations whose dental hygiene was not as rigorous as it is today. If plaque is not removed from the teeth effectively (or on a regular basis) then these plaque deposits mineralise and form concretions of calculus on the tooth crowns or roots, along the line of the gums (Hillson 1996).

Calculus deposits were noted on 29 (93.5%) teeth, suggesting poor oral hygiene. In comparison, 39.2% of teeth were affected by calculus in the early medieval period (Roberts and Cox (2003). As expected, the calculus was worse in the mature adult female (Skeleton 1554) compared with the two younger individuals.

#### 4.2 DENTAL CARIES

Dental caries (tooth decay) forms when bacteria in the plaque metabolise sugars in the diet and produce acid, which eventually leads to the formation of a cavity in the tooth (Zero 1999). Simple sugars can be found naturally in fruits, vegetables, dried fruits and honey, as well as processed, refined sugar; since the latter three contain the most sucrose they are most cariogenic. Complex sugars are usually less cariogenic and are found in carbohydrates, such as cereals. However, processing carbohydrates, including grinding grains into fine powders or cooking them, will usually increase their cariogenicity (Moynihan 2003).

Dental caries (Plate 10) were only observed in the mature adult female (Skeleton 15548), which was not unexpected since the number of cavities usually increases with age. She had caries in one of her sixteen teeth (6.25%). The prevalence rate of caries at Coppergate was 3.2% and thus lower compared with the frequency of teeth affected by dental caries in the early medieval period, which was 4.2% (Roberts and Cox 2003).



**Plate 10** Caries in right mandible of Sk 15548

#### 4.3 ABSCESSSES

Dental abscesses occur when bacteria enter the pulp cavity of a tooth causing inflammation and a build-up of pus at the apex of the root. Eventually, a hole forms in the surrounding bone allowing the pus to drain out and

relieve the pressure. They can form as a result of dental caries, heavy wear of the teeth, damage to the teeth, or periodontal disease (Roberts and Manchester 1995).

Skeleton 30944 (old middle adult) was the only individual with dental abscesses. The abscesses concentrated around the upper left first molar and the maxillary right second premolar and first molar. Both abscesses were healed. Notably, both abscesses were associated with ante-mortem tooth loss of the upper first molars. The overall prevalence at Coppergate was 3.7%, which was higher than the early medieval mean with 2.8% (Roberts and Cox 2003, 192).

#### 4.4 ANTE-MORTEM TOOTH LOSS

Ante-mortem tooth loss (AMTL), or the loss of teeth during life, can occur as a result of a variety of factors, including dental caries, pulp-exposure from heavy tooth wear, or periodontal disease (occurring when inflammation of the gums, gingivitis, spreads to the underlying bone). Gingivitis can result when deposits of calculus on the teeth aggravate the gums. Once the tooth has been lost, the empty socket is filled in with bone.

Only the old middle adult (Skeleton 30944) had lost five teeth ante-mortem. The prevalence rate of AMTL at Coppergate was 6.2%, as compared with the early medieval mean, which was 8.0% (Roberts and Cox 2003, 193).

#### 4.5 PERIODONTAL DISEASE

Periodontitis (receding gums) was slight to moderate in the maxilla and mandible of the two older adults and may have been caused by the widespread calculus deposits. The young adult female did not have periodontal disease.

#### 4.6 DENTAL ANOMALIES

Remarkably, Skeleton 15548 had 33, instead of the usual 32 tooth positions. Polydontia (or supernumerary teeth) is much less common than congenitally absent teeth. The additional teeth usually take on the shape of the adjacent tooth, and tend to be hidden on the inner side of the mouth (Hillson 1996, 114). However, in this case it appears as if there were two left second incisors beside one another, though unfortunately, the teeth were lost post-mortem.

The first left mandibular incisor of Skeleton 15548 (mature adult female) was rotated by approximately 45 degrees, so that the buccal side was now located distally and the lingual side medially.

#### 4.7 DENTAL CONCLUSIONS

Evidence for dental disease was largely restricted to deposits of calcified plaque in all three individuals, which were worse than average for the period and indicative of poor oral hygiene. The mature adult female had a small cavity in a molar. The prevalence of caries was lower than the norm for the period, as was the rate of ante-mortem tooth loss. The prevalence of dental abscesses was, however, slightly higher than the early medieval

mean. Dental anomalies included supernumerary teeth in the female with numerous congenital anomalies, as well as a rotated tooth.

## 5.0 MORTUARY PRACTICE

The presence of four burials in pits in various positions and orientations suggests that these individuals were not interred in a typical Christian manner. Burial of post-Roman skeletons in rubbish pits is relatively rare in the archaeological record. However, examples do exist, such as five skeletons that were found at 7-17 Spurriergate, within 100 metres of Coppergate. All five skeletons were buried in large pits, though unfortunately truncation by later pits meant that only two of these were almost complete individuals. Two of the skeletons were radiocarbon dated to the late eighth century AD, so about 100 years earlier than the Coppergate skeletons are thought to be.

The position and orientation of these individuals was also varied, with the skeletons in north to south or reversed orientations and supine extended, flexed and prone skeletal positions (Holst 2005).

The majority of burials dating to the eighth and ninth centuries would have been interred in churchyards, such as those at Repton, Lincolnshire, Hovingham, North Yorkshire and Bakewell in Derbyshire (Hadley 2000, 201). However, according to Hadley, there was much variety in terms of funerary ritual between the seventh and eleventh centuries (*ibid* 2000, 202) and it appears that this diversity was widely accepted before the tenth century (*ibid*, 214). Non-churchyard burials from the seventh to tenth century are largely found in barrows. Such burials from the Anglo-Scandinavian period are known from York's surrounding area, at Siward's Howe (Hall 1994, 44) or the Viking barrow cemetery at Ingleby in Derbyshire, which contained cremated remains and is thought to date to the ninth and tenth century AD (Richards *et al* 1995).

Alternatively, burials have been found in locations, which were later marked by the construction of a church in the tenth or eleventh century (Hadley 2000, 211). Examples include Barton-on-Humber, Kellington and Holton-le-Clay (*ibid*). Interments from the period excavated in York itself tend to be associated with churches, such as the burials excavated at St Mary Bishophill Junior, St Mary Bishophill Senior, York Minster and Fishergate St Andrew's (Hall 1994). Notably, there was still much variation, even in church cemeteries, such as the early burials at the Norman Minster, which included charcoal burials, coffins, and even parts of a boat (Hadley 2000, 208).

It is possible that some burials from this period are simply not recognised because of a lack of radiocarbon dating. A mature adult female skeleton interred in a west-east orientation in a supine extended position in an enclosure ditch at Brake's Farm, Sedgfield, County Durham, was thought to date to the Iron Age until radiocarbon dating stated that the individual dated to the late tenth or early eleventh century AD (Holst 2009).

## 6.0 DISCUSSION AND SUMMARY

The osteological analysis of the Anglo-Scandinavian period skeletal assemblage from Coppergate has provided an important insight into the lives of these individuals. Two of the skeletons were almost complete, while less



than 25% of the other two skeletons survived. Their preservation, however, was excellent, which meant that it was possible to identify much pathology. At the time of writing the date of the skeletons was presumed to be Anglo-Scandinavian from the late ninth century AD, based on stratigraphic and artefactual evidence. Radiocarbon dating of the remains would be beneficial in proving the skeletons dated to this period.

The skeletons buried at Coppergate comprised the remains of a young adult female, a mature adult female, an old middle adult male and a possible male adult. The individuals were interred in pits, and three of the individuals were buried in close proximity of one another. The mature adult female was some distance away, buried in another pit in a formal supine extended position in an east to west orientation (see Table 1). The younger female had been disturbed by a later feature and was therefore disarticulated, while only the left arm of the adult male was recovered, although it is assumed that he had been interred in a south to north orientation and a supine position. The old middle adult male lay with the skull to the northeast and the feet to the southwest in a supine semi-flexed position. His left arm was bent upwards, with the left hand behind his head. Parallels for these pit burials were found in York itself at Spurriergate, only 100m from Coppergate. Here five individuals were interred in large pits in a variety of positions and orientations (Holst 2005). Two of these burials were radiocarbon dated to the late eighth century AD. Although other burials from this period tend to be more formal and are often found in churchyards or under barrows, a similar interment was found near Sedgefield in County Durham, where a mature adult female lay in a west to east orientation in a supine extended position within a large enclosure ditch (Holst 2009).

Two of the individuals showed evidence for a number of congenital anomalies, of varying degrees of severity. The mature adult female, who was of average height for the period, possibly only had eleven thoracic vertebrae (rather than the usual twelve). She also had a number of minor spinal anomalies, such as twisted spinous and transverse processes, lopsided or differently sized articular facets in some vertebrae and lumbarisation of the first sacral vertebra. Her left femoral neck was abnormal; it was shortened and horizontal. She also had 33 tooth positions instead of the normal 32. The presence of supernumerary teeth is relatively uncommon. However, the most severe congenital anomaly was the congenital hip dysplasia on the right side, which meant that she would have walked with a severe limp and probably needed a walking aid. The fact that the right hip, femur, tibia and fibula had a severely diminished appearance compared with the left side suggests that the right leg was rarely used for walking. Instead, the left leg was unusually well-developed and broad, as were her shoulders and arms, perhaps due to the use of a crutch. Her left leg and arms also displayed evidence for muscular trauma, which was probably related. The left knee showed evidence for this unusual strain in the form of osteoarthritis at the knee and the spine displayed degenerative joint disease and osteoarthritis, which only affected the right side and was also likely to be a secondary complication to her congenital hip dislocation. A new hip joint had formed in the right pelvis and also on the femoral shaft (as the femoral head was not formed). The new hip socket was small and almost flat and severely affected by osteoarthritis. Whether the degenerative joint disease in her ribs, shoulders and right hand were a result of her condition could not be established. However, it is likely that the receding inflammation of her right lower leg was also related to the disuse of that leg. Her dental health was relatively good for her age, with one cavity, mild to moderate plaque concretions and slight to moderate periodontal disease.

The old middle adult male also had congenital anomalies, including the shortened and horizontal femora necks, as the female mature adult, which would have caused him to walk with a limp. He also had a twisted spinous process in one vertebra, a cleft spinous process in the firsts sacral vertebra and an unusually large transverse

process in a third vertebra. His breastbone was slightly distorted in shape, which is also a minor congenital defect. He was unusually short for the period and his skeleton was relatively gracile. Evidence for trauma was noted in both scapulae, which had unfused acromiae, a condition that is often seen in those that require increased flexibility of shoulder movement, such as archers. In both heel bones were lesions indicative of problems with his blood supply, causing a small part of the joint surfaces to detach from the joint. He also had lesions indicative of disc herniation in his lower spine and some muscular trauma. Mild degenerative joint disease affected his spine, ribs, shoulders and hips and he had osteoarthritis in the central and lower spine. His lower legs were affected by receding inflammatory lesions. His dental health was moderate, with some ante-mortem tooth loss, widespread dental plaque, moderate periodontal disease and two healed dental abscesses.

The partial skeleton of a young adult female suggested that she was slightly taller than the average for the period. During childhood, she had suffered from stress, perhaps in the form of infection. She suffered from herniation of some of the vertebral discs and showed evidence for muscular trauma. Her dental health was good.

The adult male was slightly taller than the early medieval mean. He had also incurred muscular trauma, as well as circulatory problems in his left arm.

The dental health of the population was moderate, with widespread calculus, indicative of poor oral hygiene. However, while abscesses tooth loss was higher than the early medieval average, the rate of cavities and ante-mortem tooth loss was lower.

Considering the presence of a number of congenital anomalies in the mature adult female and the old middle adult male, one of which was observed in both individuals, there is a slight possibility that these two individuals may have shared genetic links. Alternatively, it is possible that only some individuals were given pit burial at Coppergate; maybe the two individuals with congenital anomalies and limps were selected because of their disabilities.

## 7.0 FUTURE RECOMMENDATIONS

Considering the importance of these burials, it is recommended that the individuals undergo AMS radiocarbon dating. Targeted radiocarbon dating of the skeletons would provide accuracy in assigning a precise date to the skeletons, which is vital considering the rapidly changing political, social and funerary circumstances at this time.

## References

- Anderson, T. 2000. 'Congenital conditions and neoplastic disease in palaeopathology' in M. Cox and S. Mays (eds) *Human Osteology in Archaeology and Forensic Science* (London): 199-225
- Aufderheide, A. C. and Rodríguez-Martín, C. 1998. *The Cambridge Encyclopedia of Human Paleopathology* (Cambridge)
- Barnes, E. 1994. *Developmental Defects of the Axial Skeleton in Palaeopathology* (Niwot, Colorado)
- Bass, W. M. 1987. *Human Osteology: A Laboratory and Field Manual* (Columbia)
- Berry, A.C. and Berry, R.J. 1967. 'Epigenetic variation in the human cranium', *Journal of Anatomy* 101 (2): 361-379
- Brothwell, D.R. 1981. *Digging Up Bones* (New York)
- Brothwell, D.R. and Browne, S. 1994. 'Pathology', in Lilley, J.M., Stroud, G., Brothwell, D.R. and Williamson, M.H. (eds) *The Jewish Burial Ground at Jewbury* (York):457-494
- Buikstra, J.E. and Ubelaker D.H. (eds) 1994. *Standards for Data Collection from Human Skeletal Remains* (Fayetteville)
- Cox, M. 2000. 'Ageing adults from the skeleton', in M. Cox and S. Mays (eds), *Human Osteology in Archaeology and Forensic Science* (London): 61-82
- Finnegan, M. 1978. 'Non-metric variation of the infracranial skeleton', *Journal of Anatomy* 125: 23-37
- Hadley, D. 2000. 'Burial practice in the Northern Danelaw, c. 650-1100', *Northern History* 36: 199-216
- Hall, R. *Anglo-Scandinavian Age York* (York)
- Hershkovitz, I., Bedford, L., Jellema, L.M. and Latimer, B. 1996. 'Injuries to the skeleton due to prolonged activity in hand-to-hand combat', *International Journal of Osteoarchaeology* 6: 167-178
- Hillson, S. 1996. *Dental Anthropology* (Cambridge)
- Hilton, R.C., Ball, J. and Benn R.T. 1976. 'Vertebral end-plate lesions (Schmorl's nodes) in the dorsolumbar spine', *Annals of the Rheumatic Diseases* 35: 127-132
- Holst, M. 2009. 'Osteological Analysis, Brakes Farm, Sedgefield, Country Durham', York Osteoarchaeology Ltd No 0909, Unpublished Osteological Report
- Holst, M. 2005. 'Osteological Analysis, Spurriergate, York', York Osteoarchaeology, No. 1405 Unpublished Osteological Report
- Holst, M., Isaac, L. And Boylston, A. 1998. 'Hull Magistrate's Court', Unpublished Osteological Report, Calvin Wells Laboratory, University of Bradford
- Kennedy, K.A.R. 1989. 'Skeletal markers of occupational stress', in M.Y. Işcan. and K.A.R. Kennedy (eds), *Reconstruction of Life from the Skeleton* (New York):129-160
- Knüsel C. 2000b. 'Activity-related change', in Fiorato, V., Boylston, A. And Knüsel, C. *Blood Red Roses: The Archaeology of a Mass Grave from the Battle of Towton AD 1461* (Oxford): 103-118
- Larsen, C.S. 1997. *Bioarchaeology: Interpreting Behavior from the Human Skeleton* (Cambridge)
- Lewis, M. 2000. 'Non-Adult palaeopathology: Current Status and Future Potential', in M. Cox and S. Mays (eds), *Human Osteology in Archaeology and Forensic Science* (London): 39-57
- Mays, S. and Cox, M. 2000. 'Sex determination in skeletal remains', in M. Cox and S. Mays (eds), *Human Osteology in Archaeology and Forensic Science* (London): 117-130
- McKinley, J. I. 2004. 'Compiling a skeletal inventory: disarticulated and co-mingled remains', in M. Brickley and J. I. McKinley (eds), *Guidelines to the Standards for Recording Human Remains. IFA Paper No. 7* (Southampton and Reading): 14-17
- Moynihan, P. 2003. 'Diet and dental caries', in J. J. Murray, J. H. Nunn and J. G. Steele (eds) *The Prevention of Oral Disease* (Oxford): 9-34

- Ortner, D. J. 2003. *Identification of Palaeopathological Disorders in Human Skeletal Remains* (Amsterdam and San Diego)
- Puttnam, G.G. 1978. 'Analysis of the skeletal material', in P.G. Huggins, 'Excavation of a Belgic and Romano-British Farm with Middle Saxon Cemetery and Churches at Nazeingbury, Essex, 1975-6', *Essex Archaeology* 10: 29-117
- Richards, J.D., Jecock, M., Richmond, L. And Tuck, C. 1995. 'The Anglo-Scandinavian barrow cemetery at Heath Wood, Ingleby, Derbyshire', *Medieval Archaeology* 39: 51-70
- Roberts, C.A. and Cox, M. 2003. *Health and Disease in Britain from Prehistory to the Present Day* (Stroud)
- Rogers, J. 2000. 'The palaeopathology of joint disease', in M. Cox and S. Mays (eds), *Human Osteology in Archaeology and Forensic Science* (London): 163-182
- Rogers, J. 1999. 'Burials: the human skeletons', in C. Heighweay and R Bryant, *The Golden Minster. The Anglo-Saxon Minster and Later Medieval Priory of St Oswald, Gloucester* (York): 163-182
- Roberts, C.A. and Manchester, K. 2005. *The Archaeology of Disease* (third edition) (Stroud)
- Roberts, C.A. and Manchester, K. 1995. *The Archaeology of Disease* (Stroud)
- Salter, R. B. 1999. *Textbook of Disorders and Injuries of the Musculoskeletal System*
- Saunders, S.R. 1989. 'Non-metric variation', in M.Y. Işcan and K.A.R. Kennedy (eds) *Reconstruction of Life from the Skeleton* (New York): 95-108
- Scheuer, L. and Black, S. 2000a. 'Development and ageing of the juvenile skeleton', in M. Cox and S. Mays (eds), *Human Osteology in Archaeology and Forensic Science* (London): 9-22
- Scheuer, L. and Black, S. 2000b. *Developmental Juvenile Osteology* (San Diego)
- Smith, B.H. 1984. 'Patterns of molar wear in hunter-gatherers and agriculturalists', *American Journal of Physical Anthropology* 63: 39-56
- Stirland, A. 2005. 'Human remains', in J. Gardiner and M. J. Allen (eds) *Before the Mast: Life and Death Aboard the Mary Rose. The Archaeology of the Mary Rose* 4 (Portsmouth): 516-544
- Stone, R. J. and Stone, J. A. 1997. *Atlas of Skeletal Muscles* (London)
- Stroud, G. and Kemp, R.L. 1993. *Cemeteries of the Church and priory of St Andrew's, Fishergate, York, The Archaeology of York, Vol. 12/2, The Medieval Cemeteries* (York)
- Stuart-Macadam, P. 1992. 'Anemia in past populations', in P. Stuart-Macadam and S. Kent (eds) *Diet, Demography and Disease: Changing Perspectives of Anemia* (New York): 151-170
- Sture, J. F. 2001. *Biocultural Perspectives on Birth Defects in Medieval Urban and Rural English Populations*, Durham University, Unpublished PhD Thesis
- Trinkhaus, E. 1978. 'Bilateral asymmetry of human skeletal non-metric traits', *American Journal of Physical Anthropology* 49: 315-318
- Trotter, M. 1970. 'Estimation of stature from intact limb bones', in T.D. Stewart (ed), *Personal Identification in Mass Disasters* (Washington D.C.): 71-83
- Walker, P. L., Bathurst, R. R., Richman, R., Gjerdrum, T. and Andrushko, V. A. 2009. 'The causes of porotic hyperostosis and cribra orbitalia: a reappraisal of the iron-deficiency-anemia hypothesis', *American Journal of Physical Anthropology* 139: 109-125
- Wenham, L.P., Hall, R.A., Briden, C.M. and Stocker, D.A. *St Mary Bishophill Junior and St Mary Castlegate, The Archaeology of York Series, Anglo-Scandinavian York* (York)
- Zero, D. T. 1999. 'Dental caries process', *Dental Clinics of North America* 43: 635-664

**APPENDIX A: OSTEOLOGICAL AND PALAEOPATHOLOGICAL CATALOGUE**

<b>Skeleton Number</b>	<b>15548</b>															
Preservation	Surface preservation = 0 (excellent); slight fragmentation															
Completeness	70%, all except C2, C3, proximal left humerus, parts of both hands, both feet, the left fibula, right distal fibula and tibia and the majority of the left tibia															
Age	46+ years (mature adult)															
Sex	Female															
Stature	159.32 ± 3.72 cm (left femur)															
Non-Metric Traits	Ossicle at pterion (R) Transverse foramina bipartite (R); septal aperture (L); acetabular crease (L); exostosis in trochanteric fossa (L); third trochanter (L)															
Pathology	Schmorl's nodes in T8, L1, L2, L3, L4, L5, spinal DJD, DJD in clavicles, scapulae, right first metacarpal, right 5 <sup>th</sup> hand phalanx, right trapezium, hips, right proximal femur, osteoarthritis in right hip, right proximal femur, left distal femur, left proximal tibia, sacrum and L5, congenital hip dysplasia on right side, atrophy of right hip, femur and tibia, coxa vara, possibly only 11 thoracic vertebrae, lopsided facets on the right on S1, L5, L4, L3, twisted transverse processes on L5, L4, L3, right articular facets larger than left in T12, T11, T10, T9, Spinous process twisted in C4 periosteal reaction at right fibula, bone excavations for infraspinatus and supraspinatus and subscapularis at right humerus, enthesopathies for gluteus maximus at left femur															
Dental Health	33 tooth positions, 16 teeth present, calculus in 16/16, caries 1/16, slight to moderate periodontitis, LI <sub>1</sub> rotated slightly (buccal to distal)															
	Right Dentition								Left Dentition							
Present	PM	P	P	PM	P	PM	PM	PM	PM	PM	PM	PM	P	P	P	P
Calculus	-	SIMm	Ma	-	Ma	-	-	-	-	-	-	-	Sa	Sld	Smd	Fm
DEH	-	-	-	-	-	-	-	-	-	-	-	-	-	-	-	-
Caries	-	-	-	-	-	-	-	-	-	-	-	-	-	-	-	-
Wear	-	5	6	-	4	-	-	-	-	-	-	-	6	7	6	3
Maxilla	<b>8</b>	<b>7</b>	<b>6</b>	<b>5</b>	<b>4</b>	<b>3</b>	<b>2</b>	<b>1</b>	<b>1</b>	<b>2</b>	<b>3</b>	<b>4</b>	<b>5</b>	<b>6</b>	<b>7</b>	<b>8</b>
Mandible	<b>8</b>	<b>7</b>	<b>6</b>	<b>5</b>	<b>4</b>	<b>3</b>	<b>2</b>	<b>1</b>	<b>1</b>	<b>2</b>	<b>3</b>	<b>4</b>	<b>5</b>	<b>6</b>	<b>7</b>	<b>8</b>
Present	P	P	P	PM	P	P	PM	PM	P	PM	PM	PM	P	P	P	PM
Calculus	Ma	Mlmd	Sd	-	MISb	Sbl	-	-	HbSl	-	-	-	MbSl	Ml	Sldm	-
DEH	-	-	-	-	-	-	-	-	-	-	-	-	-	-	-	-
Caries	-	-	So	-	-	-	-	-	-	-	-	-	-	-	-	-
Wear	3	4	6	-	3	3	-	-	3	-	-	-	4	6	5	-

<b>Skeleton Number</b>	<b>30944</b>															
Preservation	Surface preservation = 0 (Excellent); almost no fragmentation															
Completeness	95%, all except some hand and foot bones and the right patella															
Age	36-45, old middle adult															
Sex	Male															
Stature	161.51 ± 2.99cm															

Non-Metric Traits		Ossicle in lambdoid (bilateral), mastoid foramen extrasutural (R), precondylar tubercle, incomplete foramen ovale (R), bridging of supraorbital notch (R)  Posterior atlas bridging (bilateral), transverse foramina bipartite (bilateral), vastus notch (L), vastus fossa (L), peroneal tubercle (bilateral), absent anterior calcaneal facets (bilateral)															
Pathology		Schmorl's nodes in T6, T7, T9, T12, L2, L3, L4, DJD in spine, left scapula glenoid, right proximal ulna, hips, ribs, osteoarthritis in T2, T3, L5 and sacrum, bilateral os acromiale, twisted spinous process of C5, unusually wide intertubercular lamella of transverse process of C7, distorted manubrium, cleft S1, coxa vara, periosteal reactions at tibiae and fibulae and skull, osteochondritis dissecans at calcanei, bone excavations for subscapularis at humeri, infraspinatus at right humerus, costoclavicular ligament at clavicles, talocalcanean ligament at left talus, enthesopathies for rectus femoris at left patella, semimembranosus at ischia, distorted distal left 5 <sup>th</sup> metatarsal joint															
Dental Health		32 tooth positions, 12 teeth present, 5 teeth lost AM, 12/12 teeth with calculus, abscesses at upper first molars and right upper 2 <sup>nd</sup> premolar, slight to moderate periodontal disease															
	Right Dentition								Left Dentition								
Present	P	P	AM	P M	P M	P	PM	P M	PM	PM	P	P	PM	AM	P	P	
Calculus	Fb	Sd	-	-	-	Fb	-	-	-	-	Sb	Fb	-	-	Fb	SI	
DEH	-	-	-	-	-	-	-	-	-	-	-	-	-	-	-	-	
Caries	-	-	-	-	-	-	-	-	-	-	-	-	-	-	-	-	
Wear	3	6	-	-	-	5	-	-	-	-	5	5	-	-	7	5	
Maxilla	<b>8</b>	<b>7</b>	<b>6</b>	<b>5</b>	<b>4</b>	<b>3</b>	<b>2</b>	<b>1</b>	<b>1</b>	<b>2</b>	<b>3</b>	<b>4</b>	<b>5</b>	<b>6</b>	<b>7</b>	<b>8</b>	
Mandible	<b>8</b>	<b>7</b>	<b>6</b>	<b>5</b>	<b>4</b>	<b>3</b>	<b>2</b>	<b>1</b>	<b>1</b>	<b>2</b>	<b>3</b>	<b>4</b>	<b>5</b>	<b>6</b>	<b>7</b>	<b>8</b>	
Present	P	P	P	P M	P M	PM	PM	A M	A M	PM	PM	PM	PM	P	PM	P	
Calculus	Sbd m	Mb m	Fl	-	-	-	-	-	-	-	-	-	-	Sb	-	Sbm	
DEH	-	-	-	-	-	-	-	-	-	-	-	-	-	-	-	-	
Caries	-	-	-	-	-	-	-	-	-	-	-	-	-	-	-	-	
Wear	3	5	7	-	-	-	-	-	-	-	-	-	-	7	-	4	

<b>Skeleton Number</b>	<b>30979</b>
Preservation	Surface preservation = 0 (Excellent); almost no fragmentation
Completeness	5%, left scapula and left humerus
Age	19+, adult
Sex	Male
Stature	173.63 ± 4.05cm
Non-Metric Traits	-
Pathology	Ischemia at left humerus, bone excavation for pectoralis major at left humerus
Dental Health	-

<b>Skeleton Number</b>	<b>36318</b>															
Preservation	Surface preservation = 2 (Moderate); almost no fragmentation															
Completeness	25%, skull, maxilla, C1, T4-6, T9-L1, right proximal humerus, left whole humerus, left clavicle, left scapula, 3 left hand phalanges															
Age	19-25, young adult															
Sex	Female															
Stature	163.47 ± 4.05cm															
Non-Metric Traits	Parietal foramen (bilateral), ossicle at pterion (bilateral), double anterior condylar canal (L), incomplete foramen ovale (bilateral), accessory lesser palatine foramen (R) Posterior atlas bridging (bilateral)															
Pathology	Schmorl's nodes in T6, T9, T10, T11, T12, <i>cribra orbitalia</i> in right orbit, bone excavation for pectoralis major															
Dental Health	16 tooth positions, 3 teeth present, 1/3 teeth with calculus															
	Right Dentition								Left Dentition							
Present	PM	P	P	P	P	PM	PM	P	PM	PM	PM	PM	PM	P	PM	
Calculus	-	-	SL	-	-	-	-	-	-	-	-	-	-	-	-	
DEH	-	-	-	-	-	-	-	-	-	-	-	-	-	-	-	
Caries	-	-	-	-	-	-	-	-	-	-	-	-	-	-	-	
Wear	-	2	3	-	-	-	-	-	-	-	-	-	-	2	-	
Maxilla	<b>8</b>	<b>7</b>	<b>6</b>	<b>5</b>	<b>4</b>	<b>3</b>	<b>2</b>	<b>1</b>	<b>1</b>	<b>2</b>	<b>3</b>	<b>4</b>	<b>5</b>	<b>6</b>	<b>7</b>	<b>8</b>
Mandible	<b>8</b>	<b>7</b>	<b>6</b>	<b>5</b>	<b>4</b>	<b>3</b>	<b>2</b>	<b>1</b>	<b>1</b>	<b>2</b>	<b>3</b>	<b>4</b>	<b>5</b>	<b>6</b>	<b>7</b>	<b>8</b>
Present	-	-	-	-	-	-	-	-	-	-	-	-	-	-	-	
Calculus	-	-	-	-	-	-	-	-	-	-	-	-	-	-	-	
DEH	-	-	-	-	-	-	-	-	-	-	-	-	-	-	-	
Caries	-	-	-	-	-	-	-	-	-	-	-	-	-	-	-	
Wear	-	-	-	-	-	-	-	-	-	-	-	-	-	-	-	

**KEY:**

Present - Tooth presence; am - ante-mortem tooth loss; pm - post-mortem tooth loss; p - tooth present; -- jaw not present; o - erupting  
 Caries - Calculus; F - flecks of calculus; S - slight calculus; M - moderate calculus; H - heavy calculus; a - all surfaces; b - buccal surface; d - distal surface; m - mesial surface; l - lingual surface; o - occlusal surface  
 DEH - dental enamel hypoplasia; l - lines; g - grooves; p - pits  
 Caries - caries; s - small lesions; m - moderate lesions; l - large lesions  
 Wear - dental wear; numbers from 1-8 - slight to severe wear