

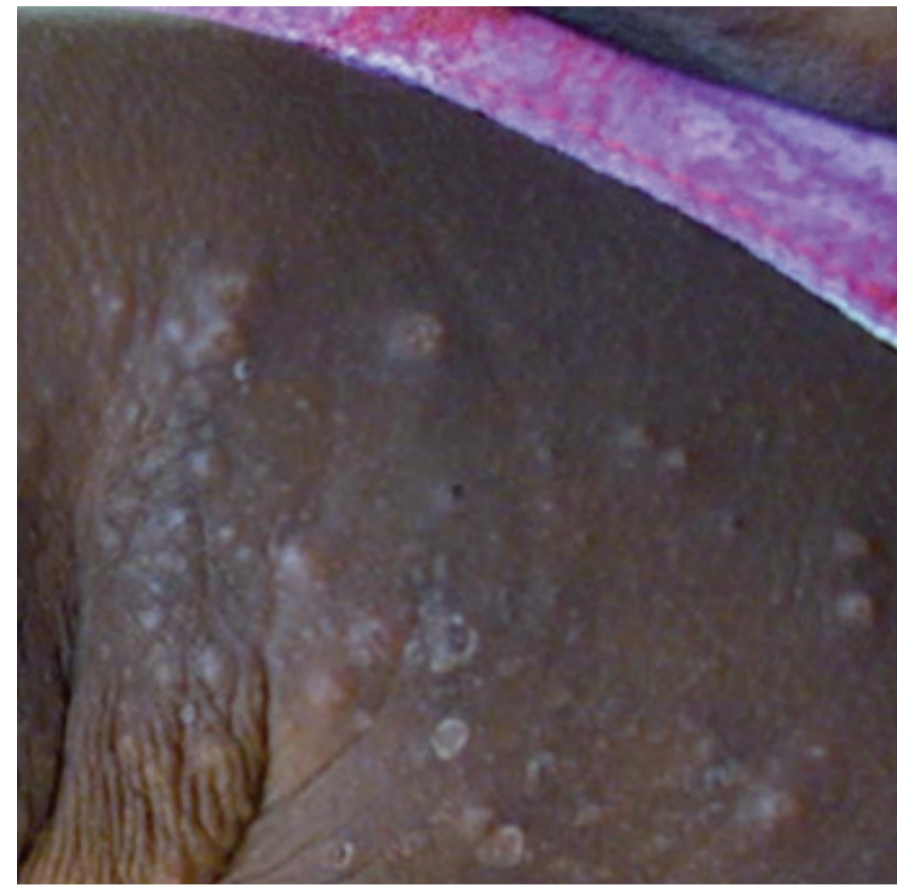
Scabies, Crusted Scabies and Other Common Skin Conditions in Central and Northern Australia



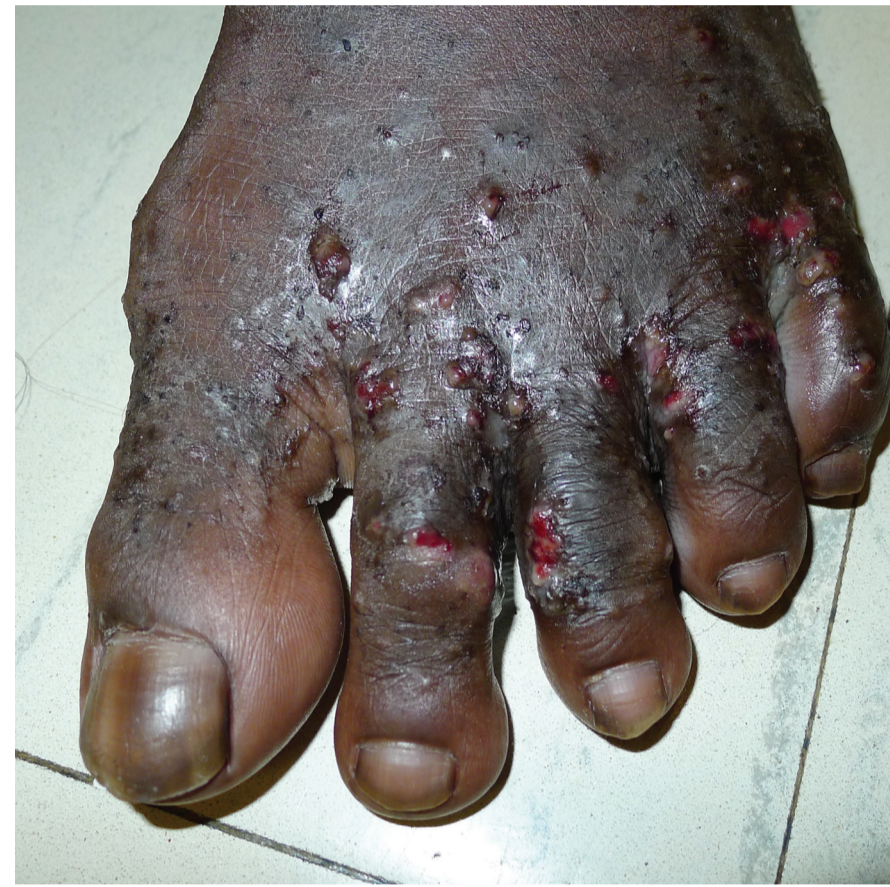For more information on diagnosing and treating skin conditions, see the latest edition of the CARPA Standard Treatment Manual or contact your local hospital Infectious Disease Specialists or Dermatologists.

As of January 2016, Crusted Scabies is a Notifiable Disease in the Northern Territory of Australia. For further information contact your local Centre for Disease Control.

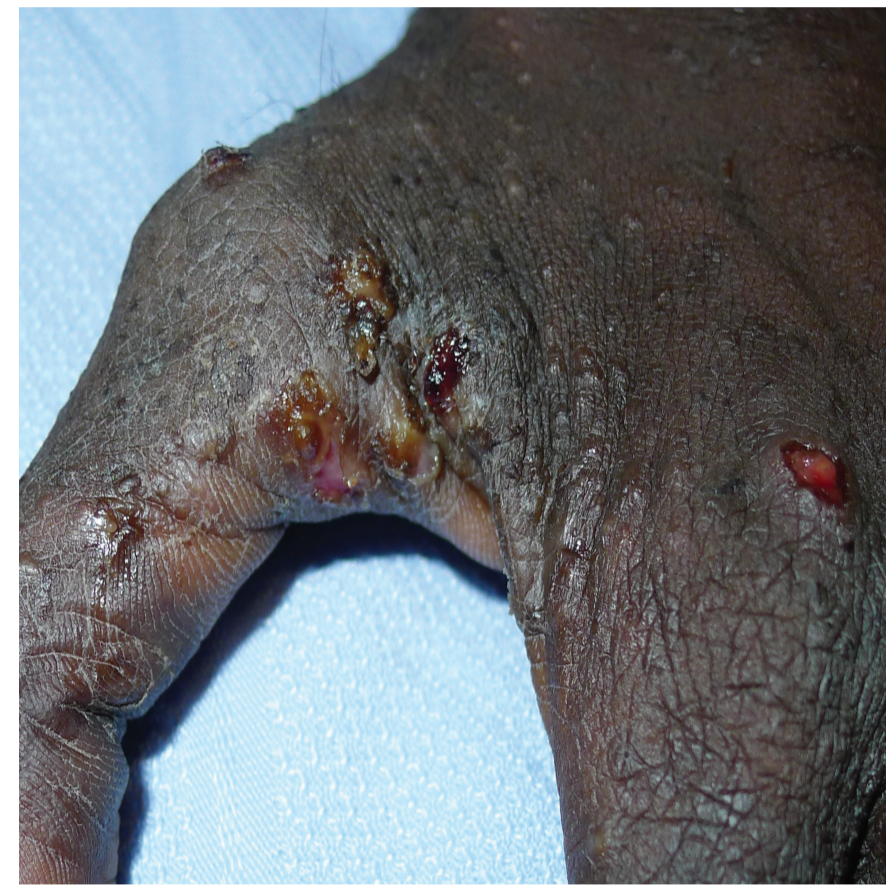This poster was collated by One Disease with thanks for images supplied by Professor Bart Currie and Dr Dev Tilakaratne.



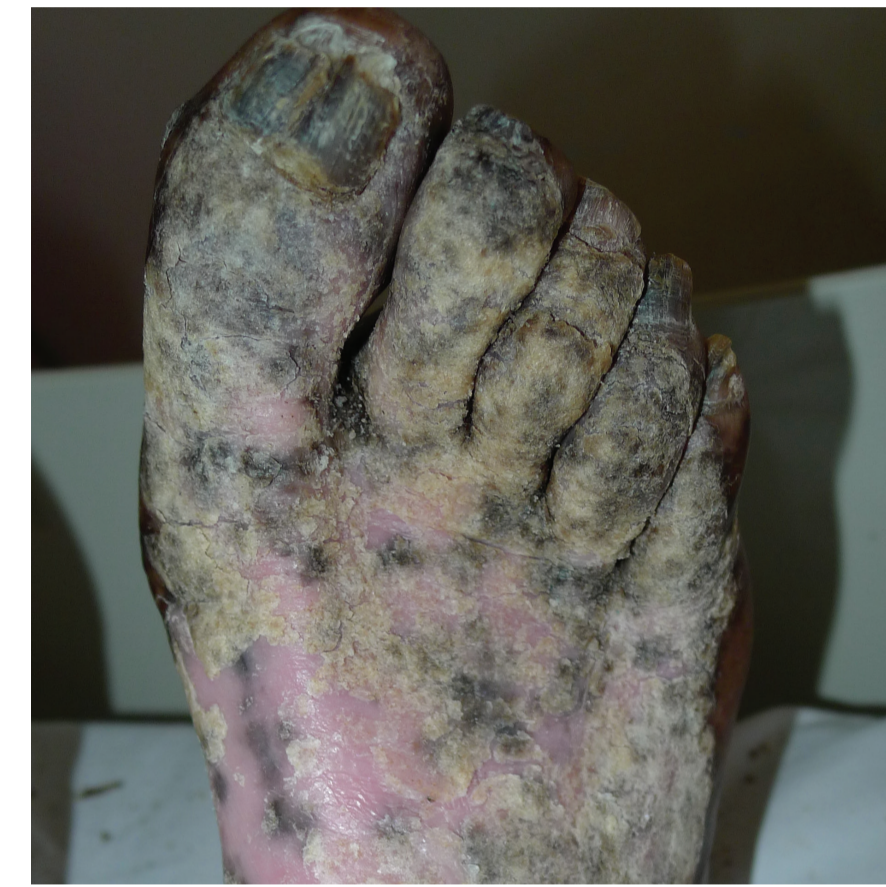Scabies



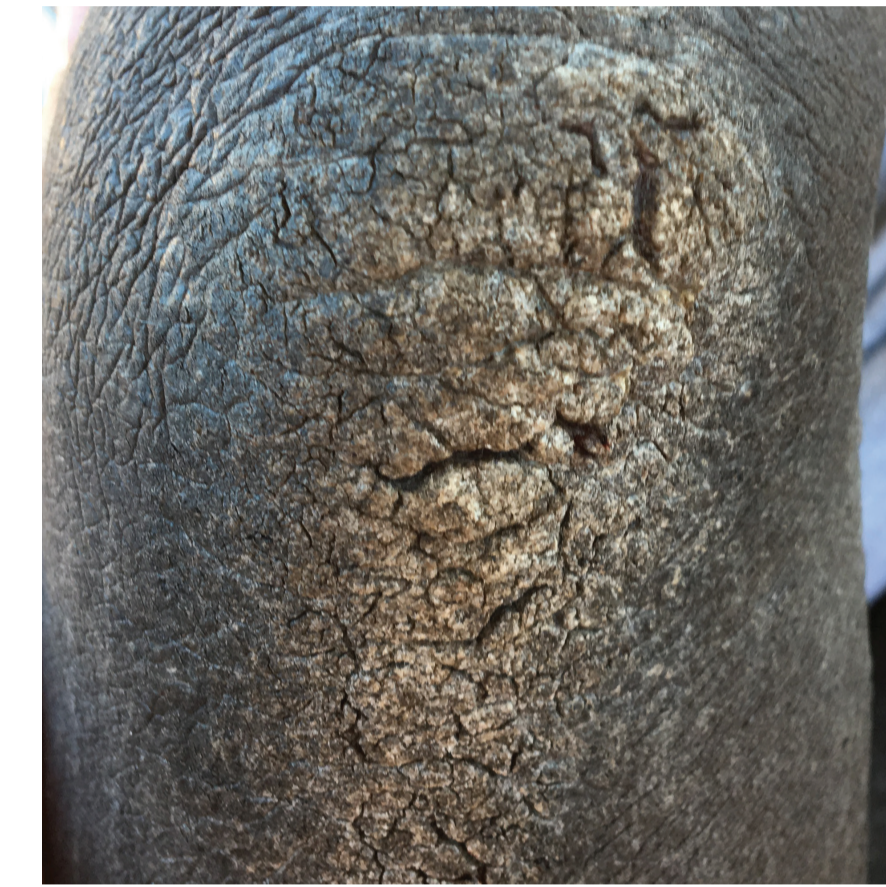Scabies with infected sores (Impetigo)



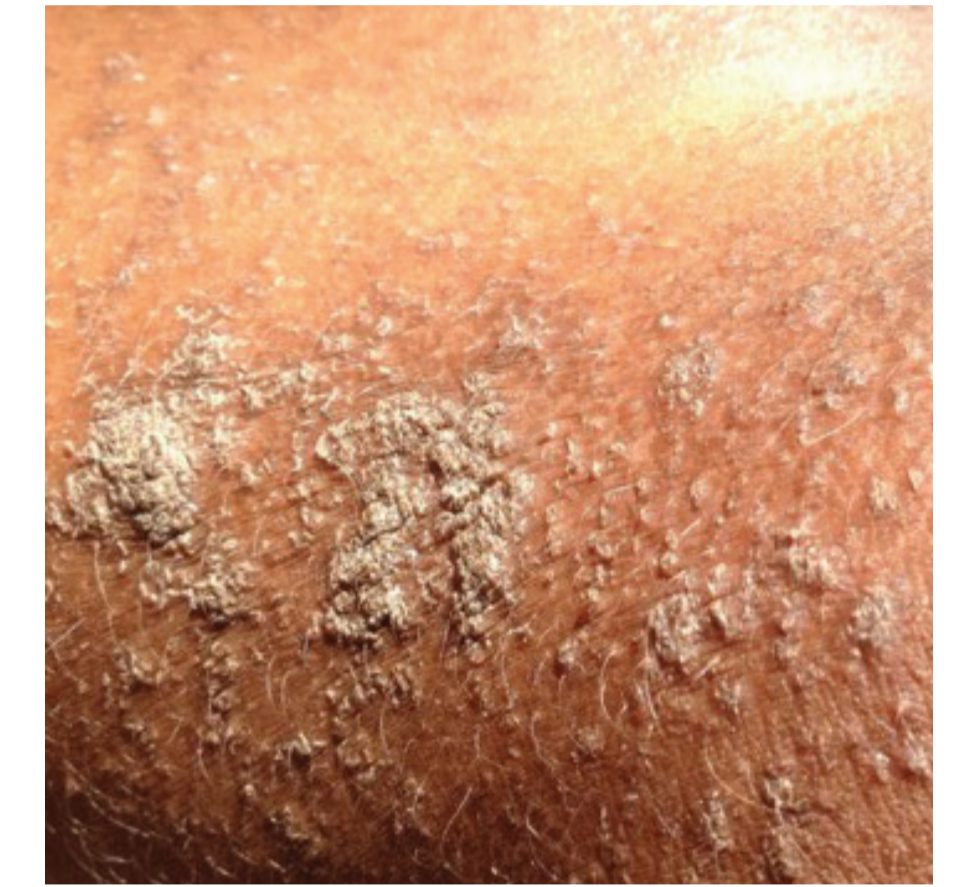Scabies with infected sores (Impetigo)



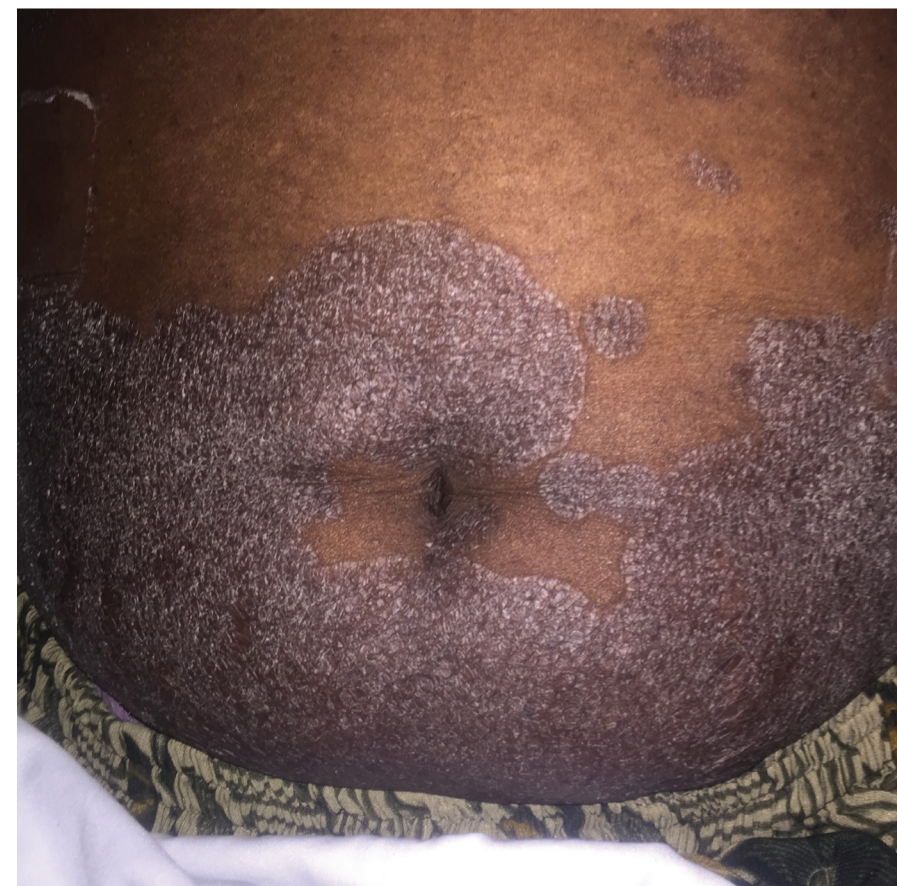Crusted Scabies and *Tinea unguium*



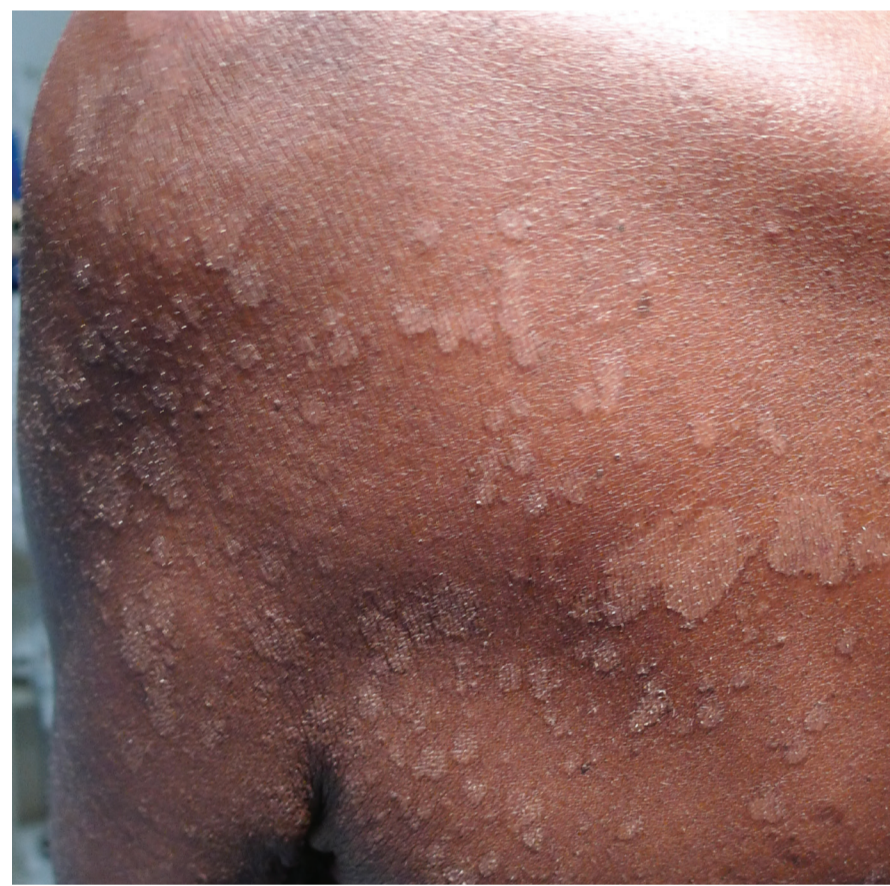Crusted Scabies



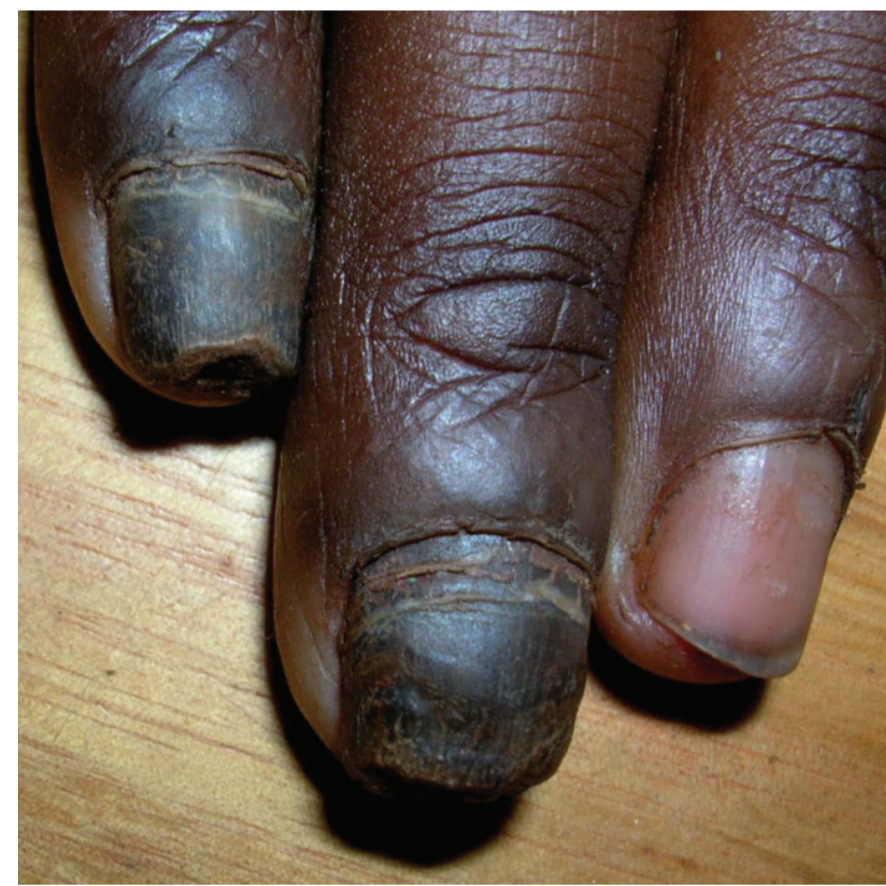Crusted Scabies



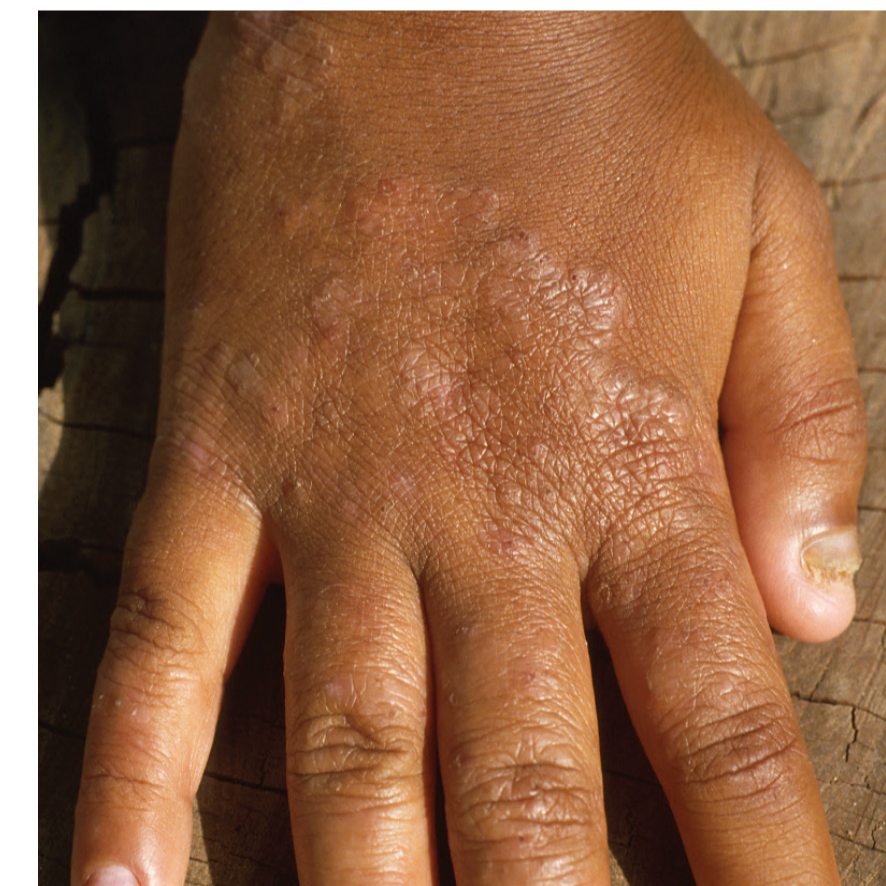Tinea corporis (caused by *T. rubrum*)



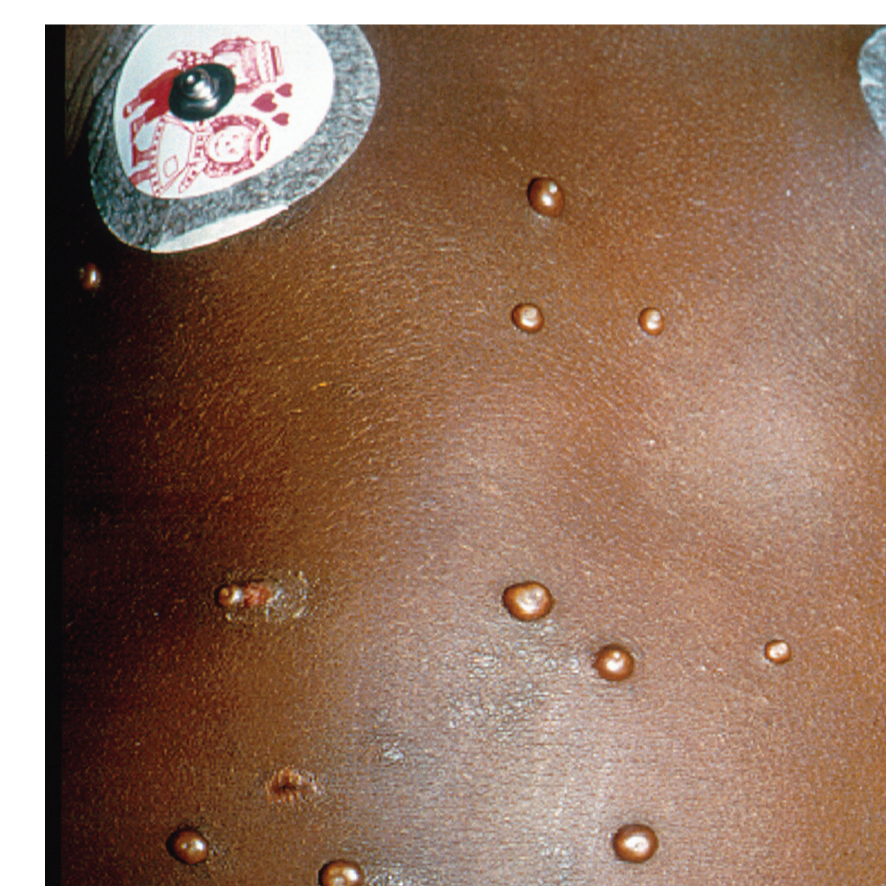Tinea versicolor (White Spot/Hankie)



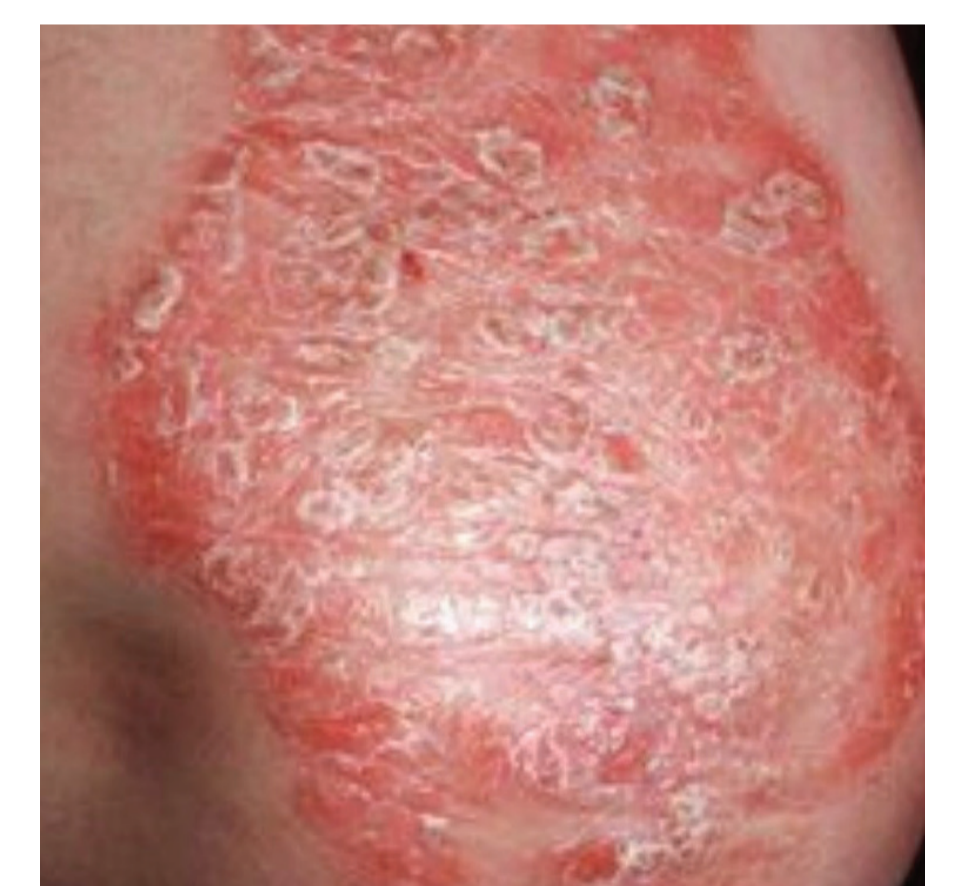Tinea unguium (Onychomycosis)



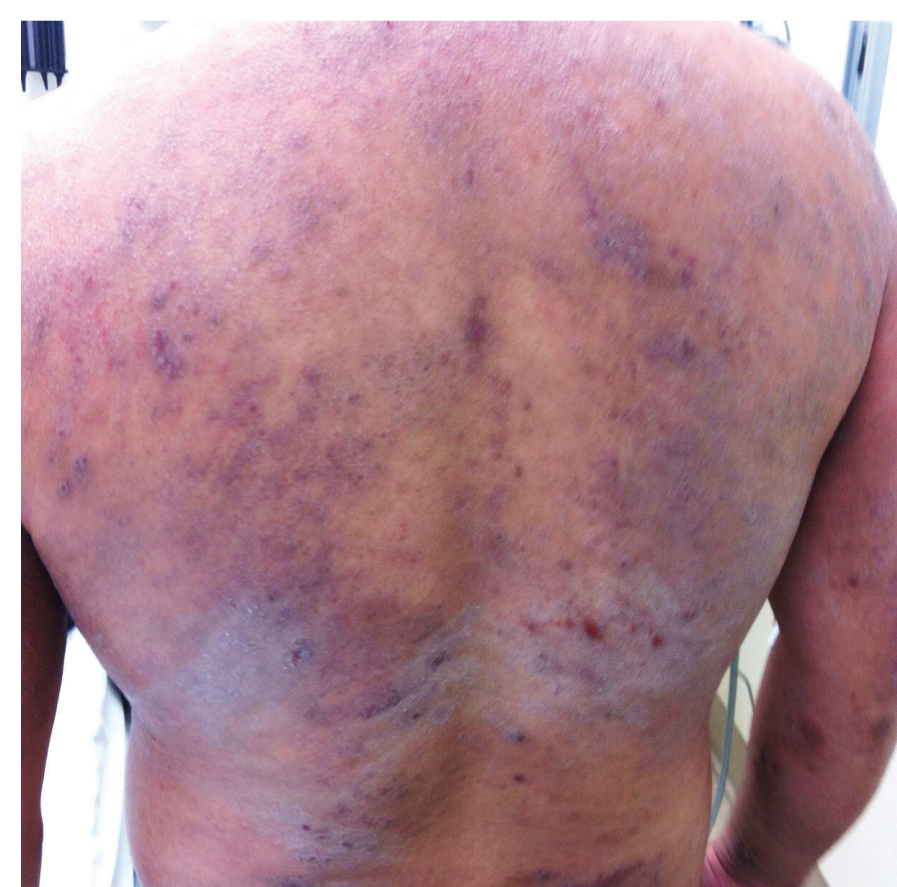Tinea manuum and unguium (Onychomycosis)



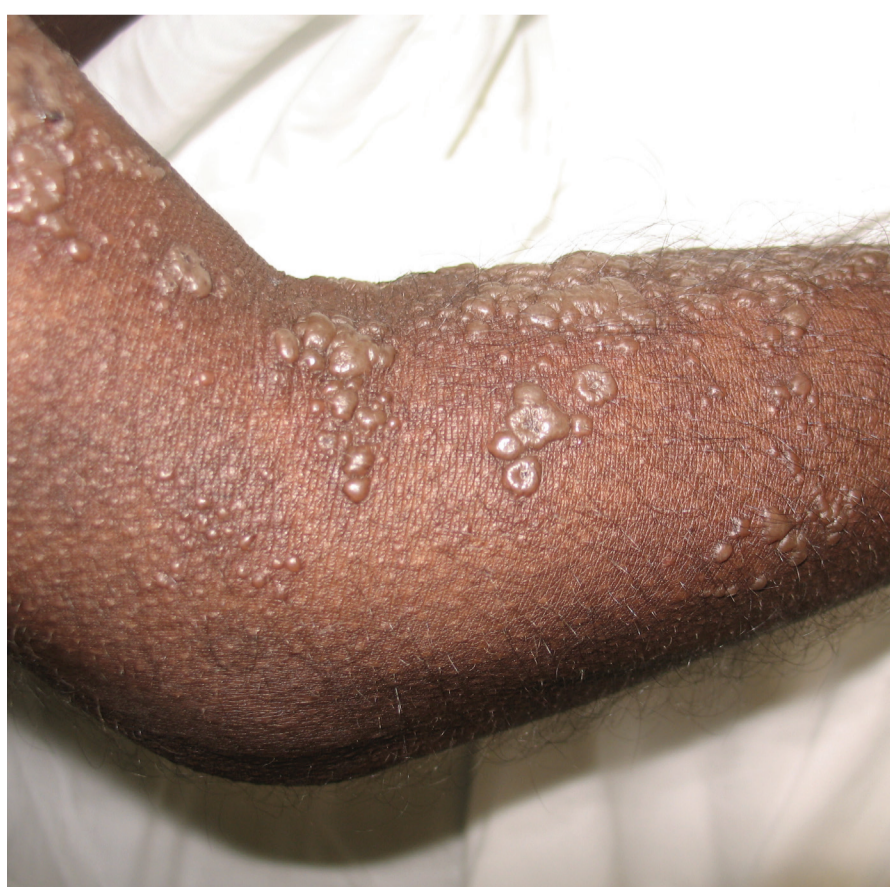Molluscum contagiosum



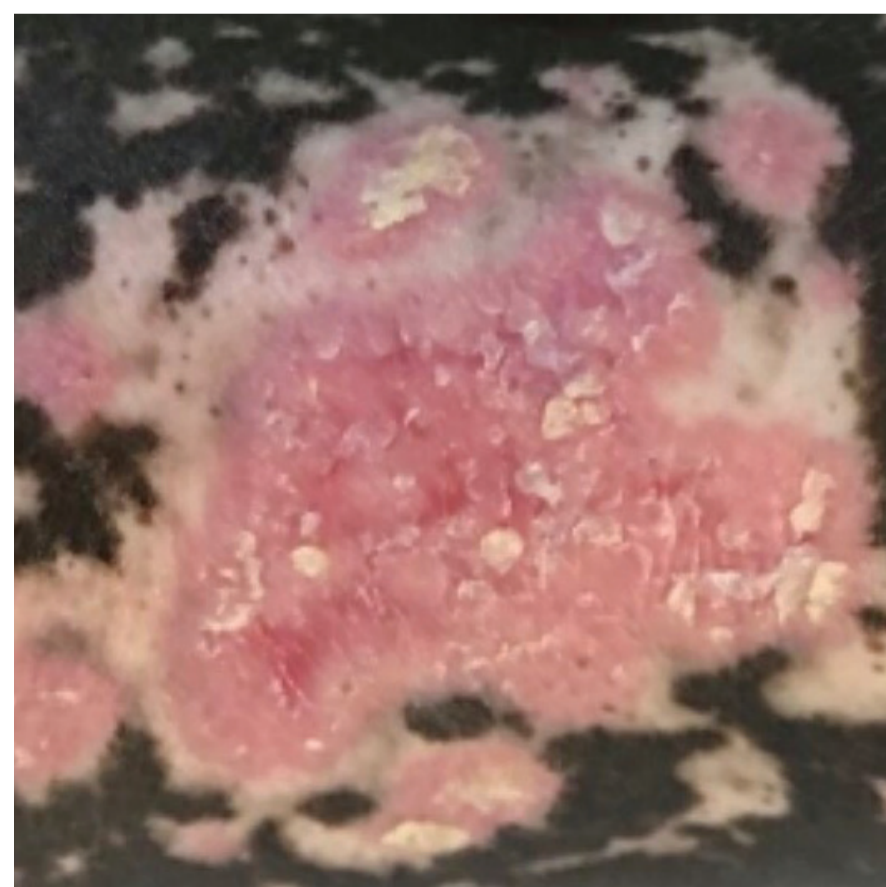
Psoriasis



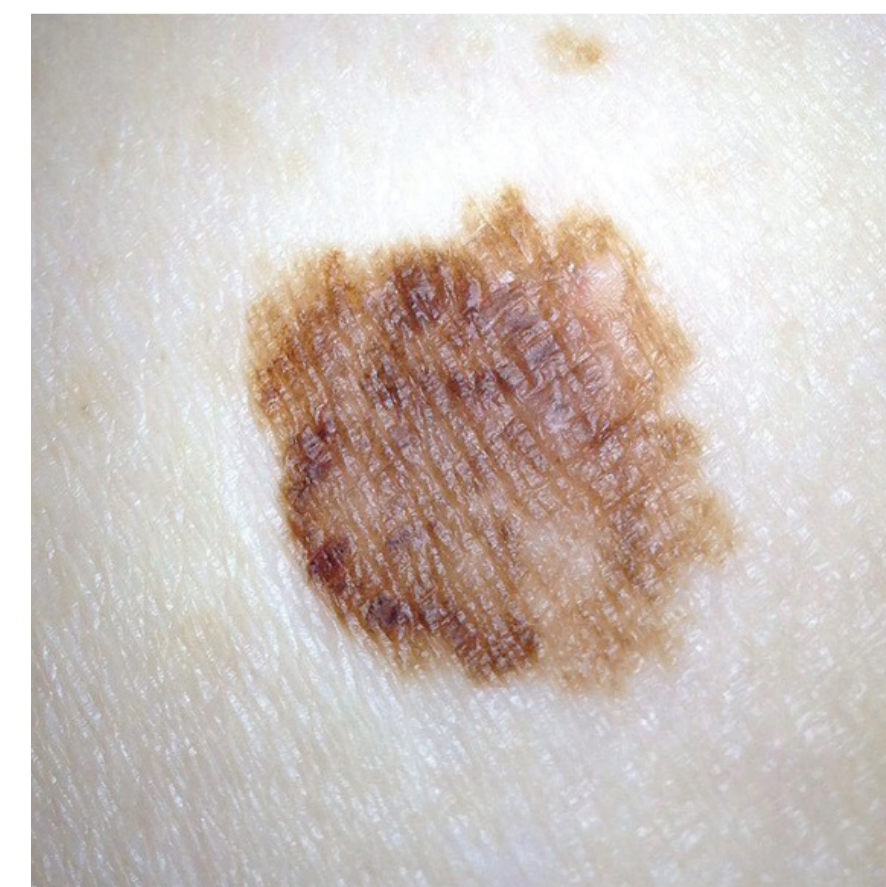Eczema (Dermatitis)



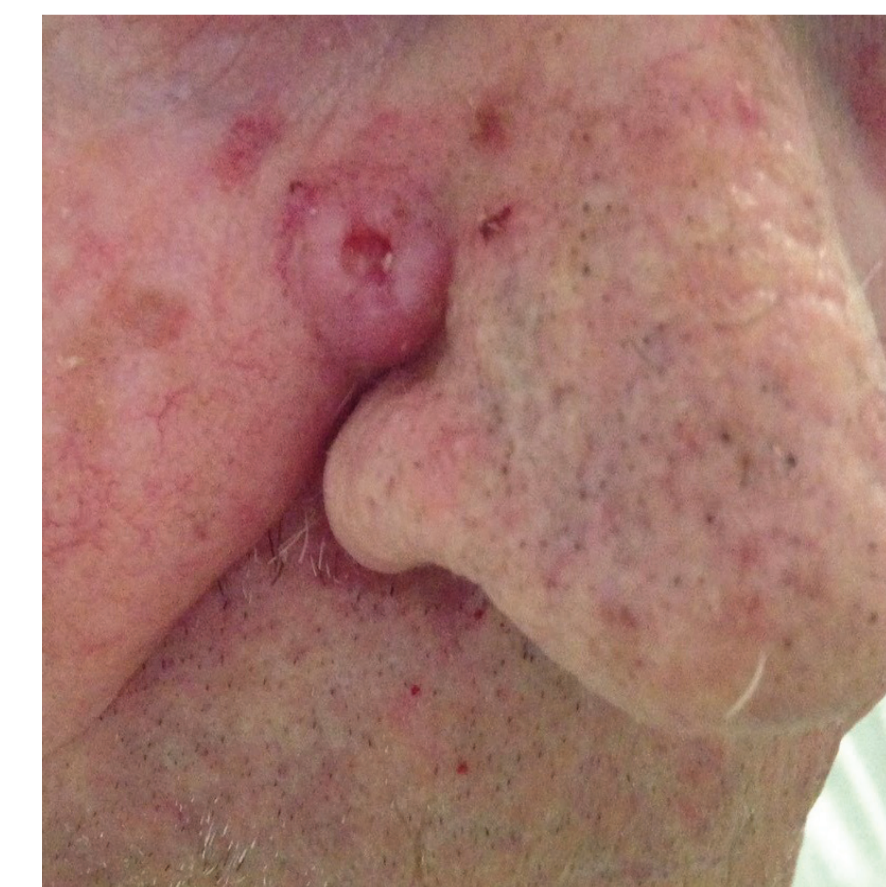
Varicella zoster (Chicken Pox)



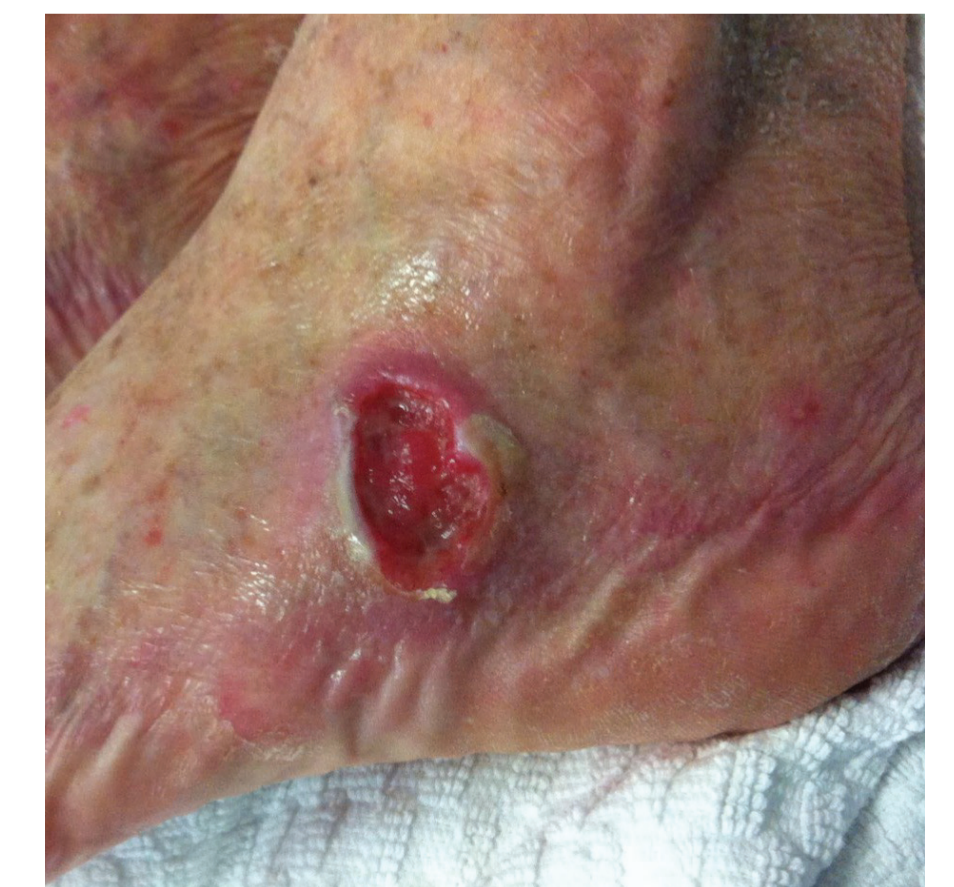Discoid lupus erythematosus (DLE)



Melanoma



Basal cell carcinoma (BCC)



Squamous cell carcinoma (SCC)