

Simultaneous Changes in Abdominal Adipose and Muscle Tissues Following Treatments by High-Intensity Focused Electromagnetic (HIFEM) Technology-Based Device: Computed Tomography Evaluation

David E. Kent MD,^a Carolyn I. Jacob MD^b

^aSkin Care Physicians of Georgia, Macon, GA

^bChicago Cosmetic Surgery and Dermatology, Chicago IL

ABSTRACT

Objective: This study investigates the effects of high-intensity focused electromagnetic technology for induction of changes in abdominal muscles and abdominal subcutaneous fat.

Methods: 22 male and female subjects (aged 34 to 64, mean BMI, 23.5kg/m²) underwent 8 treatments of the abdomen (2 per week) with a high-intensity focused electromagnetic field device. Subjects were scanned by computed tomography (CT) at baseline and 1 month after the eighth treatment. Sub-umbilical and epi-umbilical slices were used to measure the thickness of subcutaneous fat and abdominal muscles and the abdominal separation. In addition, standardized photographs, weight, and circumference measurements were collected.

Results: While comparing baseline to follow-up measurements, CT data showed on average 17.5% (-3.1±1.9mm) reduction in subcutaneous fat and simultaneous 14.8% (+1.5±0.8mm) thickening of the rectus abdominis muscle. Subjects lost on average 3.9±3.1cm in the waist circumference. Most of the waist reduction effect was achieved after the fourth treatment. The width of abdominal separation decreased by 9.5% (-2.0±1.7mm). All results were highly significant ($P<0.01$) while weight change was insignificant ($P<0.05$). Digital photographs showed aesthetic improvement in most subjects. The treatments were painless and without adverse events.

Conclusion: Results suggest that the investigated device is effective for abdominal body sculpting. This technology produced rectus muscle hypertrophy and a reduction in subcutaneous abdominal fat. Data suggests 4 treatments as the ideal protocol delivering 86% of the observed improvement.

J Drugs Dermatol. 2019;18(11):1098-1102.

INTRODUCTION

Long-term intensive resistance training programs are known to improve isometric strength^{1,2} and result in muscle hypertrophy,^{3,4} with accepted hypotheses that the hypertrophic effects are primarily caused by induced muscular micro injury.^{5,6} Yet studies demonstrate that approximately 50% of people attempting to follow some kind of exercise program drop out due to lack of motivation after several months.^{7,8} Magnetic stimulation was investigated as an alternative to resistance training and results showed improvement in muscle strength.^{9,10}

Recent studies¹¹⁻¹⁴ reported that intense muscle contractions induced by application of high-intensity focused electromagnetic (HIFEM) technology increased anterior abdominal muscle mass, reduced subcutaneous fat thickness, and reduced the distance between the rectus abdominis muscles. The net result was a reduction in abdominal waist circumference and an improvement in the overall appearance of the abdomen. HIFEM technology is based on a rapidly changing magnetic field gen-

erated with a wire coil that, as described by the Faraday's law of electromagnetic induction, induces a secondary electric current in the underlying tissue.¹⁵ The current triggers action potentials in motor neurons which consequently lead to muscle contractions in the area of application.¹⁵

Initial HIFEM studies that reported changes in both muscle and fat tissues applied four-treatments. It has been proposed that a higher number of induced muscle contractions will result in more muscle micro injury with resultant increased muscle hypertrophy and fat reduction. However, studies that have investigated this hypothesis are lacking.

This study investigated an extended treatment protocol of a novel device (EMSCULPT, BTL Industries Inc., Boston, MA) utilizing a high-intensity focused electromagnetic (HIFEM) field. The goal of this study is to evaluate the safety and effects of adipose and muscle tissues in the abdomen using computed tomography (CT) and an extended treatment protocol.

MATERIALS AND METHODS**Study Design**

Eligible candidates for this study were men or women aged 21-65 years with no weight changes exceeding 5 lbs in the preceding month. For the duration of the study, subjects were instructed to avoid major diet and lifestyle changes. Exclusion criteria for this study ruled out candidates with pregnancy, implanted electronic devices, metal implants (in near proximity to the treatment area, such as hip replacements; shoulder replacements, and/or knee replacements were not considered as exclusion criteria), heart disorders, treatment for active malignancy, and any medical conditions contraindicating the application of an electromagnetic field.

In total, 3 male and 19 female subjects were recruited for the study. The subjects aged from 34 to 65 years (mean age, 47.3±8.5 years) and had a mean BMI of 23.5±3.5 kg/m². Before the treatments, all subjects received informed consent about the treatment procedure and signed written consent. The treatment was applied to the abdomen using the EMSCULPT device (BTL Industries Inc., Boston, MA) based on HIFEM technology. The device consists of a control unit and a cable connecting the unit to a coil applicator, which is applied over the treatment area. The circular coil located in the applicator induces a magnetic field with intensities reaching up to 1.8T and an active depth of approximately 7cm.

The treatment protocol consisted of 8 sessions kept 2-3 days apart. The protocol was approved by IRB and conformed to the ethical guidelines of the 1975 Declaration of Helsinki. The duration of a single treatment was 30 minutes. Subjects were positioned in a supine position, and the treatment was performed by placing the applicator centred over their umbilicus. The applicator was secured by a Velcro belt. During the first session, the intensity of the magnetic stimulation was initially set to low levels of around 10% of the device's maximum output to allow the subjects experience the sensation felt during the treatment. The intensity was then gradually increased to induce challenging but not painful muscle contractions just below subjects' tolerance threshold. All subjects reached 100% intensity and were able to maintain this level of stimulation during treatment sessions. During each session and follow up visit the subjects were screened for any adverse events related to the treatment.

Data Collection

Computed tomography (CT) imaging was used to evaluate the outcome of the treatments. Subjects were scanned by a General Electric VCT 64 Slice Lightspeed CT scanner (the body section defined by the T2 and S1 vertebrae) at baseline and 1 month after the last treatment. The sub-umbilical and epi-umbilical slices were extracted from the acquired CT scans and analyzed and measured for the thickness of subcutaneous fat, the thickness of

rectus abdominis muscle, and the width of abdominal muscle separation. Measurements were taken at both epi-umbilical and sub-umbilical slices, and their average was recorded.

Waist circumference was measured at baseline and after each treatment by anthropometric tape. The measurements were performed at the upper edge of the umbilicus which served as a standardized point throughout the measurements. Further, standardized photographs and weight measures were taken throughout the study to monitor the subjects' progress. All data were statistically tested for significance using two-sample paired t-test with the significance level α set to 5%.

RESULTS

All 22 subjects completed the full set of treatments and underwent CT imaging at baseline and 1 month after the last treatment. The weight of all subjects was maintained within 5 lbs of the baseline with an average weight change of 1.0 lb ($P>0.05$). Fat thickness and abdominal separation were reduced, while muscle thickness increased significantly at the 1-month measurements. Waist circumference was gradually decreasing over the course of the treatments. The result summary can be seen in Table 1.

TABLE 1.

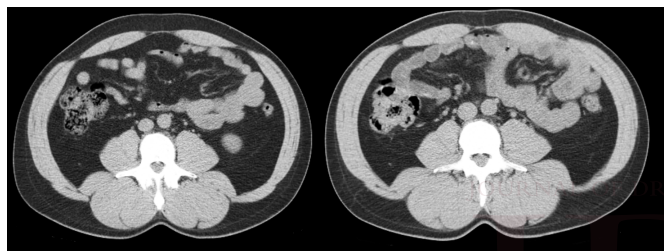
Result Summary			
Measurement	Baseline	1 month FU	Difference
Rectus abdominis thickness [mm]	11.0±2.1	12.5±2.0	1.5±0.8 ($P<0.001$)
Subcutaneous fat thickness [mm]	18.3±7.1	15.2±6.5	-3.1±1.9 ($P<0.001$)
Abdominal separation [mm]	20.1±9.2	18.1±8.8	-2.0±1.7 ($P<0.001$)
Waist circumference [cm]	81.1±7.9	77.2±7.4	-3.9±3.1 ($P<0.001$)
Weight [lb]	143.8±23.6	142.8±23.5	-1.0±2.8 ($P>0.05$)

Evaluation of the CT scans showed a statistically significant increase ($P<0.001$) of rectus abdominis muscle thickness by an average of 14.8% (1.5±0.8mm). All subjects demonstrated an increase in muscle thickness except subject ID15 who did not show any muscle thickening despite a 14.6% abdominal fat reduction. In 15 subjects the measured muscle thickening exceeded 10%.

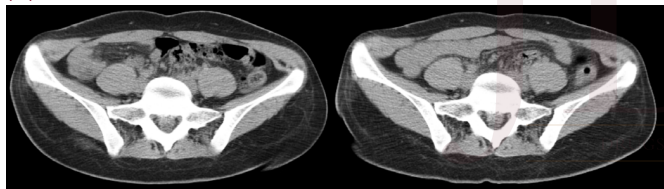
Analysis of the subcutaneous adipose tissue revealed a noticeable decrease ($P<0.001$) in the average fat thickness by 17.5% (-3.1±1.9mm). In 18 out of the 22 subjects, the measured reduction in subcutaneous fat exceeded 10%, and 12 out of the 22 subjects showed fat reduction higher than 16%. Subject ID10 did not show any fat reduction while her abdominal muscle thickened by 8%. Subject ID8 had an extremely thin fat layer and it

FIGURE 1. CT scans of three subjects taken at baseline (left) and 1 month post-treatment (right). **(A)** Subject ID 9, reduction of subcutaneous fat by -30.3% (-5.38mm), thickening of rectus abdominis muscle by +8.4% (+1.5mm). Reduction in waist circumference by -2.0cm and abdominal separation by 3.1mm. **(B)** Subject ID11, reduction of subcutaneous fat by -32.4% (-6.8mm) with simultaneous thickening of rectus abdominis muscle by +28.0% (+2.5mm) and reduction in abdominal separation by 2.9mm. The subject lost 2.5 cm in waist circumference. **(C)** Subject ID 5, reduction of subcutaneous fat by -7.7% (-1.0mm) and thickening of rectus abdominis muscle by +21.4% (+2.4mm). Reduction in abdominal separation by 0.84mm and 9cm in waist circumference.

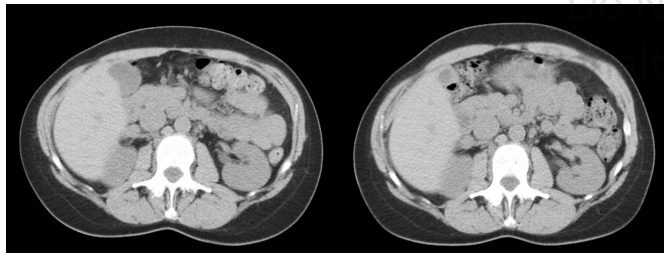
(A)



(B)



(C)

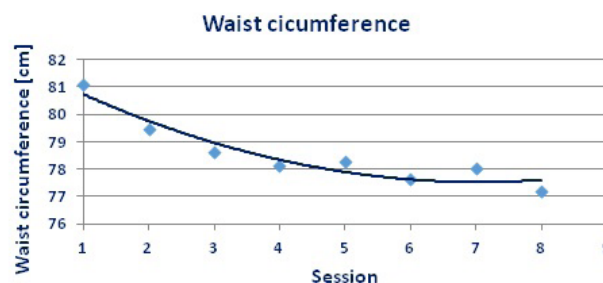


was not possible to measure any change in thickness. No significant correlation was found between the muscle thickening and reduced fat thickness ($r=0.07$, $n=21$, $P=0.77$).

The width of abdominal rectus muscle separation showed a decrease on average by 9.5% (-2.0 ± 1.7 mm) ($P<0.001$). No correlation was found between the muscle thickening and reduction of abdominal separation of the right and left rectus muscles ($r=0.35$, $n=20$, $p=0.13$). Baseline and 1-month CT scans of three subjects are displayed as an example in Figure 1. Rectus abdominis separation was not measurable in subject ID1 who had undergone abdominoplasty some time before this study.

Waist circumference measurements showed an average decrease 3.9 ± 3.1 cm ($P<0.001$) when compared to post-treatment measurements. The decreasing trend was seen throughout all

FIGURE 2. Chart displaying the average waist circumference after each session.



measurements, however, the main descent was observed during the first four sessions (average 3.0 ± 2.52 cm). Additional treatments lead to further circumferential reduction (0.93 ± 1.78 cm) but not to such extent as during the first four treatments. The course of the waist circumference throughout the procedure is documented in Figure 2, where a polynomial curve of a 3rd order was fitted into the data.

The subjects, who experienced muscle contractions induced by the electromagnetic field for the first time, described the initial pulses of the treatment as intense, but quickly adapted to the feeling and further on found the treatments comfortable. Most of them reported intense and strong muscle contractions but no discomfort. None of the subjects reported any pain associated with the treatment. Several subjects reported soreness and muscle fatigue on the day after the treatment, which was comparable to post-workout fatigue. Besides that, no adverse events were observed.

DISCUSSION

The results of this study demonstrate that the HIFEM technology effectively induced a dual effect in abdominal fat and skeletal muscles. Increased muscle thickening was accompanied by reduction of the abdominal fat layer and waist circumference in almost all patients. One subject did not show fat reduction and one subject did not show any muscle thickening yet each subject showed improvement in at least 2 out of the 3 conducted measurements. There were no non-responding patients. The degree of fat reduction appears to be independent of the degree of muscle thickening.

The increase in muscle thickness by 14.8% correlates with a study done by Kinney et al¹¹ who used MRI evaluations of muscle thickness 2 months after the protocol of 4 treatments and found an average reduction of 15.4% (Difference was statistically insignificant $P<0.05$). Because CT scans were obtained 1 month post-treatment, transient muscle swelling can be ruled out as a reason for the observed hypertrophy, as it typically resolves within 7 to 11 days after muscle micro injury.¹⁶ Comparison of

TABLE 2.

Comparison of the Present Study With Kinney et al		
Study	Kinney et al.*	Present Study**
Evaluation	MRI	CT
#Subjects	22	22
Age	39.4	47.3
BMI	25.7kg/m ²	23.5kg/m ²
#Treatments	4	8
Waist reduction	3.8cm	3.9cm
Muscle thickening	15.4%	14.8%
Fat reduction	18.6%	17.5%
Abdominal separation	10.4%	9.7%

*Measurements 2 months post-treatments

**Measurements 1 month post-treatments

our results with the Kinney et al data is seen in Table 2.

Subjects maintained their regular diet and activity level without any modifications. In the absence of other mechanisms of fat reduction, it is likely the observed fat reduction resulted from lipolytic and/or apoptotic actions induced by the intense muscle contractions during the treatment. Intensive resistance training is known to induce lipolysis.^{17,18} The study by Weiss et al¹⁴ found an increased apoptotic index in the porcine model after single HIFEM treatment. They hypothesized that local supramaximal sustained muscle contractions may cause high levels of lipolysis which can induce stress of endoplasmic reticulum and fat cell apoptosis.

Our fat thickness measurements when compared to previous studies of Kinney et al and Katz et al¹³ (Table 2) had similar fat reduction. Their data demonstrated 18.6% and 19% reduction one month post four treatments, respectively. While not entirely certain, the slightly higher average improvement of Kinney et al might be attributed to the difference in time of the after measurements. Measures performed by Kinney et al were obtained 2 months post-treatment, which were twice as long as our study. Theoretically, skeletal muscles thus had more time to adapt to contractions by muscle growth, and more fat cells could be flushed out of the system when compared to our measurements 1 month post-treatment. The age of the subjects could also play a role. The subject group in the study by Kinney et al was approximately 8 years younger, and younger subjects could, therefore, yield more prominent changes. Similarly, for muscle thickness, the comparison indicates that protocol with more than 4 treatments may not necessarily produce any additional fat reduction.

No changes were observed in the BMI, which can be explained by the fact that the increased volume of the muscles compensated for the weight of the reduced fat. The waist circumference was reduced during the first 4 treatments ($-3.0\pm 2.52\text{cm}$), then,

the circumference reduced in a slower pace by additional $0.93\pm 1.78\text{cm}$. This suggests that 4 treatments may be sufficient for inducing substantial changes in the abdominal skeletal muscle. The reduction of the waist circumference can be caused not only by the fat reduction but also by firmer abdominal musculature. The waist circumference reduction observed in our study conforms to study by Jacob et al.¹² who found a reduction of $3.29\pm 1.9\text{cm}$ after the fourth treatment with HIFEM device and even $4.37\pm 2.63\text{cm}$ reduction during 3-month follow-up.

One of the limitations of the present study is the patient population as the study included 22 subjects. A bigger patient group would provide higher reliability of the statistical analysis and would bring a broader insight on how different patient group react to the treatments and whether the same result would have been seen. Another limitation of the study is that the present study evaluated the subjects 1-month post-treatment. Future studies focusing on longer-term evaluation and follow up regarding the durability of results would be beneficial. Additionally, studies designed to evaluate the role of potential maintenance treatments for sustained improvement would be insightful. Functional parameters that measure isometric strength¹⁹ and dynamic endurance¹⁹ of abdominal muscles might provide insight into actual physical conditioning.

CONCLUSION

Results show that a HIFEM device is successful for abdominal body sculpting. CT scans documented improvement in both subcutaneous adipose tissue reduction and abdominal skeletal muscle hypertrophy. These results provided pleasing aesthetic improvement. This device also has a very low-risk profile with no thermal effects. Comparison with other studies suggests that treatment protocol including eight sessions does not necessarily bring a significant increment in results compared to 4 treatment protocol results.

DISCLOSURES

David Kent MD and Carolyn I. Jacob are medical advisors for BTL.

ACKNOWLEDGMENT

We would like to thank the Radiology Associates of Macon for performing all CT scans.

REFERENCES

1. Skelton DA, Young A, Greig CA, Malbut KE. Effects of Resistance training on strength, power, and selected functional abilities of women aged 75 and older. *J Am Geriatr Soc.* 1995;43(10):1081-1087. doi:10.1111/j.1532-5415.1995.tb07004.x
2. Macaluso A, De Vito G. Muscle strength, power and adaptations to resistance training in older people. *Eur J Appl Physiol.* 2004;91(4):450-472. doi:10.1007/s00421-003-0991-3
3. Verdijk LB, Gleeson BG, Jonkers RAM, et al. Skeletal muscle hypertrophy following resistance training is accompanied by a fiber type-specific increase in satellite cell content in elderly men. *J Gerontol Ser A.* 2009;64A(3):332-339. doi:10.1093/gerona/gln050

4. Ruther CL, Golden CL, Harris RT, et al. Hypertrophy, resistance training, and the nature of skeletal muscle activation. *J Strength Cond Res.* 1995;9(3):155.
5. Evans WJ. Effects of exercise on senescent muscle. *Clin Orthop.* 2002;(403 Suppl):S211-220.
6. Hill M, Goldspink G. Expression and splicing of the insulin-like growth factor gene in rodent muscle is associated with muscle satellite (stem) cell activation following local tissue damage. *J Physiol.* 2003;549(Pt 2):409-418. doi:10.1113/jphysiol.2002.035832
7. Matsumoto H, Takenaka K. Motivational profiles and stages of exercise behavior change. *Int J Sport Health Sci.* 2004;2:89-96. doi:10.5432/ijshs.2.89
8. Wilson K, Brookfield D. Effect of goal setting on motivation and adherence in a six-week exercise program. *Int J Sport Exerc Psychol.* 2009;7(1):89-100. doi:10.1080/1612197X.2009.9671894
9. Selkowitz DM. Improvement in Isometric strength of the quadriceps femoris muscle after training with electrical stimulation. *Phys Ther.* 1985;65(2):186-196. doi:10.1093/ptj/65.2.186
10. Currier DP, Mann R. Muscular Strength Development by Electrical Stimulation in Healthy Individuals. *Phys Ther.* 1983;63(6):915-921. doi:10.1093/ptj/63.6.915
11. Kinney BM, Lozanova P. High intensity focused electromagnetic therapy evaluated by magnetic resonance imaging: Safety and efficacy study of a dual tissue effect based non-invasive abdominal body shaping. *Lasers Surg Med.* 0(0). doi:10.1002/lsm.23024
12. Jacob CI, Paskova K. Safety and efficacy of a novel high-intensity focused electromagnetic technology device for noninvasive abdominal body shaping. *J Cosmet Dermatol.* September 2018. doi:10.1111/jocd.12779
13. Katz BE, Bard RL, Goldfarb R, et al. Changes in subcutaneous abdominal fat thickness following high-intensity focused electro-magnetic hifem field treatments: a multi center ultrasound study. In: Vol 50. Dallas TX, USA: *Lasers in Surgery and Medicine.* 2018:360-361. doi:10.1002/lsm.22814
14. Weiss R, Bernardy J. Induction of fat apoptosis by a non-thermal device: safety and mechanism of action of non-invasive HIFEM technology evaluated in a histological porcine model. *Present Annu Meet Am Soc Lasers Surg Med.* 2018.
15. Barker AT. An introduction to the basic principles of magnetic nerve stimulation. *J Clin Neurophysiol Off Publ Am Electroencephalogr Soc.* 1991;8(1):26-37.
16. Zainuddin Z, Newton M, Sacco P, et al. Effects of massage on delayed-onset muscle soreness, swelling, and recovery of muscle function. *J Athl Train.* 2005;40(3):174-180.
17. Ormsbee MJ, Thyfault JP, Johnson EA, et al. Fat metabolism and acute resistance exercise in trained men. *J Appl Physiol Bethesda Md 1985.* 2007;102(5):1767-1772. doi:10.1152/jappphysiol.00704.2006
18. Chatzinikolaou A, Fatouros I, Petridou A, et al. adipose tissue lipolysis is up-regulated in lean and obese men during acute resistance exercise. *Diabetes Care.* 2008;31(7):1397-1399. doi:10.2337/dc08-0072
19. Porcari JP, Miller J, Cornwell K, et al. The effects of neuromuscular electrical stimulation training on abdominal strength, endurance, and selected anthropometric measures. *J Sports Sci Med.* 2005;4(1):66-75.

AUTHOR CORRESPONDENCE

David E. Kent MD

E-mail:..... DEKent@dsspc.com