

Anterior Vaginal Mesh Revision with Partial Excision Augmented with a Next-Generation Decellularized Dermal Allograft (DermaPure®)

R. Keith Huffaker, MD, MBA, FACOG

Surgical Summary

Presentation:

A 62-year-old female with a history of pelvic/vaginal pain, urinary urgency, frequency, nocturia, MUI, fecal urgency, fecal incontinence. Prior Surgical History: TVH/RS&O/"bladder tack" by patient report (per another provider, 17 years prior); LS&O (per another provider, 14 years prior); history of "bladder tack" by patient report and prolapse repair w/ mesh placement (per another provider, 9 years prior).

Assessment:

Clinical evaluation revealed near-full thickness anterior mesh exposure, cystocele and stage 2 pelvic organ prolapse.

Procedures:

- Anterior vaginal mesh revision with partial excision
- DermaPure®, a decellularized dermal allograft, implanted to regenerate attenuated tissues
- Mid-urethral sling revision
- Cystourethroscopy

Intra-Operative Implantation of DermaPure:



Figure 1




Figure 2

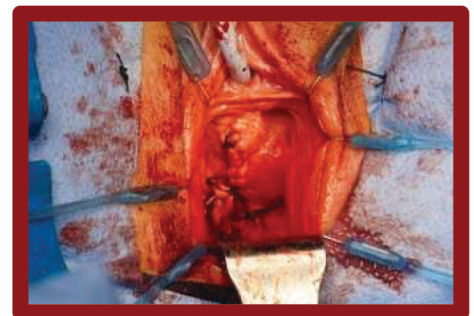


Figure 3


Outcome:

- 4 week follow-up revealed appropriate healing, although not yet matured.
- The patient reported vaginal and pelvic pain markedly improved.
- DermaPure® allograft implant allowed for regeneration of attenuated and missing tissues.

Surgeon Perspective:

"The Veronikis Vaginal Retraction System markedly lessens the surgeon's dependence on Surgical Assistants and improves visualization during vaginal procedures. I find it especially helpful with mesh revision procedures. The DermaPure® dermal allograft was utilized in this case due to extensive tissue involvement with mesh and related tissue disruption with mesh revision. Both connective tissues and vaginal epithelium were significantly affected, and grafts were placed for both purposes."

– R. Keith Huffaker, MD, MBA, FACOG



4 Weeks Post Op

Anterior Vaginal Mesh Revision with Partial Excision Augmented with a Next-Generation Decellularized Dermal Allograft (DermaPure®)

R. Keith Huffaker, MD, MBA, FACOG

Case Report

Preoperative Diagnosis:

- Vaginal and pelvic pain status post vaginal mesh insertion
- Attenuated pelvic support and vaginal tissues

Postoperative Diagnosis:

- Same as preoperative diagnosis
- Finding of mid-urethral sling that was under tension

Intraoperative Findings:

- Previously unknown mid-urethral sling identified and found to be under tension.
- Anterior pelvic organ support mesh, with the apical aspect of the mesh folded upon itself with very dense fibrotic response associated with the apical aspect of the mesh.
- Stage 2 post hysterectomy pelvic organ prolapse.
- Vaginal support mesh involving anterior vaginal epithelium with resultant vaginal epithelium defect status post mesh excision.
- No evidence of vaginal width or length compromise from current procedure.

Surgical Treatment:

- The patient was placed in dorsal supine position; general anesthesia administered; placed in Yellowfin leg holders; prepped and draped for a vaginal procedure. The bladder was drained.
- The Veronikis Vaginal Retraction System™ was placed along with a Lone Star retraction system.
- A combination of sharp and blunt dissection was carried out to separate vaginal epithelium from underlying mesh and surrounding tissues, including bladder and urethra. Hemostasis was somewhat difficult to maintain due to the dense adherence of the mesh to surrounding tissues.
- Could not preserve vaginal epithelium apically to the right due to the dense involvement of mesh.
- Mid-urethral sling in place, which appeared to be under tension.
- Both the mid-urethral sling and the vaginal mesh were separately mobilized away in the midline from underlying tissues and transected in the midline. The mid-urethral sling was mobilized back to the obturator region and transected. No attempt was made to remove mesh arms.
- A 7 x 5 cm transversely oriented segment of DermaPure® allograft was placed in the anterior vagina due to the resultant marked defect in connective tissues. The graft was secured to underlying pubocervical connective tissue and vaginal epithelium with 2-0 Vicryl suture at each corner, in the midline, and then laterally.
- Vaginal epithelium was closed in running, locking midline longitudinal fashion in the distal anterior compartment with 2-0 Vicryl. The apex of the anterior compartment was closed with 3 interrupted 2-0 Vicryl sutures placed in simple side-to-side midline interrupted longitudinal serial fashion.
- There was a resultant defect in between the 2 closures oriented more toward the apical aspect of the anterior vagina to the right.
- The additional DermaPure allograft was fashioned to be approximately a 4 cm graft, approximately circular shape, sewn to the deep aspect of the vaginal epithelium with a 2-0 Vicryl suture in interrupted fashion circumferentially at approximately 1-1.5 cm segments.
- Following cystourethroscopy without abnormalities, vaginal Kling packing with Premarin cream was placed

DermaPure Decellurized		
030400HD	3 cm x 4 cm	DermaPure Decellularized Dermal Allograft
040600HD	4 cm x 6 cm	DermaPure Decellularized Dermal Allograft
071000HD	7 cm x 10 cm	DermaPure Decellularized Dermal Allograft