


# Healing Dynamics Following Alveolar Ridge Preservation with Autologous Tooth Structure



Ziv Mazor, DMD<sup>1</sup>  
 Robert A. Horowitz, DDS<sup>2</sup>  
 Hari Prasad, MS<sup>3</sup>  
 Georgios A. Kotsakis, DDS, MS<sup>4</sup>

*The objective of this clinical study was to assess the outcomes of autologous tooth structure in alveolar ridge preservation procedures. Extraction sites were grafted with autologous tooth structure prepared from the extracted teeth, and histologic samples were obtained at varying intervals to allow observation of bone-healing dynamics over time. Grafted areas were occupied by dentin particles that had begun to connect via bridges of woven bone at 3 months posthealing, and vital bone was in direct contact with residual particles with no inflammatory infiltrate. Further clinical investigation is warranted on the comparative effectiveness of autologous tooth structure against established bone-substitute biomaterials.*  
 Int J Periodontics Restorative Dent 2019;39:697–702. doi: 10.11607/prd.4138

Alveolar ridge preservation procedures that aim to limit postextraction ridge resorption have become mainstream dental procedures.<sup>1</sup> Nearly all available types of bone grafts and bone substitute biomaterials have been proposed for this indication and tested clinically.<sup>1,2</sup> Various types of allografts, xenografts, and alloplastic biomaterials have been recommended as viable alternatives to the use of autogenous grafts for ridge preservation due to the morbidity associated with the latter.<sup>2</sup> Nonetheless, an alternate source of autogenous mineralized tissue has been investigated for this indication: autologous dentin and cementum.<sup>3–5</sup>

This nonimmunogenic approach includes other benefits, such as immediate availability of the extracted tooth. This concept is not novel. The first approaches to using autologous tooth structure as a bone substitute date back to the late 1960s.<sup>6</sup> Bone induction has been shown after grafting with decalcified dentin implanted into oral, osseous, and muscle tissues.<sup>6,7</sup> In particular, Yeomans and Urist reported that the use of either decalcified dentin or bone as socket grafts demonstrated osteoinductive properties as compared to tendon or muscle grafts.<sup>6</sup> This research area was forgotten for nearly half a century until the recent interest in optimal extraction site

<sup>1</sup>Private Practice, Ra'anana, Israel.

<sup>2</sup>Departments of Periodontics, Implant Dentistry and Oral Surgery, New York University College of Dentistry, New York; Private Practice, Scarsdale; Private Practice, New York, New York, USA.

<sup>3</sup>Hard Tissue Research Lab, University of Minnesota, Minneapolis, Minnesota, USA.

<sup>4</sup>Department of Periodontics, UT Health San Antonio School of Dentistry, San Antonio, Texas, USA.

Correspondence to: Dr Ziv Mazor, 142 Ahuza Street, Ra'anana 43300, Israel.  
 Fax: 972-97602839. Email: mazor2@yahoo.com

Submitted October 8, 2018; accepted March 9, 2019.

©2019 by Quintessence Publishing Co Inc.

management for implant dentistry. Collectively, these efforts provide proof-of-principle data for the successful conservation of hopeless tooth material as a bone substitute.

Existing bone substitutes vary in their composition and origin from allogenic or xenogenic to alloplastic biomaterials. Notably, each bone substitute has unique physicochemical and biologic properties that dictate a singular resorption rate.<sup>8</sup> This has significant implications on two key determinants of treatment success: (1) required healing time, which is a patient-perceived outcome; and (2) quality of the regenerated bone, which is a clinical outcome.<sup>9</sup> Consequently, the rate and quality of new bone formation that each graft material stimulates or supports, and its capacity to allow creeping substitution by the host, are key determinants of material selection for grafting prior to implant placement. If an autologous, easily available, and nonimmunogenic structure could be utilized as an efficacious osteoconductive—and potentially osteoinductive—bone substitute, there would be merit in its clinical use. Therefore, the aim of this case series was to assess the outcomes of autologous tooth structure for ridge preservation in preparation for implant placement.

## Materials and Methods

The sample population consisted of 4 participants scheduled for tooth extraction and ridge preservation treatment using the extracted autologous tooth structure. Following

a thorough oral evaluation, patients were informed about the diagnosis and treatment alternatives and signed written consent forms.

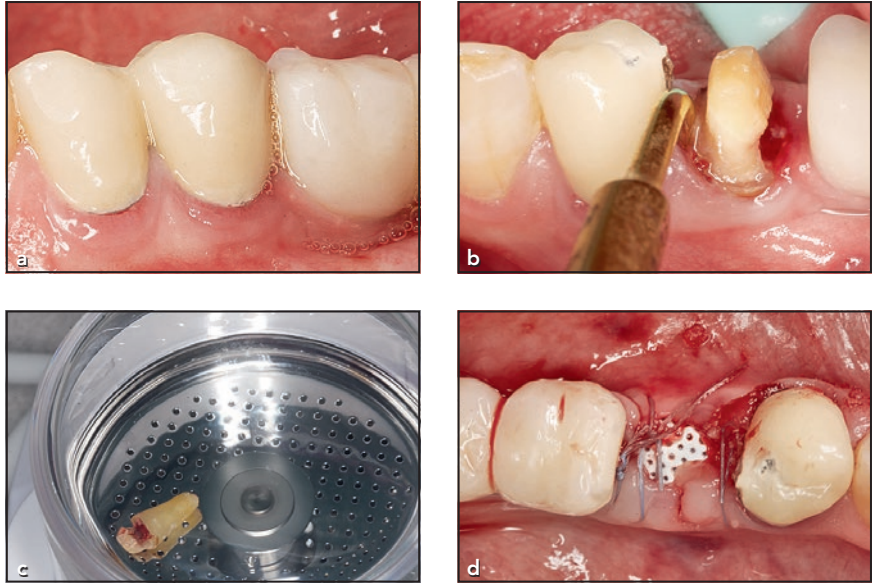
All participants in this case series were adults with noncontributory medical histories who underwent extractions of single teeth and had autologous tooth root tissue processed, filtered, and placed in their extraction sockets for ridge preservation according to a previously described protocol.<sup>10</sup> Briefly, teeth without previous history of endodontic treatment or pulpal necrosis were extracted and denuded of enamel, calculus, restorations, and periodontal ligament (PDL) with a tungsten carbide bur in a high-speed handpiece. The cases reported in the present study had teeth extracted due to nonrestorable caries. The teeth were then dried and placed in the sterile chamber of a dentin grinding machine (Smart Dentin Grinder, Kometa Bio). The machine performed grinding followed by filtering out particles < 300  $\mu\text{m}$ , finally yielding a bone substitute biomaterial consisting of autologous root particles ranging between 300 to 1200  $\mu\text{m}$  in size. The autologous particles were subsequently immersed in basic alcohol for cleaning and removal of organic debris following a modification of the protocol previously described.<sup>10</sup> Specifically, effort was made to remove enamel from the teeth prior to grinding because new data<sup>11</sup> show that, due to its high mineral density, enamel inhibits the proliferation of osteoblastic cells. Alcohol was selected because it is effective in reducing bacteria via denaturation but also evaporates rap-

idly, thus not leading to cytotoxicity as compared to other antimicrobials, such as chlorhexidine. Nonetheless, other authors have advocated for the use of ethylene oxide for contaminated teeth.<sup>12</sup> However, this was not employed in the present study because it is unclear whether the implantation of an autologous tooth structure that has been decontaminated with ethylene oxide is safe in humans.

## Surgical Procedures

Each participant received a standardized baseline examination consisting of dental and periodontal evaluations of the area around the involved tooth with periapical radiographs obtained using the long cone paralleling technique as per routine clinical practice. After establishing a hopeless tooth prognosis, extractions were performed atraumatically as previously described.<sup>8</sup> Briefly, the procedure consisted of cutting through the epithelial attachment with a 15c or 12b blade (Bard Parker) to transect the supracrestal fibers; PDL fibers were severed with a sharp periosteal. Piezosurgery was utilized to widen the PDL space and facilitate atraumatic tooth extraction (Figs 1a and 1b). Subsequently, the alveolus was thoroughly degranulated and care was given to avoid bi-digital compression of the postextraction sockets, as this may lead to excessive bone loss. The extraction socket was then grafted with the autologous tooth graft, which was procured as described above. Following grafting,

**Fig 1** Case 3. (a) A mandibular left second premolar underwent atraumatic extraction aided via (b) Piezosurgery. The tooth is then thoroughly debrided on the root surface and placed in (c) a dentin grinder to reduce the tooth to autologous tooth particles. Following particle preparation, the particles are brought to neutral pH and (d) used to graft the extraction socket prior to placement of a nonresorbable dense PTFE barrier.



a dense polytetrafluoroethylene (PTFE) membrane (Cytoplast Single, Osteogenics) was placed and left to heal in a nonsubmerged manner after being secured with horizontal mattress sutures (Figs 1c and 1d). A postoperative periapical radiograph was taken to verify the socket fill.

Postsurgical instructions included antibiotics (amoxicillin, 500 mg tid for 7 days), salt-water rinses, and nonsteroidal anti-inflammatory drugs (ibuprofen, 400 mg qid or as needed). Patients were also instructed to defer from toothbrushing or any mechanical trauma in the area for 2 weeks. A postoperative evaluation was performed at 2 weeks to check for complications, including infection, wound dehiscence, and resorption. Membrane removal was performed at 4 weeks postsurgery.

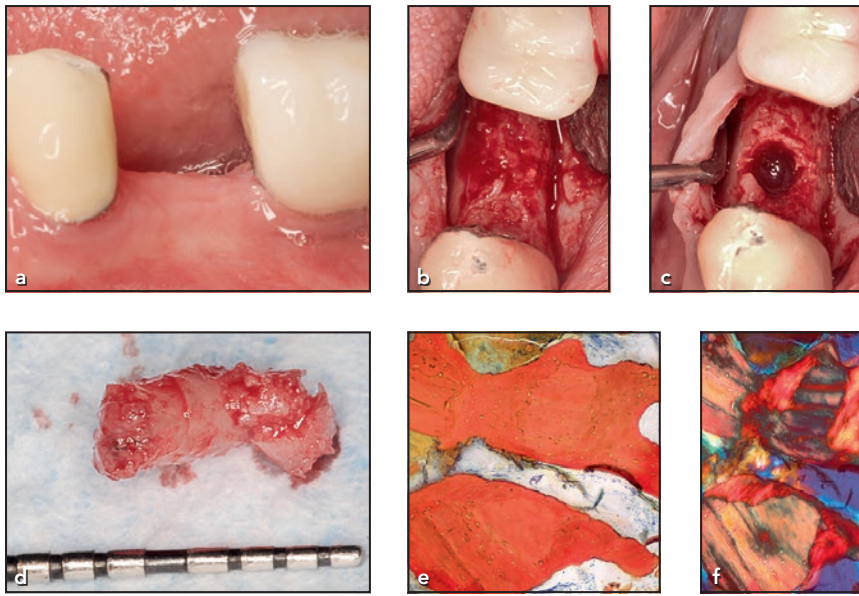
Surgical reentry was scheduled at varying postextraction time points, ranging from 2 to 7 months for implant placement. At the time

of implant placement, soft tissue healing was assessed and full-thickness envelope flaps were raised to provide direct access to the healed ridges. Clinical photographs of the grafted areas were obtained, and the osteotomies were initiated using a trephine drill modified protocol as previously described<sup>13</sup> to allow for harvesting of bone specimens from the implant sites. Subsequently, implants were placed at bone level and allowed to heal for 3 months in a submerged fashion prior to uncovering and restoration.

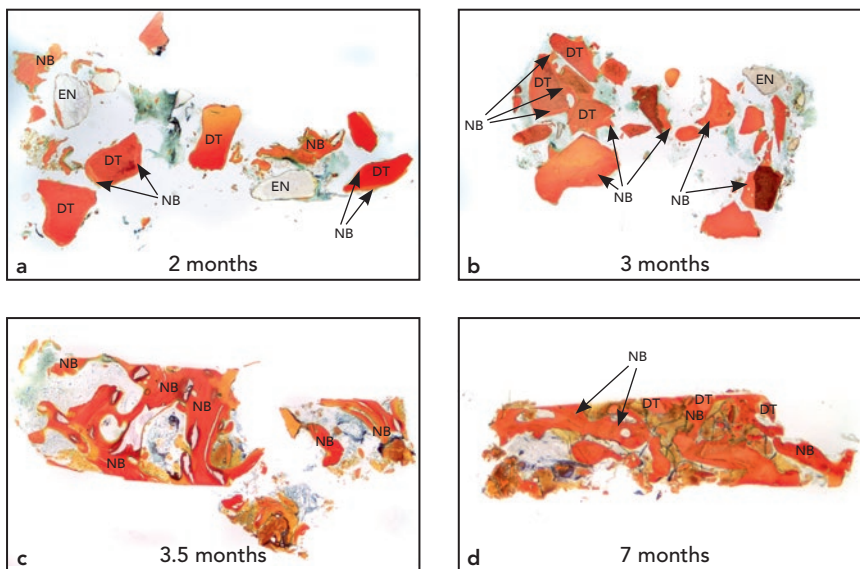
#### *Histologic Analysis*

Four cores were procured in conjunction with the scheduled implant procedures, processed, and analyzed histomorphometrically at the Hard Tissue Research laboratory, University of Minnesota in Minneapolis, Minnesota. The tissue-

processing protocol has been previously described.<sup>13</sup> Briefly, specimens were dehydrated with a graded series of alcohols for 9 days. Following dehydration, the specimens were infiltrated with a light-curing embedding resin, and after 20 days of infiltration, the specimens were embedded and polymerized at 450 nm and then cut and ground according to Rohrer and Schubert.<sup>14</sup> Specimens were cut to a thickness of 150  $\mu\text{m}$  and polished to a thickness of 45 to 65  $\mu\text{m}$  with a series of polishing sandpaper disks. The slides were stained with Stevenel blue and van Gieson picrofuchsin, and coverslips were placed on the slides for histologic analysis using Brightfield and polarized microscopy. Histomorphometric analysis was performed using ImageJ (National Institutes of Health), which recorded the percentage of new bone formation and percentage of remaining root fragments.



**Fig 2** Case 3. (a) Clinical view prior to implant surgery. Note that the site demonstrates good ridge dimensional stability with minimal recession on adjacent teeth. (b, c) Surgical reentry revealed a healed bone site with a consistency indiscernible from the adjacent native bone, and (d) a core was extracted. (e) Histologic analysis on the extracted core revealed newly formed vital bone in direct contact with few remaining dentin particles. (f) The polarized view shows the mature trabeculation of the newly formed bone.



**Fig 3** Bone core harvesting at different postextraction time points allows for insight in the dynamics of socket healing with autologous tooth structure grafting. Early samples show a large number of remaining dentin particles surrounded by immature woven bone, with some isles of bone bridging the particles as early as 3 months postextraction. Also note the inadvertently retained enamel remnants in the 2-month core. At 7 months, the low magnification view of the core reveals 85% new bone and 25% residual dentin. NB = new bone; DT = dentin; EN = enamel remnants.

## Results

Patients presented for the scheduled implant surgical procedures at 2 to 7 months postextraction. Clinically, grafted sites healed uneventfully and demonstrated limited ridge resorption, which allowed for subsequent implant placement without needing to use additional biomaterials. Four implants were placed in the mandible, all replacing nonmolar teeth. No major adverse events were recorded except for mild postoperative pain for the first few postextraction days, which was adequately controlled with over-the-counter analgesics in all cases.

The implants were fully stable and appeared osseointegrated at uncovering, resulting in a 100% osseointegration success rate. Clinically at reentry, the new bone could not be discerned from native bone and adjacent sites except for small areas where there were a few large particles of dentin (Fig 2). All implants placed achieved osseointegration and were successfully loaded and followed for at least 1 year postloading.

### Histologic Analysis

The cores were processed and analyzed as described in Materials and Methods, and visualization was performed via light and polarized microscopy. Representative microphotographs are depicted in Fig 3. Histologic analysis revealed that the grafted area was occupied by dentin particles that had begun to connect via bridges of woven bone

as early as 3 months posthealing. Qualitatively, the images revealed new bone surrounding the graft particles at all time points. As healing progressed, there was more vital bone throughout the core and more bridging of the graft particles. After 3.5 months of healing, the percent area of vital bone surpassed the area of residual tooth particles; a core retrieved at 7 months revealed 63% new vital bone, with vital osteocytes in the lacunae and signs of remodeling, that was densely packed around a small fraction of residual particles. The vital bone present was in direct contact with residual particles with no signs of inflammatory infiltrate supporting the osteoconductivity of autologous sterilized tooth structure.

## Discussion

The main findings of the present case series are that autologous tooth particles are osteoconductive and undergo a timely turnover with substitution by vital alveolar bone. This finding is corroborated by a previous report of the use of autologous particles<sup>10</sup> that supports their clinical application. Because tooth dentin and cortical bone have chemically similar minerals and organic and osteoinductive properties, dentin has a potential utility that could be superior to that of osteoconductive grafts. Specifically, dentin, cementum, and alveolar bone all are highly mineralized organic matrices. The core component of the organic matrix of dentin and bone is type I collagen, along with lesser fractions of other types of collagenous and

noncollagenous proteins, coexisting with signaling proteins that are important to bone remodeling, such as the dentin matrix's bone morphogenetic proteins.<sup>3</sup> Thus, the composition of the dentin matrix provides cues for not only osteoconductive properties as a biomaterial but also osteoinductive properties. This is further supported by findings of ectopic bone formation following dentin implantation in muscle pouches.<sup>6</sup> Importantly, prospective data from controlled studies are necessary to validate the theoretical advantage of autologous dentin grafts beyond those of existing proof-of-principle studies.

A tooth root has been previously utilized for guided bone regeneration by Schwarz et al.<sup>15</sup> Results from the use of an extracted root for alveolar ridge augmentation were comparable to the present findings of a homogeneous incorporation of the tooth structure with the resident bone tissue and clinically appropriate turnover of the mineralized tooth structure.<sup>15</sup> Further, when another study combined dentin with calcium sulfate to graft large jaw defects (> 20 mm), the radiographic changes were consistent with adequate mineralized tissue changes in the defect areas, while no graft-related adverse events were noted outside of the expected postsurgical sequella.<sup>16</sup> Despite being a low level of evidence, this data supports that the remodeling of mineralized dentin is compatible with the expectations of graft healing in implant dentistry, potentially even more than that of osteoconductive inorganic calcium salts.

In terms of the histologic appearance of the bone cores analyzed in the present study, a temporal association between dentin to bone contact and percent of new bone growth was noted, which highlights how bioinert dentin is. It is well established that during the remodeling phase of bone substitutes, the rate and time of substitution of scaffolds may influence its structural support for new mature and functional bone deposition.<sup>17</sup> The current case series is suggestive of favorable scaffolding properties of autologous dentin. Nonetheless, a more definitive answer is necessary via controlled comparative investigations against well-characterized bone-substitute biomaterials.

Importantly in the present study a confounder was present (ie, the use of PTFE barriers). It is well established that dense PTFE membranes offer good wound stability and facilitate bone turnover following non-submerged healing.<sup>18</sup> Therefore, the present article cannot definitively assess the performance of autologous tooth structure in extraction socket healing in the absence of a barrier membrane, such as in the context of the socket-plug technique.<sup>2,8</sup> A prospective controlled clinical trial with membrane use as a covariable is warranted.

## Conclusions

Clinically, using ground dentin as a graft material preserved alveolar volume in this human extraction-socket study. Histologically, the material was shown to perform better

than expected for osteoconductive biomaterials, with more vital bone formed at longer healing times. Upon reentry for implant placement, the grafted material was clinically indistinguishable from native bone. Autologous tooth-structure biomaterials appear to be clinically and biologically acceptable for preserving alveolar volume, forming vital bone, and supporting osseointegration.

## Acknowledgments

The authors declare no conflicts of interest.

## References

- Ashman A. Ridge preservation: Important buzzwords in dentistry. *Gen Dent* 2000;48:304–312.
- Kotsakis G, Chrepa V, Marcou N, Prasad H, Hinrichs J. Flapless alveolar ridge preservation utilizing the “socket-plug” technique: Clinical technique and review of the literature. *J Oral Implantol* 2014;40:690–698.
- Kim YK, Lee J, Um IW, et al. Tooth-derived bone graft material. *J Korean Assoc Oral Maxillofac Surg* 2013;39:103–111.
- Park SM, Kim DH, Pang EK. Bone formation of demineralized human dentin block graft with different demineralization time: In vitro and in vivo study. *J Craniomaxillofac Surg* 2017;45:903–912.
- Schwartz Z, Lohmann CH, Wieland M, et al. Osteoblast proliferation and differentiation on dentin slices are modulated by pretreatment of the surface with tetracycline or osteoclasts. *J Periodontol* 2000;71:586–597.
- Yeomans JD, Urist MR. Bone induction by decalcified dentine implanted into oral, osseous and muscle tissues. *Arch Oral Biol* 1967;12:999–1008.
- Huggins C, Wiseman S, Reddi AH. Transformation of fibroblasts by allogeneic and xenogeneic transplants of demineralized tooth and bone. *J Exp Med* 1970;132:1250–1258.
- Kotsakis GA, Salama M, Chrepa V, Hinrichs JE, Gaillard P. A randomized, blinded, controlled clinical study of particulate anorganic bovine bone mineral and calcium phosphosilicate putty bone substitutes for socket preservation. *Int J Oral Maxillofac Implants* 2014;29:141–151.
- Babbush CA, Kanawati A, Kotsakis GA, Hinrichs JE. Patient-related and financial outcomes analysis of conventional full-arch rehabilitation versus the All-on-4 concept: A cohort study. *Implant Dent* 2014;23:218–224.
- Binderman I, Hallel G, Nardy C, Yaffe A, Sapoznikov L. A novel procedure to process extracted teeth for immediate grafting of autogenous dentin. *J Interdiscipl Med Dent Sci* 2014;2:154.
- Bono N, Tarsini P, Candiani G. Demineralized dentin and enamel matrices as suitable substrates for bone regeneration. *J Appl Biomater Funct Mater* 2017;15:e236–e243.
- Jin SY, Kim SG, Oh JS, et al. Histomorphometric analysis of contaminated autogenous tooth graft materials after various sterilization. *Implant Dent* 2016;25:83–89.
- Kotsakis GA, Joachim FP, Saroff SA, Mahesh L, Prasad H, Rohrer MD. Histomorphometric evaluation of a calcium-phosphosilicate putty bone substitute in extraction sockets. *Int J Periodontics Restorative Dent* 2014;34:233–239.
- Rohrer MD, Schubert CC. The cutting-grinding technique for histologic preparation of undecalcified bone and bone-anchored implants. Improvements in instrumentation and procedures. *Oral Surg Oral Med Oral Pathol* 1992;74:73–78.
- Schwarz F, Schmucker A, Becker J. Initial case report of an extracted tooth root used for lateral alveolar ridge augmentation. *J Clin Periodontol* 2016;43:985–989.
- Kim SG, Yeo HH, Kim YK. Grafting of large defects of the jaws with a particulate dentin-plaster of paris combination. *Oral Surg Oral Med Oral Pathol Oral Radiol Endod* 1999;88:22–25.
- Wood RA, Mealey BL. Histologic comparison of healing after tooth extraction with ridge preservation using mineralized versus demineralized freeze-dried bone allograft. *J Periodontol* 2012;83:329–336.
- Hoffmann O, Bartee BK, Beaumont C, Kasaj A, Deli G, Zafropoulos GG. Alveolar bone preservation in extraction sockets using non-resorbable dPTFE membranes: A retrospective non-randomized study. *J Periodontol* 2008;79:1355–1369.