

May 2017 Pulmonary Case of the Month

Lewis J. Wesselius, MD
Robert W. Viggiano, MD

Department of Pulmonary Medicine
Mayo Clinic Arizona
Scottsdale, AZ USA

History of Present Illness

A 69-year-old man with known heart failure, COPD and prostate cancer with presented with increased shortness of breath. He denied any fever, chills, cough or sputum.

Past Medical History, Social History and Family History

- Diastolic heart failure with a preserved ejection fraction
- Prostate cancer with bone metastasis treated with leuprolide (Lupron®)
- COPD treated with salmeterol/fluticasone and tiotropium
- He is married, retired and had quit smoking a number of years ago.
- Family history was unremarkable

Physical Examination

- Oxygen saturation (SpO₂) was 93% on room air.
- Physical examination showed jugular venous distention (JVD), bilateral lung rales a laterally displaced pulse of maximal impulse (PMI) and 1+ pretibial edema.

Radiography

A chest x-ray was performed (Figure 1).

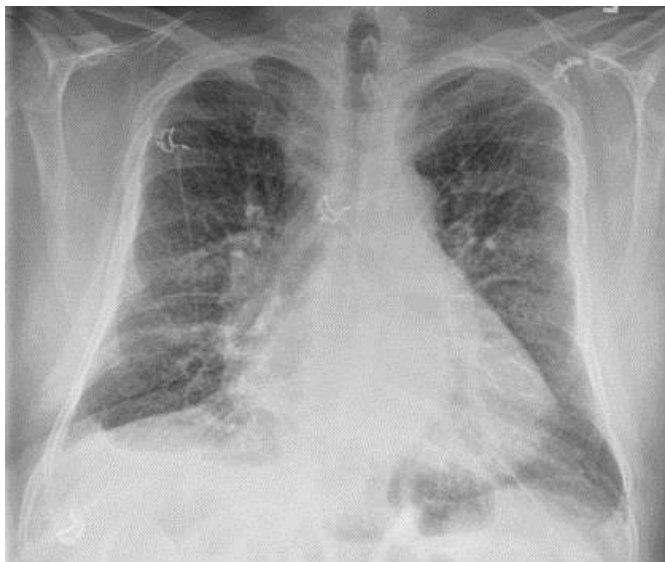

Figure 1. Admission chest x-ray.

Based on the history and chest x-ray which of the following is the **most likely diagnosis?**

1. Community-acquired pneumonia
2. Congestive heart failure
3. COPD exacerbation
4. Metastatic prostate cancer
5. Pulmonary embolism

Correct!
2. Congestive heart failure

The physical findings are suggestive of congestive heart failure. The chest radiograph shows cardiomegaly and small bilateral pleural effusions, increased reticular interstitial markings, and prominent perihilar vasculature suggestive of pulmonary edema. He was treated with furosemide and clinically improved. He was discharged after 1 day in the hospital.

He was subsequently started on enzalutamide, an antiandrogen, for his progressing prostate cancer due to increased bone metastases. Three months later his prostate specific antigen had increased to 639 ng/mL and he was started on carboplatin.

Approximately 4 months after his first hospitalization, he was admitted again to the hospital due to increasing dyspnea. Oxygen saturation was 93% on 3 lpm by nasal cannula. There was no JVD but chest exam again revealed scattered crackles. There was 1+ pretibial ankle edema.

A chest radiograph was again performed (Figure 2).

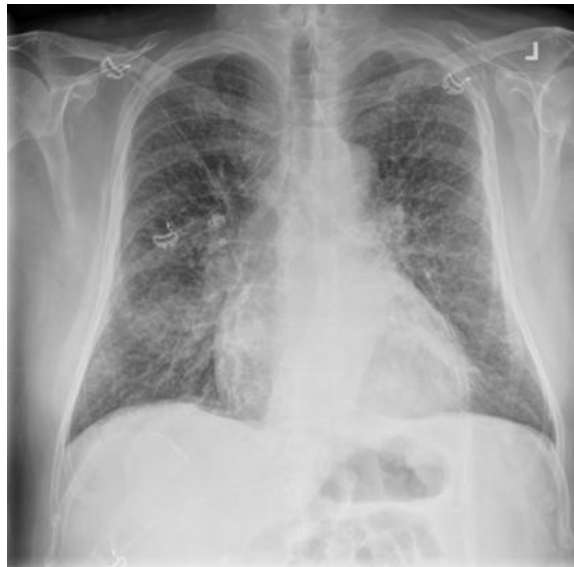

Figure 2. Chest x-ray from second admission.

Which of the following is the **most appropriate therapy**?

1. Broad-spectrum antibiotics for community-acquired pneumonia
2. Bronchodilators for an exacerbation of COPD
3. Cabazitaxel for metastatic prostate cancer
4. Diuresis for congestive heart failure
5. Increase oxygen to 15 lpm

Correct!

4. Diuresis for congestive heart failure

The patient's physical examination and chest x-ray are much the same as they did on his first admission although the interstitial markings are more prominent. His presentation and chest x-ray do not suggest pneumonia or an exacerbation of his COPD. His prostate cancer appears to be progressing but metastatic prostate cancer to the lungs is rare. His SpO₂ is adequate and increasing his oxygen administration is unlikely to be beneficial.

Furosemide was again administered but three days later the patient was not clinically changed.

Which of the following is **appropriate**?

1. Repeat his PSA
2. Switch diuretics to bumetanide
3. Thoracic CT scan
4. 1 and 3
5. All of the above

Correct!
3. Thoracic CT scan

His course is not as expected. Usually pulmonary edema responds well to diuresis and it seems unlikely that switching diuretics would be helpful. Repeating his PSA would probably also not be helpful since it is known to be quite high. A thoracic CT scan was performed (Figure 3).

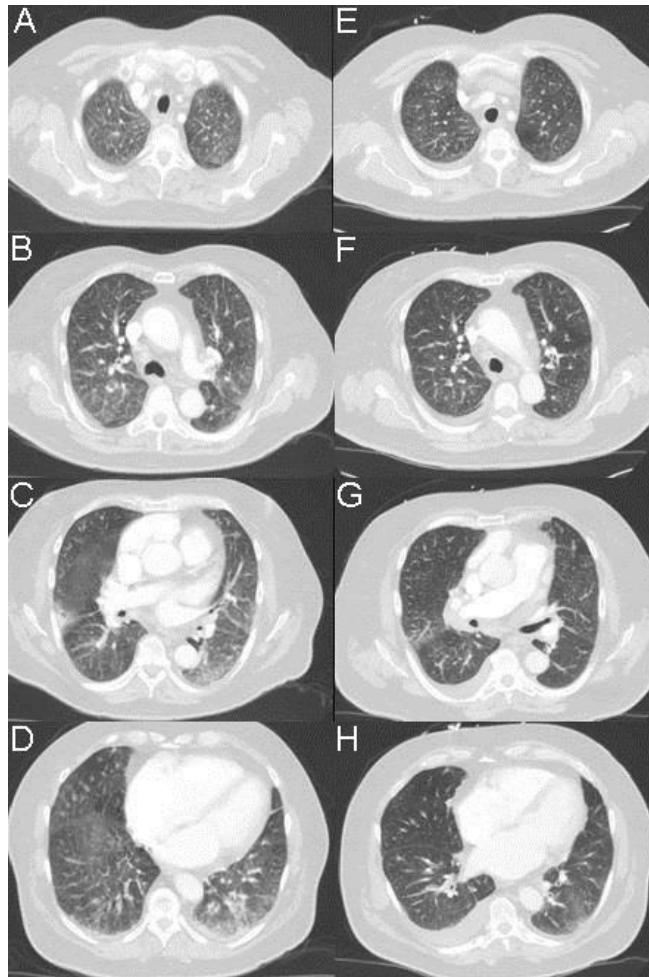


Figure 3. A-D: Thoracic CT scan with contrast from present admission. E-H: Thoracic CT from admission 4 months earlier for comparison.

Which of the following are **true** regarding the CT scans?

1. The interstitial prominence has increased
2. There are multiple pulmonary emboli
3. The pleural effusions have decreased in size
4. 1 and 3
5. All of the above

Correct!
4. 1 and 3

The interstitial prominence is increased and seems more nodular. The small pleural effusions have decreased in size. There are no intraluminal filling defects or vessel cutoffs suggestive of pulmonary emboli. In addition, the soft tissue views showed prominent lymph nodes in the 4R position (Figure 4).

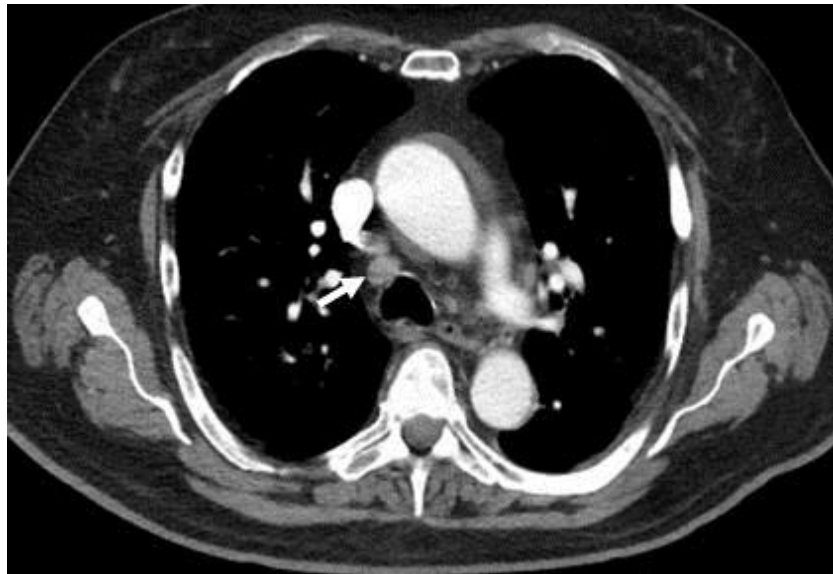

Figure 4. Thoracic CT in soft tissue windows showing lymph node at 4R (arrow).

What should be **done next?**

1. ^{18}F -FDG PET-CT scan
2. Bronchoscopy with endobronchial ultrasound (EBUS)
3. Mediastinoscopy
4. Needle biopsy of the mediastinal lymph nodes
5. Video-assisted thorascopic surgery

Correct!

2. Bronchoscopy with endobronchial ultrasound (EBUS)

At this juncture, the patient's lack of clinical improvement, his progression on CT scan and the development of enlarged mediastinal lymph nodes suggest tissue biopsy is warranted. Of the choices listed, bronchoscopy with biopsy of the mediastinal lymph nodes is least invasive and probably the best choice although none are necessarily wrong. It is unclear if knowing there is increased glucose uptake in the mediastinal lymph nodes ¹⁸F-FDG PET-CT scan would be helpful, VATS is invasive, and needle biopsy would only sample the lymph nodes.

Bronchoscopy with bronchoalveolar lavage and EBUS were performed. BAL fluid recovered from both lower lobes also was positive for metastatic prostate cancer indicating lymphangitic spread into the lungs. Lymph nodes at station 4R, 7 and 10R were positive for metastatic prostate cancer.

Lymphangitic carcinomatosis is defined as presence of tumor present in the lymphatic vessels of bronchovascular bundles, interlobular septa and pleura (1). It is most commonly seen with breast, lung, colon and stomach cancer but has been rarely reported with prostate cancer (2). Chest radiograph is not very sensitive and 25% of patients with biopsy-proven lymphangitic carcinomatosis may have normal chest radiographs (1). Findings are usually of a reticulonodular pattern with thickening of interlobular septa which may resemble Kerley B lines. On CT scan the typical appearance is interlobular septal thickening which may either be smooth or nodular. Hilar and mediastinal lymph node enlargement is seen in 40 to 50%. Bronchoalveolar lavage has been reported to have a high diagnostic yield in lymphangitic carcinomatosis (3).

References

1. Khan AN. Lymphangitic carcinomatosis imaging. Medscape. May 6, 2015. Available at: <http://emedicine.medscape.com/article/359006-overview> (accessed 4/28/17).
2. Fabozzi SJ, Schellhammer PF, el-Mahdi AM. Pulmonary metastases from prostate cancer. Cancer. 1995 Jun 1;75(11):2706-9. [\[CrossRef\]](#) [\[PubMed\]](#)
3. Linder J, Radio SJ, Robbins RA, Ghafouri M, Rennard SI. Bronchoalveolar lavage in the cytologic diagnosis of carcinoma of the lung. Acta Cytol. 1987 Nov-Dec;31(6):796-801. [\[PubMed\]](#)