

Medical Image of the Week: Iatrogenic Pneumothorax

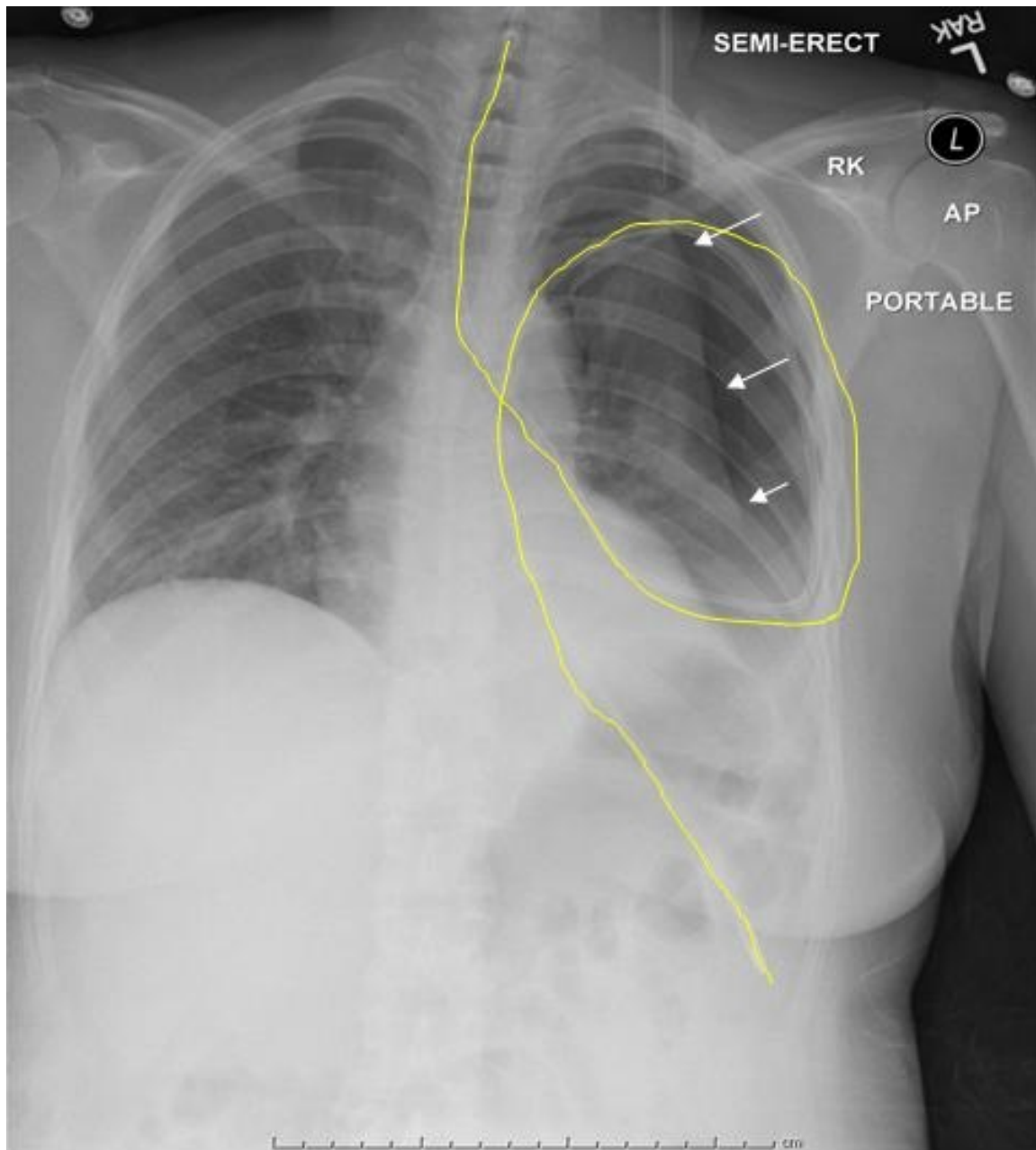


Figure 1: AP Chest X Ray showing an unfortunate placement of a feeding tube (yellow tracing) as it passes through the left mainstem bronchus and loops into the left pleural space causing a moderate size pneumothorax (arrows).

Aarthi Ganesh, MD; Ryan Nahapetian, MD; Prathima Guruguri, MD, and Carmen Luraschi-Monjagatta, MD
Department of Medicine
University of Arizona, South Campus
Tucson, Arizona