

November 2013 Pulmonary Case of the Month: Dalmatian Lungs

Lewis J. Wesselius, MD

Department of Pulmonary Medicine
Mayo Clinic Arizona
Scottsdale, AZ

History of Present Illness

A 36 year old woman was referred to the pulmonary clinic at Mayo Clinic Arizona. In early May 2013 she developed headache and blurred vision. She was referred to a neuroophthalmologist who diagnosed a 6th cranial nerve palsy. She had a brain MRI and lumbar puncture (LP). Both were reported as normal. She was treated with corticosteroids and improved.

She was tapered off prednisone in late May and developed discomfort in her left ear with hearing loss and tinnitus. Some left facial asymmetry was noted. She was treated with intra-tympanic steroid injections as well as oral steroids with some improvement. Her last dose of corticosteroids was 3 weeks prior to being seen.

At the beginning of August she developed speech and swallowing difficulties and was neurologically diagnosed with palsies in 4th, 6th, 8th, 9th, 10th and 11th cranial nerves. Other symptoms included photophobia and a non-productive cough. Two additional LPs were reported to be normal.

PMH, SH, FH

She had cervical cancer with a cone biopsy 2006 and right arthroscopic shoulder surgery. She is a nonsmoker who is a field engineer for a medical device company. She travels throughout the US extensively. There is no significant family history.

Medications

- Zolpidem
- Vitamin B and D
- Herbal remedy immunotox

Physical Examination

On neurologic exam she had blurred vision with left gaze and facial asymmetry. Otherwise, the physical exam was unremarkable.

Laboratory

Her complete blood count (CBC) and erythrocyte sedimentation rate (ESR) were within normal limits.

At this point which of the following are **diagnostic tests that should be ordered?**

1. Anti-neutrophil cytoplasmic antibody (ANCA)
2. Coccidiomycosis serology
3. Lyme disease serology
4. Serum angiotensin converting enzyme (ACE)
5. All of the above

Correct!
5. All of the above

At this stage the cause of her neurologic findings is unclear.

The following additional laboratory tests were ordered:

- ANA, ANCA and Lyme serology were all negative
- Serum ACE was within normal limits.
- VDRL was nonreactive.
- Chest x-ray was interpreted as normal.

Based on these findings which of the following are **reasonable differential diagnosis** possibilities?

1. Idiopathic hypertrophic pachymeningitis
2. Sarcoidosis
3. Wegener's granulomatosis (granulomatosis with polyangiitis, GPA)
4. 1 and 3
5. All of the above

Correct!
5. All of the above

Idiopathic hypertrophic pachymeningitis is an uncommon disorder that causes a localized or diffuse thickening of the dura mater (1). The disease can produce a spectrum of neurologic symptoms depending on the anatomic location of the affected dura. It can be idiopathic but has been associated with rheumatoid arthritis, syphilis, Wegener's granulomatosis, tuberculosis, and cancer.

The negative ANCA and the normal serum ACE make GPA and sarcoidosis less likely but neither excludes these diagnoses.

What should be **done next** in her diagnostic work up?

1. Chest CT scan
2. Repeat LP
3. Repeat MRI
4. 1 and 3
5. All of the above

Correct!
All of the above

At this point she has definite neurologic symptoms and physical findings with a negative neurologic radiographic and laboratory workup. The MRI was repeated and showed “progressive pachymeningeal and leptomenigeal inflammatory process - left side dominant”. A repeat LP had findings as below:

- Normal opening pressure
- Clear fluid
- Glucose-within normal limits
- Protein-within normal limits
- Cell count 4-WBCs/mm³
- Lyme PCR-negative
- HSV-negative
- ACE-normal

Thoracic chest CT is below (Figure 1).

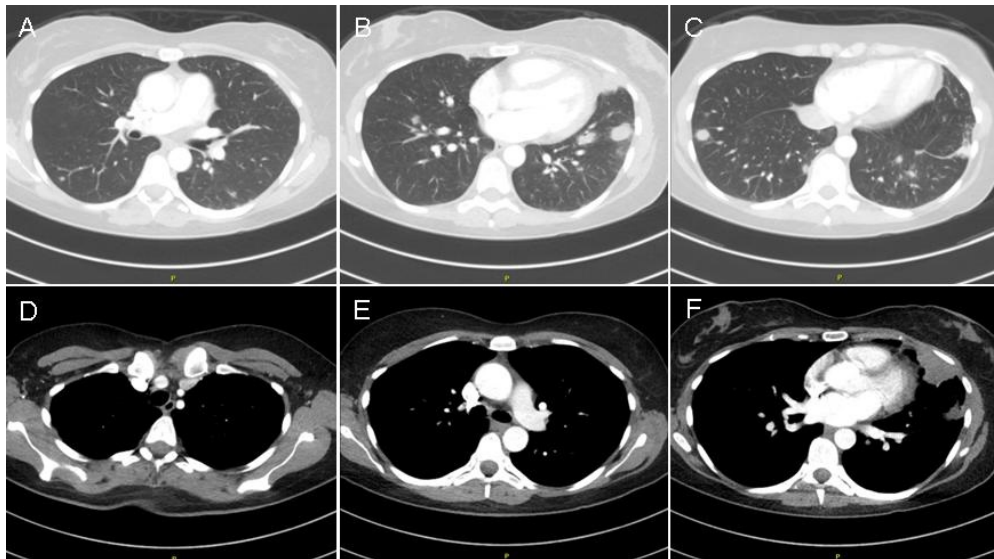


Figure 1. Representative images from the thoracic CT scan lung windows (A-C) and mediastinal windows (D-F).

Which of the following **best describe(s) the CT scan?**

1. No enlarged mediastinal lymph nodes
2. Normal lungs
3. Small pulmonary nodules predominately in the lower lobes
4. Subcarinal mediastinal lymphadenopathy
5. 1 and 3
6. 2 and 4

Correct!
5. 1 and 3

The chest CT scan shows a number of small lung nodules predominately in the lower lobes (Figure 2).

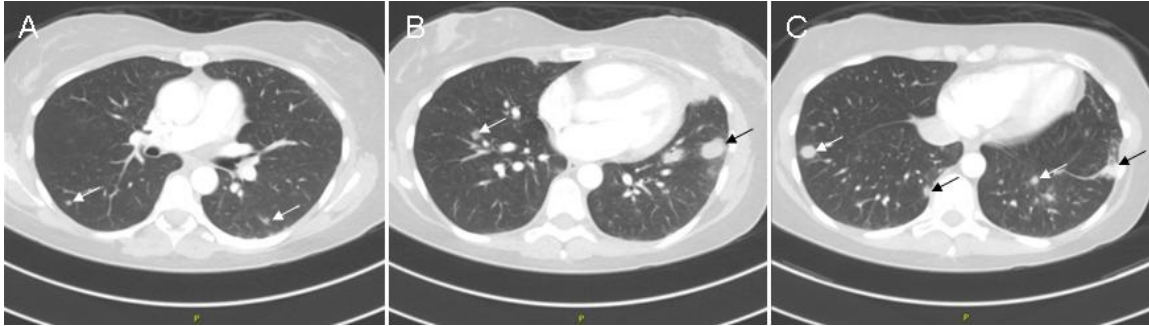


Figure 2. Thoracic CT scan lung windows from figure 1 showing multiple lung nodules (arrows). The mediastinal windows do not show any mediastinal lymphadenopathy.

What is the **best choice** as the next diagnostic step?

1. Bronchoscopy with bronchoalveolar lavage
2. Bronchoscopy with transbronchial biopsy
3. Needle biopsy of the nodules
4. Serial thoracic CT scans with biopsy of any enlarging nodules
5. Video-assisted thorascopic biopsy

Correct!

2. Bronchoscopy with transbronchial biopsy

None of the choices other than following the thoracic CT are wrong. However, in my view the best choice in this situation is bronchoscopy with transbronchial biopsy. Although it has lower yield than needle biopsy or VATS, it has a lower complication rate and has the added advantage of visualizing the airways (2). Bronchoscopy with transbronchial biopsies was performed (Figure 3).

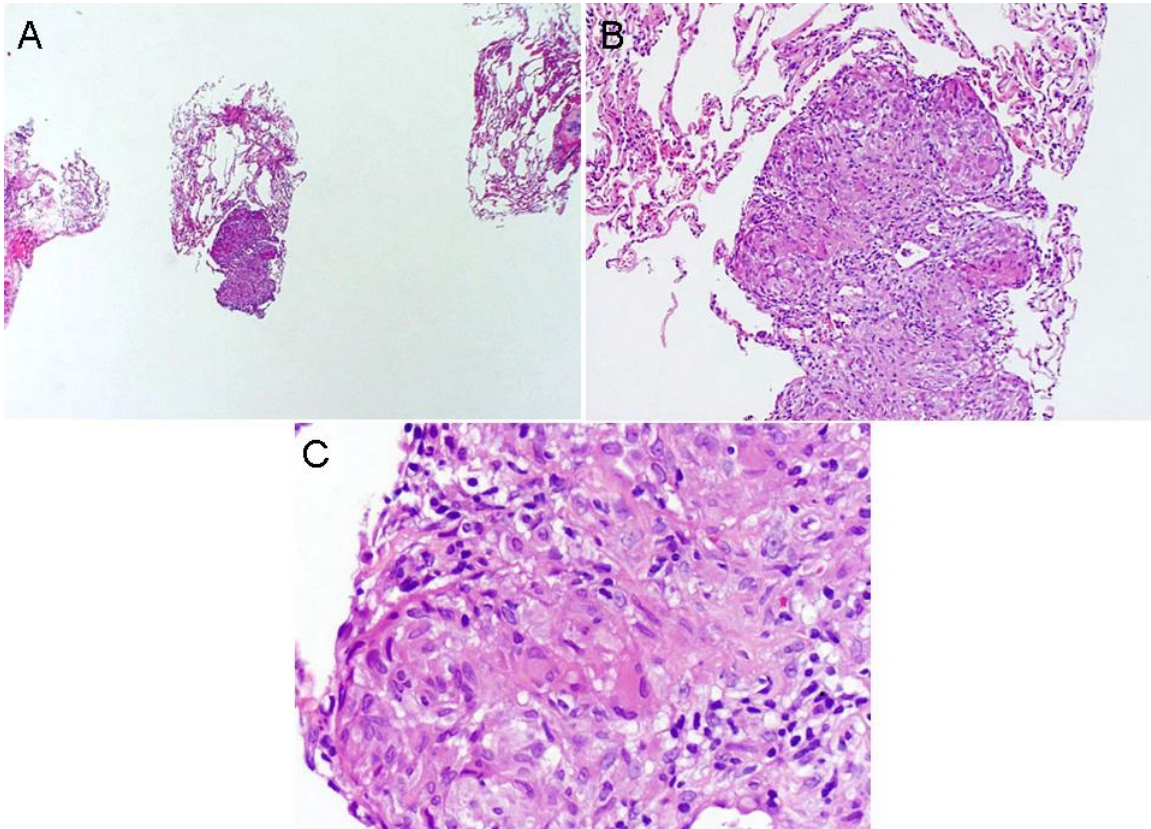


Figure 3. H&E staining of the low (Panel A), intermediate (Panel B) and high power (Panel C) of the transbronchial lung biopsies.

What is the ***likely diagnosis?***

1. Granulomatosis with polyangitis (GPA)
2. Metastatic breast cancer
3. Sarcoidosis
4. Tuberculosis
5. Valley fever

Correct!
3. Sarcoidosis

The biopsy shows normal lung with a nodule consisting of a granuloma without necrosis. The lung presentation and the biopsy are characteristic of nodular sarcoidosis (3).

Nodular sarcoidosis is an uncommon presentation of the disease. Malaisamy et al. (4) reported 33 cases of nodular sarcoidosis. The patients were predominantly young (mean age 35), female (28/33), and all were African-American. Extrapulmonary involvement was seen in 14 (liver 6, skin 5, eyes 5, heart 1, other 4). Mediastinal adenopathy was present in 30/33, upper lobe involvement 27, pleural-based masses 20, and pleural effusion in 11. Corticosteroid treatment was given in 27 cases with good radiologic response in 19. Only one case progressed to pulmonary fibrosis.

Symptomatic neurosarcoidosis occurs in perhaps 5% of sarcoidosis patients (5). Imaging (MRI) abnormalities are reported in 10%. Neurologic symptoms are the initial clinical manifestation in 50 to 70% of cases of neurosarcoidosis. Cranial neuropathies are the most common manifestation of neurosarcoidosis, typically a facial nerve palsy. Isolated cranial neuropathies typically resolve. Multiple neuropathies typically have a chronic course

This patient was treated with corticosteroids and had an excellent response with resolution of her symptoms.

References

1. Kupersmith MJ, Martin V, Heller G, Shah A, Mitnick HJ. Idiopathic hypertrophic pachymeningitis. *Neurology*. 2004;62(5):686-94. [\[CrossRef\]](#) [\[PubMed\]](#)
2. Soubani AO. The evaluation and management of the solitary pulmonary nodule. *Postgrad Med J*. 2008;84(995):459-66. [\[CrossRef\]](#) [\[PubMed\]](#)
3. McCullough PC, McCullough AE. Images in clinical medicine. Nodular sarcoidosis. *N Engl J Med*. 2002;346(25):1970. [\[CrossRef\]](#) [\[PubMed\]](#)
4. Malaisamy S, Dalal B, Bimenyuy C, Soubani AO. The clinical and radiologic features of nodular pulmonary sarcoidosis. *Lung*. 2009;187(1):9-15. [\[CrossRef\]](#) [\[PubMed\]](#)
5. Vargas DL, Stern BJ. Neurosarcoidosis: diagnosis and management. *Semin Respir Crit Care Med*. 2010;31(4):419-27. [\[CrossRef\]](#) [\[PubMed\]](#)