

biJanuary 2017 Imaging Case of the Month

Michael B. Gotway, MD

Department of Radiology
Mayo Clinic Arizona
Scottsdale, Arizona USA

Clinical History: A 35-year-old woman presented with complaints of increasing shortness of breath and a non-productive cough. She had no significant past medical history.

Laboratory data, including a white blood cell count, coagulation profile, and serum chemistries, were within normal limits. Oxygen saturation on room air was normal.

Frontal and lateral chest radiographs (Figure 1) were performed.

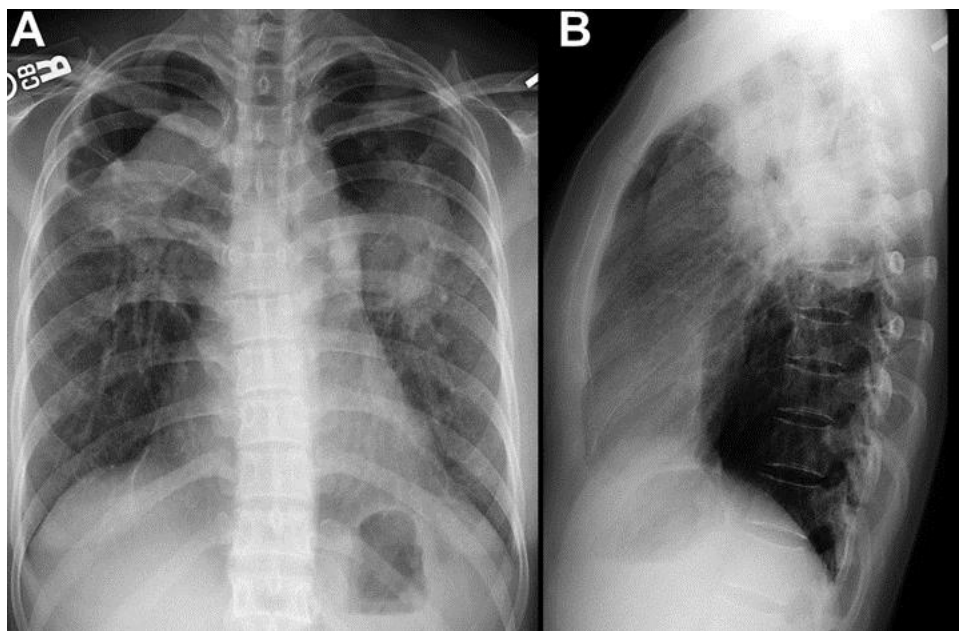


Figure 1. Frontal (A) and lateral (B) chest radiography.

Which of the following statements regarding the chest radiograph is **most accurate**?

1. Frontal and lateral chest radiography shows abnormal mediastinal contours
2. Frontal and lateral chest radiography shows basal reticulation suggesting possible fibrotic disease
3. Frontal and lateral chest radiography shows multifocal pleural thickening
4. Frontal and lateral chest radiography shows numerous small nodules
5. Frontal and lateral chest radiography shows upper lobe, bilateral perihilar masses

Correct!

5. Frontal and lateral chest radiography shows upper lobe, bilateral perihilar masses

Frontal and lateral chest radiograph shows bilateral upper lobe masses in proximity to the hila. Right hilar retraction is present. The visible mediastinal contours and pleural surfaces appear normal. There is no evidence of fibrotic lung disease. There is no clear evidence of small nodules on the chest radiograph.

Which of the following would be **most useful** for the evaluation of this patient?

1. ^{18}F FDG-PET scanning
2. Contrast-enhanced thoracic CT
3. Pulmonary function testing
4. Repeat frontal chest radiography
5. Video-assisted thoracoscopic biopsy

Correct!

2. Contrast-enhanced thoracic CT

Repeat frontal chest radiography is not likely to be beneficial as the abnormality detected at presentation chest radiography is unlikely to be artefactual and the chest radiographic abnormalities are substantial and merit immediate investigation. Pulmonary function testing could prove useful for physiologic assessment, but it is unlikely that pulmonary function testing would provide information that would provide an explanation for the marked abnormalities seen at chest radiography. Video-assisted thoracoscopic surgical lung biopsy certainly could provide a diagnosis, but invasive diagnostic procedures are premature at this point- further non-invasive techniques could yield important information that may change the diagnostic approach. ^{18}F FDG-PET scanning could also prove useful for further investigation, but generally this examination delivers a higher radiation exposure than thoracic CT, and the demonstration of metabolic activity, or the lack thereof, would not preclude the need for further investigation of the patient's clinical complaints and chest radiographic findings. In general, ^{18}F FDG-PET scanning is more rewarding when the need for the examination is more clearly defined through previous non-invasive imaging examinations and clarification of the clinical context. Thoracic CT, preferably performed with intravenous iodinated contrast, would be the most useful procedure to provide information regarding the etiology of the chest radiographic findings.

The patient underwent enhanced CT of the thorax (Figure 2).

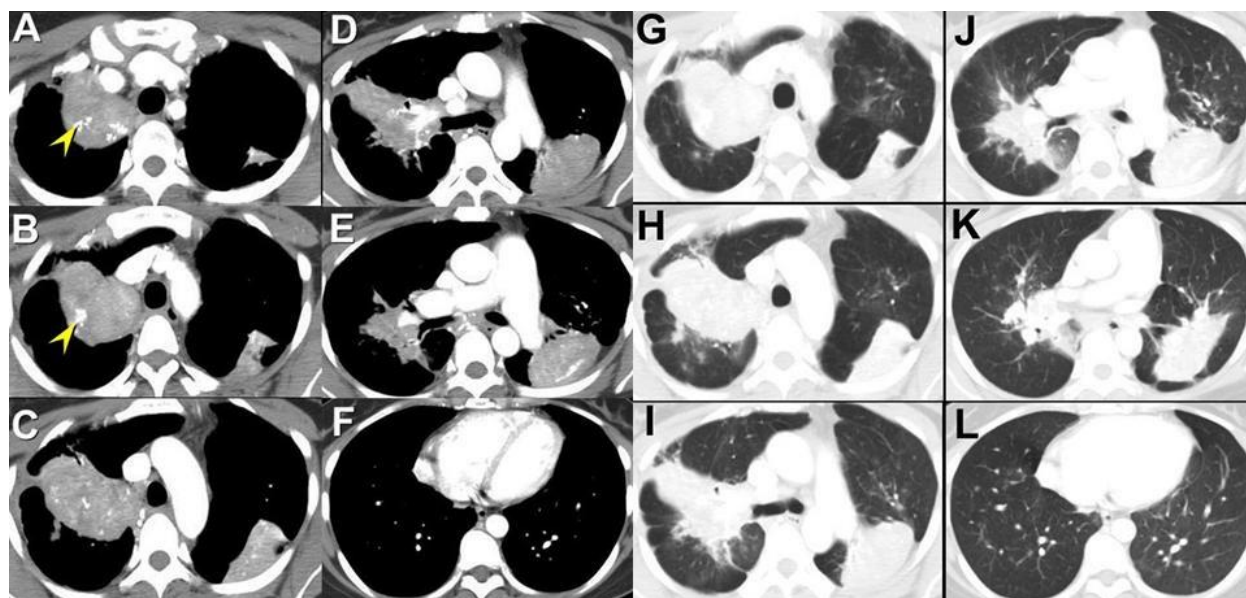


Figure 2. Representative images from axial enhanced thoracic CT displayed in soft tissue (A-F) and lung (G-L) windows.

Which of the following is **correct** regarding the description of the thoracic CT findings?

1. CT shows mediastinal lymph node enlargement
2. CT shows multilobulated pleural thickening and masses
3. CT shows multiple bilateral, randomly distributed pulmonary nodules
4. CT shows multiple osseous lesions
5. CT shows solid, partially calcified upper lobe masses bilaterally

Correct!

5. CT shows solid, partially calcified upper lobe masses bilaterally

Enhanced thoracic CT shows bilateral, upper lobe, partially calcified masses, correlating with the chest radiographic findings. The pleural surfaces are largely normal- some trace finely lobulated right upper lateral pleural thickening may be present. No mediastinal lymph node enlargement is clearly seen (although right peribronchial lymph node enlargement is present). The visualized bones appear normal- no lytic or destructive processes are evident. Several small nodules are present in proximity to the upper lobe masses, but multiple, bilateral, randomly distributed nodules are not present.

Which of the following differential diagnostic considerations is **least appropriate** for the imaging findings in this patient?

1. Fungal infection
2. Lipoid pneumonia
3. Metastatic disease
4. Occupational lung disease / environmental exposure
5. Sarcoidosis

Correct!

2. Lipoid pneumonia

The *least* likely etiology for the observed radiographic findings among those listed is lipoid pneumonia. Lipoid pneumonia can certainly present as a focal opacity, even mass-like; this manifestation has sometimes been referred to as “paraffinoma”. Typically, however, lipoid pneumonia may show areas of low attenuation, representing fat, and, more importantly in this case, lipoid pneumonia typically does not calcify. Sarcoidosis can present in a fashion similar to what is seen in this patient, causing upper lobe predominant masses resembling “progressive massive fibrosis.” Furthermore, sarcoidosis often causes calcification. Fungal infections could rarely present in this fashion as well. Although uncommon, metastatic lesions in the thorax could cause large masses that calcify- this is particularly true of osteosarcoma and chondrosarcoma (technically ossification in the former case). Occupational lung diseases and environmental exposures, particularly complicated chronic silicosis, can present with upper lobe masses with calcification.

Which of the following would be **most useful** for further evaluation of this patient?

1. Chamberlain procedure
2. Flexible fiberoptic bronchoscopy
3. Mediastinoscopy
4. Upper endoscopy
5. Video-assisted thoracoscopic surgical lung biopsy

Correct!

2. Flexible fiberoptic bronchoscopy

Mediastinoscopy is useful for assessing lesions found in particular mediastinal locations, typically the right paratracheal and anterior subcarinal spaces; such lesions are frequently due to lymphadenopathy. This patient, however, does not clearly have abnormally enlarged mediastinal lymph nodes accessible with either cervical mediastinoscopy or the Chamberlain procedure (a left anterior mediastinotomy). Similarly, esophageal endoscopic ultrasound is an excellent tool for visualizing and possibly biopsying lesions in close proximity to the esophagus, such as lymph nodes or masses in the left paratracheal space (2L and 4L), subcarinal space (station 7), periesophageal spaces (station 8), and aorto-pulmonary window (station 5), but no lesions amenable to this technique are present in this patient. Video-assisted thoracoscopic surgical lung biopsy could obtain a diagnosis for this patient, but is more invasive than flexible fiberoptic bronchoscopic biopsy, and the latter stands a good chance of obtaining tissue that could establish a diagnosis for this patient. Therefore, video-assisted thoracoscopic lung biopsy may be pursued if flexible fiberoptic bronchoscopy fails to obtain a diagnosis.

The patient underwent flexible fiberoptic bronchoscopy with biopsy. The tissue obtained showed peribronchial and perivascular dust-filled macrophages with foreign body granulomas. Birefringent particulate matter was seen on polarized light microscopy (Figure 3), consistent with talc particles.

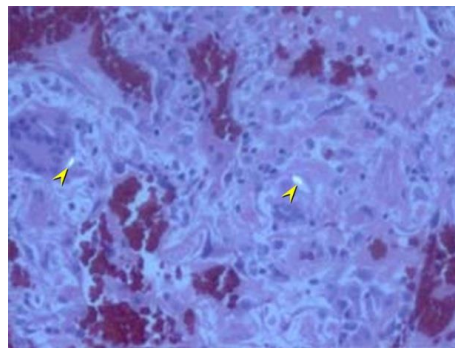


Figure 3. Polarized light microscopy of the tissue obtained at flexible fiberoptic bronchoscopy shows particulate matter demonstrating birefringence (arrowheads), representing talc particles.

Based on this information, which of the following would be **most useful** for establishing a diagnosis for this patient?

1. ^{18}F FDG-PET scan
2. $^{99\text{m}}\text{Tc}$ -Methylene diphosphonate bone scan
3. Obtain a detailed occupational / exposure history
4. Percutaneous transthoracic core biopsy of one of the upper lobe masses
5. Pulmonary function testing

Correct!

3. Obtain a detailed occupational / exposure history

^{99m}Tc-Methylene diphosphonate bone scan would not provide information that would clearly establish a diagnosis for this patient. It is possible that the upper lobe masses could show tracer accumulation on bone scan, but this finding is ultimately non-specific. ¹⁸FDG-PET scanning would not provide information that would help establish a diagnosis for this patient, regardless of whether the pulmonary opacities show increased, or lack of, tracer utilization. While pulmonary function testing would provide useful data, the results of this testing would not provide a diagnosis for this patient; rather, the data from pulmonary function testing in this patient would be useful more for following her disease once a diagnosis is established. Percutaneous transthoracic core biopsy of the lesion is unnecessary. While this procedure would undoubtedly provide more tissue for diagnostic evaluation, and the sample obtained with this procedure is typically larger than that obtained with bronchoscopic biopsy, tissue sufficient for diagnosis has already been obtained at bronchoscopy- the question now is, “what is the cause of the peribronchial and perivascular dust-filled macrophages with foreign body granulomas and talc particles found at bronchoscopic biopsy?”

A detailed occupational and environmental exposure history was performed. The patient worked in a bicycle shop, and had held this job for a number of years. No exposures in her home were found, and no hobbies or pastimes that could potentially be associated with an exposure or inhalational disorder were elicited. Further investigation into the patient's duties at the bicycle shop found that she placed rubber inner-tubes within tires. During this process, a powder containing a substantial amount of talc, used to reduce friction, was employed by the patient, and it was not uncommon that the patient was immersed in a cloud of this powder during the course of her duties at work.

Diagnosis: Complicated chronic silicatosi

References

1. Blum T, Kollmeier J, Ott S, Serke M, Schönfeld N, Bauer T. Computed tomography for diagnosis and grading of dust-induced occupational lung disease. *Curr Opin Pulm Med*. 2008 Mar;14(2):135-40. [\[CrossRef\]](#) [\[PubMed\]](#)
2. Cox CW, Rose CS, Lynch DA. State of the art: Imaging of occupational lung disease. *Radiology*. 2014 Mar;270(3):681-96. [\[CrossRef\]](#) [\[PubMed\]](#)
3. Cox CW, Lynch DA. Medical imaging in occupational and environmental lung disease. *Curr Opin Pulm Med*. 2015 Mar;21(2):163-70. [\[CrossRef\]](#) [\[PubMed\]](#)
4. Sirajuddin A, Kanne JP. Occupational lung disease. *J Thorac Imaging*. 2009 Nov;24(4):310-20. [\[CrossRef\]](#) [\[PubMed\]](#)