

February 2017 Imaging Case of the Month

Michael B. Gotway, MD

Department of Radiology
Mayo Clinic Arizona
Scottsdale, Arizona USA

Clinical History: A 49-year-old man presented with complaint of slow worsening of shortness of breath over a period of several months. He was otherwise healthy with no significant past medical history.

Laboratory data, include white blood cell count, coagulation profile, and serum chemistries were within normal limits. Oxygen saturation on room air was 94%.

Frontal and lateral chest radiographs (Figure 1) were performed.

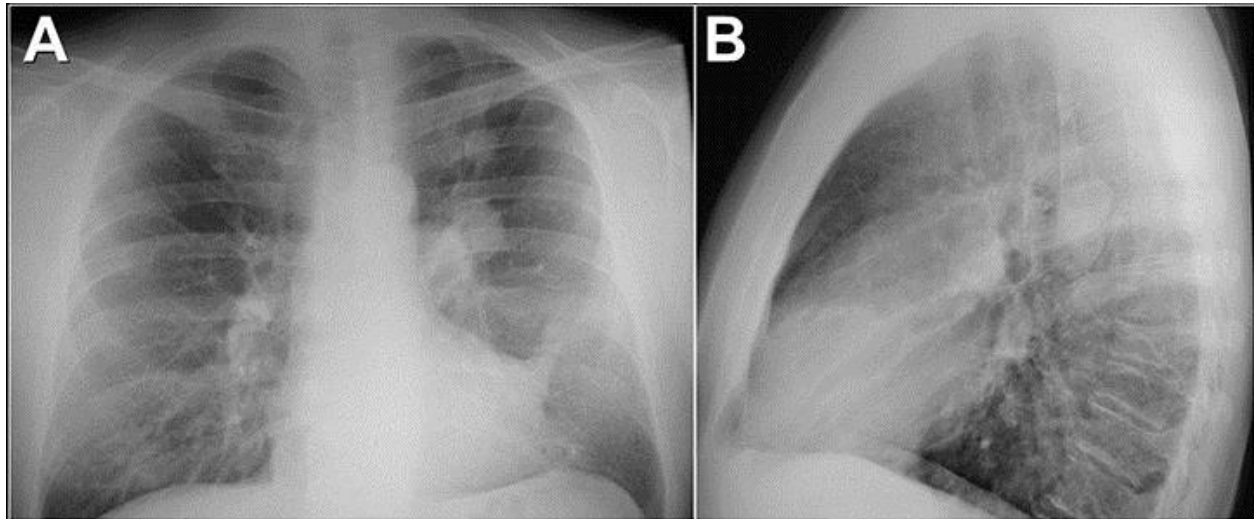


Figure 1. Frontal (A) and lateral (B) chest radiography.

Which of the following statements regarding the chest radiograph is **most accurate**?

1. Frontal and lateral chest radiography shows a right paratracheal mass
2. Frontal and lateral chest radiography shows basal reticulation suggesting possible fibrotic disease
3. Frontal and lateral chest radiography shows left-sided lung nodules
4. Frontal and lateral chest radiography shows lobulated left-sided pleural disease
5. Frontal and lateral chest radiography shows numerous small nodules

Correct!

3. Frontal and lateral chest radiography shows left-sided lung nodules

The frontal and lateral chest radiograph shows two left-sided nodules, one in the left perihilar region, the other slightly more cranially located, projecting over the left suprahilar region. No clear pleural disease is present and the right paratracheal “stripe” appears normal. Numerous small nodules are not evident. Scarring in the lingula, manifesting as a triangular-shaped opacity obscuring a portion of the left cardiac border, is present, but there is no evidence of basal fibrotic lung disease. The left hilum does appear enlarged.

Which of the following would be **most useful** for the evaluation of this patient?

1. ^{18}F FDG-PET scanning
2. Comparison to prior chest radiographs
3. Pulmonary function testing
4. Repeat frontal chest radiography
5. Video-assisted thoracoscopic biopsy

Correct!

2. Comparison to prior chest radiographs

The initial approach to the abnormal chest radiograph nearly always is comparison to prior images. When an abnormality is found on a chest radiograph, if that abnormality can be shown to be stable for a significant length of time, the potential cost and morbidity associated with more advanced evaluation may be obviated entirely or at least directed in a more focused fashion. In this case, repeating the chest radiograph is unlikely to be of benefit as the findings are not artifactual in nature. Pulmonary function testing would provide useful information, but is unlikely to provide data that would directly assist in the management of indeterminate pulmonary nodules. ¹⁸FDG-PET scanning would provide useful data for indeterminate nodules detected at chest radiography, but is premature at this point. Video-assisted thoracoscopic biopsy could be diagnostically definitive, but is also premature at this point in the patient's evaluation.

No prior chest imaging was available for comparison.

Which of the following would be **most useful** for the evaluation of this patient?

1. ⁶⁸Ga-Dotatate PET/CT
2. Enhanced thoracic MRI
3. Lateral decubitus chest radiographs
4. Unenhanced thoracic CT
5. Ventilation / perfusion scintigraphy

Correct!

4. Unenhanced thoracic CT

Typically, unenhanced thoracic CT is the study of choice for the characterization of indeterminate pulmonary nodules when prior imaging is lacking or unavailable. CT may be performed with intravenous iodinated contrast for nodule characterization, typically when a specific “nodule enhancement study” is desired, usually for nodules at least 1 cm in size. This examination measures the degree of enhancement of a nodule, compared to an unenhanced baseline, at each of 4, 1-minute intervals, assessing for degree of contrast enhancement. If the nodule attenuation does not increase 15 HU or greater compared with the baseline unenhanced images, the nodule is very likely benign; enhancement greater than 15 HU at any of the 4 post-contrast time points suggests possible malignancy, but is non-specific, as some benign nodules may show enhancement. Such nodule enhancement CT protocols are not typically performed when more than one nodule is present. Enhanced thoracic MRI is not typically employed for nodule characterization. Some data regarding the ability of MRI to characterize nodules has recently emerged, but the utility of MRI in this regard is still speculative and far less well understood than the role of CT for nodule characterization. Lateral decubitus chest radiography is typically employed to assess for laying pleural effusion or pneumothorax, but neither is a consideration here. ^{131}Xe ventilation – $^{99\text{m}}\text{Tc}$ -MAA perfusion scanning is used to assess pulmonary blood flow, typically for thromboembolic disease assessment or in the context of pre-operative testing for differential pulmonary blood flow assessment, but neither consideration is particularly applicable to a patient with indeterminate pulmonary nodules. Finally, ^{68}Ga -Dotatate PET/CT is a somatostatin analogue and is most commonly employed for assessment of neuroendocrine malignancies, and therefore is not applicable to this patient’s evaluation at this point.

The patient underwent unenhanced CT of the thorax (Figure 2).

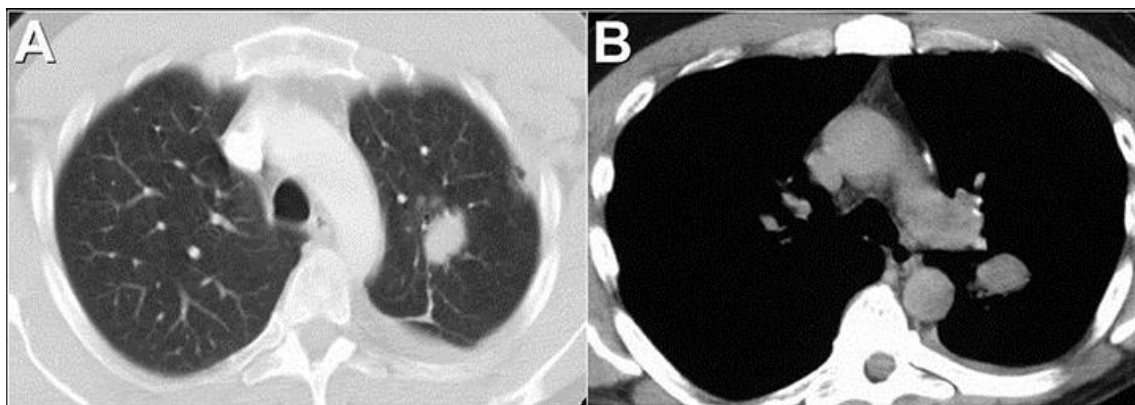


Figure 2. Axial enhanced thoracic CT through the level of the aortic arch (A) displayed in lung windows and slightly more caudally, at the level of the left pulmonary artery (B), the latter displayed in soft tissue windows.

Which of the following is **correct** regarding the description of the thoracic CT findings?

1. CT shows left pulmonary artery aneurysms
2. CT shows left-sided multilobulated pleural thickening and masses
3. CT shows non-specific left upper lobe non-calcified nodules
4. CT shows peribronchial lymph node enlargement
5. CT shows the left lung nodules are cavitory

Correct!

3. CT shows non-specific left upper lobe non-calcified nodules

The unenhanced thoracic CT shows non-specific non-calcified left lung nodules correlating with the chest radiographic findings; the nodules are not cavitary. A trace amount of left pleural liquid may be present, but no lobulated pleural thickening and masses are seen. There is no peribronchial lymph node enlargement. Finally, the nodules appear spatially separated from the left-sided pulmonary arteries and therefore are unlikely to represent pulmonary artery aneurysms.

Which of the following would be **most useful** for further evaluation of this patient?

1. Chamberlain procedure
2. Mediastinoscopy
3. Percutaneous fine needle aspiration biopsy
4. Upper endoscopy
5. Video-assisted thoracoscopic surgical lung biopsy

Correct!

3. Percutaneous fine needle aspiration biopsy

Mediastinoscopy is useful for assessing lesions found in particular mediastinal locations, typically the right paratracheal and anterior subcarinal spaces; such lesions are frequently due to lymphadenopathy. This patient, however, does not clearly have abnormally enlarged mediastinal lymph nodes accessible with either cervical mediastinoscopy or the Chamberlain procedure (a left anterior mediastinotomy), and neither procedure can access the two left-sided lung nodules. Similarly, esophageal endoscopic ultrasound (upper endoscopy) is an excellent tool for visualizing and possibly biopsying lesions in close proximity to the esophagus, such as lymph nodes or masses in the left paratracheal space (2L and 4L), subcarinal space (station 7), periesophageal spaces (station 8), and aorto-pulmonary window (station 5), but is not appropriate for pulmonary nodule evaluation. Video-assisted thoracoscopic surgical lung biopsy could obtain a diagnosis for this patient, but is more invasive percutaneous fine needle aspiration biopsy, and the latter stands a good chance of obtaining tissue that could establish a diagnosis for this patient. Therefore, video-assisted thoracoscopic lung biopsy may be pursued if percutaneous fine needle aspiration biopsy fails to obtain a diagnosis.

The patient underwent percutaneous fine needle aspiration biopsy (Figure 3).

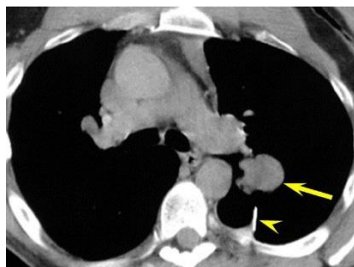


Figure 3. Axial unenhanced prone thoracic CT (image rotated to resemble the typical display of axial CT images) shows the fine needle aspiration biopsy needle (arrowhead) approaching the larger, more caudally located, pulmonary nodule (arrow).

The cytological analysis of the material obtained at this procedure showed granulomatous inflammation, with no organisms identified. No specific features of malignancy were noted, but no definitive diagnosis was offered.

Based on this information, which of the following would be **an appropriate** next management step for this patient?

1. Obtain ^{18}F FDG-PET scan
2. Perform follow up CT in 1 year
3. Perform percutaneous transthoracic core biopsy of one of the upper lobe nodules
4. Treat for fungal infection
5. Treat for mycobacterial infection

Correct!

3. Perform percutaneous transthoracic core biopsy of one of the upper lobe nodules

Percutaneous fine needle aspiration biopsy is a sensitive technique for the diagnosis of lung malignancy. However, the lack of a report of malignant cells on a fine needle aspiration biopsy specimen should not be regarded as indicative of a benign diagnosis for the biopsied nodule, even when “granulomatous inflammation” is seen. Fine needle aspiration biopsy techniques can establish a benign etiology for lung nodules in a substantial number of cases, but one should only have confidence that a benign etiology for a biopsied lung nodule has been firmly established if a specific benign diagnosis is offered by the cytopathologist. In other words, non-malignant descriptive cytopathologic findings should not be considered as equivalent to a benign diagnosis when a patient with a lung nodule undergoes percutaneous biopsy. The addition of core biopsies using a cutting needle may increase the yield of percutaneous lung biopsy over fine needle aspiration techniques alone, particularly for benign nodule etiologies- the latter yields material appropriate for cytological evaluation only, whereas the former provides material that allows for histopathological evaluation also. Often core needle and fine needle aspiration techniques are performed as part of the same biopsy procedure, but not always. When fine needle aspiration techniques fail to provide a definitive diagnosis for a lung nodule undergoing percutaneous biopsy, repeating the procedure using core biopsy techniques may provide a definitive diagnosis.

Given the lack of a clearly high-risk situation and the absence of a definitive diagnosis, presumptive therapy for either mycobacterial or fungal disease is premature. FDG-PET scan is potentially a reasonable test to consider, but tracer uptake within the nodules would prompt a tissue diagnosis, whereas lack of tracer utilization can still be seen with a number of infections, non-infectious causes of nodules, and even low-grade malignancy. Therefore, the results of FDG-PET in this circumstance would probably not be management-altering. Follow up CT is appropriate for nodule evaluation in some patients, and would be a management strategy to consider when percutaneous lung biopsy results are inconclusive. However, given the size of these nodules, follow up CT is probably not appropriate, and even if follow up CT were chosen as a management strategy, the interval for follow up should be much shorter than 1 year, given the size of these nodules.

The patient underwent repeat percutaneous fine needle aspiration biopsy and core biopsy. The material retrieved at this procedure yielded the diagnosis of sarcoma,

Based on this information, what is the **most appropriate** next management step for this patient?

1. ⁶⁸Gallium citrate scintigraphy
2. Contrast-enhanced chest, abdomen, and pelvis CT
3. CT of the brain
4. Lower extremity radiography
5. Pulmonary function testing

Correct!

2. Contrast-enhanced chest, abdomen, and pelvis CT

CT of the brain may play a role in the staging of the diagnosis of sarcoma, but chest, abdomen, and pelvis CT is more appropriate at this point to stage the malignancy, and, if brain imaging is required, MRI of the brain would be preferable to CT for staging purposes. Lower extremity radiography is a reasonable study to perform to assess for the potential primary lesion site, as osteosarcoma arising for the knee would be a primary consideration. However, the type of sarcoma was not specified in the biopsy report (synovial sarcoma, leiomyosarcoma, osteosarcoma, etc.); therefore, the primary sarcoma location could be practically anywhere in the body, and random radiography is unlikely to be revealing in this case. ⁶⁸Ga-citrate scintigraphy is occasionally used to assess diffuse lung disease or for possible infection, but does not play a role for the evaluation of presumed metastatic sarcoma. Pulmonary function testing may provide useful data, particularly as regards operative candidacy if appropriate, but would not be useful for staging presumed metastatic disease or localizing the site of the primary malignancy.

The patient underwent contrast-enhanced chest, abdomen, and pelvis CT (Figure 4) and FDG-PET imaging (Figure 5).

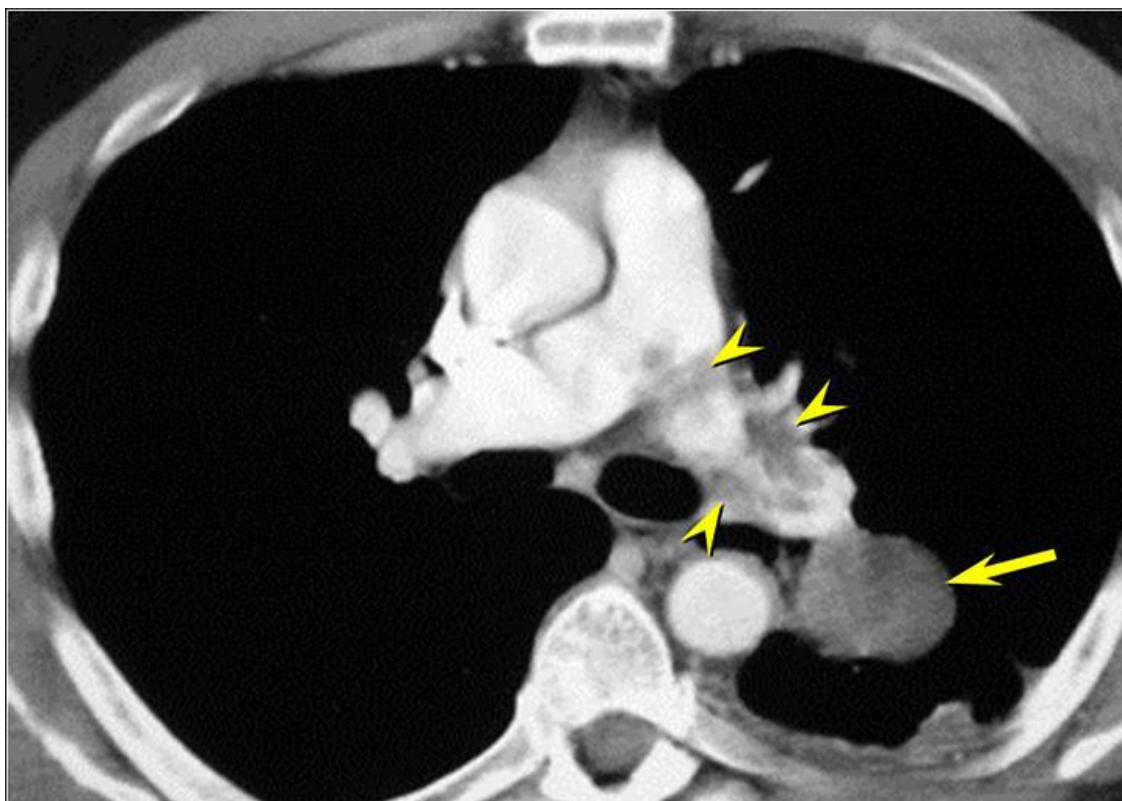

Figure 4. Axial enhanced thoracic CT, obtained as part of a chest, abdomen, and pelvis CT obtained for staging purposes, shows the left perihilar nodule (arrow) is associated with an irregular filling defect (arrowheads) within the left pulmonary artery.

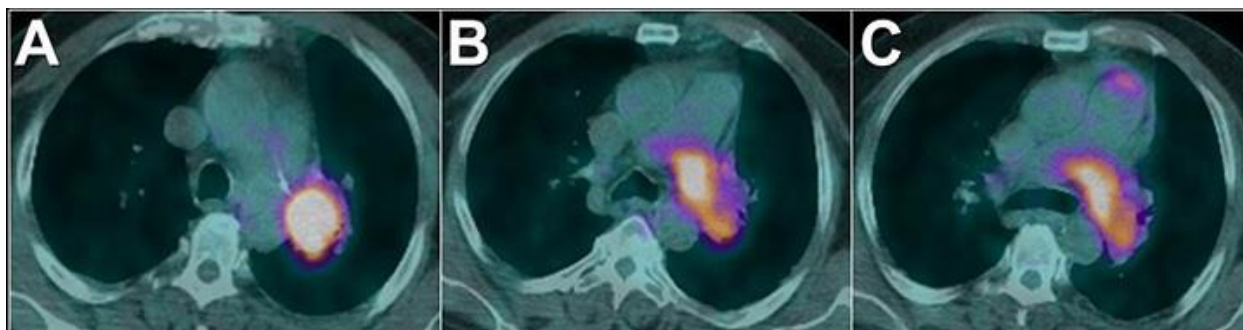


Figure 5. Axial FDG-PET images show intense hypermetabolic activity corresponding to the filling defect within the left pulmonary artery seen at contrast-enhanced thoracic CT.

These examinations did not show features of metastatic disease in the abdomen or pelvis, nor did they show thoracic lymphadenopathy or other lung nodules, in addition to the two nodules detected at chest radiography.

Based on the CT (Figure 4) and FDG-PET study (Figure 5), what is the **most likely diagnosis** for this patient?

1. Non-thrombotic pulmonary embolization
2. Pulmonary artery dissection
3. Pulmonary artery sarcoma
4. Pulmonary embolism
5. Septic pulmonary embolism

Correct!

3. Pulmonary artery sarcoma

is an intraluminal filling defect that is heterogeneous, possibly enhancing, in the left pulmonary artery, which is the same side as the two lung nodules, and this filling defect is highly FDG-avid. The morphology of this lesion is consistent with a lesion arising from the left pulmonary artery itself, and is not typical for thromboembolic disease. Occasionally thromboembolic disease can show FDG tracer uptake, but usually the uptake is far less intense than seen here. In the context of a lung biopsy showing sarcoma, the findings are diagnostic of primary pulmonary artery sarcoma. There are numerous potential causes of non-thrombotic pulmonary artery emboli, including hydatid disease, particulates, foreign bodies [such as wires, filter fragments, catheters, etc.], methyl methacrylate, and other etiologies, but these conditions usually have characteristic appearances that suggest the proper diagnosis, and would not be expected to be FDG-avid. For example, wires and catheters have a tubular appearance, the former appearing metallic, the latter plastic and hyperattenuating. Hydatid embolism may appear as low attenuation, cystic expansion of the pulmonary artery, perhaps accompanied by cardiac cysts as well. The lesion in this circumstance shows soft tissue attenuation and appears quite irregular. Septic embolization often shows no pulmonary arterial filling defects and is associated with multiple bilateral lung nodules with poorly defined margins that undergo cavitation. When septic pulmonary embolization is associated with central pulmonary arterial filling defects, these defects have an appearance identical to thromboembolic disease. Pulmonary arterial dissection is a rare condition that is most commonly encountered in the setting of pulmonary hypertension, on CT appearing a long, typically single, linear filling defect, representing the intimo-medial flap, within the lumen of the pulmonary artery. Pulmonary artery dissection would not show focal, mass-like tracer accumulation at FDG-PET scan.

Diagnosis: Pulmonary artery sarcoma

Post-script. The patient underwent left pneumonectomy without complication. Shortly following his recovery from surgery, repeat chest CT (Figure 6) showed expected post-pneumonectomy findings, without tumor recurrence.

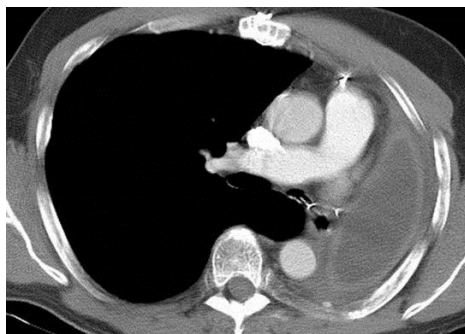

Figure 6: Axial enhanced thoracic CT through the level of the main and right pulmonary artery 3 months following left pneumonectomy shows a normal post-operative appearance of the left pneumonectomy space.

However, 8 months later, repeat chest CT (Figure 7) showed recurrence of the tumor.

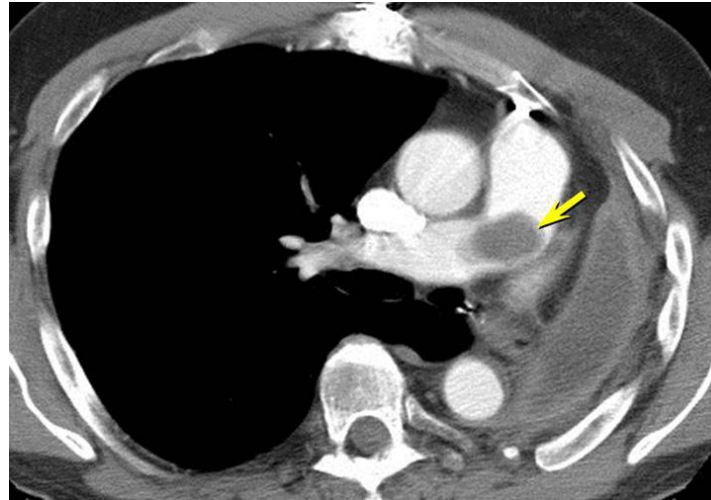

Figure 7. Axial enhanced thoracic CT through the level of the main and right pulmonary artery 10 months following left pneumonectomy shows a new soft tissue filling defect within the main and proximal right pulmonary artery (arrow), representing tumor recurrence.

References

1. Li J, Zhao Q, He L, Zhuang X, Li F. Primary pulmonary artery sarcoma on dual-time point FDG PET/CT imaging. *Clin Nucl Med*. 2016;41(8):656-8. [\[CrossRef\]](#) [\[PubMed\]](#)
2. Umezawa K, Takamura K, Yamamoto M, Kikuchi K. Pulmonary artery intimal sarcoma. *Am J Respir Crit Care Med*. 2014;190(12):e67-8. [\[CrossRef\]](#) [\[PubMed\]](#)
3. Stella F, Davoli F, Brandolini J, Dolci G, Sellitri F, Bini A. Pulmonary artery leiomyosarcoma successfully treated by right pneumonectomy. *Asian Cardiovasc Thorac Ann*. 2009;17(5):513-5. [\[CrossRef\]](#) [\[PubMed\]](#)
4. Kessler A, Son H. Pulmonary artery angiosarcoma on 18F-FDG PET/CT masquerading as pulmonary embolism. *Clin Nucl Med*. 2015;40(1):82-4. [\[CrossRef\]](#) [\[PubMed\]](#)
5. Grazioli V, Vistarini N, Morsolini M, Klersy C, Orlandoni G, Dore R, D'Armini AM. Surgical treatment of primary pulmonary artery sarcoma. *J Thorac Cardiovasc Surg*. 2014;148(1):113-8. [\[CrossRef\]](#) [\[PubMed\]](#)
6. Fatima J, Duncan AA, Maleszewski JJ, Kalra M, Oderich GS, Gloviczki P, Suri RM, Bower TC. Primary angiosarcoma of the aorta, great vessels, and the heart. *J Vasc Surg*. 2013;57(3):756-64. [\[CrossRef\]](#) [\[PubMed\]](#)
7. Restrepo CS, Betancourt SL, Martinez-Jimenez S, Gutierrez FR. Tumors of the pulmonary artery and veins. *Semin Ultrasound CT MR*. 2012;33(6):580-90. [\[CrossRef\]](#) [\[PubMed\]](#)
8. Tueller C, Fischer Biner R, Minder S, Gugger M, Stoupis C, Krause TM, Carrel TP, Schmid RA, Vock P, Nicod LP. FDG-PET in diagnostic work-up of pulmonary artery sarcomas. *Eur Respir J*. 2010;35(2):444-6. [\[CrossRef\]](#) [\[PubMed\]](#)